



Poor prognosis in paediatric haemorrhagic stroke

Hüseyin Çaksen¹, Saniye Yasemin Yılmaz¹, Ahmet Sami Güven¹, Furkan Güldibi¹,
Mehmet Fatih Erdi², Saim Açıkgözoğlu³

¹Division of Paediatric Neurology, Department of Paediatrics, Meram Medical Faculty, Necmettin Erbakan University, Meram, Konya, Turkey

²Department of Neurosurgery, Meram Medical Faculty, Necmettin Erbakan University, Meram, Konya, Turkey

³Department of Radiology, Meram Medical Faculty, Necmettin Erbakan University, Meram, Konya, Turkey

Key words: haemorrhagic stroke, child, prognosis

To the Editors

Stroke, increasingly recognised in children in recent years, is an important cause of long-term morbidity and disability. A wide range of conditions associated with paediatric stroke has been identified, which differ significantly from those in adults. Paediatric stroke can also present with a variety of symptoms and signs, both specific and non-specific [1, 2]. Paediatric haemorrhagic stroke (HS) is a rare but severe condition, with lifelong multifaceted adverse functional, psychosocial, and economic consequences [3].

In this study, we have evaluated the clinical, laboratory and neuroimaging findings in children with HS in order to draw attention to the high morbidity and mortality rates of paediatric HS.

Our study included 12 children with HS admitted to the Department of Paediatric Neurology, Necmettin Erbakan University, Turkey between January 2010 and January 2019. Paediatric HS has been defined as intracerebral haemorrhage, which is brain parenchymal bleeding with or without intraventricular extension, occurring between the ages of 29 days and 18 years [3]. For cerebral palsy, the insult to the brain is believed to occur between the time of conception and the age of two years, at which time a significant amount of motor development has already occurred. A similar injury to the brain after the age of two can have a similar effect however, and this is often also called cerebral palsy. By the age of eight, most of the development of the immature brain is complete, as is gait development, and an insult to the brain now will

result in a more adult-type clinical picture and outcome [4]. Patient data for our study was obtained from a chart review of hospital records. Children who had a history of head trauma, a haemorrhage that was restricted to epidural, subdural, intraventricular or subarachnoid compartments, and children with both cerebral sinovenous thrombosis and haemorrhagic transformation were excluded from our study. The patients were evaluated for demographic characteristics, risk factors, and clinical, laboratory and neuroimaging findings including cranial computerised tomography and cranial magnetic resonance imaging, retrospectively.

Demographic, clinical and laboratory characteristics of the children with HS are set out in Table 1. The most common symptoms and the most common abnormal physical examination finding were headache and altered mental status, respectively. All patients except for one child had at least one risk factor. The most common risk factors were sepsis and thrombocytopenia. Haemorrhage on a single lobe was more common than haemorrhage on multiple lobes (Fig. 1). None of the patients except for one child had vascular imaging. Digital subtraction angiography showed an arteriovenous malformation (AVM) feeding from the left anterior cerebral artery in this child. HS recurred in two patients (15%). Four patients (33.3%) required evacuation of haematoma, and one patient (8.3%) underwent ventriculoperitoneal shunt because of hydrocephalus. Embolisation for cerebral AVM was performed in one patient. HS recurred in two patients (15%) with factor VII deficiency during their follow-up. Three and five HS attacks occurred in these patients, respectively. Three patients

Address for correspondence: Hüseyin Çaksen, Division of Paediatric Neurology, Department of Paediatrics, Meram Medical Faculty, Necmettin Erbakan University, 42090 Meram, Konya, Turkey; e-mail: huseyincaksen@hotmail.com

Received: 09.11.2022 Accepted: 22.12.2022 Early publication date: 20.01.2023

This article is available in open access under Creative Commons Attribution-Non-Commercial-No Derivatives 4.0 International (CC BY-NC-ND 4.0) license, allowing to download articles and share them with others as long as they credit the authors and the publisher, but without permission to change them in any way or use them commercially.

Table 1. Demographic, clinical and laboratory characteristics of children with haemorrhagic stroke

Characteristics*	N = 12 n (%)	Characteristics*	N = 12 n (%)
Age (months) [median (Q1–Q3)]	74 (3–128.5)	Imaging methods	
Gender		Computerised tomography	5 (41.6)
Female	7 (58.3)	Computerised tomography + magnetic resonance imaging	4 (33.3)
Male	5 (41.6)	Magnetic resonance imaging	2 (16.6)
Symptoms		Computerised tomography + digital subtraction angiography	1 (8.3)
Headache	6 (50.0)	Lateralisation of haemorrhage	
Nausea/vomiting	5 (41.6)	Right	5 (41.6)
Prone to sleep	4 (33.3)	Left	4 (33.3)
Restlessness	4 (33.3)	Both sides	3 (25.0)
Impaired consciousness	3 (25.0)	Location of haemorrhage	
Decrease in feeding	3 (25.0)	Single	
Convulsion	2 (16.6)	Parietal lobe	2 (16.6)
Focal numbness	1 (8.3)	Temporal lobe	2 (16.6)
Fainting	1 (8.3)	Frontal lobe	3 (25.0)
Physical examination findings		Subependymal	1 (8.3)
Altered mental status	8 (66.6)	Multiple	
Agitation/irritability	4 (33.3)	Frontal + parietal lobes	1 (8.3)
Left hemiparesis	1 (8.3)	Frontal lobe + temporal + parietal lobes	1 (8.3)
Risk factors/underlying diseases		Frontal lobe + subarachnoid	1 (8.3)
Thrombocytopenia	3 (25.0)	Temporal + occipital lobes	1 (8.3)
Sepsis	3 (25.0)	Hospitalisation in paediatric intensive care unit	
Factor VII deficiency	2 (16.6)	Yes	8 (66.6)
Vitamin K deficiency	2 (16.6)	No	4 (33.3)
Arteriovenous malformation	1 (8.3)	Duration of hospitalisation (days) [median (Q1–Q3)]	27 (10–66)
Afibrinogenemia	1 (8.3)	Prognosis	
Acute lymphoblastic leukaemia	1 (8.3)	Died	3 (25.0)
Disseminated intravascular coagulation	1 (8.3)	Survived without sequelae	1 (8.3)
Immune thrombocytopenic purpura	1 (8.3)	Survived with sequelae	8 (66.6)
Fanconi aplastic anaemia	1 (8.3)	Cerebral palsy	3 (37.5)
Renal tubular acidosis	1 (8.3)	Cerebral palsy + epilepsy	2 (25.0)
		Hemiparesis + epilepsy	1 (12.5)
		Hemiparesis	1 (12.5)
		Paraparesis	1 (12.5)

*One patient had more than one clinical and imaging characteristic

died from sepsis, disseminated intravascular coagulation, and severe haemorrhage, respectively. Nine patients were followed up for 37.6 ± 36.6 months (0.5–120 months). All of these patients, except for one, demonstrated at least one sequel, of which cerebral palsy was the most common. The ages of the patients with cerebral palsy at the time of stroke were 21.6 ± 17.8 months (2–33 months).

It has been reported that the most common symptoms in many series of childhood HS are headache, vomiting, and altered mental status [5–9]. Cerebral AVM has been reported as the most common cause of HS [7–9]. Yock-Corrales et al. [5] reported that seven patients (20.5%) had an AVM and five

patients (14.7%) had a cavernous venous malformation, subarachnoid haemorrhage, and bleeding diathesis. The cause was not established in one third of the patients. In another series, haematological causes were identified in 26 (52%) patients and vascular malformations in seven (14%). No cause could be identified in 13 (26%) patients [6]. Gerstl et al. [7] reported that HS was caused by vascular malformations in more than half of patients. Other risk factors were brain tumour, coagulopathy, and miscellaneous severe underlying diseases. A known aetiology was identified in 121 (86.4%) patients and the leading cause of HS was AVM in 72 (51.4%) patients in another series [8]. In a systematic review, haemorrhages

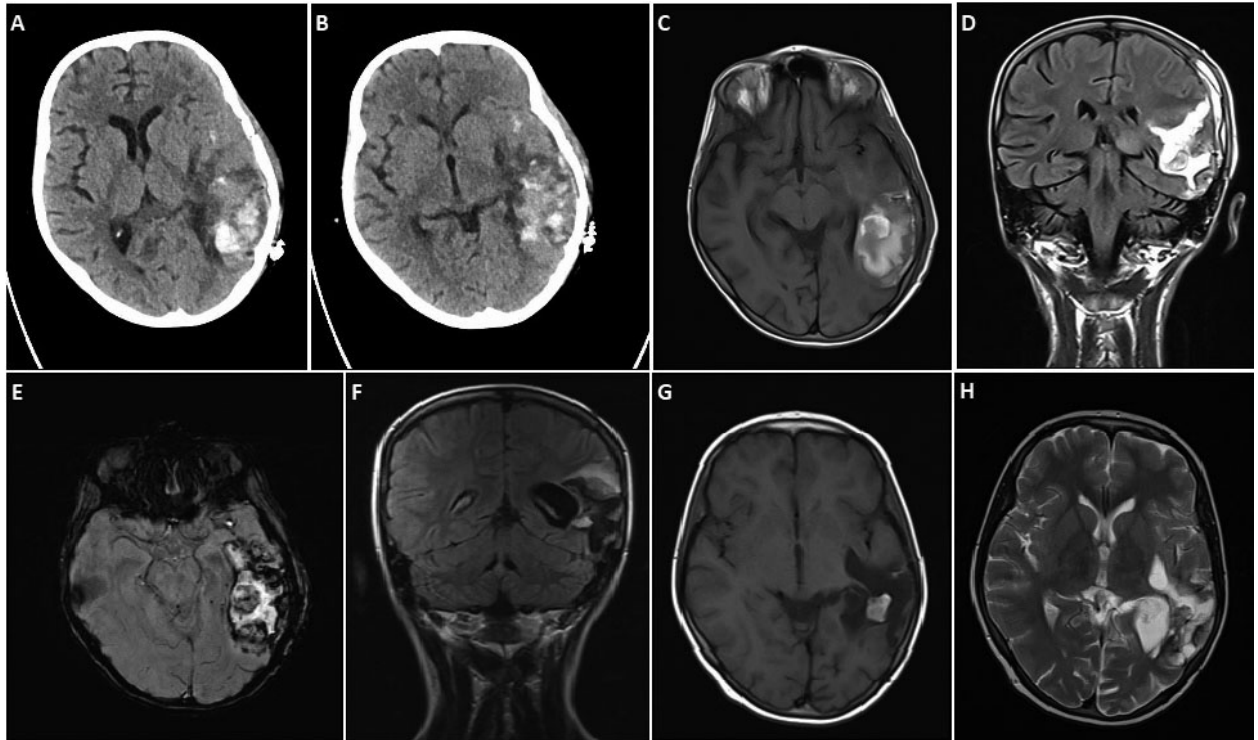


Figure 1. In a 12-year-old girl, cranial computerised tomography demonstrates acute haemorrhage in left temporal lobe (A, B). Fifteen days after evacuation of haematoma, axial T1-weighted and coronal fluid attenuated inversion recovery images show haemorrhage and haematoma (C, D). Axial susceptibility-weighted imaging shows haemorrhage in acute-subacute period (E). After 8 months, coronal fluid attenuated inversion recovery, axial T1-weighted, and axial T2-weighted, images show enlarged occipital horn of left lateral ventricle, porencephaly, and gliotic changes in cerebral parenchyma (F–H)

comprised 43% of all identified aetiologies or risk factors, with AVMs being the most common vascular cause (70.9% of all vascular causes). Haematological and systemic causes, brain tumours, intracranial infections, and cardiac causes were the less commonly encountered risk factors and aetiologies [10].

In line with the literature, the most common symptoms in our series were headache, nausea/vomiting, and altered mental status. All patients except for one had one or more risk factor. Sepsis and thrombocytopenia were the most common risk factors. However, in contrast to the literature, we found vascular malformation in one patient (8.3%) only. This low ratio is related to the fact that not all patients underwent vascular imaging.

HS is a serious condition that may require early surgical intervention in many patients. Of 50 patients with HS, 18 (36%) and three (6%) underwent neurosurgical intervention and vascular interventional radiology, respectively [6]. In another series including 25 children with HS, 17 (68%) required neurosurgical therapy. Neurological deficits were noted in 12 (48%) patients: hemiparesis ± facial palsy ($n = 8$), ataxia ($n = 1$), speech disturbance ($n = 1$), impaired short-term memory ($n = 1$), and multiple severe neurological sequelae ($n = 1$). No data was provided about the long-term outcome in this series [7]. Deng et al. [8] reported that neurological deficits occurred in 72.8% of patients with HS on discharge. The most common complications were epilepsy (17.1%) and

hydrocephalus (12.1%). Early post-stroke rehabilitation strategies using, in addition to the daily rehabilitation programme, virtual reality therapy with visual biofeedback is more effective on upper extremity motor performance than is conventional physiotherapy, and their effectiveness does not diminish with patient age. This may represent a promising addition to conventional physiotherapy in older stroke patients, as well as in younger [11]. Although no death was noted in the series of Uzunhan et al. [12], mortality rates of up to 33.8% have been reported in paediatric HS [5–7, 13]. In our series, four (33.3%) children required evacuation of haematoma and one (7.5%) child underwent ventriculoperitoneal shunt due to hydrocephalus. Three patients (25%) died. During follow-up, neurological sequelae, mostly cerebral palsy, were diagnosed in eight (88.8%) of the nine patients who survived. Conventional physiotherapy was applied to the children with neurological sequelae.

In conclusion, our study showed that sepsis and thrombocytopenia were the most common risk factors in children with HS, and that paediatric HS had a poor prognosis with high morbidity (66.6%) and mortality (25%) rates. Therefore, we suggest that HS can be prevented by early diagnosis and treatment of the risk factors that lead to HS in a group of patients, and thus the prognosis of HS can be improved.

Conflicts of interest: *None.*

Funding: *None.*

References

1. Oborska Z, Urban P, Wychowanec K, et al. Paediatric stroke - a review of current guidelines for diagnosis and treatment. *Neurol Neurochir Pol.* 2020; 54(2): 116–124, doi: [10.5603/PJNNS.a2020.0010](https://doi.org/10.5603/PJNNS.a2020.0010), indexed in Pubmed: [31985031](https://pubmed.ncbi.nlm.nih.gov/31985031/).
2. Powers WJ, Rabinstein AA, Ackerson T, et al. Guidelines for the early management of patients with acute ischemic stroke: 2019 update to the 2018 guidelines for the early management of acute ischemic stroke: a guideline for healthcare professionals from the american heart association/american stroke association. *Stroke.* 2019; 50(12): e344–e418, doi: [10.1161/STR.0000000000000211](https://doi.org/10.1161/STR.0000000000000211), indexed in Pubmed: [31662037](https://pubmed.ncbi.nlm.nih.gov/31662037/).
3. Boulouis G, Blauwblomme T, Hak JF, et al. Nontraumatic pediatric intracerebral hemorrhage. *Stroke.* 2019; 50(12): 3654–3661, doi: [10.1161/STROKEAHA.119.025783](https://doi.org/10.1161/STROKEAHA.119.025783), indexed in Pubmed: [31637968](https://pubmed.ncbi.nlm.nih.gov/31637968/).
4. Spence DD, Sheffer BW. Cerebral palsy. In: Azar F, Canale STW, Beaty J. ed. *Campbell's Operative Orthopaedics*. 14th ed. Elsevier, Amsterdam 2020: 1316–1368.
5. Yock-Corrales A, Varela-Bulgarelli F, Barboza C, et al. Presentation of acute childhood stroke in a tertiary pediatric emergency department. *Pediatr Emerg Care.* 2018; 34(8): 552–557, doi: [10.1097/PEC.0000000000000918](https://doi.org/10.1097/PEC.0000000000000918), indexed in Pubmed: [27749807](https://pubmed.ncbi.nlm.nih.gov/27749807/).
6. Abbas Q, Merchant QU, Nasir B, et al. Spectrum of intracerebral hemorrhage in children: a report from PICU of a resource limited country. *Crit Care Res Pract.* 2016; 2016: 9124245, doi: [10.1155/2016/9124245](https://doi.org/10.1155/2016/9124245), indexed in Pubmed: [26881068](https://pubmed.ncbi.nlm.nih.gov/26881068/).
7. Gerstl L, Badura K, Heinen F, et al. Childhood haemorrhagic stroke: a 7-year single-centre experience. *Arch Dis Child.* 2019; 104(12): 1198–1202, doi: [10.1136/archdischild-2018-316749](https://doi.org/10.1136/archdischild-2018-316749), indexed in Pubmed: [31221624](https://pubmed.ncbi.nlm.nih.gov/31221624/).
8. Deng Y, Liu G, Zhang G, et al. Childhood strokes in China describing clinical characteristics, risk factors and performance indicators: a case-series study. *Stroke Vasc Neurol.* 2022; 7(2): 140–148, doi: [10.1136/svn-2021-001062](https://doi.org/10.1136/svn-2021-001062), indexed in Pubmed: [34862326](https://pubmed.ncbi.nlm.nih.gov/34862326/).
9. Pangprasertkul S, Borisoot W, Buawangpong N, et al. Comparison of arterial ischemic and hemorrhagic pediatric stroke in etiology, risk factors, clinical manifestations, and prognosis. *Pediatr Emerg Care.* 2022; 38(9): e1569–e1573, doi: [10.1097/PEC.0000000000002614](https://doi.org/10.1097/PEC.0000000000002614), indexed in Pubmed: [35113509](https://pubmed.ncbi.nlm.nih.gov/35113509/).
10. Ciochon UM, Bindslev JB, Hoei-Hansen CE, et al. Causes and risk factors of pediatric spontaneous intracranial hemorrhage – a systematic review. *Diagnostics (Basel).* 2022; 12(6), doi: [10.3390/diagnostics12061459](https://doi.org/10.3390/diagnostics12061459), indexed in Pubmed: [35741269](https://pubmed.ncbi.nlm.nih.gov/35741269/).
11. Gueye T, Dedkova M, Rogalewicz V, et al. Early post-stroke rehabilitation for upper limb motor function using virtual reality and exoskeleton: equally efficient in older patients. *Neurol Neurochir Pol.* 2021; 55(1): 91–96, doi: [10.5603/PJNNS.a2020.0096](https://doi.org/10.5603/PJNNS.a2020.0096), indexed in Pubmed: [33314016](https://pubmed.ncbi.nlm.nih.gov/33314016/).
12. Uzunhan TA, Aydinli N, Çalışkan M, et al. Short-term neurological outcomes in ischemic and hemorrhagic pediatric stroke. *Pediatr Int.* 2019; 61(2): 166–174, doi: [10.1111/ped.13737](https://doi.org/10.1111/ped.13737), indexed in Pubmed: [30449056](https://pubmed.ncbi.nlm.nih.gov/30449056/).
13. Lo WD, Hajek C, Pappa C, et al. Outcomes in children with hemorrhagic stroke. *JAMA Neurol.* 2013; 70(1): 66–71, doi: [10.1001/jamaneurol.2013.577](https://doi.org/10.1001/jamaneurol.2013.577), indexed in Pubmed: [23108798](https://pubmed.ncbi.nlm.nih.gov/23108798/).