



KARDIOLOGIA POLSKA

Polish Heart Journal
The Official Peer-reviewed Journal
of the Polish Cardiac Society
since 1957

Online first

This is a provisional PDF only. Copyedited and fully
formatted version will be made available soon

ISSN 0022-9032

e-ISSN 1897-4279

Apples and oranges in coronary artery disease diagnostics

Authors: J Peper, LM Becker, MJ Swaans

Article type: Editorial

Received: January 3, 2023

Accepted: January 3, 2023

Early publication date: February 15, 2023

This article is available in open access under Creative Common Attribution-Non-Commercial-No Derivatives 4.0 International (CC BY-NC-ND 4.0) license, allowing to download articles and share them with others as long as they credit the authors and the publisher, but without permission to change them in any way or use them commercially.

Apples and oranges in coronary artery disease diagnostics

J Peper, LM Becker, MJ Swaans

Coronary artery disease (CAD) is the most common type of heart disease and causes morbidity and mortality globally despite advances in medical and procedural therapies [1]. The diagnostic pathway for stable CAD includes non-invasive tests prior to invasive testing to diagnose patients with stable chest pain and a low or intermediate probability of CAD. The current European Society of Cardiology (ESC) guidelines for Chronic Coronary Artery Syndromes recommend coronary computed tomography angiography (CTA) for patients with low clinical likelihood of obstructive CAD, and ischemia testing, preferably by imaging, in patients with a high likelihood of CAD [2]. Whereas CTA only focus on anatomical information, non-invasive imaging technique as computed tomography [CT] derived fractional flow reserve (CT-FFR) combines both anatomical and functional information based on standard CTA.

Risk stratification and diagnostics are conducted to confirm or rule out stable CAD. The vast majority of these patients do not have CAD and even in patients with CAD, a large proportion is not in need for revascularization. Many patients undergoing invasive coronary angiography (ICA) after CTA have no indication for treatment and ICA could have been avoided. Both CTA and ICA are associated with the use of radiation and contrast media. Considering their possible detrimental effect on skin, bone marrow and kidney function, minimizing the utilization of radiation and contrast media would be beneficial to the patient [3, 4]. CT-FFR seems promising due to the addition of functional information to existing anatomic features without the need for additional scan time (radiation use) or contrast use [5]. Furthermore, selective ICA by means of visualizing the diseased vessel only, might also reduce the need for radiation dose and contrast agent volume. Possible risk of this hybrid strategy can be found in missing significant coronary stenosis that requires revascularization.

In the present issue of *Kardiologia Polska (Kardiol Pol, Polish Heart Journal)*, Dębski et al. [6] further refined this hybrid strategy by performing ICA only for the vessel that is significantly narrowed according to CT-FFR. The main objective was to assess the impact of a selective invasive approach (diseased-vessel-only) in patients undergoing ICA following coronary CTA and CT-FFR as compared to the standard of care (complete ICA). The study enrolled 100 consecutive patients who underwent ICA following CTA. ICA was performed if the CTA findings suggested significant or borderline stenosis in an artery suitable for

intervention in the presence of clinical symptoms suggestive of CAD or additional tests indicating cardiac ischemia. The diagnostic performance of CTA (including quantitative diameter stenosis analysis) and CT-FFR in the detection of significant CAD was assessed using ICA with quantitative coronary angiography (QCA) as reference. Diameter stenosis of at least 50% on CTA or ICA was defined as CAD. The authors observed an excellent diagnostic performance of CTA — sensitivity of 99%, specificity of 97%, positive predictive value (PPV) of 94% and negative predictive value (NPV) of 100%. Beyond the diagnostic performance, a comparison of contrast agent and radiation use when performing ICA strategy versus “diseased-vessel-only” ICA was made. Using CTA to guide ICA leads to a contrast volume reduction of 35% and estimated radiation dose reduction of 42%. Both can be further reduced when using CT-FFR to 57% and 69%, respectively.

The results of this study of Dębski et al. [6] seems very promising, especially given the increasing numbers of patients undergoing CTA. However, the results should be interpreted with caution. First of all, in the discussion is mentioned that the reported diagnostic values for both CTA and CT-FFR are similar to those found in previous studies. In fact, these are remarkably higher, particularly for CTA and especially since a threshold of 50% diameter reduction was used (Figure 1) [7, 8]. A possible explanation can be found in the selection criteria of the study. Only patients that underwent ICA after a significant or borderline CTA were included, causing significant selection bias.

Secondly, for intermediate coronary stenoses (50%–90% diameter reduction), the correlation between anatomical stenosis severity and hemodynamical significance is not straightforward [9]. This is regardless of operator experience or the accuracy of stenosis severity assessment. A stenosis of 50% diameter reduction can lead to impaired coronary blood flow, while a stenosis of 80% might have no relevant impact. Especially if a threshold of 50% diameter stenosis is used as revascularization indication, there exists a significant risk of overtreatment. This is associated with worse long-term clinical outcomes. Therefore, current guidelines recommend functional assessment of intermediary lesions to assess treatment indication [10].

The current standard for functional assessment is invasive fractional flow reserve (FFR), the ratio of blood pressure distal to a stenosis divided by the proximal pressure [2]. Imaging-based techniques that derive functional information from images, such as CT-FFR, are calibrated and verified against invasive FFR. However, in Debski et al. [6] a functional assessment was compared to an anatomical reference as revascularization indication was assessed with QCA. This is like comparing apples and oranges — they are not comparable. However, the authors are not alone in making this skewed comparison. When indicated,

functional measurements such as FFR are only used in less than 20% of situations and many studies assessing the diagnostic value of CT-FFR have compared this to QCA, or even visual estimates [11, 12]. The authors conclude that skipping vessels during ICA that had <50% diameter stenosis on CTA and negative FFR-CT will not lead to missed diagnoses. This is difficult to assess based on this data alone as this study only included patients that underwent both CTA and ICA without functional measurements. Moreover, the future position of revascularization in the management of stable CAD is uncertain. Previous studies as the ISCHEMIA [13] and ORBITA-trial [14] showed that the actual benefit of revascularization in stable CAD might be less than previously thought.

To conclude: the future position of revascularization in stable CAD remains uncertain, although the current guidelines still recommend revascularization of ischemia-inducing lesions. With the development of noninvasive assessments such as CT-FFR, functional assessments might finally make their way from the guidelines into routine clinical care.

Article information

Conflict of interest: None declared.

Funding: None.

Open access: This article is available in open access under Creative Common Attribution-Non-Commercial-No Derivatives 4.0 International (CC BY-NC-ND 4.0) license, allowing to download articles and share them with others as long as they credit the authors and the publisher, but without permission to change them in any way or use them commercially. For commercial use, please contact the journal office at kardiologiapolska@ptkardio.pl.

REFERENCES

1. American Heart Association.. 2021 Heart Disease & Stroke Statistical Update Fact Sheet Global Burden of Disease High Blood Cholesterol and Other Lipids. Am Heart Assoc. 2021.
2. Saraste A, Knuuti J, Saraste A, et al. 2019 ESC Guidelines for the diagnosis and management of chronic coronary syndromes. *Eur Heart J*. 2020; 41(3): 407–477, doi: [10.1093/eurheartj/ehz425](https://doi.org/10.1093/eurheartj/ehz425), indexed in Pubmed: [31504439](https://pubmed.ncbi.nlm.nih.gov/31504439/).
3. Picano E, Santoro G, Vano E. Sustainability in the cardiac cath lab. *Int J Cardiovasc Imaging*. 2007; 23(2): 143–147, doi: [10.1007/s10554-006-9148-x](https://doi.org/10.1007/s10554-006-9148-x), indexed in Pubmed: [17033729](https://pubmed.ncbi.nlm.nih.gov/17033729/).
4. European Society of Radiology (ESR). White paper on radiation protection by the European Society of Radiology. *Insights Imaging*. 2011; 2(4): 357–362, doi: [10.1007/s13244-011-0108-1](https://doi.org/10.1007/s13244-011-0108-1), indexed in Pubmed: [22358387](https://pubmed.ncbi.nlm.nih.gov/22358387/).
5. Peper J, Schaap J, Kelder JC, et al. Added value of computed tomography fractional flow reserve in the diagnosis of coronary artery disease. *Sci Rep*. 2021; 11(1): 6748, doi: [10.1038/s41598-021-86245-8](https://doi.org/10.1038/s41598-021-86245-8), indexed in Pubmed: [33762686](https://pubmed.ncbi.nlm.nih.gov/33762686/).
6. Dębski MA, Kruk M, Bujak S, et al. Benefits of the selective invasive strategy guided by CTA and CT-FFR in patients with coronary artery disease. *Kardiol Pol*. 2022 [epub ahead of print], doi: [10.33963/KP.a2022.0264](https://doi.org/10.33963/KP.a2022.0264), indexed in Pubmed: [36446067](https://pubmed.ncbi.nlm.nih.gov/36446067/).
7. Celeng C, Leiner T, Maurovich-Horvat P, et al. Anatomical and Functional Computed Tomography for Diagnosing Hemodynamically Significant Coronary Artery Disease: A Meta-Analysis. *JACC Cardiovasc Imaging*. 2019; 12(7 Pt 2): 1316–1325, doi: [10.1016/j.jcmg.2018.07.022](https://doi.org/10.1016/j.jcmg.2018.07.022), indexed in Pubmed: [30219398](https://pubmed.ncbi.nlm.nih.gov/30219398/).
8. Zhou T, Wang X, Wu T, et al. Clinical application of computed tomography angiography and fractional flow reserve computed tomography in patients with coronary artery disease: A meta-analysis based on pre- and post-test probability. *Eur J Radiol*. 2021; 139: 109712, doi: [10.1016/j.ejrad.2021.109712](https://doi.org/10.1016/j.ejrad.2021.109712), indexed in Pubmed: [33865062](https://pubmed.ncbi.nlm.nih.gov/33865062/).
9. Peper J, Becker LM, van Kuijk JP, et al. Fractional flow reserve: patient selection and perspectives. *Vasc Health Risk Manag*. 2021; 17: 817–831, doi: [10.2147/VHRM.S286916](https://doi.org/10.2147/VHRM.S286916), indexed in Pubmed: [34934324](https://pubmed.ncbi.nlm.nih.gov/34934324/).
10. Neumann FJ, Sousa-Uva M, Neumann FJ, et al. Considerations for the choice between coronary artery bypass grafting and percutaneous coronary intervention as

revascularization strategies in major categories of patients with stable multivessel coronary artery disease: an accompanying article of the task force of the 2018 ESC/EACTS guidelines on myocardial revascularization. *Eur Heart J.* 2019; 40(2): 204–212, doi: [10.1093/eurheartj/ehy532](https://doi.org/10.1093/eurheartj/ehy532), indexed in Pubmed: [30165435](https://pubmed.ncbi.nlm.nih.gov/30165435/).

11. Dattilo PB, Prasad A, Honeycutt E, et al. Contemporary patterns of fractional flow reserve and intravascular ultrasound use among patients undergoing percutaneous coronary intervention in the United States: insights from the National Cardiovascular Data Registry. *J Am Coll Cardiol.* 2012; 60(22): 2337–2339, doi: [10.1016/j.jacc.2012.08.990](https://doi.org/10.1016/j.jacc.2012.08.990), indexed in Pubmed: [23194945](https://pubmed.ncbi.nlm.nih.gov/23194945/).

12. Parikh RV, Liu G, Plomondon ME, et al. Utilization and Outcomes of Measuring Fractional Flow Reserve in Patients With Stable Ischemic Heart Disease. *J Am Coll Cardiol.* 2020; 75(4): 409–419, doi: [10.1016/j.jacc.2019.10.060](https://doi.org/10.1016/j.jacc.2019.10.060), indexed in Pubmed: [32000953](https://pubmed.ncbi.nlm.nih.gov/32000953/).

13. Maron D, Hochman J, Reynolds H, et al. Initial Invasive or Conservative Strategy for Stable Coronary Disease. *N Engl J Med.* 2020; 382(15): 1395–1407, doi: [10.1056/nejmoa1915922](https://doi.org/10.1056/nejmoa1915922).

14. Al-Lamee R, Thompson D, Dehbi HM, et al. Percutaneous coronary intervention in stable angina (ORBITA): a double-blind, randomised controlled trial. *Lancet.* 2018; 391(10115): 31–40, doi: [10.1016/S0140-6736\(17\)32714-9](https://doi.org/10.1016/S0140-6736(17)32714-9), indexed in Pubmed: [29103656](https://pubmed.ncbi.nlm.nih.gov/29103656/).

%

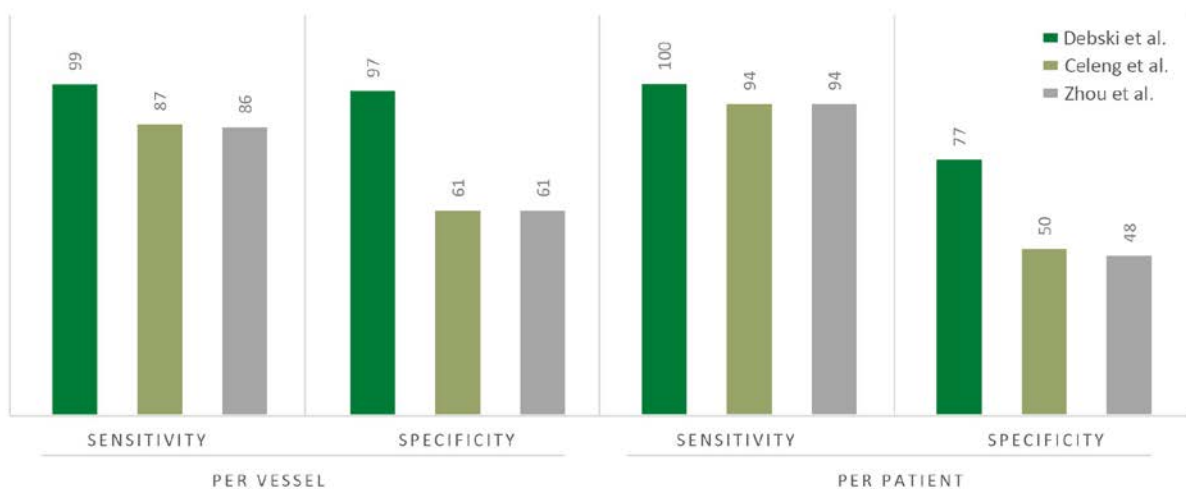


Figure 1. Sensitivity and specificity of computed tomography angiography for the detection of coronary artery disease (CAD). CAD is defined by an angiographic stenosis >50%.

Coronary computed tomographic angiography performance presented by Dębski et al. [6] are represented in dark green. For the comparison, the results of the meta-analyses of Celeng [7] and Zhou [8] are displayed in olive and grey