



Left anterior descending artery injury during routine dual-chamber pacemaker implantation leading to myocardial infarction

Authors: Piotr Denysiuk, Erwin Ciechański, Tomasz Klecha, Adrianna Denysiuk, Gerard Grossmann, Marcin Szczasny, Piotr Błaszczak

Article type: Clinical vignette

Received: December 4, 2022

Accepted: February 5, 2023

Early publication date: February 17, 2023

Left anterior descending artery injury during routine dual-chamber pacemaker implantation leading to myocardial infarction

Short title: Pacemaker implantation complicated by myocardial infarction

Piotr Denysiuk¹, Erwin Ciechański^{1, 2}, Tomasz Klecha¹, Adrianna Denysiuk³, Gerard Grossmann¹, Marcin Szczasny¹, Piotr Błaszczak¹

¹Department of Cardiology, Stefan Cardinal Wyszyński Province Specialist Hospital, Lublin, Poland

²Department of Toxicology, Medical University of Lublin, Poland

³Voivodeship Center of Occupational Medicine Prevention and Treatment Center in Lublin, Lublin, Poland

Correspondence to:

Piotr Denysiuk, MD,
Department of Cardiology,
Stefan Cardinal Wyszyński Regional Specialist Hospital,
al. Kraśnicka 100, 20–718 Lublin, Poland,
phone: +48 79 146 05 07,
e-mail: piotr.denysiuk@gmail.com

A 73-year-old male was admitted to the Cardiology Ward from the Emergency Department after an episode of syncope for further evaluation and treatment. The patient had a history of hypertension and recurrent presyncope episodes. On admission he was in stable condition with no significant findings on physical examination. Electrocardiogram recorded after the syncope revealed sinus bradycardia with junctional escape rhythm and a heart rate of 38 beats per minute. There were no other significant findings on 24-hour Holter monitoring. The patient was diagnosed with symptomatic sinus node dysfunction and scheduled for a dual-chamber pacemaker implantation the next day. The procedure was carried out routinely with a 52 cm right atrial lead placed in the right atrial appendage with a capture threshold of 1 V at 0.4 ms, sensing at 3 mV and impedance of 628 Ω and a 58 cm ventricular lead placed in the right ventricular outflow tract with a capture threshold of 0.5 V at 0.4 ms, sensing at >12 mV and impedance of 640 Ω . Lead placement was confirmed with two independent fluoroscopy

angles. Within minutes after placement of the ventricular lead, the patient developed chest pain and became hypotensive with a sudden drop of blood pressure to 60/30 mm Hg. Pneumothorax and cardiac tamponade were ruled out using fluoroscopy in 30° left anterior oblique view and intraprocedural transthoracic echocardiography. The patient status quickly improved after administration of inotropes and intravenous fluids and the symptoms subsided; the procedure was completed without further complications. After obtaining a post-procedure 12-lead electrocardiogram ST-segment elevation myocardial infarction was confirmed (**Figure 1A**). Emergency coronary angiography revealed critical stenosis of the left anterior descending artery with compromised distal flow, the diagonal branch, and a significant stenosis of the circumflex branch of the left coronary artery. An angioplasty of the left anterior descending artery and the diagonal branch was performed using two drug eluting stents; the patient was scheduled for an elective circumflex artery angioplasty before discharge.

Due to the complicated pacemaker implantation course and the electrocardiogram suggesting epicardial pacing, suspicion of direct injury to the coronary artery was raised. After careful re-evaluation of the coronary angiography, a direct left anterior descending artery perforation by the ventricular lead helix was confirmed (**Figure 1B, D**, Supplementary material, *Video S1–S3*). The lead was replaced without further complications and the scheduled angioplasty was carried out as planned. No significant pericardial effusion was present on control echocardiography following the procedure. After an observation period the patient was discharged home.

Myocardial infarction due to coronary artery injury is a rare complication of cardiac electronic devices implantation [1]. There were only several recorded cases of left anterior descending artery injury caused by a ventricular lead [2–5]. In the presented case, the patient developed symptoms of acute myocardial infarction due to inadvertent malposition of the ventricular lead in the right ventricle anteroseptal junction leading to coronary artery perforation by the lead helix, requiring urgent revascularization and lead replacement. Routine use of a 12-lead ECG and right anterior oblique (RAO) imaging during implantation should be considered to avoid this high-risk pseudo-septal position and potential complications. Utilization of novel imaging algorithms such as iterative metal artifact reduction for computed tomography might be helpful for better evaluation of the perforated leads [6].

Supplementary material

Supplementary material is available at https://journals.viamedica.pl/kardiologia_polska

Article information

Conflict of interest: None declared.

Funding: None.

Open access: This article is available in open access under Creative Common Attribution-Non-Commercial-No Derivatives 4.0 International (CC BY-NC-ND 4.0) license, allowing to download articles and share them with others as long as they credit the authors and the publisher, but without permission to change them in any way or use them commercially. For commercial use, please contact the journal office at kardiologiapolska@ptkardio.pl.

REFERENCES

1. Pang BJ, Barold SS, Mond HG. Injury to the coronary arteries and related structures by implantation of cardiac implantable electronic devices. *Europace*. 2015; 17(4): 524–529, doi: [10.1093/europace/euu345](https://doi.org/10.1093/europace/euu345), indexed in Pubmed: [25564549](https://pubmed.ncbi.nlm.nih.gov/25564549/).
2. Parwani AS, Rolf S, Haverkamp W. Coronary artery occlusion due to lead insertion into the right ventricular outflow tract. *Eur Heart J*. 2009; 30(4): 425, doi: [10.1093/eurheartj/ehn487](https://doi.org/10.1093/eurheartj/ehn487), indexed in Pubmed: [18987097](https://pubmed.ncbi.nlm.nih.gov/18987097/).
3. Nishiyama N, Takatsuki S, Kimura T, et al. Implantation of the right ventricular lead of an implantable cardioverter-defibrillator complicated by apical myocardial infarction. *Circulation*. 2012; 126(10): 1314–1315, doi: [10.1161/CIRCULATIONAHA.112.097527](https://doi.org/10.1161/CIRCULATIONAHA.112.097527), indexed in Pubmed: [22949541](https://pubmed.ncbi.nlm.nih.gov/22949541/).
4. Karalis I, Bleeker GB, SchaliJ MJ. Obstruction of distal left anterior descending artery by the right ventricular lead of an implantable cardiac defibrillator. *Neth Heart J*. 2014; 22(6): 309, doi: [10.1007/s12471-012-0272-z](https://doi.org/10.1007/s12471-012-0272-z), indexed in Pubmed: [22592562](https://pubmed.ncbi.nlm.nih.gov/22592562/).
5. Hayase J, Shapiro H, Bae D, et al. Dual chamber pacemaker implantation complicated by left anterior descending coronary artery injury. *JACC Case Rep*. 2019; 1(4): 633–637, doi: [10.1016/j.jaccas.2019.10.001](https://doi.org/10.1016/j.jaccas.2019.10.001), indexed in Pubmed: [34316895](https://pubmed.ncbi.nlm.nih.gov/34316895/).
6. Młynarski R, Sosna M, Honkowicz M, et al. Usefulness of metal artifact reduction algorithms from pacemaker lead in diagnostic of late perforation: The right choice makes it easier to make a decision. *Kardiol Pol*. 2023 [Epub ahead of print], doi: [10.33963/KP.a2023.0014](https://doi.org/10.33963/KP.a2023.0014), indexed in Pubmed: [36640017](https://pubmed.ncbi.nlm.nih.gov/36640017/).

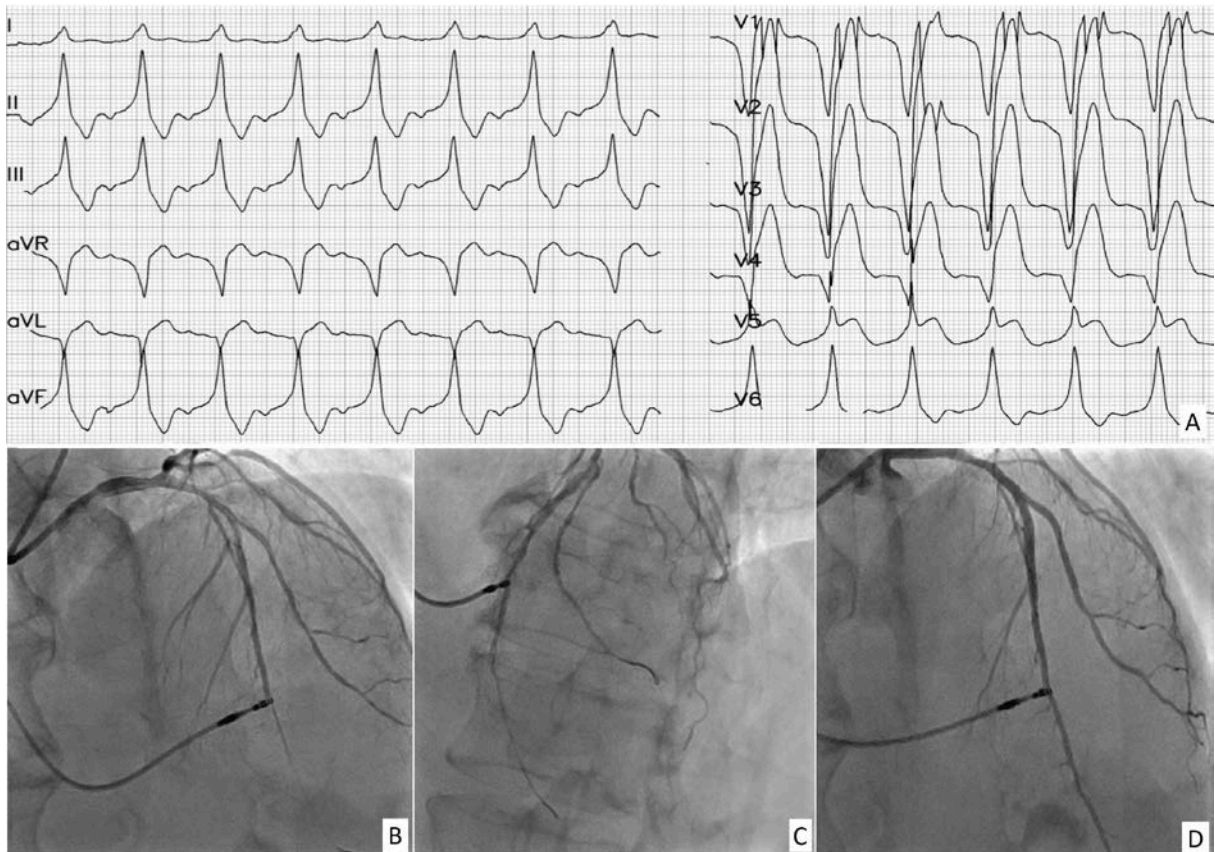


Figure 1. **A.** ST-segment elevation myocardial infarction in bipolar paced evolutions fulfilling Sgarbossa Criteria — concordant ST elevation >1 mm in lead V5, discordant ST elevation >5 mm in leads V2–V4. Atypical QRS morphology suggesting possible epicardial pacing. **B.** Coronary angiography revealing left anterior descending artery perforation by the ventricular lead helix with TIMI grade 1 flow beyond the injury point, RAO 19°, CRA 35° view. **C.** LAO 33°, CRA 25° view. **D.** Control angiography after coronary stenting RAO 15°, CRA 36° view

Abbreviations: CRA, cranial angle; LAO, left anterior oblique; RAO, right anterior oblique;