



Hypofractionated Stereotactic Ablative Radiotherapy for Recurrent or Oligometastatic Tumours in Children and Young Adults

Document Version
Final published version

[Link to publication record in Manchester Research Explorer](#)

Citation for published version (APA):

Chandy, E., Taylor, A., Gaito, S., Wells, E. J., Jones, C., Meehan, C., Burland, H., Stone, J., Snowball, C., Mashru, J., Riddell, C., Hon, Y., Welsh, L. C., Saran, F., & Mandeville, H. (2020). Hypofractionated Stereotactic Ablative Radiotherapy for Recurrent or Oligometastatic Tumours in Children and Young Adults. *Clinical Oncology*, 32(5), 316-326.

Published in:
Clinical Oncology

Citing this paper

Please note that where the full-text provided on Manchester Research Explorer is the Author Accepted Manuscript or Proof version this may differ from the final Published version. If citing, it is advised that you check and use the publisher's definitive version.

General rights

Copyright and moral rights for the publications made accessible in the Research Explorer are retained by the authors and/or other copyright owners and it is a condition of accessing publications that users recognise and abide by the legal requirements associated with these rights.

Takedown policy

If you believe that this document breaches copyright please refer to the University of Manchester's Takedown Procedures [<http://man.ac.uk/04Y6Bo>] or contact uml.scholarlycommunications@manchester.ac.uk providing relevant details, so we can investigate your claim.





Original Article

Hypofractionated Stereotactic Ablative Radiotherapy for Recurrent or Oligometastatic Tumours in Children and Young Adults



E. Chandy^{*}, H. Taylor^{*}, S. Gaito^{*}, E. Wells^{*}, C. Jones^{*}, C. Meehan^{*}, H. Burland^{*}, J. Stone^{*}, C. Snowball^{*}, J. Mashru^{*}, C. Riddell^{*}, Y. Hon^{*}, L. Welsh^{*†}, F. Saran^{*‡}, H. Mandeville^{*†}

^{*}Royal Marsden Hospital, Sutton, UK

[†]Institute of Cancer Research, Sutton, UK

[‡]Auckland City Hospital, Grafton, Auckland, New Zealand

Received 16 July 2019; received in revised form 9 September 2019; accepted 20 October 2019

Abstract

Aims: Cancer remains a leading cause of death in children and adolescents in the developed world. Despite advances in oncological management, rates of primary treatment failure remain significant. Radiation of recurrent or metastatic disease improves survival in adults but there is little data to support clinical decision making in the paediatric/teenage and young adult population.

Materials and methods: We present a retrospective case series of 14 patients treated with stereotactic ablative body radiotherapy or stereotactic radiosurgery at The Royal Marsden Hospital from September 2011 to December 2015. Eligible patients were aged <25 years, with Lansky/Karnofsky performance status ≥ 60 with confirmed relapsed or metastatic tumour in fewer than three sites. Follow-up was in accordance with standard clinical care and included regular outpatient review and radiological surveillance. Local control, progression-free survival and overall survival are presented.

Results: Data for 14 patients with 18 treated lesions were included. The median patient age was 15 years (range 5–20 years). Nine patients were treated for local recurrence and five for metastatic lesions. All patients had already undergone multiple previous treatments. Eleven patients had undergone previous radiotherapy. The median interval between the completion of initial radiotherapy and reirradiation was 29.0 months (range 0.2–49.5 months). The median follow-up was 3.4 years (range 0.28–6.4 years). The 1-year local control rate was 78.6% and the 2-year local control rate was 57.1%. Overall median survival was 58.4 months (95% confidence interval 33.8–82.9 months). Cumulative biologically effective doses (BED) over 200 Gy were associated with late toxicity ($P = 0.04$).

Conclusion: Radical doses of short-course hypofractionated radiotherapy can achieve excellent local control and may contribute to the prolongation of overall survival. There is a need for prospective trials exploring the use of ablative radiotherapy in metastatic disease in paediatric/teenage and young adult patients in order to establish safe and effective treatment schedules.

Crown Copyright © 2019 Published by Elsevier Ltd on behalf of The Royal College of Radiologists. This is an open access article under the CC BY-NC-ND license (<http://creativecommons.org/licenses/by-nc-nd/4.0/>).

Keywords: Oligometastatic disease; Paediatric oncology; Stereotactic radiosurgery; Stereotactic radiotherapy

Introduction

Cancer remains a leading cause of death in children and adolescents. Despite advances in oncological management, rates of primary treatment failure, which portends a poor outcome, remain significant [1]. Radiation and reirradiation are increasingly being used in the recurrent or metastatic setting [2] and, in the adult population, there is now randomised evidence to support the use of stereotactic

ablative radiation to prolong overall survival [3]. However, in the paediatric population, there has been little published data describing the use of stereotactic radiosurgery/stereotactic ablative body radiotherapy (SRS/SABR) in the oligometastatic setting.

The use of high radiation dose per fraction appears to give greater tumour kill than predicted by standard radiobiological models and may result from endothelial, vascular and immune effects [4]. As well as the promise that SRS/SABR offers in terms of efficacy, there are other considerations motivating its increased use. Hypofractionation has the advantage for the patient of the overall treatment length being significantly shortened, an important factor for

Author for correspondence: H. Mandeville, The Royal Marsden Hospital, Downs Road, Sutton, Surrey SM2 5PT, UK.

E-mail address: hmandeville@nhs.net (H. Mandeville).

children and adolescents when there is minimal realistic chance of cure. It also has the benefit of sparing staff and equipment resources and decreasing healthcare costs [5]. The use of SRS/SABR in the paediatric setting can also lead to a reduction in the total number of general anaesthetics required compared with conventional fractionation [6].

Although the ICRU has recently published a report on stereotactic treatments [7], the lack of standardised conventions for reporting dosimetric data, treatment response and toxicity has hindered the undertaking of meaningful systematic reviews. Radiobiological uncertainty with regards to extreme hypofractionation adds to the complexity of anticipating toxicity [8]. In the paediatric population, where late effects of conventional radiation are still incompletely understood [9], there is even greater uncertainty as to the boundaries of safety and efficacy in these technologies. The use of SABR in children is currently being prospectively evaluated in a Children Oncology Group Study [10] for the treatment of metastatic bone sites, but the paediatric community does not yet have the benefit of mature data from randomised trials. Here we present a case series of paediatric and teenage and young adult (TYA) patients with recurrent or metastatic disease treated with SRS or SABR.

Materials and Methods

A retrospective review of paediatric/TYA patients treated with SRS or SABR at The Royal Marsden Hospital (RMH) from September 2011 to December 2015 was carried out to allow at least 3 years of follow-up. Eligible patients were aged <25 years, with Lansky/Karnofsky performance status ≥ 60 with confirmed relapsed or metastatic tumour in fewer than three sites. Follow-up was in accordance with standard clinical care and included regular outpatient review and radiological surveillance. For response assessment of intracranial lesions RANO [11,12] criteria were used, whereas RECIST [13] criteria were used to record response for extracranial disease [13,14]. Toxicity was recorded according to CTCAE [15] v4.03. All patients were treated using the Cyberknife® system (Accuray Inc., Sunnyvale, CA, USA) [16].

The decision to treat patients with stereotactic ablative radiotherapy was made in the site-specific multidisciplinary team (MDT) meeting and confirmed at the RMH stereotactic radiotherapy MDT. MDT decisions were made on an individual basis taking all patient and tumour factors into account. Eligibility criteria were based on local and national adult experience [17] and included histological confirmation of primary malignancy and metachronous presentation of oligometastases. Patients with a synchronous presentation of disease were also eligible, if they had previously received radical treatment to their primary disease and had evidence of disease control. Patient selection was limited to those with three or fewer imaging-defined metastases, all suitable for SABR to an ablative dose.

SABR doses, fractionation and normal tissue constraints were according to local guidelines, which were derived from national and international guidelines [18–20]. All

SABR cases were treated using three to five fractions of treatment, most receiving between 24 and 30 Gy, taking the location, volume and inherent radiosensitivity of the individual tumour type into consideration.

The local SRS protocol recommended that 24 Gy was prescribed to planning tumour volumes (PTVs) smaller than 4 cm³, 20 Gy for between 4 and 8 cm³ and 18 Gy up to 14 cm³, although the treating clinician used alternative dose prescription at their clinical discretion. Where the volume and distribution of brain lesions or considerations arising from previous brain radiation therapy precluded meeting organ at risk tolerances for single-fraction SRS, consideration was given to fractionated stereotactic radiotherapy, using three to five fractions.

PTV margins of between 0 and 2 mm were used according to the local protocol. Six-dimensional skull tracking was used in patients with cranial or intracranial lesions and X-sight® spine tracking was used in patients with extracranial lesions. No fiducial markers were implanted for any of the patients. Immobilisation was achieved with a thermoplastic shell for cranial and cervical spine lesions. A vacuum bag immobilisation device, together with a knee rest where required, was used for SABR. General anaesthesia was used when necessary (see [Figures 1 and 2](#)).

Data collection was retrospective and was collected from the hospital trust electronic patient record, PACS (Picture Archiving Communication Systems) and radiotherapy planning software. Survival analysis was carried out according to the most recent entry in the electronic patient record. The statistical analysis was carried out using Microsoft Excel for Mac (Version 16.15) and IBM SPSS Statistics Version 25.

A systematic literature search was carried out using EMBASE and MEDLINE on 10 February 2019. The following search strategy was used: *ADOLESCENT/OR *CHILD/(teenage* OR adolescent* OR children OR paediatric* OR paediatric*). (1 OR 2) **STEREOTACTIC RADIOSURGERY"/(stereotactic ADJ3 (radiosurg* OR radiotherap* OR "radiation therap*")). (Cyberknife OR gammaknife OR "cyber knife" OR "gamma knife"). ((sabr OR sbprt) AND (radiation OR radiotherapy OR irradiat*)). (4 OR 5 OR 6 OR 7) (3 AND 8). Abstracts were then manually selected according to their relevance. Inclusion criteria included reports of four or more, predominantly paediatric, patients with residual or recurrent malignancies treated with SRS or extremely hypofractionated radiotherapy. Only reports from 2000 to 2019 in English were included.

This study was approved by the local institutional review board.

Results

Patient Characteristics

Fourteen patients with 18 treated lesions met the inclusion criteria. Their characteristics are summarised in [Tables 1 and 2](#). The median patient age was 15 years (range 5–20 years). The youngest patient, aged 5 years at the time

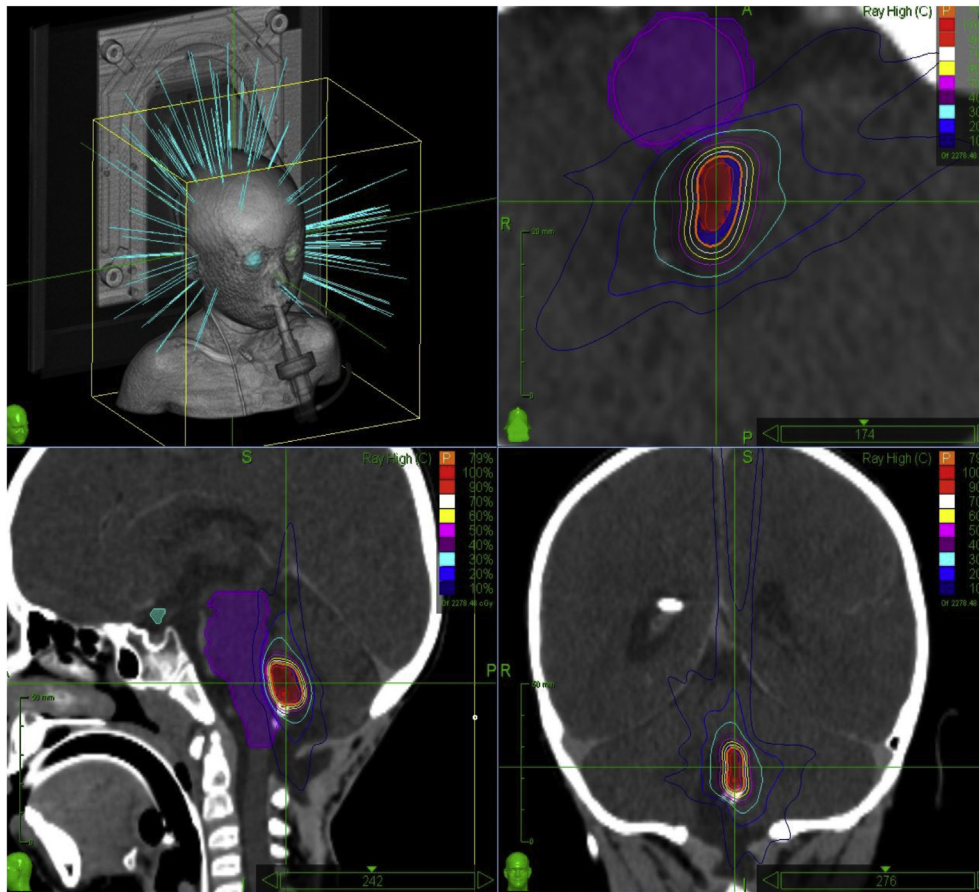


Fig 1. Cyberknife plan of patient 4: A 5-year-old with ependymoma who received 20 Gy in a single fraction to a posterior fossa local recurrence. The patient required general anaesthesia and an endotracheal tube can be seen on the images.

of treatment, was the only one who required general anaesthesia. All patients were Lansky/Karnofsky performance status ≥ 70 . Eight of the patients had Cyberknife treatment to cranial/intracranial lesions: the treated tumours were ependymoma ($n = 3$), medulloblastoma ($n = 3$), metastatic melanoma ($n = 1$) and ameloblastic fibro-odontosarcoma ($n = 1$). Six patients were treated with SABR to extracranial tumours: the tumour histologies were Ewing sarcoma ($n = 3$), neuroblastoma ($n = 2$) and paraganglioma ($n = 1$) and the sites of treatment were all vertebral or para-vertebral. Eleven patients were treated for recurrence (nine locoregional and two distant) and three for synchronous metastatic lesions. In the former, the recurrence was the only site of disease. In the latter, two patients had two metastatic sites treated (patients 13 and 9) and one patient had three metastatic sites treated (patient 7).

Six treatments, all intracranial, were delivered as a single fraction SRS (median dose 19 Gy; range 18–24 Gy). For the remaining patients, five treatments were given in three fractions (median dose 27 Gy; range 27–42 Gy) and three treatments in five fractions (median dose 30 Gy; range 30–35 Gy). The median prescription isodose was 79% (range 70–81%) and the median PTV was 2.42 cm³ (range 0.41–68.71 cm³).

All patients had already undergone multiple treatments before SRS/SABR. All had undergone previous oncological surgery and eight patients (57%) had undergone at least two previous operations. Eleven (79%) patients had received prior systemic chemotherapy.

Eleven patients (79%) had already undergone radiotherapy; nine of them with conventional fractionation schemes. One patient had received proton beam therapy (patient 4) and another had been treated with the hyper-fractionated Milan protocol craniospinal radiotherapy [21] (patient 6). Ten patients had in-field reirradiation; six of these were cranial/intracranial sites and three were extracranial. The median time between the completion of the previous treatment and the completion of reirradiation was 28.3 months (range 0.2–49.5 months).

Clinical Outcome

After a median follow-up of 3.4 years (range 0.28–6.4 years), five patients remained alive, six had died from disease progression, one died from an unclear cause (death from a stroke secondary to cranial radiotherapy could not be excluded) and two had incomplete follow-up data (patients 10 and 12, who were lost to follow-up after distant

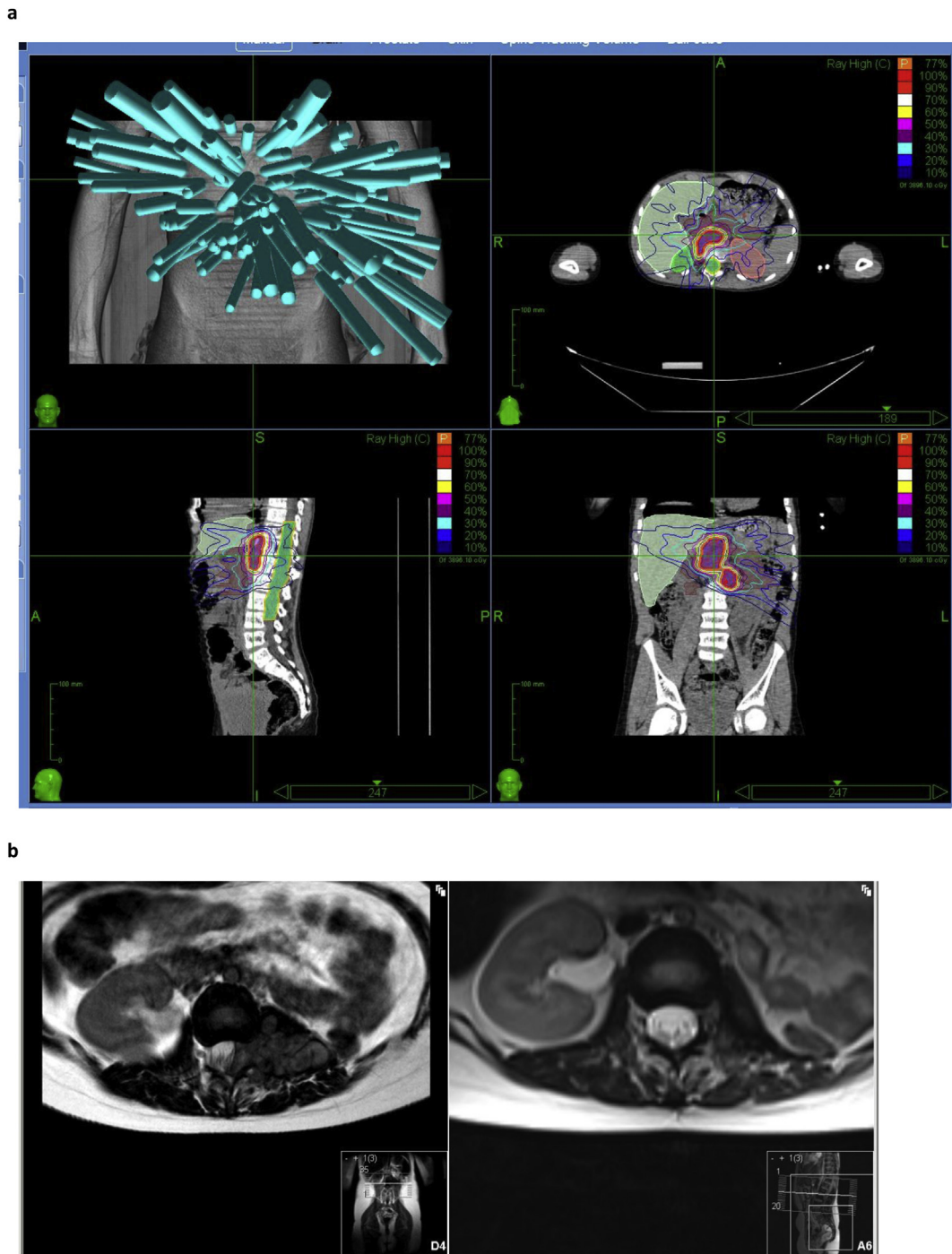


Fig 2. (a) Patient 11: 10-year-old with neuroblastoma, local recurrence. (b) Patient 11: lesion prior to (left) and 3 months after stereotactic ablative body radiotherapy (right).

progression at 21.1 and 14.1 months, respectively). In the cranial cohort, the 2-year local control rate was 75% and the grade 3 toxicity rate was 38%. In the SABR cohort, the 2 year local control rate was 50% and there was no late toxicity.

A Kaplan–Meier analysis for the whole cohort revealed a mean local progression-free survival (PFS) of 54 months (95% confidence interval 37.17–71.05 months), median not reached. The mean distant PFS was 44.1 months (95% confidence interval 28.3–60.0 months), median not reached.

The median overall survival was 58.4 months (95% confidence interval 33.8–82.9 months). A sensitivity analysis was carried out to test the assumption that the two patients lost to follow-up died on the date of their last recorded follow-up. This gave a median overall survival of 40.9 months (95% confidence interval 25.7–56.0 months).

Including only the 10 patients receiving in-field reirradiation, the estimated median overall survival was 47.25 months, the estimated mean local PFS was 59.3 months

Table 1
Patient characteristics

Study number	Gender	Age (years)	Diagnosis	Site of primary	Site of treatment	SABR/(f)SRS	Treatment context	Total dose	Dose per fraction
1	Male	14	Ependymoma	Posterior fossa	Brainstem	SRS	Local recurrence	18	18
2	Male	9	Medulloblastoma	Posterior fossa	Left frontal lobe	SRS	Regional recurrence, post-surgical bed	24	24
3	Male	20	Medulloblastoma	Posterior fossa	Posterior fossa	fSRS	Local recurrence, residual postoperative	35	7
4	Male	5	Ependymoma	Posterior fossa	Posterior fossa	SRS	Local recurrence, post-surgical bed	20	20
5	Female	15	Ependymoma	Spine	Posterior fossa	SRS	Solitary metachronous metastasis	24	24
6	Female	14	Medulloblastoma	Supratentorial	Right frontal lobe	SRS	Local recurrence, post-surgical bed	24	24
7	Male	15	Melanoma	Cheek	Right temporal lobe	SRS	Metastases	20	20
8	Female	17	Fibro-odontosarcoma	Oral cavity	Sphenoid	fSRS	Local recurrence	42	14
9	Male	18	Ewing's sarcoma	Cervical spine	C3 and C5	SABR	Local recurrence	30	10
10	Male	18	Ewing's sarcoma	Right tibia	Paravertebral	SABR	Distant recurrence	27	9
11*	Male	10	Neuroblastoma	Paravertebral	Paravertebral T11-L3	SABR	Local recurrence	30	6
12	Male	18	Ewing's sarcoma	Right fibula	T2	SABR	Distant recurrence	27	9
13	Male	15	Parangioma	Abdomen	T3 and T10	SABR	Synchronous oligometastases	27	9
14	Female	10	Neuroblastoma	Paraspinal mass	Paravertebral mass L1-L3	SABR	Local recurrence	30	6

SABR, stereotactic ablative body radiotherapy; SRS, stereotactic radiosurgery; fSRS, fractionated stereotactic radiosurgery.

* Patient 11 had a second treatment with Cyberknife 5 years later, but this treatment occurred in 2017 and was therefore not included in this analysis. He remains well with no toxicity from either of his treatments at present.

(median not reached) and the estimated median time to distant recurrence was 42.0 months.

Toxicity

Acute and late toxicity were respectively defined according to whether they occurred within or beyond the first 90 days after the completion of treatment. Two patients had documented early toxicity and four patients developed late toxicity (see Table 2). Acute toxicity included one patient with grade 1 oesophagitis (patient 10) and another patient who was diagnosed with radiologically confirmed frontal lobe radionecrosis that resulted in hemiplegia (patient 6). The latter patient's symptoms persisted beyond 90 days and the radionecrosis was treated with bevacizumab with a partial response. Patient 8 also developed late toxicity with brain, skin and bone necrosis around the treated sphenoid lesion. Elective plastic reconstructive surgery was planned but the patient developed local tumour recurrence before the procedure. Patient 1 developed transient tongue fasciculations that resulted in mild dysarthria and dysphagia at 94 days. This was treated as brainstem radionecrosis and responded well, clinically and radiologically, to a course of steroids. Unfortunately, the patient died unexpectedly 12 months after treatment, 78 days after a magnetic resonance imaging scan of the brain and spine that showed only treatment response; the cause of death was not ascertained. A fourth patient (patient 3) who suffered late toxicity developed posterior fossa radionecrosis. This resulted in a cerebellar syndrome that presented with ataxia and also possible occipital lobe epilepsy that manifested as headaches, nausea and visual disturbance, requiring management with anticonvulsant medication.

Of the four patients who suffered late toxicity, two received single fraction SRS: 24 Gy to a right frontal lobe lesion (patient 6) and 18 Gy to a brainstem lesion (patient 1). The other two patients received fractionated treatment with 35 Gy in five fractions to the posterior fossa (patient 3) and 42 Gy in three fractions to a sphenoid bone recurrence of ameloblastic fibro-odontosarcoma (patient 8). The median time of onset between treatment and late toxicity was 243 days (range 94–423 days). The median PTV in patients who developed late toxicity was 8.91 cm³ (interquartile range 2.04–18.98 cm³). The median PTV of the patients who did not develop late toxicity was 1.68 cm³ (interquartile range 0.59–28.31 cm³). A Mann–Whitney test did not demonstrate statistical significance ($P = 0.651$).

All four of these patients had received reirradiation in the field of previous fractionated radiotherapy. The median interval between the completion of previous radiotherapy and in-field irradiation was 22.5 months (range 15.1–34.5 months) compared with a median of 29.9 months (range 0.2–49.5 months) for the six patients who received in-field reirradiation and developed no late toxicity. The median cumulative BED (assuming an alpha/beta ratio = 2) for patients who developed late toxicity was 335 Gy (range 258–456 Gy). The median cumulative BED for patients who did not develop late toxicity was 184 Gy

Table 2
Toxicity summary

Study number	In-field retreat?	Radiotherapy treatment interval (months)	Cumulative BED (Gy)	Volume of PTV1 cm ³	Volume of PTV2 cm ³	Volume of PTV3 cm ³	V12 (cm ³)	Highest grade of acute toxicity	Description	Highest grade of late toxicity	Description	Onset (days)
1	Yes	15.1	293	2.42			4.17	0		2	Dysarthria	94
2	Yes	30.9	356	0.61			2.91	0		0		
3	Yes	34.5	258	15.4			74.54	0		3	Ataxia, partial occipital lobe seizures	376
4	Yes	21.9	333	0.59			1.92	0		0		
5	No		404	0.57			1.59	0		0		
6	Yes	27.5	377	0.89			5.11	3	Hemiplegia	3	Hemiplegia	110
7	Yes	0.2	295	Right temporal 7.51	Right frontal 0.44	Left frontal 1.68	21.23	0		0		
8	Yes	17.5	456	29.71			66.18	0		3	Brain necrosis and osteonecrosis	423
9	Yes	34.9	171	18.07			NA	0				
10	No		149	52.73			NA	1	Oesophagitis	0		
11	Yes	49.5	157	29.88			NA	0		0		
12	No		149	28.31			NA	0		0		
13	No		149	T3 0.97	T10 0.41		NA	0		0		
14	Yes	29.0	197	68.71			NA	0		0		

BED, biologically effective dose; PTV, planning tumour volume.

(range 149–404 Gy). A Pearson chi-squared test revealed a statistically significant dose response, with cumulative BED doses over 200 Gy associated with a higher probability of experiencing late toxicity ($P = 0.04$). A chi-squared test was carried out to test the hypothesis that a V12 over 5 cm³ was associated with late toxicity and a P value of 0.16 was obtained.

Discussion

Here we present a case series of children and young adults who received stereotactic ablative radiotherapy for metastatic or recurrent malignancies. This is a cohort that generally has a poor prognosis, and has often had extensive previous treatment, including prior radiotherapy to the treated area. However, there is now randomised evidence in adults that radical treatment of oligometastatic sites of disease confers a survival advantage, supporting the concept of the 'oligometastatic state' [3,22,23]. This case series shows that ablative doses of radiotherapy can achieve excellent local control and overall survival in children/TYA, with 64% of the cohort surviving 3 years or more.

In our cranial/intracranial cohort of eight patients, despite excellent local control (2-year local control rate was 75%), the late toxicity rate in this small series is significant and suggests that a relatively long interval (median >2 years) between original treatment and reirradiation does not in itself protect against radionecrosis. We found a late brain radionecrosis rate of 50% for patients receiving a cumulative BED >200 Gy. The high proportion of medulloblastoma in our cohort means that many of the patients had been heavily pretreated and this may have been a contributory factor to the toxicity rate.

QUANTEC [24] data based on adult studies have shown that the incidence of brain necrosis depends on the dose, the volume and the region irradiated. Toxicity is correlated with the V12 and increases significantly beyond 5–10 cm³. We found a trend towards increased late toxicity with a greater V12. The RTOG 90-05 dose escalation study [25] defined the maximum tolerated dose of SRS in a previously irradiated brain as 24 Gy for targets <20 mm diameter, 18 Gy for targets 21–30 mm and 15 Gy for targets 31–40 mm. (These equate to a volume of <1.05 cm³, 1.1–1.57 cm³ and 1.62–2.09 cm³, respectively, assuming a spherical target.) They reported a 20% rate of irreversible grade 3/4 toxicity and a 3% grade 5 (fatal) toxicity rate. Other studies in adults have reported rates of clinically symptomatic radionecrosis between 0 and 40% with cumulative doses between 163 and 268 Gy BED [26].

Despite it being known since the early 1990s [27] that hypofractionated reirradiation achieves good local control, the published literature concerning the use of SRS for intracranial recurrence in children/TYA includes generally small cohort numbers and heterogeneous treatment schedules and outcome measures so drawing robust dosimetric conclusions is difficult (see Table 3). Hodgson *et al.* [28] reported the outcomes of 90 patients with recurrent or residual

intracranial tumours <4 cm who received SRS. The median number of tumours treated was one with a target volume of 4.5 cm. The prescribed dose was 6–25 Gy normalised to the 80% isodose. It is not clear what proportion of patients had had previous radiotherapy. The median duration of follow-up was 24 months. The 3-year local control was 54% for all patients and ranged from 29% for patients with ependymoma to 57% for patients with medulloblastoma. The 3-year rate of radionecrosis requiring reoperation was 26%.

Milker-Zabel *et al.* [29] published a case series of 20 recurrent medulloblastomas in a mixed adult and paediatric population (median age = 16 years); 72.4% of the lesions were treated with fractionated stereotactic radiotherapy. The rest received single fraction SRS (median dose = 15 Gy) prescribed to the 80% isodose. No toxicity grade >2 was reported and there were no documented cases of symptomatic radionecrosis after a mean follow-up of 88.5 months. The overall local control rate was 89.7%.

Waxweiler *et al.* [30] retrospectively reviewed 24 paediatric patients who had received SRS to previously irradiated brainstem lesions with various histologies. The patients received 20–30 Gy in three to five fractions. A 45% rate (5/11 patients) of radionecrosis was seen in the patients receiving 24 Gy in three fractions and no cases of radionecrosis in the 13 patients who received five fractions of SRS. The interval between initial treatment and retreatment was shorter in the patients who developed radionecrosis (26 months versus 36.5 months).

The use of single fraction SRS in recurrent disease remains controversial [31]. Merchant *et al.* [32] described a retrospective series of six children who received a mean dose of 18 Gy (range 15–20 Gy) for recurrent ependymoma in a previously treated field. Outcomes were poor and 4/6 patients progressed locally within 18.5 months and died, another died of radiation necrosis at 40 months and the final patient required surgery and hyperbaric oxygen therapy for radionecrosis but was a long-term survivor.

In our cohort of six SABR patients, 50% achieved 2-year local control and tolerance was excellent, with only a single episode of acute grade 1 oesophagitis documented. Fifty per cent of the patients were receiving in-field reirradiation, but no late toxicity was reported. There are few published case report series reporting outcomes of paediatric patients receiving SABR in the recurrent setting (see Table 3). Lazarev *et al.* [33] have published a retrospective series of 62 patients, aged 3–18 years, with metastatic or recurrent neuroblastoma (48%), osteosarcoma (16%) and Ewing sarcoma (13%). All received three to five fractions of hypofractionated palliative radiation to a variety of anatomical sites, including the central nervous system (17%). Of 104 lesions treated in total, 25% received SABR. The rest received intensity-modulated radiotherapy (23%) or conformal three-dimensional/two-dimensional radiotherapy (46%). The median delivered dose was 24 Gy over a median of five fractions. Thirty-two per cent of treatments were in-field reirradiation. They achieved a 1-year local control and overall survival rate of 74% and 44%, respectively. The grade ≥3 toxicity rate was 6.7% and included two cases of small bowel obstruction requiring surgical intervention.

Table 3

Published reports of the use of stereotactic radiosurgery or hypofractionated radiotherapy in children or teenagers and young adults with recurrent or residual malignant disease. Total number of patients = 476

Reference	Type of publication	Number of patients	Age (years)	Diagnosis	Treated site	Dose	In-field irradiation (%)	Treated volume (median PTV cm ³ unless specified)	Length of follow-up (median months unless specified)	Outcome	Reported toxicity rate
[36]	Journal article	12	4–31	Recurrent medulloblastoma	Intracranial	12–24 Gy/1–3 fractions	100	2.3	NA	25% OS at 3 years	8% (brainstem oedema)
[37]	Abstract	14	4–66	Bone tumours	Extracranial	16–60 Gy/1–10 fractions	NA	16.5	7.4	5 local failures	7% grade 3 toxicity
[38]	Abstract	11	<16	Recurrent or residual ependymoma	Intracranial	5.4–20 Gy/3–5 fractions	100	8.7 (average GTV)	21	53% 3-year PFS in radical patients	No grade 3 toxicity
[39]	Abstract	23	4–18	Recurrent and metastatic paediatric tumours	Intracranial	16–40 Gy/1–5 fractions	100	NA	13	6 months median local control	No acute or late toxicity
[31]	Journal article	23	4–18	Recurrent tumours	Intracranial (82%), extracranial (18%)	15–40 Gy/1–5 fractions	100	1.58	41	MOS 65 months	9% (brain necrosis)
[28]	Journal article	90	1–21	Recurrent or residual brain tumours	Intracranial	6–25 Gy/1 fraction	NA	4.5	24	13 months median PFS	26% rate of radionecrosis at 3 years
[40]	Journal article	12	1–14	Relapsed ependymoma	Intracranial	24–30 Gy/3 fractions	100	NA	25	71% 2-year OS	50% radionecrosis
[41]	Journal article	21	2–17	Recurrent or residual ependymoma	Intracranial	9–22 Gy/1 fraction	100	NA	27.6	MOS 27.6 months	10% (radionecrosis)
[42]	Abstract	47	2–17	Recurrent or residual ependymoma	Intracranial	9–24 Gy/1 fraction	100	1.6	22	47% 3-year OS	4% (symptomatic)
[43]	Abstract	5	Paediatric	Recurrent ependymoma	Intracranial	NA	100	NA	10 years (mean)	NA	NA
[44]	Abstract	4	6–16	Lung metastases	Extracranial	24 Gy/1 fraction, 28 Gy/2 fractions	NA	2.1–4.7	0	NA	NA
[33]	Journal article	62*	3–18	Recurrent and metastatic paediatric tumours	Extracranial and intracranial	15–40 Gy/3–5 fractions	33	NA	8.7	28% 2-year OS	7% grade ≥3 toxicity

(continued on next page)

Table 3 (continued)

Reference	Type of publication	Number of patients	Age (years)	Diagnosis	Treated site	Dose	In-field irradiation (%)	Treated volume (median PTV cm ³ unless specified)	Length of follow-up (median months unless specified)	Outcome	Reported toxicity rate
[32]	Journal article	6	2–9	Recurrent ependymoma	Intracranial	15–20 Gy/1 fraction	100	NA	NA	1 long term survivor	67% (radionecrosis including 1 (17%) fatal)
[45]	Abstract	14	2–24	Recurrent or residual brain tumours	Intracranial	10–20 Gy/1 fraction	79	0.6	1.9 years	MOS 6.3 years	No significant late toxicity
[29]	Journal article	20	5–44	Recurrent medulloblastoma	Intracranial	24.5 Gy in 4 Gy/ fraction, 10–18 Gy/1 fraction	100	10.7 (hypofractionated), 2.8 (SRS)	88.5 (mean)	25% OS at 3 years	No toxicity reported
[46]	Journal article	14	3–46	Recurrent medulloblastoma and ependymoma	Intracranial	6–30 Gy/1–6 fractions	100	1.36	NA	39% 2-year survival	No late toxicity reported
[27]	Journal article	14	7–41	Recurrent or residual PNET/medulloblastoma	Intracranial	30–40 Gy/6–8 fractions	100	7.3	NA	MOS 29 months	7% (late radionecrosis)
[47]	Abstract	12	13–20	Brain metastases	Intracranial	6–22 Gy/1 fraction	33	1.34 (mean)	8.6	91% 6-month local control	8% fatal toxicity, 8% requiring surgical intervention
[35]	Abstract	15	4–31	Recurrent and metastatic paediatric tumours	Extracranial	20–40 Gy/3/5 fractions	60	NA	22	Local control 75%	15% grade 3 toxicity
[34]	Abstract	33	5–26	Recurrent and metastatic paediatric tumours	Extracranial	40 Gy in 6 Gy/ fraction (median)	NA	27.3	9.9	63% 1-year OS	No grade 3 toxicity
[30]	Abstract	24	Paediatric	Recurrent brainstem tumours	Intracranial	20–30 Gy/3–5 fractions	100	NA	12.1	MOS 12.8 months	45% in 3 fractions (radionecrosis), 0/13 in 5 fractions

GTV, gross tumour volume; MOS, median overall survival; OS, overall survival; PFS, progression-free survival; PNET, Primitive neuroectodermal tumours; PTV, planning tumour volume; SRS, stereotactic radiosurgery.

* 25% of lesions were treated with stereotactic radiotherapy. Most were treated with a variety of less conformal modalities. The other columns summarise data for the entire cohort as presented in the paper. See main body of text for more details.

Tinkle *et al.* [34] presented a retrospective review of 33 patients aged 5–26 years with metastatic or recurrent tumours in bone (66%) or soft tissue (33%). The median total dose was 40 Gy delivered in a median dose per fraction of 6 Gy. The 1-year PFS and overall survival was 7% and 63%, respectively. No acute or late toxicity rate of grade 3 or higher was reported after a median follow-up of 9.9 months. Taunk and Wolden [35] reported a 75% local control rate for their cohort of 15 patients (median age 17 years, range 4–31) with osseous oligometastatic or recurrent tumours treated with SABR. Sixty per cent of treated lesions had received previous radiotherapy. Grade 3 toxicity was 15% and included severe myositis and neuropathy.

Conclusion

The data presented here show that radical doses of short-course hypofractionated radiotherapy can achieve excellent local control and may contribute to the prolongation of overall survival in oligometastatic disease. SABR is well tolerated, even in cases of in-field reirradiation to large volumes. We have also shown that exceeding a cumulative dose of 200 Gy BED is associated with symptomatic brain radionecrosis.

This study contributes to a field that currently has insufficient high-quality data to guide management. The authors hope that the opportunities that SRS/SABR offer will lead to prospective clinical trials to quantify better its risks and confirm its survival benefits in the oligometastatic state, as recently demonstrated in adults.

Conflicts of Interest

The authors declare no conflicts of interest.

Appendix A. Supplementary data

Supplementary data to this article can be found online at <https://doi.org/10.1016/j.clon.2019.11.005>.

References

- [1] Wolfe I, Macfarlane A, Donkin A, Marmot M, Vine R. *Why children die: death in infants, children and young people in the UK Part A*. Royal College of Paediatrics and Child Health National Children's Bureau British Association for Child and Adolescent Public Health; 2014.
- [2] Tsang DS, Laperriere NJ. Re-irradiation for paediatric tumours. *Clin Oncol* 2019;31:191–198.
- [3] Palma DA, Olson RA, Harrow S, Gaede S, Louie AV, Haasbeek C, *et al.* Stereotactic Ablative Radiation Therapy for the Comprehensive Treatment of Oligometastatic Tumors (SABR-COMET): results of a randomized trial. *Int J Radiat Oncol Biol Phys* 2018;102:S3–S4.
- [4] Brown JM, Carlson DJ, Brenner DJ. The tumor radiobiology of SRS and SBRT: are more than the 5 Rs involved? *Int J Radiat Oncol Biol Phys* 2014;88:254–262.
- [5] Hunter D, Mauldon E, Anderson N. Cost-containment in hypofractionated radiation therapy: a literature review. *J Med Radiat Sci* 2018;65:148–157.
- [6] Verma V, Beethe AB, LeRiger M, Kulkarni RR, Zhang M, Lin C. Anesthesia complications of pediatric radiation therapy. *Pract Radiat Oncol* 2016;6:143–154.
- [7] Wilke L, Andratschke N, Blanck O, Brunner TB, Combs SE, Grosu AL, *et al.* ICRU report 91 on prescribing, recording, and reporting of stereotactic treatments with small photon beams: statement from the DEGRO/DGMP working group stereotactic radiotherapy and radiosurgery. *Strahlentherapie Und Onkologie – Organ Der Deutschen Rontgengesellschaft* 2019;195:193–198.
- [8] Bentzen SM, Constine LS, Deasy JO, Eisbruch A, Jackson A, Marks LB, *et al.* Quantitative Analyses of Normal Tissue Effects in the Clinic (QUANTEC): an introduction to the scientific issues. *Int J Radiat Oncol Biol Phys* 2010;76:S3–S9.
- [9] Constine LS, Ronckers CM, Hua CH, Olch A, Kremer LCM, Jackson A, *et al.* Pediatric Normal Tissue Effects in the Clinic (PENTEC): an international collaboration to analyse normal tissue radiation dose–volume response relationships for paediatric cancer patients. *Clin Oncol* 2019;31:199–207.
- [10] *Randomized phase 3 trial evaluating the addition of the IGF-1R monoclonal antibody ganitumab (AMG 479, NSC# 750008) to multiagent chemotherapy for patients with newly diagnosed metastatic Ewing sarcoma. NCT02306161*. National Institute of Health; 2019.
- [11] Quant EC, Wen PY. Response assessment in neuro-oncology. *Curr Oncol Rep* 2011;13:50–56.
- [12] Lin NU, Lee EQ, Aoyama H, Barani IJ, Barboriak DP, Baumert BG, *et al.* Response assessment criteria for brain metastases: proposal from the RANO group. *Lancet Oncol* 2015;16:e270–e278.
- [13] Eisenhauer EA, Therasse P, Bogaerts J, Schwartz LH, Sargent D, Ford R, *et al.* New response evaluation criteria in solid tumours: revised RECIST guideline (version 1.1). *Eur J Cancer* 2009;45:228–247.
- [14] Abramson RG, McGhee CR, Lakomkin N, Arteaga CL. Pitfalls in RECIST data extraction for clinical trials: beyond the basics. *Acad Radiol* 2015;22:779–786.
- [15] Trotti A, Colevas AD, Setser A, Basch E. Patient-reported outcomes and the evolution of adverse event reporting in oncology. *J Clin Oncol* 2007;25:5121–5127.
- [16] Adler Jr JR, Chang SD, Murphy MJ, Doty J, Geis P, Hancock SL. The Cyberknife: a frameless robotic system for radiosurgery. *Stereotact Funct Neurosurg* 1997;69:124–128.
- [17] Aitken K, Tree A, Thomas K, Nutting C, Hawkins M, Tait D, *et al.* Initial UK experience of stereotactic body radiotherapy for extracranial oligometastases: can we change the therapeutic paradigm? *Clin Oncol* 2015;27:411–419.
- [18] Timmerman RD. An overview of hypofractionation and introduction to this issue of seminars in radiation oncology. *Semin Radiat Oncol* 2008;18:215–222.
- [19] Benedict SH, Yenice KM, Followill D, Galvin JM, Hinson W, Kavanagh B, *et al.* Stereotactic body radiation therapy: the report of AAPM Task Group 101. *Med Phys* 2010;37:4078–4101.
- [20] *Stereotactic ablative body radiation therapy: a resource version 5.0*. UK SABR Consortium; 2015.
- [21] Gandola L, Massimino M, Cefalo G, Solero C, Spreafico F, Pecori E, *et al.* Hyperfractionated accelerated radiotherapy in the Milan strategy for metastatic medulloblastoma. *J Clin Oncol* 2009;27:566–571.
- [22] Gomez DR, Tang C, Zhang J, Blumenschein GR, Hernandez M, Lee JJ, *et al.* Local consolidative therapy (LCT) improves overall survival (OS) compared to maintenance therapy/observation

- in oligometastatic non-small cell lung cancer (NSCLC): final results of a multicenter, randomized, controlled phase 2 trial. *Int J Radiat Oncol Biol Phys* 2018;102:1604.
- [23] Palma DA, Louie AV, Rodrigues GB. New strategies in stereotactic radiotherapy for oligometastases. *Clin Cancer Res* 2015; 21:5198.
- [24] Lawrence YR, Li XA, el Naqa I, Hahn CA, Marks LB, Merchant TE, et al. Radiation dose–volume effects in the brain. *Int J Radiat Oncol Biol Phys* 2010;76:S20–S27.
- [25] Shaw E, Scott C, Souhami L, Dinapoli R, Kline R, Loeffler J, et al. Single dose radiosurgical treatment of recurrent previously irradiated primary brain tumors and brain metastases: final report of RTOG protocol 90-05. *Int J Radiat Oncol Biol Phys* 2000;47:291–298.
- [26] Mayer R, Sminia P. Reirradiation tolerance of the human brain. *Int J Radiat Oncol Biol Phys* 2008;70:1350–1360.
- [27] Saran F, Baumert BG, Creak AL, Warrington AP, Ashley S, Traish D, et al. Hypofractionated stereotactic radiotherapy in the management of recurrent or residual medulloblastoma/PNET. *Pediatr Blood Cancer* 2008;50:554–560.
- [28] Hodgson DC, Goumnerova LC, Loeffler JS, Dutton S, Black PM, Alexander 3rd E, et al. Radiosurgery in the management of pediatric brain tumors. *Int J Radiat Oncol Biol Phys* 2001;50: 929–935.
- [29] Milker-Zabel S, Zabel A, Thilmann C, Zuna I, Hoess A, Wannemacher M, et al. Results of three-dimensional stereotactically-guided radiotherapy in recurrent medulloblastoma. *J Neurooncol* 2002;60:227–233.
- [30] Waxweiler TV, Vinogradskiy Y, Amini A, Yeh N, Jackson MW, Hankinson T, et al. Toxicity assessment of hypofractionated stereotactic radiosurgery for brainstem reirradiation in pediatric patients with locally recurrent disease. *Int J Radiat Oncol Biol Phys* 2015;93:E506.
- [31] Gultekin M, Cengiz M, Sezen D, Zorlu F, Yildiz F, Yazici G, et al. Reirradiation of pediatric tumors using hypofractionated stereotactic radiotherapy. *Technol Cancer Res Treat* 2017;16: 195–202.
- [32] Merchant TE, Boop FA, Kun LE, Sanford RA. A retrospective study of surgery and reirradiation for recurrent ependymoma. *Int J Radiat Oncol Biol Phys* 2008;71:87–97.
- [33] Lazarev S, Kushner BH, Wolden SL. Short hypofractionated radiation therapy in palliation of pediatric malignancies: outcomes and toxicities. *Int J Radiat Oncol Biol Phys* 2018;102: 1457–1464.
- [34] Tinkle CL, Singh C, Hyun JW, Li Y, Pappo A, Terezakis SA, et al. Stereotactic body radiotherapy for metastatic and recurrent lesions in pediatric patients. *Int J Radiat Oncol Biol Phys* 2017; 99:E572.
- [35] Taunk NK, Wolden SL. Acute toxicity and local control in pediatric cancers treated with stereotactic body radiation therapy (SBRT). *Int J Radiat Oncol Biol Phys* 2015;93:E508–E509.
- [36] Abe M, Tokumaru S, Tabuchi K, Kida Y, Takagi M, Imamura J. Stereotactic radiation therapy with chemotherapy in the management of recurrent medulloblastomas. *Pediatr Neurosurg* 2006;42:81–88.
- [37] Brown LC, Lester RA, Haddock MG, Sarkaria JN, Olivier KR, Arndt CAS, et al. Stereotactic body radiation therapy (SBRT) for pediatric bone tumors. *Int J Radiat Oncol Biol Phys* 2013;87:S71.
- [38] Elbeltagi M, Mousa A, Khafaga Y. Cyberknife in paediatric posterior fossa ependymoma. *Pediatr Blood Cancer* 2016;63: S5–S321.
- [39] Gultekin M, Cengiz M, Sezen D, Yazici G, Hurmuz P, Ozyigit G, et al. Reirradiation of pediatric tumors with robotic stereotactic radiosurgery. *Int J Radiat Oncol Biol Phys* 2014;90:S722.
- [40] Hoffman LM, Plimpton SR, Foreman NK, Stence NV, Hankinson TC, Handler MH, et al. Fractionated stereotactic radiosurgery for recurrent ependymoma in children. *J Neurooncol* 2014;116:107–111.
- [41] Kano H, Yang HC, Kondziolka D, Niranjan A, Arai Y, Flickinger JC, et al. Stereotactic radiosurgery for pediatric recurrent intracranial ependymomas. *J Neurosurg Pediatr* 2010;6:417–423.
- [42] Kano H, Su YH, Wu HM, Simonova G, Liscak R, Cohen-Inbar O, et al. Stereotactic radiosurgery for intracranial ependymomas: an international multicenter study. *Neurosurgery* 2019;84: 227–234.
- [43] Kawamura A, Koyama J, Akutsu N, Nagashima T. EPN-08: The effect of gamma knife radiosurgery as the salvage therapy for the recurrent pediatric ependymoma. *Neuro-Oncology* 2016; 18:iii31.
- [44] Kron T, Donahoo G, Ungureanu E, Dwyer M, Hall L, Siva S, et al. Stereotactic ablative body radiotherapy (SABR) for paediatric patients. *J Med Imaging Radiat Oncol* 2018;62: 143–174.
- [45] Merrell K, Planchard R, Link M, Pollock B, Parney N, Laack N. Gamma knife radiosurgery as salvage therapy for recurrent or residual pediatric and young adult brain tumors. *Pediatr Blood Cancer* 2015;62:S143–S418.
- [46] Napieralska A, Braclik I, Radwan M, Mandera M, Blamek S. Radiosurgery or hypofractionated stereotactic radiotherapy after craniospinal irradiation in children and adults with medulloblastoma and ependymoma. *Childs Nerv Syst* 2019; 35:267–275.
- [47] Sheu T, Zavala AM, Bishop AJ, McAleer MF, Briere TM. RONC-03. Stereotactic radiosurgery provides effective local control for radioresistant brain metastases in pediatric patients. *Neuro-Oncology* 2018;20:i175–i.