



**Manchester
Metropolitan
University**

Fadhil, Enas, Dosh, Rasha H, Wally, Zena J and Haider, Julfikar ORCID logoORCID: <https://orcid.org/0000-0001-7010-8285> (2023) Histological evaluation of the effects of bone morphogenetic protein 9 and angiopoietin 1 on bone healing. *Journal of Taibah University Medical Sciences*, 18 (5). pp. 954-963. ISSN 1658-3612

Downloaded from: <https://e-space.mmu.ac.uk/631431/>

Version: Published Version

Publisher: Elsevier

DOI: <https://doi.org/10.1016/j.jtumed.2023.02.005>

Usage rights: Creative Commons: Attribution-Noncommercial-No Derivative Works 4.0

Please cite the published version


<https://e-space.mmu.ac.uk>



Taibah University

Journal of Taibah University Medical Sciences

www.sciencedirect.com



Original Article

Histological evaluation of the effects of bone morphogenetic protein 9 and angiopoietin 1 on bone healing

Enas Fadhil, PhD^a, Rasha H. Dosh, PhD^{b,*}, Zena J. Wally, PhD^c and Julfikar Haider, PhD^d

^a Department of Oral Diagnosis, College of Dentistry, University of Baghdad, Baghdad, Iraq

^b Department of Human Anatomy, Faculty of Medicine, University of Kufa, Najaf, Iraq

^c Department of Prosthodontic, Faculty of Dentistry, University of Kufa, Najaf, Iraq

^d Department of Engineering, Manchester Metropolitan University, Manchester, UK

Received 19 November 2022; revised 9 January 2023; accepted 8 February 2023; Available online 16 February 2023



المخلص

أهداف البحث: يظل التئام العظام مشكلة عظام إكلينيكية حرجة. يعتمد العظم الذي هو عبارة عن أنسجة وعانية بشكل كبير على ارتباط زمني ومكاني ضيق بين الأوعية الدموية وخلايا العظام. وبالتالي، فإن تكوين الأوعية الدموية أمر بالغ الأهمية لنمو الهيكل العظمي وشفاء كسر العظام. كان الغرض من هذه الدراسة هو تقييم فعالية التطبيق الموضعي للعوامل المكونة للعظم مثل البروتينات المخلقة للعظام 9 وللأوعية مثل أنجيوبوتين 1، والجمع بينهما كمحفز عظمي في عملية التئام العظام.

طرق البحث: تم استخدام ثمانية وأربعين من ذكور الجرذان البيضاء، التي يتراوح وزنها بين 300 و 400 جرام وتتراوح أعمارهم من 6 إلى 8 أشهر في هذه الدراسة. خضعت الحيوانات لعملية جراحية في الجانب الإنسي من عظم القصبية. في المجموعة الضابطة، تم تطبيق إسفنجة مرقة قابلة للامتصاص محليا على عيب العظام، بينما تم فصل المجموعات التجريبية إلى ثلاث مجموعات. في المجموعة الأولى، تم تطبيق 1 مجم من البروتينات المخلقة للعظام 9 محليا، وعولجت المجموعة الثانية بـ 1 مجم من أنجيوبوتين 1، وعولجت المجموعة الثالثة باستخدام مزيج محلي (0.5 مجم من البروتينات المخلقة للعظام 9 و 0.5 مجم من أنجيوبوتين 1). تم إصلاح جميع المجموعات التجريبية بإسفنجة مرقة قابلة للامتصاص. تم التضحية بالفئران في اليوم 14 واليوم 28 بعد الجراحة.

النتائج: التطبيق الموضعي لـ البروتينات المخلقة للعظام 9، أنجيوبوتين 1 وحده، وتوليفها مع عيب في قصبية الساق يؤدي إلى تكوين الأنسجة العظمية وزيادة عدد الخلايا العظمية بشكل ملحوظ. لوحظ انخفاض تدريجي في عدد العظام

التربيقية، وزيادة في منطقة التربيق، وعدم وجود فرق كبير في منطقة نخاع العظم.

الاستنتاجات: إن الجمع بين البروتينات المخلقة للعظام 9 وأنجيوبوتين 1 له إمكانات علاجية في تعزيز عملية التئام عيوب العظام. يتم تنظيم تكون العظام وتكوين الأوعية بواسطة البروتينات المخلقة للعظام 9 وأنجيوبوتين 1. تعمل هذه العوامل معا لتسريع عملية تجديد العظام بشكل أكثر كفاءة من أي عاملين على حدة.

الكلمات المفتاحية: تولد الأوعية؛ أنجيوبوتين 1؛ البروتينات المخلقة للعظام 9؛ تكون العظم

Abstract

Objectives: Bone healing remains a critical clinical orthopedic problem. Bone, which is a greatly vascularized tissue, depends on the tight temporal and spatial link between blood vessels and bone cells. Thus, angiogenesis is crucial for skeletal growth and bone fracture healing. The purpose of this study was to evaluate the efficacy of the local application of osteogenic and angiogenic factors such as bone morphogenetic protein 9 (BMP9) and angiopoietin 1 (Ang1), respectively, and their combination as an osteoinducer in the process of bone healing.

Methods: Forty-eight male albino rats, weighing 300–400 g and aged 6–8 months, were utilized in this study. The animals underwent surgery on the medial side of the tibia bone. In the control group, an absorbable hemostatic sponge was locally applied to the bone defect, while experimental groups were separated into three groups. In Group I, 1 mg BMP9 was locally applied, Group II was treated with 1 mg Ang1, and Group III was treated with

* Corresponding address: Department of Human Anatomy, Faculty of Medicine, University of Kufa, Kufa, Iraq

E-mail: rasha.dosh@uokufa.edu.iq (R.H. Dosh)

Peer review under responsibility of Taibah University.



Production and hosting by Elsevier

local application of a combination (0.5 mg BMP9 and 0.5 mg Ang1). All experimental groups were fixed with an absorbable hemostatic sponge. The rats were sacrificed on days 14 and 28 after surgery.

Results: Local application of BMP9 alone, Ang1 alone, and their combination to a tibia defect caused osteoid tissue formation and significantly increased the number of bone cells. A gradual decrease in the number of trabecular bone, an increase in trabecular area, and no significant difference in the bone marrow area were noted.

Conclusion: The combination of BMP9 and Ang1 has therapeutic potential in promoting the healing process of bone defects. Osteogenesis and angiogenesis are regulated by BMP9 and Ang1. These factors act together to accelerate bone regeneration more efficiently than either factor alone.

Keywords: Angiogenesis; Angiopoietin 1; Bone morphogenetic protein 9; Osteogenesis

© 2023 The Authors.

Production and hosting by Elsevier Ltd on behalf of Taibah University. This is an open access article under the CC BY-NC-ND license (<http://creativecommons.org/licenses/by-nc-nd/4.0/>).

Introduction

Bones are solid organs that constitute a part of the endoskeleton of vertebrates. They supply protection and support to various organs of the body, in addition to the formation of red and white blood cells and the deposit of minerals.¹ Bone is composed of osteoblasts and osteocytes, which serve as support cells; osteoclasts, which are responsible for remodeling the bone; and a non-mineralized matrix of collagen and non-collagenous proteins named osteoid. The matrix also has inorganic mineral salts deposited within. Production of the bone matrix and subsequent mineralization of that matrix are carried out by the osteoblasts, which develop from mesenchymal stem cells of the bone marrow stroma.² The periosteal rupture causes a hematoma at the site of bone damage.³ Local vascular thrombosis causes bone necrosis around the fracture borders. Increased permeability of the capillary causes a local inflammatory callus to develop on the periphery of the injury (intramembranous ossification initiated by preosteoblasts).⁴ In the middle of the fracture site, an intramedullary callus occurs. Callus development and mineralization are enhanced by chemical and mechanical factors.⁵ The medullary cavity is restored as woven bone, which is ultimately converted to lamellar bone.⁶

Osteogenesis and angiogenesis work together to promote bone formation and regeneration. Bone morphogenetic proteins (BMPs) may contribute significantly to the

development of bone and cartilage, as well as the healing of fractures and the repair of other musculoskeletal tissues.⁷ BMP9 is a protein encoded by the growth differentiation factor 2 (GDF2) gene in humans.⁸ *In vivo*, GDF2 is one of the most effective BMPs for orthotropic bone growth.⁹ BMP9 is thought to be the strongest osteoinducer of the numerous recombinant BMPs, and it may help osteogenic differentiation of bone marrow-derived mesenchymal stem cells *in vitro* and *in vivo*.^{5,10} The ability of BMP9 to induce bone formation was established for the repair of critical-sized cranial lesions and compatibility with bone-inducing bioimplants.¹¹ Furthermore, BMP9 has a wide range of biological roles including neurogenesis, tumorigenesis, angiogenesis, metabolism, and osteogenic activity.¹²

Angiopoietin 1 (Ang1) protein is an oligomer that belongs to the Ang family of growth factors. The Ang family (Ang1–4) is essential for controlling both pathological and physiological angiogenesis.¹³ Angs play a key role in the formation of blood vessels.¹⁴ Angs all bind to the same tyrosine kinase receptor found in endothelial cells, and are important for managing bilateral interactions between the endothelium and the matrix and surrounding mesenchyme.¹⁵ Angs also help in the maturity and stability of blood vessels, and may play a role in early development of the heart.¹⁶ Ang1 has many effects on adult vascular systems including promoting vessel survival, preventing vascular leakage, and suppressing the expression of inflammatory genes. Therefore, it is no surprise that this ligand is being evaluated in preclinical trials and has promise for therapeutic usage in a variety of diseases such as stroke, sepsis, diabetic retinopathy, and transplant arteriosclerosis.¹⁷ Ang1 induces vascular remodeling and angiogenesis in addition to promoting vessel stability and has been linked to pulmonary hypertension. These therapeutic uses may need measures to reduce the risk of possible negative consequences while increasing vessel-protective outcomes.¹⁸

An absorbable hemostatic sponge is prepared from special neutral purified gelatin foam with a homogenous tiny porosity that provides proper hemostasis.¹⁹ When blood comes into contact with the matrix of the sponge, the gelatin sponge stimulates the thrombocytes. This induces the thrombocytes to release a substance that stimulates their aggregation while also altering the characteristic of their surface, enabling them to behave like a catalyst for the synthesis of fibrin.²⁰ The absorbable gelatin sponge is 100% biodegradable. In 2–4 min, it becomes hemostatic. It has a neutral pH and when it comes into contact with the mucosa, and liquefies in 2–5 days. It absorbs 35 times its weight in fluids and blood, is compatible with medications, and has a 4-year lifespan.

Many studies have demonstrated that the interaction of angiogenic and osteogenic factors can promote bone regeneration and repair. Therefore, the ability to provide a combination of growth factors locally could improve the repair process of critical-sized bone lesions, simulating the circumstances of *in vivo* bone healing. Thus, the aim of this study was to assess the effects of these treatments on the tissue structure of the tibia and to investigate whether these

treatments play a vital role as an osteoinducer in the process of bone healing in albino rats.

Materials and Methods

Experimental design and surgical procedure

All experimental procedures were applied in agreement with the ethical principles of animal experimentation with ethical approval granted by the University of Baghdad (Reference No. 583; Baghdad, Iraq). Forty-eight male Albino rats, weighing 300–400 g and aged 6–8 months, originating from the University of Baghdad, were used in this study. During the experimental period, the rats were housed in a plastic cage under standard laboratory conditions of 13/11 h light/dark cycles. The rats were fed with commercial food bits and distilled water. The rats were randomly divided into eight groups, with six rats per group.

The rats had a surgical procedure on the medial side of the tibia. The procedure was carried out in sterile conditions using a gentle method. The dose of general anesthetic administered to each rat was calculated depending on its weight. To induce general anesthesia, intramuscular injections of 2% xylazine (0.4 mg/kg body weight) and 50 mg ketamine hydrochloride (40 mg/kg body weight) were used. Furthermore, an antibiotic of 20% oxytetracycline (0.7 mL/kg) intramuscular injection was provided. The tibiae were shaved, and the skin was washed with ethanol and iodine solution. The skin and fascia flap were reflected after creating an incision. A hole of 1.8 mm was drilled with a small round bur at a rotary speed of 1500 rpm using instrument drilling and constant cooling with watered saline. Following hole preparation, saline solution was used to clean the operation site to eliminate debris from the drilling site, and the region was air-dried. In the control group, an absorbable hemostatic sponge (Gelfoam sponge; Abcam, Cambridge, UK) was locally applied to the bone defect, whereas the experimental groups were divided into three groups (six rats for each period in each group). In the first group, 1 mg BMP9 (Abcam) was applied locally, the second group was treated with local application of 1 mg Ang1 (Abcam), and the third group was treated with a combination of 0.5 mg BMP9 and 0.5 mg Ang1. The muscles were sutured using absorbable catgut, and the skin was sutured. The absorbable hemostatic sponge (Gelfoam) was used to repair each experimental group. On days 14 and 28 after surgery, the rats were sacrificed to assess the effects of BMP9, Ang1, and their combination on the histological changes and number of osteoblasts, osteocytes, osteoclasts, trabecular number (TN), trabecular area (TA), and bone marrow area (BMA) of the tibiae bone.

Histological examination

Tissue specimens were fixed immediately for 3 days in 10% freshly prepared formalin, and then were decalcified in a formic acid-sodium citrate solution made from two separate solutions (125 ccs of 90% formic acid and 125 ccs distilled water; 50 mg sodium citrate and 250 ccs distilled water). The decalcification solution was replaced every 3–4 days, and the specimens were examined regularly with a tiny

needle. Decalcification occurred when the needle was entered the specimen unchallenged. To eliminate the remaining acid, the specimens were rinsed in running water for 30 min.²¹

The specimens underwent a routine tissue processing procedure. Histological examination of the prepared specimens was carried out with a light microscope at 40× magnification. Microscopically, images were analyzed with Image J software (NIH, Bethesda, MD, USA) to determine the trabecular bone area and BMA, whereas the number of osteoblasts, osteocytes, osteoclasts, and the TN were histologically calculated in four fields of view under a light microscope at 40× magnification. An experienced histologist conducted the histological assessment, who was blind to the grouping to avoid any bias.

Statistical analyses

Statistical analyses were carried out to evaluate the effects of using BMP9 and Ang1 protein separately and in combination on bone healing in rats. The data are presented as the mean and standard deviation. In the statistical analyses, the experimental values were compared to the control. Data were analyzed by GraphPad Prism (version 9; GraphPad software, LLC, Boston, MA, USA) using two-way analysis of variance with Tukey's multiple comparison post-hoc test. $P < 0.05$ was considered statistically significant.

Results

Histological examination of the tibia-operating site

Histological examination of the tibiae-operating site on days 14 and 28 of treatment with BMP9 and Ang1 alone, and the combination (BMP9 + Ang1) in addition to the control group is presented in [Figure 1](#).

On day 14, histological examination of the tibiae-operating site of the control group showed new immature trabeculated bone occupied by a large number of irregularly arranged osteoblasts and osteocytes at the peripheries of the trabeculae as shown in [Figure 1A](#). Rats treated with BMP9, Ang1 alone, and the combination (BMP9 + Ang1) showed newly formed bone trabeculae surrounding areas of the bone marrow, including several osteoblasts and osteocytes at the peripheries. Moreover, osteoclast and reversal lines were observed between old and new bone ([Figure 1B–D](#)).

On day 28, histological investigation of the tibiae-operating site of the control group showed that mature bone, including osteoblasts and osteocytes, almost filled the operating site ([Figure 1E](#)). Rats treated with BMP9 showed mature bone filling the defected area, which was characterized by the existence of osteon (haversian system) with consistent arrangement of osteocytes around the canal of the haversian system. Osteoblasts also lined the border of the haversian canals, as shown in [Figure 1F](#). Rats treated with Ang1 showed arrangement of osteocytes in a consistent pattern around the haversian canal within dense bone in the defected site. As shown in [Figure 1G](#), osteoblasts were seen at the borders of the bone. Again, rats treated with the combination of BMP9 + Ang1 showed mature bone filling the defected area, which was characterized by the existence of osteon with regularly

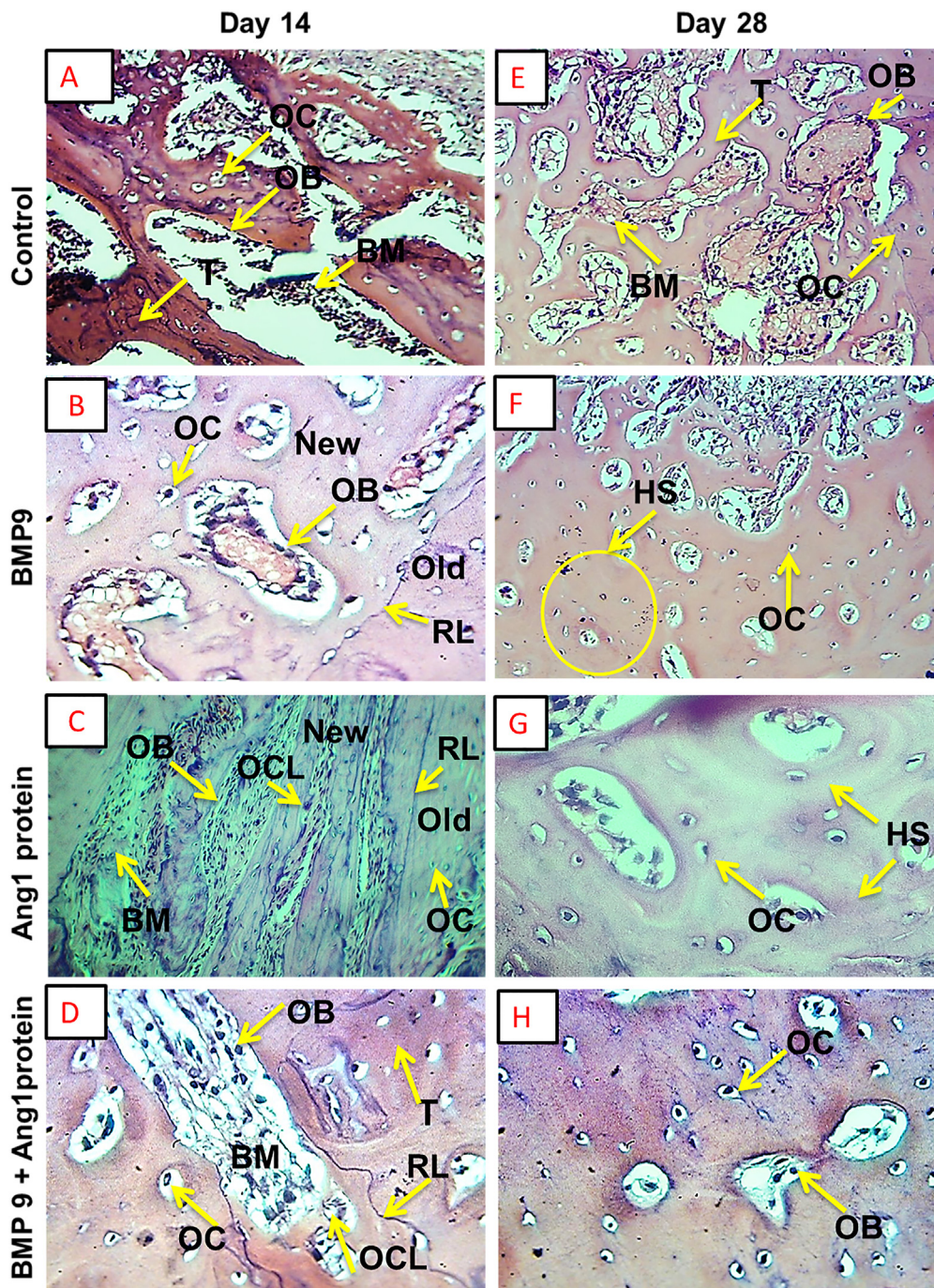


Figure 1: Histological images of the tibia bone-operating site under a light microscope (hematoxylin and eosin, 40 \times) on days 14 and 28. (A, E) control group (B, F) group treated with bone morphogenetic protein 9 (BMP9), (C, G) group treated with angiopoietin 1 protein (Ang1), and (D, H) group treated with the combination of BMP9 + Ang1.

distributed osteocytes around the haversian canal. Osteoblasts also lined the border of the haversian canals (Figure 1H).

Histomorphometric analyses of the tibia-operating site

Number of osteoblasts

On day 14, descriptive analyses of the number of osteoblasts showed a significant increase in the number of

osteoblasts in all experimental groups compared with the control group. The highest number of osteoblasts (17.33 ± 1.03) was counted in the combined treatment (BMP9 + Ang1) group, while the lowest number (17.10 ± 1.12) was found in rats treated with BMP9 alone. However, on day 28, non-significant differences in the number of osteoblasts were found between the groups treated with BMP9 and Ang1 and the control group, while a significant decrease was noted in the number of osteoblasts in

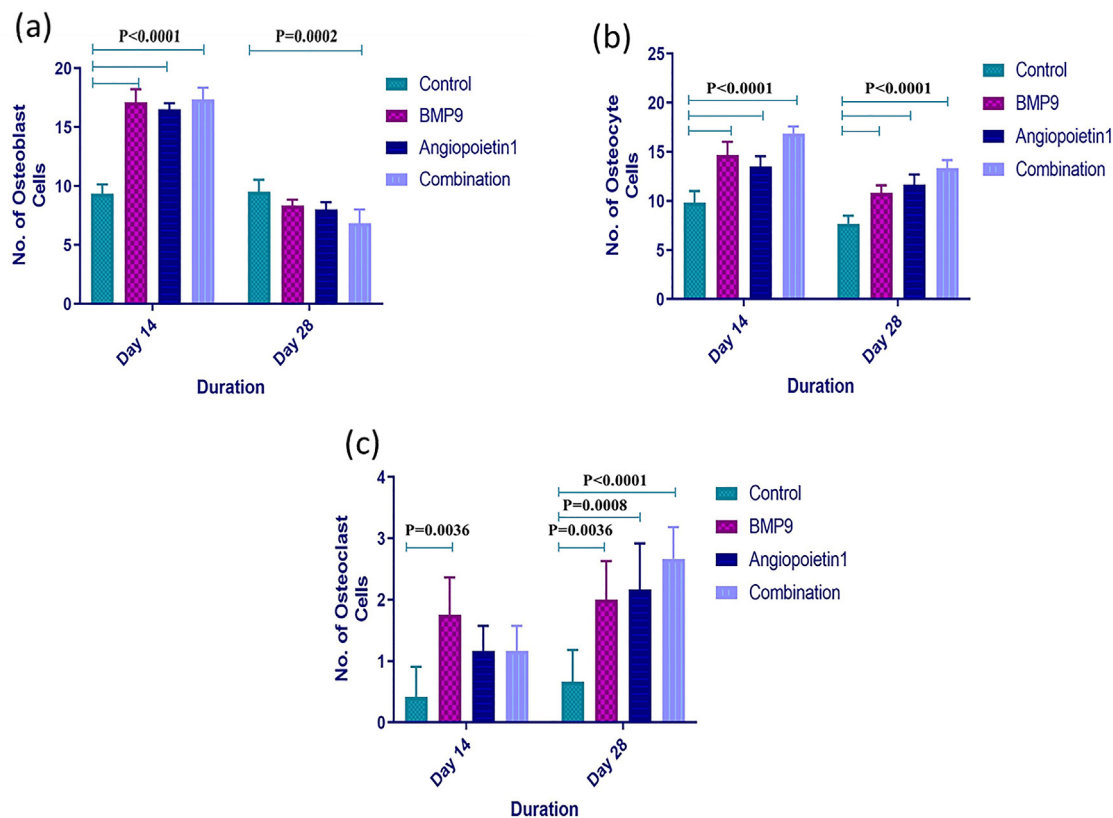


Figure 2: Histomorphometric analyses of the number of (A) osteoblasts, (B) osteocytes, and (C) osteoclasts in the tibiae bone of albino rats on days 14 and 28 of treatment with bone morphogenetic protein 9 (BMP9), angiopoietin 1 (Ang1), and the combination of BMP9 + Ang1, and a control group treated with a hemostatic sponge. $P < 0.05$ indicated a significant difference.

rats treated with the combination (BMP9 + Ang1) compared with the control group (Figure 2A, Table 1).

Number of osteocytes

On days 14 and 28, statistically significant differences were seen in the number of osteocytes between all of the treated groups and the control group. This number was significantly increased from 9.83 ± 1.16 and 7.66 ± 0.81 for the control group to the highest values of 16.83 ± 0.75 and 13.33 ± 0.81 for the combination group on days 14 and 28, respectively. Furthermore, on day 14, there were significant differences between the combination group and groups treated with BMP9 and Ang1 protein alone, whereas on day 28, a significant difference was noted between rats treated with BMP9 alone and rats treated with a combination of BMP9 + Ang1 (Figure 2B, Table 1).

Number of osteoclasts

On day 14, a statistically significant increase was found in the number of osteoclasts in the BMP9-treated group (1.75 ± 0.61) compared with the control group (0.41 ± 0.49). However, a non-significant difference was seen between the groups treated with Ang1 (1.16 ± 0.40) and the combination group (1.16 ± 0.40) and the control group. On day 28, however, osteoclast count significantly increased from 0.66 ± 0.51 in the control group to 2.0 ± 0.63 , 2.16 ± 0.75 , and 2.66 ± 0.51 in the BMP9, Ang1, and combination groups, respectively (Figure 2C, Table 1).

Trabecular number (TN)

Histological investigation of the tibiae bone-operating site in the treated rats showed a general decrease in TN compared with the control group as shown in Figure 3A and Table 2. On day 14, maximum TN (16.00 ± 0.89) was found in the control group, whereas the rats treated with a combination of BMP9 and Ang1 had a minimum TN (10.00 ± 0.89). Moreover, there were significant differences between the combination group (10.00 ± 0.89) and the groups treated with BMP9 (14.00 ± 0.89) and Ang1 (13.00 ± 0.89), as shown in Table 2. On day 28, a statistically significant decrease was found in TN between the treated groups and the control group. This number significantly declined from 16.00 ± 0.89 for the control group to 14.00 ± 0.89 for BMP9, 13.00 ± 0.89 for Ang1, and 9.33 ± 0.51 for the combined group. Furthermore, a significant difference was noted between the BMP9 (14.00 ± 0.89) and Ang1 (13.00 ± 0.89) groups and the combination group (9.33 ± 0.51) as shown in Figure 3A and Table 2.

Trabecular area (TA)

The influence of different treatments on TA in the tibiae-operating site of the rats is shown in Figure 3B and Table 2. On day 14, the TA significantly increased only in rats treated with BMP9 (4.16 ± 0.40) and the combination (3.50 ± 0.54) compared to the control group (1.75 ± 0.05). Furthermore, significant differences between BMP9- and Ang1-treated groups as well as between Ang1- and combination-treated

Table 1: Mean values of the number of osteoblasts, osteocytes, and osteoclasts in the tibiae bone of albino rats on days 14 and 28 of the experimental groups treated with bone morphogenetic protein 9 (BMP9), angiopoietin 1 (Ang1), and the combination of BMP9 + Ang1, and a control group treated with a hemostatic sponge.

Bone cells	Duration	Groups	Descriptive statistics			
			Mean	S.D	Min	Max
Osteoblasts	14 days	Control	9.33 ^a	0.81	9.00	11.00
		BMP9	17.10 ^{b,c}	1.12	16.00	19.00
		Ang1	16.50 ^b	0.54	16.00	17.00
		Combination	17.33 ^{b,c}	1.03	16.00	19.00
Osteoblasts	28 days	Control	9.50 ^a	1.04	8.00	11.00
		BMP9	8.33 ^{a,c}	0.51	8.00	9.00
		Ang1	8.00 ^a	0.63	7.00	9.00
		Combination	6.83 ^{b,c}	1.16	6.00	9.00
Osteocytes	14 days	Control	9.83 ^a	1.16	8.00	11.00
		BMP9	14.66 ^b	1.36	13.00	15.00
		Ang1	13.50 ^b	1.04	12.00	15.00
		Combination	16.83 ^b	0.75	16.00	18.00
Osteocytes	28 days	Control	7.66 ^a	0.81	7.00	9.00
		BMP9	10.83 ^b	0.75	10.00	12.00
		Ang1	11.66 ^b	1.03	10.00	13.00
		Combination	13.33 ^b	0.81	12.00	14.00
Osteoclasts	14 days	Control	0.41 ^a	0.49	0.5	1.00
		BMP9	1.75 ^b	0.61	1.00	2.5
		Ang1	1.16 ^a	0.40	1.00	2.00
		Combination	1.16 ^a	0.40	1.00	2.00
Osteoclasts	28 days	Control	0.66 ^a	0.51	0.00	1.00
		BMP9	2.00 ^b	0.63	1.00	3.00
		Ang1	2.16 ^b	0.75	1.00	3.00
		Combination	2.66 ^b	0.51	2.00	3.00

^{a-c} Different letters show statistically significant differences ($P < 0.05$).

groups were observed. On day 28, Figure 3B demonstrates statistically significant differences between the control group and the treated groups. This area significantly increased gradually from 1.75 ± 0.05 for the control group, to 3.00 ± 0.63 for BMP9 and 2.66 ± 0.51 for Ang1, to reach the highest value of 3.66 ± 0.51 for the combination group. In addition, a statistically significant difference between Ang1 and combination-treated groups was found (Table 2).

Bone marrow area (BMA)

The effects of three types of treatment on the BMA on days 14 and 28 are shown in Figure 3C and Table 2, where the treated groups did not significantly differ from the control group.

Discussion

A balance between bone formation by osteoblasts, which are from mesenchymal stem cells, and bone resorption by osteoclasts, which are from hematopoietic stem cells, controls bone volume. In general, mesenchymal cell recruitment, proliferation, differentiation, and secretion of the extracellular matrix (ECM) and biomineralization are the stages involved in hard tissue formation.^{22,23} During all phases of

bone fracture healing including formation of cartilaginous callus, callus remodeling, and bony bridging of the fracture space, the ECM offers cell migration, structural support, cell proliferation, and differentiation signals.²⁴ Bones have numerous blood vessels, and bleeding occurs once a bone is fractured. Around the bone fracture, blood clots form, which is known as a hematoma, and it includes a protein meshwork that acts as a plug which temporarily closes the hole left by the fracture.²⁵ Then the immune system mobilizes to control inflammation, a crucial step in the healing process.²⁶ In response to the immune system's signal, stem cells from the blood, bone marrow, and surrounding tissues migrate toward the fracture. These stem cells initiate the formation pathways of cartilage and bone, which together enable bone healing.²⁷ While most fractures mend quickly and without leaving scars, fracture healing may occasionally be slowed down or results in a non-union consequence.²⁸ Delayed or unsuccessful fracture treatment results in higher medical expenses, more operations, and a longer recovery period, all of which are linked to higher death rates in older populations.²⁹ Thus, the current study determined the effects of BMP9, Ang1, and the combination (BMP9+Ang1) on bone healing through histological and histomorphometric analyses.

In this study, general histological findings showed that all histological sections showed good healing in both the control and experimental groups, but with differences in the rate of bone deposition and remodeling. On day 14, rats treated with BMP9, Ang1 alone, or the combination had newly formed bone trabeculae in which lacunae containing osteocytes were scattered and osteoblasts rimmed their trabecular borders. These results are in agreement with previous studies, which demonstrated that the irregular region was occupied by delicate and interwoven bone trabeculae 14 days after surgery, where the newly formed trabeculae contained substantial osteocytes and were encompassed by cuboid osteoblasts in all cases.^{30,31} On day 28, the results obtained from the BMP9, Ang1, and combination groups showed that mature bone filled the defected region and was distinguished by the presence of osteon and consistent arrangement of osteocytes alongside the haversian canal. Along the edge of the haversian canals, osteoblasts were also detected. In normal bone healing, vascular tissue growth occurs before bone formation. Angiogenesis is first stimulated by Ang1, and then bone formation is supported by BMP9. The results in this study are in agreement with the findings by Beederman et al.⁹ (2013), who showed that BMP9 was the most osteoinductive of the various forms of recombinant BMPs, and may improve *in vitro* and *in vivo* osteogenic differentiation of bone mesenchymal stem cells.⁹ BMPs are considered osteoinductive due to their ability to transform connective tissue into bone tissue. They induce stem cells to differentiate into various cell types (adipose tissue, cartilage, and bone). They are extremely prevalent in the bone tissue and help to create bone and cartilage during embryogenesis. They are thought to prevent osteoclast formation in addition to stimulating osteogenesis, and greatly stimulate osteoblastic differentiation.^{2,10} BMP9 induces Smad signaling pathways and stimulates Runt-related transcription factor 2 expression.³² BMP9 enhances the production of mineralized nodules, increases the activity of alkaline phosphatase and osteogenic-associated gene expression to

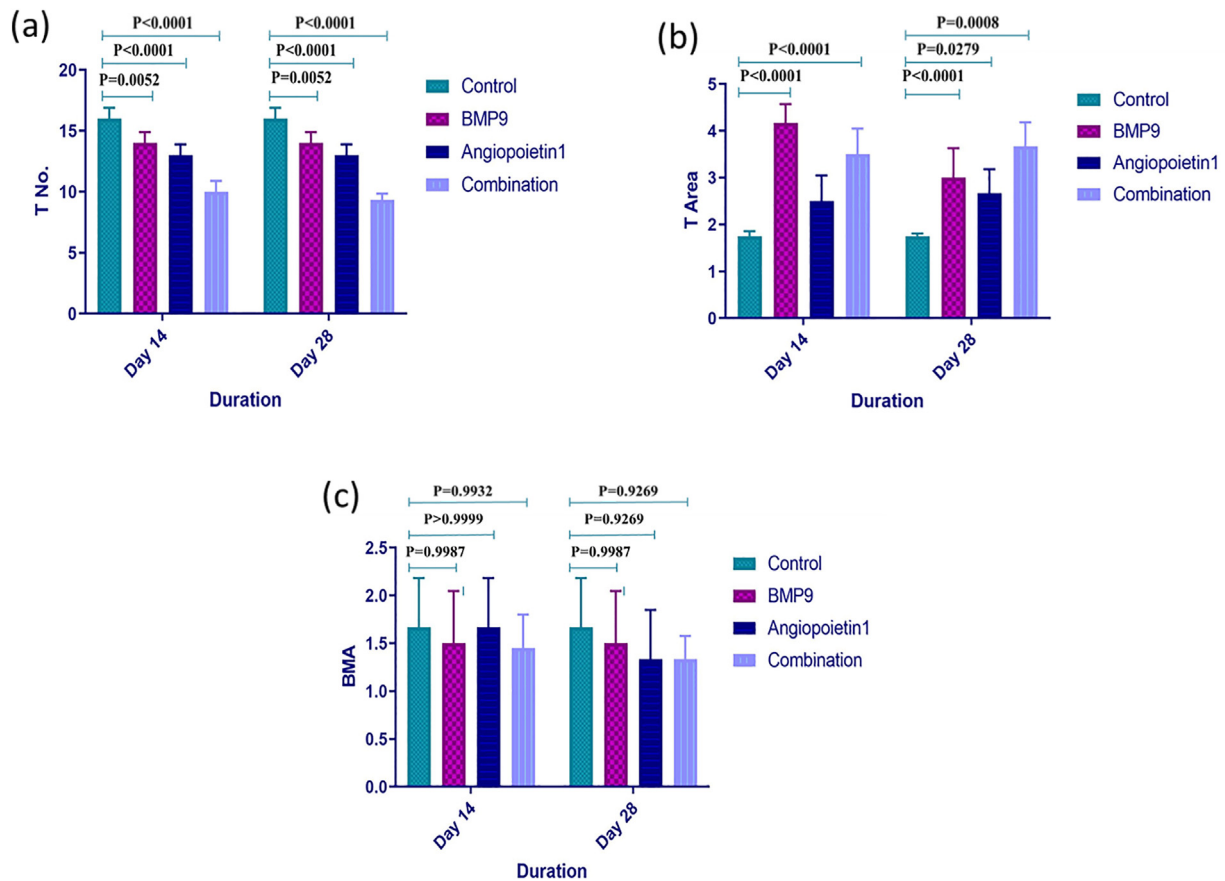


Figure 3: Histomorphometric analyses of (A) the number of trabeculae, (A) area of trabeculae, and (C) bone marrow area in the tibiae of albino rats on days 14 and 28 of treatment with bone morphogenic protein 9 (BMP9), angiopoietin 1 (Ang1), and the combination of BMP9 + Ang1, and a control group treated with a hemostatic sponge. $P < 0.05$ indicated a significant difference.

encourage the regeneration of bone and joints.³³ Additionally, BMP9 upregulates β -catenin protein levels, stimulates the Wnt/ β catenin signaling pathway, and enhances bone healing.³⁴

Bone is highly vascularized; hence, angiogenesis is thought to be a crucial stage in the process of bone repair. Newly created blood vessels contribute to the process of bone healing by supplying nutrients, transporting large molecules, allowing cells to aggregate, and maintaining the ideal metabolic environment. Ang1 has been linked to vessel remodeling and protection.¹⁰ Ang1 has the ability to inhibit apoptosis and stimulate migration of endothelial cells. Ang1 binds and transmits signals via Tie2 receptor tyrosine kinase. The quiescence of hematopoietic stem cells in the bone marrow niche is controlled by Tie2/Ang1 signaling.¹⁷

Quantitative analyses are crucial for studies that attempt to evaluate the efficacy of new therapeutic approaches for bone osteogenesis and angiogenesis. Therefore, histomorphometric analyses were carried out to detect the presence of bone in the defected area. Osteoblasts, osteocytes, and osteoclasts are the primary agents of bone resorption and production.³⁵ This study illustrated that treatment with a combination of BMP9 + Ang1 significantly decreased the number of osteoblasts while significantly increasing the number of osteocytes and osteoclasts on day 28 after operation compared with the control group. Osteoblasts

play a key role in the development of new mineralized tissues, comprising vascular endothelium and autonomic or sensory neurons throughout the subsequent stages of bone creation and rehabilitation.³⁶ This result may be explained by the fact that cell counting revealed that most of the surviving osteoblasts settled on the bone defect site because woven bone is formed and matured. The majority of osteoblasts that generate the bone become stuck inside the matrix and are referred to as osteocytes, which eventually stop secreting osteoid.² In a previous study conducted by Monfoulet et al.,³⁷ the authors created a drilled hole transcortical bone defect in the mid-diaphysis of the mouse femur and found that after 2 weeks, immature bone kept accumulating in the drilled hole and the cavity was filled with mature lamellar cortical bone after 4 weeks.

Neovascularization is crucial for the repair of bone defects and fractures.³⁸ It was clear from the results that the TN was significantly decreased in all treated groups, which enclosed newly formed bone marrow compared with the control group. Our results are in accordance with those of Toru et al.,²³ who found that osteogenesis and angiogenesis were stimulated by Ang1, which is expressed by osteoblasts. While for the combination group, a significant decrease was found in the number of bone trabeculae surrounding the haversian canals with a decreasing BMA, which indicated the formation of new

Table 2: Mean values of the number of trabeculae, trabecular area, and area of bone marrow in the tibiae bone of albino rats on days 14 and 28 of experimental groups treated with bone morphogenic protein 9 (BMP9), angiopoietin 1 (Ang1), and the combination of BMP9 + Ang1, and a control group treated with a hemostatic sponge.

	Duration	Groups	Descriptive statistics			
			Mean	SD	Min	Max
Trabecular number	14 days	Control	16.00 ^a	0.89	15.00	17.00
		BMP9	14.00 ^{b,c}	0.89	13.00	15.00
		Ang1	13.00 ^{b,c}	0.89	12.00	14.00
		Combination	10.00 ^{b,c}	0.89	9.00	11.00
Trabecular number	28 days	Control	16.00 ^a	0.89	15.00	17.00
		BMP9	14.00 ^{b,c}	0.89	13.00	15.00
		Ang1	13.00 ^{b,c}	0.89	12.00	14.00
		Combination	9.33 ^{b,c}	0.51	9.00	10.00
Trabecular area	14 days	Control	1.75 ^a	0.10	1.60	1.90
		BMP9	4.16 ^{b,c}	0.40	4.00	5.00
		Ang1	2.50 ^{a,c}	0.54	2.00	3.00
		Combination	3.50 ^{b,c}	0.54	3.00	4.00
Trabecular area	28 days	Control	1.75 ^a	0.05	1.70	1.80
		BMP9	3.00 ^b	0.63	2.00	4.00
		Ang1	2.66 ^{b,c}	0.51	2.00	3.00
		Combination	3.66 ^{b,c}	0.51	3.00	4.00
Bone marrow area	14 days	Control	1.66 ^a	0.51	1.00	2.00
		BMP9	1.50 ^a	0.54	1.00	2.00
		Ang1	1.66 ^a	0.51	1.00	2.00
		Combination	1.45 ^a	0.35	1.00	1.90
Bone marrow area	28 days	Control	1.66 ^a	0.51	1.00	2.00
		BMP9	1.50 ^a	0.54	1.00	2.00
		Ang1	1.33 ^a	0.51	1.00	2.00
		Combination	1.33 ^a	0.24	1.00	1.70

^{a-c} Different letters show statistically significant differences ($P < 0.05$).

bone compared with the control group. This was due to BMP9's potent angiogenesis and remodeling of bone marrow stem cells that differentiate into osteoblasts when combined with Ang1.

The trabecular bone area recorded in this study was significantly increased in all treated groups compared with the control group and was more clearly observed in the combination group after 4 weeks. A previous study suggested that the process of bone repair occurs at the same level as the progression of bone maturation, and the TA values in the experimental groups were higher than those in the control group.³⁹

The results of this study showed that the BMA decreased in the treated groups compared with the control group on days 14 and 28. However, this decrease was statistically non-significant, and the lowest values were observed in the combination group, indicating increased density and maturity of the bone that filled the defected site. This finding could be explained according to the outcomes of a previous study conducted by Tera et al.,⁴⁰ who showed that osteoblast

precursors proliferate and differentiate into osteoblasts, which occupy the resorption area and start to produce new bone by releasing osteoid, which is ultimately mineralized. Despite these promising consequences, future studies are necessary to expand the understanding of mechanisms associated with induced bone healing. In addition, more investigations are needed to determine the effectiveness and safety of administering BMP9 and Ang1 to large animals and humans.

Conclusion

In conclusion, osteogenesis and angiogenesis work together to produce and repair bones. The results obtained in this study showed that the combination of BMP9 and Ang1 has therapeutic potential in promoting the healing process of bone defects. These factors act together to accelerate bone regeneration more efficiently than either factor alone.

Source of funding

This research did not receive any specific grant from funding agencies in the public, commercial, or not-for-profit sectors.

Conflict of interest

The authors have no conflicts of interest to declare.

Ethical approval

Ethical approval was granted by the University of Baghdad (Approval No. 583, 17/04/2022).

Authors contributions

EF conceived and designed the study, conducted the research, and provided research materials. RHD analyzed and interpreted the data, and wrote the initial and final drafts of the article. ZJW collected and organized the data. JH provided logistical support. All authors have critically reviewed and approved the final draft and are responsible for the content and similarity index of the manuscript.

References

- Fadhil E, Alhijazi AY. Histological and immunohistochemical evaluation of the effect of local exogenous application of VEGF on bone healing (experimental study in rat). *J Bagh Coll Dent* 2014; 26(4): 108–115. <https://jbc.d.uobaghdad.edu.iq/index.php/jbcd/article/view/599>.
- McGonnell IM, Grigoriadis AE, Lam EW-F, Price JS, Sinters A. A specific role for phosphoinositide 3-kinase and AKT in osteoblasts. *Front Endocrinol (Lausanne)* 2012; 3: 88. <http://www.ncbi.nlm.nih.gov/pubmed/22833734>.
- Wang X, Wang Y, Gou W, Lu Q, Peng J, Lu S. Role of mesenchymal stem cells in bone regeneration and fracture repair: a review. *Int Orthop* 2013; 37(12): 2491–2498. <http://link.springer.com/10.1007/s00264-013-2059-2>.
- Setiawati R, Rahardjo P. Bone development and growth. In: *Osteogenesis and bone regeneration*. IntechOpen 2019. <https://>

- www.intechopen.com/books/osteogenesis-and-bone-regeneration/bone-development-and-growth.
5. Wang P, Wang Y, Tang W, Wang X, Pang Y, Yang S, et al. Bone morphogenetic protein-9 enhances osteogenic differentiation of human periodontal ligament stem cells via the JNK pathway. Reilly G, editor. *PLoS One* 2017; 12(1):e0169123. <https://dx.plos.org/10.1371/journal.pone.0169123>.
 6. Mescher AL. *Bone. Junqueira's basic histology: text and atlas*. 15th ed. McGraw-Hill; 2018.
 7. Garrison KR, Shemilt I, Donell S, Ryder JJ, Mugford M, Harvey I, et al. Bone morphogenetic protein (BMP) for fracture healing in adults. *Cochrane Database Syst Rev* 2010; 6. <https://doi.wiley.com/10.1002/14651858.CD006950.pub2>.
 8. Hodgson J, Swietlik EM, Salmon RM, Hadinnapola C, Nikolic I, Wharton J, et al. Characterization of GDF2 mutations and levels of BMP9 and BMP10 in pulmonary arterial hypertension. *Am J Respir Crit Care Med* 2020; 201(5): 575–585.
 9. Beederman M, Lamplot JD, Nan G, Wang J, Liu X, Yin L, et al. BMP signaling in mesenchymal stem cell differentiation and bone formation. *J Biomed Sci Eng* 2013; 6(8): 32–52. <http://www.scirp.org/journal/doi.aspx?DOI=10.4236/jbise.2013.68A1004>.
 10. Zhu L, Liu Y, Wang A, Zhu Z, Li Y, Zhu C, et al. Application of BMP in bone tissue engineering. *Front Bioeng Biotechnol* 2022; 10. <https://www.frontiersin.org/articles/10.3389/fbioe.2022.810880/full>.
 11. Khazaal H, Helman J. Narrative review: craniofacial bone regeneration—where are we now? *Front Oral Maxillofac Med* 2022; 4. <https://doi.org/10.21037/fomm-21-9>. 9–9.
 12. Mostafa S, Pakvasa M, Coalson E, Zhu A, Alverdy A, Castillo H, et al. The wonders of BMP9: from mesenchymal stem cell differentiation, angiogenesis, neurogenesis, tumorigenesis, and metabolism to regenerative medicine. *Genes Dis* 2019; 6(3): 201–223. <https://linkinghub.elsevier.com/retrieve/pii/S2352304219300467>.
 13. Balaji S, Han N, Moles C, Shaaban AF, Bollyky PL, Crombleholme TM, et al. Angiopoietin-1 improves endothelial progenitor cell-dependent neovascularization in diabetic wounds. *Surgery* 2015; 158(3): 846–856. <https://linkinghub.elsevier.com/retrieve/pii/S0039606015005334>.
 14. Santulli G. Angiopoietin-like proteins: a comprehensive look. *Front Endocrinol (Lausanne)* 2014; 5. <http://journal.frontiersin.org/article/10.3389/fendo.2014.00004/abstract>.
 15. Alawo DOA, Tahir TA, Fischer M, Bates DG, Amirova SR, Brindle NPJ. Regulation of angiopoietin signalling by soluble Tie2 ectodomain and engineered ligand trap. *Sci Rep* 2017; 7(1): 3658. <http://www.nature.com/articles/s41598-017-03981-6>.
 16. Cleaver O, Krieg PA. Vascular development. In: Rosenthal N, Harvey RP, editors. *Heart Development and Regeneration*; 2010. pp. 487–528. <https://linkinghub.elsevier.com/retrieve/pii/B9780123813329000232>.
 17. Brindle NPJ, Saharinen P, Alitalo K. Signaling and functions of angiopoietin-1 in vascular protection. *Circ Res* 2006; 98(8): 1014–1023. <https://www.ahajournals.org/doi/10.1161/01.RES.0000218275.54089.12>.
 18. Saharinen P, Eklund L, Alitalo K. Therapeutic targeting of the angiopoietin-TIE pathway. *Nat Rev* 2017; 16: 635–661.
 19. Hajosch R, Suckfuell M, Oesser S, Ahlers M, Flechsenhar K, Schlosshauer B. A novel gelatin sponge for accelerated hemostasis. *J Biomed Mater Res Part B Appl Biomater* 2010; 94B(2): 372–379. <https://onlinelibrary.wiley.com/doi/10.1002/jbm.b.31663>.
 20. Tsugawa AJ, Verstraete FJM. Suture materials and biomaterials. In: *Oral and maxillofacial surgery in dogs and cats*; 2012. pp. 69–78. <https://linkinghub.elsevier.com/retrieve/pii/B9780702046186000075>.
 21. Ibrahim LM, Jassim RK, Gabban A Al. Biomechanical and histomorphometric analysis of max phase (Ti2AlC) alloy as an implant. *J Res Med Dent Sci* 2022; 10(8): 51–57.
 22. Tambursetuen MV, Reseland JE, Spahr A, Brookes SJ, Kvalheim G, Slaby I, et al. Ameloblastin expression and putative autoregulation in mesenchymal cells suggest a role in early bone formation and repair. *Bone* 2011; 48(2): 406–413. <https://linkinghub.elsevier.com/retrieve/pii/S8756328210014523>.
 23. Suzuki T, Miyamoto T, Fujita N, Ninomiya K, Iwasaki R, Toyama Y, et al. Osteoblast-specific Angiopoietin 1 over-expression increases bone mass. *Biochem Biophys Res Commun* 2007; 362(4): 1019–1025. <https://linkinghub.elsevier.com/retrieve/pii/S0006291X07018244>.
 24. Lu X, Li W, Fukumoto S, Yamada Y, Evans CA, Diekwisch T, et al. The ameloblastin extracellular matrix molecule enhances bone fracture resistance and promotes rapid bone fracture healing. *Matrix Biol* 2016; 52–54: 113–126. <https://linkinghub.elsevier.com/retrieve/pii/S0945053X1630018X>.
 25. Schell H, Duda GN, Peters A, Tsitsilonis S, Johnson KA, Schmidt-Bleek K. The haematoma and its role in bone healing. *J Exp Orthop* 2017; 4(1): 5. <http://jeo-esska.springeropen.com/articles/10.1186/s40634-017-0079-3>.
 26. Raggatt LJ, Partridge NC. Cellular and molecular mechanisms of bone remodeling. *J Biol Chem* 2010; 285(33): 25103–25108. <https://linkinghub.elsevier.com/retrieve/pii/S002192582059892X>.
 27. Sheen JG. Fracture healing overview. *Ncbi* 2021. <https://www.ncbi.nlm.nih.gov/books/NBK551678/>.
 28. Panteli M, Pountos I, Jones E, Giannoudis PV. Biological and molecular profile of fracture non-union tissue: current insights. *J Cell Mol Med* 2015; 19(4): 685–713. <https://onlinelibrary.wiley.com/doi/10.1111/jcmm.12532>.
 29. Liu Z, Zhang J, He K, Zhang Y, Zhang Y. Optimized clinical practice for superaged patients with hip fracture: significance of damage control and enhanced recovery program. *Burn Trauma* 2019; 7. <https://academic.oup.com/burnstrauma/article/doi/10.1186/s41038-019-0159-y/5685889>.
 30. Albertazzi P. Purified phytoestrogens in postmenopausal bone health: is there a role for genistein? *Climacteric* 2002; 5(2): 190–196. <http://www.tandfonline.com/doi/full/10.1080/cmt.5.2.190.196>.
 31. Bastos MF, Brilhante FV, Bezerra JP, Silva CA, Duarte PM. Trabecular bone area and bone healing in spontaneously hypertensive rats: a histometric study. *Braz Oral Res* 2010; 24(2): 170–176. http://www.scielo.br/scielo.php?script=sci_arttext&pid=S1806-83242010000200008&lng=en&tng=en.
 32. Zhang L, Luo Q, Shu Y, Zeng Z, Huang B, Feng Y, et al. Transcriptomic landscape regulated by the 14 types of bone morphogenetic proteins (BMPs) in lineage commitment and differentiation of mesenchymal stem cells (MSCs). *Genes Dis* 2019; 6(3): 258–275. <https://linkinghub.elsevier.com/retrieve/pii/S2352304219300169>.
 33. Yu L, Dawson LA, Yan M, Zimmer K, Lin YL, Dolan CP, et al. BMP9 stimulates joint regeneration at digit amputation wounds in mice. *Nat Commun* 2019; 10(1).
 34. Kusuyama J, Seong C, Nakamura T, Ohnishi T, Amir MS, Shima K, et al. BMP9 prevents induction of osteopontin in JNK-inactivated osteoblasts via Hey1-Id4 interaction. *Int J Biochem Cell Biol* 2019; 116.
 35. Hu C, Qin Q-H. Bone remodeling and biological effects of mechanical stimulus. *Bioengineering* 2020; 7(1): 12–28.
 36. Kusumbe AP, Ramasamy SK, Adams RH. Coupling of angiogenesis and osteogenesis by a specific vessel subtype in bone. *Nature* 2014; 507(7492): 323–328. <http://www.nature.com/articles/nature13145>.
 37. Monfoulet L, Rabier B, Chassande O, Fricain J-C. Drilled hole defects in mouse femur as models of intramembranous cortical

- and cancellous bone regeneration. *Calcif Tissue Int* **2010**; 86(1): 72–81. <http://link.springer.com/10.1007/s00223-009-9314-y>.
38. Liu Z, Li Y, Yang J, Huang J, Luo C, Zhang J, et al. Bone morphogenetic protein 9 enhances osteogenic and angiogenic responses of human amniotic mesenchymal stem cells cocultured with umbilical vein endothelial cells through the PI3K/AKT/m-TOR signaling pathway. *Aging (Albany NY)* **2021**; 13(22): 24829–24849. <https://www.aging-us.com/lookup/doi/10.18632/aging.203718>.
39. Majeed SS, Ghani BA. Effect of topical application of flavonoids extract of *Hibiscus sabdariffa* on experimentally induced bone defect. *J Baghdad Coll Dent* **2018**; 30(1): 33–38. <http://jbcd.uobaghdad.edu.iq/index.php/jbcd/article/view/2439>.
40. Tera T de M, Nascimento RD, Prado RF, Santamaria MP, Jardini M. Immunolocalization of markers for bone formation during guided bone regeneration in osteopenic rats. *J Appl Oral Sci* **2014**; 22(6): 541–553. http://www.scielo.br/scielo.php?script=sci_arttext&pid=S1678-77572014000600541&lng=en&tlng=en.

How to cite this article: Fadhil E, Dosh RH, Wally ZJ, Haider J. Histological evaluation of the effects of bone morphogenetic protein 9 and angiopoietin 1 on bone healing. *J Taibah Univ Med Sc* 2023;18(5):954–963.