



9-2022

## Clinical Spectrum, Risk Factors and Electrophysiologic Aspect of Radial Nerve Injury

Arfah Kanwal

*King Edward Medical University, Lahore*

Safia Bano

*King Edward Medical University, Lahore*

Ubaid Ullah

*Ibn-e-Siena Hospital and Medical Research Institute*

Ahsan Numan

*King Edward Medical University, Lahore*

Follow this and additional works at: <https://ecommons.aku.edu/pjns>

 Part of the [Neurology Commons](#)

### Recommended Citation

Kanwal, Arfah; Bano, Safia; Ullah, Ubaid; and Numan, Ahsan (2022) "Clinical Spectrum, Risk Factors and Electrophysiologic Aspect of Radial Nerve Injury," *Pakistan Journal of Neurological Sciences (PJNS)*: Vol. 17: Iss. 3, Article 5.

Available at: <https://ecommons.aku.edu/pjns/vol17/iss3/5>



# CLINICAL SPECTRUM, RISK FACTORS AND ELECTROPHYSIOLOGIC ASPECT OF RADIAL NERVE INJURY

Arfah Kanwal<sup>1</sup>, Safia Bano<sup>2</sup>, Ubaid Ullah<sup>3</sup>, Ahsan Numan<sup>2</sup>

<sup>1</sup>.Department of Neurophysiology, King Edward Medical University, Lahore

<sup>2</sup>.Department of Neurology, King Edward Medical University, Lahore

<sup>3</sup>.Department of Neurology, Ibn-e-Siena Hospital and Medical Research Institute

**Corresponding author:** Safia Bano Department of Neurology, King Edward Medical University, Lahore **Email:** safiabano207@gmail.com

**Date of submission:** January 15, 2022 **Date of revision:** February 5, 2023 **Date of acceptance:** February 5, 2023

## ABSTRACT

### Background and objective:

Radial nerve is injured due to a variety of reasons. The objective of this study was to determine the clinical spectrum, risk factors and electrophysiologic aspect of radial nerve injury presenting to a tertiary care hospital in Lahore.

### Methods:

This descriptive prospective cross-sectional study was conducted at department of Neurology, Mayo hospital Lahore from July 2022 to December 2022 and comprised patients with isolated radial nerve injury on the basis of history and clinical examination regardless of their gender, above 15 years of age. NCS/EMG was done on a Japanese machine Nihon Kohden by an expert as per recommended protocol for electrodiagnostic evaluation of a suspected radial nerve injury and interpreted by consultant neurologist.

### Results:

Of 75 patients, 52(69.3%) were males and 23(30.7%) were females. The most common etiology turned out to be misplaced intramuscular injection in 45(60%) of the patients. The site of lesion in most cases was in the spiral groove in 36 (40%) of the patient. Most of the patients i.e. 71(94.7%) had a wrist drop. Evidence of reinnervation was present in 30(40%) of patients.

**Conclusion:** Most cases of radial nerve injury presented with a wrist drop in which the commonest etiology was misplaced intramuscular injection. The site of lesion in most cases turned out to be at the level of spiral groove, and the nature of lesion was primarily axonal loss followed by secondary demyelination.

**Key words:** Electromyography (EMG), Nerve conduction studies(NCS), Radial nerve injury (RNI), Electro diagnostic studies (EDX), Intramuscular (IM) injection

## INTRODUCTION

Radial nerve injury is the third most commonly injured nerve after median and ulnar nerve.<sup>1</sup> Wrist drop is the manifestation in most of radial neuropathy however its manifestation can mimic brachial plexopathy, C7 radiculopathy or central lesion.<sup>2</sup> Radial nerve injury may occur as a result of fracture of humerus, blunt or penetrating trauma, compression or ischemia and rarely from tumors. Other causes may involve misplaced IM injection or Saturday night palsy.<sup>3,4</sup>

The success of treatment in radial nerve injury is directly related to appropriate decision making regarding requirement of surgery or alternative interventions.<sup>1</sup> This necessitates the localization and assessment of severity of lesion. Electrodiagnostic studies serve this purpose by confirming, localizing and quantifying the lesion severity. It can narrow down the differential diagnosis and find out subclinical recovery or hidden clinical disorders. Thus, electro diagnostic studies are an important investigation complementing thorough history, physical examination and imaging

studies that can lead to an accurate diagnosis and treatment plan. Nerve conduction studies and electromyography form the core of electrodiagnostic evaluation.<sup>2,5</sup>

The current study was planned to use electrodiagnostic evaluation in patients with radial nerve injury, to assess the clinical spectrum and various risk factors that can lead to radial nerve injury.

## **METHODS**

**Study design:** Prospective cross-sectional observational study.

**Place and duration of study:** This study was conducted at the Department of Neurology, Mayo hospital, Lahore, Pakistan from July 2022 to December 2022, and comprised patients with isolated radial nerve injury on the basis of history and clinical examination regardless of gender, with age above 15 years.

**Sample size:** Seventy-five patients were included in this study. **Sampling technique:** Non-probability consecutive sampling.

**Data collection:** After getting approval of the study from ethical and institutional review board of King Edward Medical University, 75 patients were included in the study. The included patients had radial nerve injury for more than three preceding weeks. Those with a history of polyneuropathy, radiculopathy or any other central nervous system disorder were not included in this study. After detailed history and physical examination, electrodiagnostic evaluation was done using a Japanese machine Nihon Kohden in accordance with the protocol recommended by Preston

and Shapiro for EDX evaluation of a suspected radial nerve injury.<sup>6</sup> The procedure was performed by an expert electro-physiologist and the results were interpreted by a consultant neurologist. Radial, Ulnar and Median nerves were tested during NCS. Radial innervated muscles (extensor indices/extensor digitorum, brachioradialis, and triceps) were sampled during EMG. The data obtained was recorded on pre-designed Performa.

**Statistical analysis:** Statistical analysis was done using SPSS 20.

## **RESULTS**

Of 75 patients, 52(69.3%) were males and 23(30.7%) were females. Most of the patients were between 20-30 years age group. Mean age of the patients was  $35 \pm 11.3$ .

Left upper limb was affected in 44(58.7%) patients while right upper limb was involved in 31(41.3%) individuals. Most of the patients presenting to electrophysiology room had chronic course i.e. in 70(93.1%) patients.

Pain was a prominent feature in many individuals ranging from mild to moderate, although some patients had no complaint of pain. Thirty-five (46.7%) patients experienced mild pain while 30(40%) of patients experienced moderate pain. Two (2.7%) patients did not experience any pain while eight (10.7%) patients experienced severe pain.

In our sample of 75 patients, 11(14.7%) patients had diabetes along with radial nerve injury (RNI), 12 (16%) patients had hypertension and one (1.3%) patient was obese (Table 1).

**Table 1:** Demographic and clinical characteristics of the study population

		Frequency (n)	Percentage (%)
<b>Age</b>	<b>Less than 20 years</b>	18	24
	<b>20-30 years</b>	29	38.7
	<b>31-40 years</b>	11	14.7
	<b>41-50 years</b>	10	13.3
	<b>Above 50 years</b>	07	9.3
<b>Gender</b>	<b>Male</b>	52	69.3
	<b>Female</b>	23	30.7
<b>Side involved</b>	<b>Right upper limb</b>	31	41.3
	<b>Left upper limb</b>	44	58.7
<b>Temporal course</b>	<b>Acute</b>	0.0	0.0
	<b>Subacute</b>	05	6.7
	<b>Chronic</b>	70	93.3
<b>Pain scale</b>	<b>No pain (0)</b>	02	2.7
	<b>Mild pain (1-3)</b>	35	46.7
	<b>Moderate pain (4-6)</b>	30	40
	<b>Severe pain (7-9)</b>	08	10.7
	<b>Very severe pain (10)</b>	0.0	0.0
<b>Comorbidities</b>	<b>Diabetes</b>	11	14.7
	<b>Hypertension</b>	12	16
	<b>Obesity</b>	01	1.3

All the patients had some common clinical features i.e. wrist drop due to weakness of extensor muscle, paresthesia and sensory loss over the radial nerve territory. However, some patients felt radiating neck pain i.e. 28(37.3%).

The commonest cause of radial nerve injury was misplaced IM injection in 45(60%). It was followed by trauma in 29(38.7%) patients with or without fracture of humerus, caused by motor vehicle accidents, stab injuries, and gunshot injuries. Only one patient was presented with abscess causing damage to radial nerve.

Electrodiagnostic evaluation revealed that 36(48%) patient had RNI at level of spiral groove, 34(45.3%) patients had RNI above the level of spiral groove and five (6.7%) patients had posterior interosseous nerve injury at arcade of Frohse which is the motor branch of radial nerve.

The pathophysiology behind most of the cases was primarily axonal loss with secondary demyelination, however 16 (21.3%) cases were purely axonal loss lesion. Evidence of reinnervation was present in 30(40%) of patients. (Table 2).

**Table 2:** Electrophysiologic characteristics of the study population

		<b>Frequency (n)</b>	<b>Percentage (%)</b>
<b>Motor nerve conduction studies</b>	<b>Absent response of radial nerve</b>	53	70.7
	<b>Abnormal response of radial nerve</b>	22	29.3
	<b>Normal response of radial nerve</b>	0.0	0.0
<b>Sensory nerve conduction studies</b>	<b>Absent response of radial nerve</b>	41	54.7
	<b>Abnormal response of radial nerve</b>	29	38.7
	<b>Normal response of radial nerve</b>	05	6.7
<b>Localization of the lesion on the basis of EMG</b>	<b>At the spiral groove</b>	36	48.0
	<b>Above the spiral groove</b>	34	45.3
	<b>Posterior interosseous nerve</b>	05	6.7
<b>Evidence of reinnervation at the time of presentation</b>	<b>Present</b>	30	40
	<b>Absent</b>	45	60
<b>Severity on the basis of EDX findings</b>	<b>Demyelinating lesion</b>	0.0	0.0
	<b>Axonal loss lesion</b>	16	21.3
	<b>Both</b>	59	78.7

## DISCUSSION

The most common clinical feature of radial nerve injury in our study was wrist drop due to weakness of extensor muscles, which was consistent with the study conducted by Rasheed et al in 2015.<sup>4</sup>

A retrospective study conducted by Kakati et al in 2013 showed higher percentage of males affected by RNI as compared to females which is also consistent with our findings (i.e. 69.3% of patients were males and 30.7% were females).<sup>7</sup>

Another study conducted by Bawiskar et al in June, 2020 showed that left side was mostly involved in RNI, which is also consistent with our study (i.e. 58.7% of patients were having their left side affected).<sup>8</sup> This result might be due to injection is given on non-dominant arm.

Misplaced intramuscular injection was the most common etiology in our study that was inconsistent with the study conducted by Gill et al in which radial

nerve injury due to trauma(fracture of humerus) was the most common etiology of RNI.<sup>9</sup> This disparity might be due to people preference for injection as mode of treatment rather oral route or quacks/untrained medical practitioners in our setting.

EDX of radial nerve injury behind most of the cases was primarily axonal loss with secondary demyelination, which is in consistent with cited literature.<sup>4,9,10</sup> However, 16(21.3%) cases were purely axonal loss lesion. Evidence of re-innervation was present in 30(40%) of patients.

Our study showed 36(48%) patient had RNI at level of spiral groove, 34(45.3%) patients had RNI high in the arm above the level of spiral groove and five (6.7%) patients had posterior interosseous nerve injury which is the motor branch of radial nerve. This result is similar to other studies.<sup>11-13</sup> EDX studies help in localization, determine the pattern of peripheral nerve injuries i.e. axonal or demyelination, and prognosis depending nature of injury.<sup>11,12,14</sup>

There are few limitations of our study as single center study with small sample size. No follow up EDX was not done and nature of medications given via injection route was not inquired.

## CONCLUSION

The most common clinical presentation of radial nerve injury was wrist drop along with sensory loss over the radial territory. Posterior interosseous nerve injury due to trauma was not an unusual finding in our study. Most common etiology of radial nerve injury was reported as

misplaced IM injection. In our local population, injections are usually preferred over oral medication for quick relief and most of the time misplaced injections are administered by quacks or untrained health worker causing injuries to peripheral nerves. Thus, neuroanatomy understanding and proper structural training of health care workers is required with an emphasis on nerve injury at important anatomical locations and public awareness to avoid unnecessary injection practices.

## REFERENCES

1. DeFranco MJ, Lawton JN. Radial nerve injuries associated with humeral fractures. *J Hand Surg Am.* 2006;31(4):655-63.
2. Latef TJ, Bilal M, Vetter M, Iwanaga J, Oskouian RJ, Tubbs RS. Injury of the radial nerve in the arm: a review. *Cureus.* 2018 Feb 16;10(2).
3. Kimbrough DA, Mehta K, Wissman RD. Case of the season: Saturday Night Palsy. In *Seminars in Roentgenology* 2013 Apr 1 (Vol. 48, No. 2, pp. 108-110).
4. Rasheed MU, Mashhood AA, Akhtar MR, Khan MB. Radial nerve injuries: presenting as wrist drop-analysis of 100 patients. *Professional Med J.* 2008 Mar 10; 15(01):67-73.
5. Kirici Y, Irmak MK. Investigation of two possible compression sites of the deep branch of the radial nerve and nerve supply of the extensor carpi radialis brevis muscle. *Neurol Med Chir (Tokyo)* 2004
6. Shapiro BE, Preston DC. Entrapment and compressive neuropathies. *Med Clin North Am.* 2009 Mar 1;93(2):285-315.
7. Kakati A, Bhat D, Devi BI, Shukla D. Injection nerve palsy. *J Neurosci Rural Pract.* 2013 Jan; 4(1):13-8.
8. Bawiskar DP, Bais AS, Naqvi WM, Sahu A. Physiotherapy approach towards a typical case of injection induced radial nerve palsy presenting as wrist drop. *J Evol Med Dent Sci.* 2020 Jun 1;9(22):1722-4.
9. Gill ZA, Ayaz SB, Ahmad A, Matee S, Ahmad N. Electrophysiological and etiological evaluation of 119 cases of wrist drop: A single center study. *J Pak Med Assoc.* 2019 May 1;69:672-6.
10. Uzun N, Savrun FK, Kiziltan ME. Electrophysiologic evaluation of peripheral nerve injuries in children following the Marmara earthquake. *J Child Neurol.* 2005; 20: 207-12
11. Wang LH, Weiss MD. Anatomical, clinical, and electrodiagnostic features of radial neuropathies. *Phys Med Rehabil Clin N Am.*
12. Barnes SL, Miller TA, Simon NG. Traumatic peripheral nerve injuries: diagnosis and management. *Curr Opin Neurol.* 2022 Dec 1;35(6):718-27.
13. Pandian JD, Bose S, Daniel V, Singh Y, Abraham AP. Nerve injuries following intramuscular injections: a clinical and neurophysiological study from Northwest India. *J Peripher Nerv Syst.* 2006;11(2):165-71.
14. Malinkowski T, Mickleson PJ, Robinson LR. Prognostic values of electrodiagnostic studies in traumatic radial neuropathy. *Muscle Nerve.* 2007;36(3):364-7.

Conflict of interest: Author declares no conflict of interest.

Funding disclosure: Nil

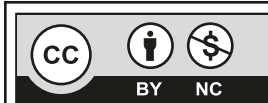
Author's contribution:

**Arfah Kanwal;** concept, data collection, data analysis, manuscript writing, manuscript review

**Safia Bano;** data collection, data analysis, manuscript writing, manuscript review

**Ubaid Ullah;** data collection, data analysis, manuscript writing

**Ahsan Numan;** concept, manuscript review



This is an Open Access article distributed under the terms of the Creative Commons Attribution-Non Commercial 2.0 Generic License.