

12-1-2020

Cardiac biomarkers during cancer therapy: Practical applications for cardio-oncology

Jose A Alvarez-Cardona
Washington University School of Medicine in St. Louis

Kathleen W Zhang
Washington University School of Medicine in St. Louis

Joshua D Mitchell
Washington University School of Medicine in St. Louis

Vlad G Zaha
University of Texas Southwestern

Michael J Fisch
University of Texas MD Anderson Cancer Center

See next page for additional authors

Follow this and additional works at: https://digitalcommons.wustl.edu/oa_4



Part of the [Medicine and Health Sciences Commons](#)

Please let us know how this document benefits you.

Recommended Citation

Alvarez-Cardona, Jose A; Zhang, Kathleen W; Mitchell, Joshua D; Zaha, Vlad G; Fisch, Michael J; and Lenihan, Daniel J, "Cardiac biomarkers during cancer therapy: Practical applications for cardio-oncology." *JACC: CardioOncology*. 2, 5. 791 - 794. (2020).
https://digitalcommons.wustl.edu/oa_4/1123

This Open Access Publication is brought to you for free and open access by the Open Access Publications at Digital Commons@Becker. It has been accepted for inclusion in 2020-Current year OA Pubs by an authorized administrator of Digital Commons@Becker. For more information, please contact vanam@wustl.edu.

Authors

Jose A Alvarez-Cardona, Kathleen W Zhang, Joshua D Mitchell, Vlad G Zaha, Michael J Fisch, and Daniel J Lenihan

HOW TO

Cardiac Biomarkers During Cancer Therapy



Practical Applications for Cardio-Oncology

Jose A. Alvarez-Cardona, MD,^a Kathleen W. Zhang, MD,^a Joshua D. Mitchell, MD,^a Vlad G. Zaha, MD, PhD,^b Michael J. Fisch, MD,^c Daniel J. Lenihan, MD^a

Combined modality approaches to cancer treatment have dramatically improved clinical outcomes. At the same time, there has been increased attention to acute, chronic, and late effects of treatment, including the management of cardiac disease in patients with cancer (1). It is recognized that there are limited sensitivity and specificity of traditional cardiovascular (CV) testing, such as electrocardiography (ECG) and transthoracic echocardiography (TTE), for early detection of myocardial injury. Therefore, there is a compelling need to improve risk prediction and to detect subclinical disease at a potentially reversible stage to allow implementation of cardioprotective strategies and improve outcomes (2). Cardiac blood-based biomarkers continue to be explored to improve the detection and long-term monitoring of subclinical cardiotoxicity.

In order for a biomarker to be useful, it should be accurate, be easy to measure, and provide important information relative to treatment outcome. A prognostic biomarker forecasts the likely course of a disease irrespective of treatment, whereas a predictive biomarker forecasts the likely response to a specific treatment (3). It is important to understand the clinical implications of an abnormal cardiac biomarker and how this information can inform treatment decisions. **Figure 1** shows 4 different profiles (I, II, III, and IV) in which traditional cardiac biomarkers, natriuretic

peptides (N-terminal pro-B-type natriuretic peptide [NT-proBNP] or B-type natriuretic peptide [BNP]) and troponins, can help identify the development of a CV adverse event during cancer therapy. In general, an elevated natriuretic peptide (NP) level represents hemodynamic congestion, whereas an abnormal troponin is a marker of myocardial injury. Although the specific CV conditions a patient may experience with contemporary cancer therapy are broad (**Figure 1**), cardiac biomarkers can indicate ongoing stress and injury. The following cases illustrate how cardiac biomarkers may be used to guide clinical decision-making in cardio-oncology.

CASE 1: PREDICTION AND DETECTION OF CARDIOTOXICITY

A 73-year-old woman with stage IVB diffuse large B-cell lymphoma was scheduled for 6 cycles of rituximab, cyclophosphamide, doxorubicin (anticipated cumulative dose 280 mg/m²), vincristine, prednisone, and CC-122 (an experimental pleiotropic pathway modifier that is an immune modulatory therapy), and 4 cycles of intrathecal methotrexate. Pre-chemotherapy evaluation showed a left ventricular (LV) ejection fraction (LVEF) of 53%, global longitudinal strain (GLS) -15.5% (normal <-18% to -22%), and grade I diastolic dysfunction on TTE, NT-proBNP elevation at 864 pg/ml (normal <300 pg/ml), and

From the ^aCardio-Oncology Center of Excellence, Cardiovascular Division, Washington University School of Medicine, St. Louis, Missouri, USA; ^bDivision of Cardiology, Department of Internal Medicine, Harold C. Simmons Comprehensive Cancer Center and Advanced Imaging Research Center, University of Texas Southwestern, Dallas, Texas, USA; and the ^cDepartment of General Oncology, University of Texas MD Anderson Cancer Center, Houston, Texas, USA. Daniela Cardinale, MD, served as the Guest Associate Editor for this paper. Anju Nohria, MD, served as Guest Editor-in-Chief for this paper. The authors attest they are in compliance with human studies committees and animal welfare regulations of the authors' institutions and Food and Drug Administration guidelines, including patient consent where appropriate. For more information, visit the [Author Center](#).

Manuscript received May 22, 2020; revised manuscript received August 19, 2020, accepted August 21, 2020.

**ABBREVIATIONS
AND ACRONYMS****BNP** = B-type natriuretic peptide**cmRI** = cardiac magnetic resonance imaging**CV** = cardiovascular**ECG** = electrocardiography**EMBx** = endomyocardial biopsy**GLS** = global longitudinal strain**HF** = heart failure**HFpEF** = heart failure with preserved ejection fraction**LGE** = late gadolinium enhancement**LV** = left ventricular**LVEF** = left ventricular ejection fraction**NP** = natriuretic peptide**NT-proBNP** = N-terminal pro-B-type natriuretic peptide**TTE** = transthoracic echocardiography

undetectable troponin I (**Figure 1**) (profile II). Her total cholesterol was 250 mg/dl and low-density lipoprotein was 133 mg/dl, and chest computed tomography revealed substantial coronary calcifications. Her age, hyperlipidemia, anticipated high-dose exposure to anthracyclines (>250 mg/m²), coronary calcification, and underlying heart failure (HF) with preserved ejection fraction (HFpEF) placed her at high risk for cardiotoxicity. Carvedilol, rosuvastatin, and aspirin 81 mg were initiated before and continued through chemotherapy (1,4). Furosemide was prescribed for evidence of volume overload and HF. At 3 months, LVEF remained unchanged, but NT-proBNP increased to 2,963 pg/ml, and troponin I had become minimally elevated at 0.05 ng/ml (normal <0.03 ng/ml) indicating congestion and potential injury, prompting adjustment of furosemide and carvedilol dosing. Upon completion of 6 months of chemotherapy, the LVEF decreased to 45% (GLS not obtained), NT-proBNP had improved to 795 pg/ml, but

troponin I was persistently elevated (0.22 to 0.25 ng/ml) on serial assessment (profile IV), with an unchanged ECG. Lisinopril was added to optimize CV therapy. The differential diagnosis included myocardial ischemia, anthracycline-related cardiotoxicity, and CC-122-related myocarditis, and a cardiac magnetic resonance imaging (cmRI) was performed showing a mildly depressed LVEF (43%) with late gadolinium enhancement (LGE) in the right coronary artery territory suggestive of prior myocardial infarction. Subsequent left heart catheterization showed mild, nonobstructive multivessel coronary artery disease and elevated LV end-diastolic pressure at 18 mm Hg. The combination of an elevated troponin and LGE on cmRI is consistent with myocardial injury, probably related to anthracycline chemotherapy especially in the absence of significant coronary artery disease. It is currently unknown whether there are important CV effects of CC-122. Twelve months after initiating anthracycline-based chemotherapy and with optimal cardioprotective therapy, her LVEF normalized (67%), but GLS did not (–11.9%). NT-proBNP remained modestly elevated at 440 pg/ml and troponin was undetectable (profile II).

This case illustrates how cardiac biomarkers may help with CV risk stratification before and during cardiotoxic cancer therapy (4). Although this patient's LVEF fully recovered at 1-year post-chemotherapy, medical optimization is an essential priority to allow the most effective cancer therapy to occur. Given the

biomarker elevation in this case, cardioprotective therapy and heightened surveillance for progressive cardiac dysfunction are recommended (1).

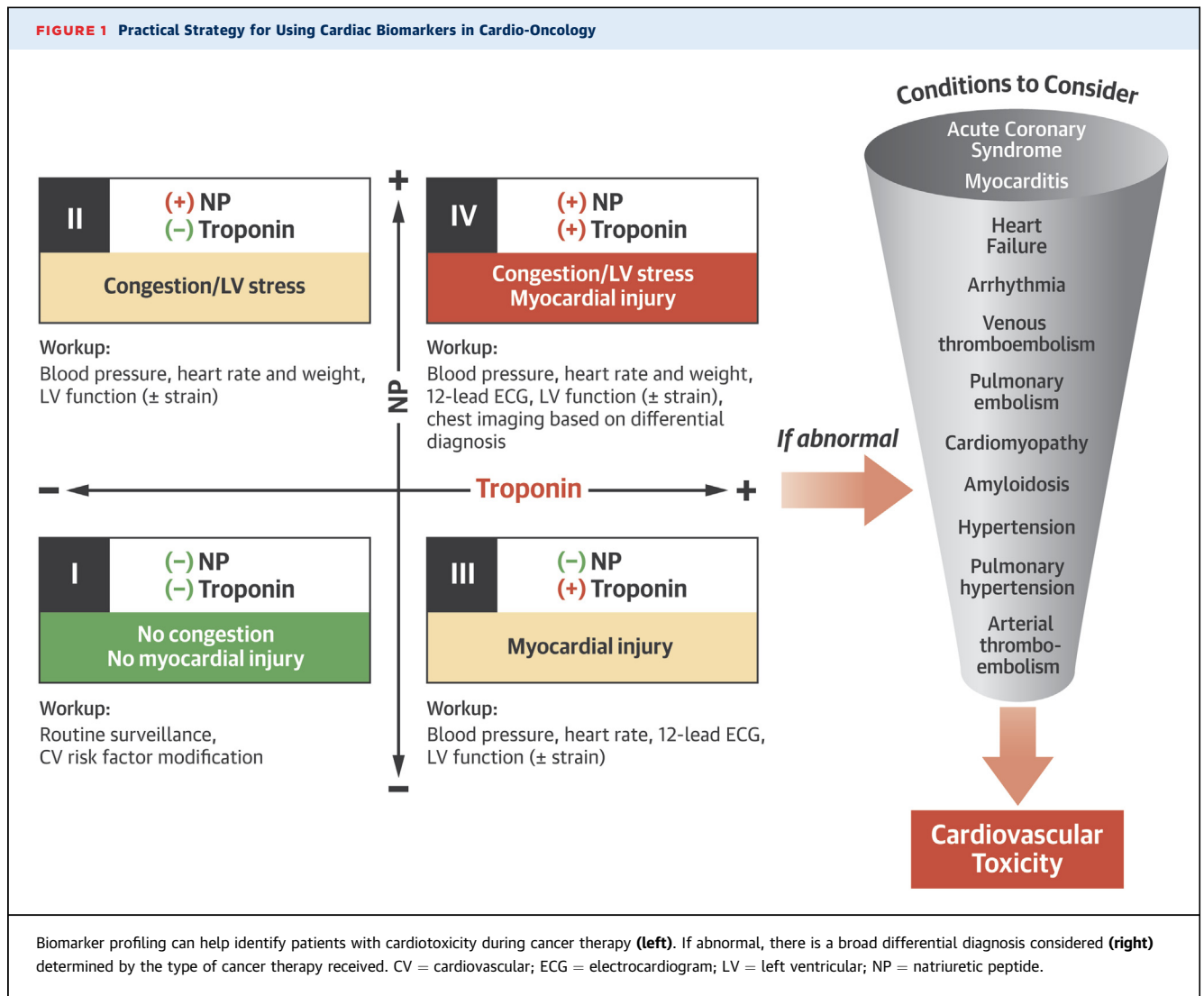
LEARNING POINTS

- Elevated pre-chemotherapy cardiac biomarkers can detect underlying myocardial injury and stress, and help with risk stratification and medical optimization before and during cancer therapy (5).
- NPs and troponin may detect congestion and injury during and after anthracycline-based cardiotoxic cancer therapy, independent of detectable changes in LVEF (6).

**CASE 2: DETECTION AND MONITORING
OF IMMUNOTHERAPY-RELATED CARDIOTOXICITY**

A 48-year-old African-American woman with stage IV lung adenocarcinoma was initially treated over a 4-year period with right lower lobe wedge resection followed by sequential carboplatin/pemetrexed and radiation therapy. She was ultimately switched to atezolizumab, a programmed cell death 1 receptor (PD-L1) inhibitor, due to suboptimal treatment response. Cardiac testing was not obtained before initiation on immunotherapy. Approximately 2 months later, she developed dyspnea and edema. TTE showed severe global hypokinesis with LVEF 28%, GLS –5%, normal right ventricular size and function, and a small-to-moderate pericardial effusion without tamponade physiology. Biomarker testing included troponin I of 0.35 ng/ml, NT-proBNP 3,863 pg/ml, and high-sensitivity C-reactive protein (hsCRP) 55.2 mg/dl (normal <3 mg/dl) (**Figure 1**) (profile IV). The ECG was unrevealing. A cmRI was not feasible, so an endomyocardial biopsy (EMBx) was performed showing focal, mild cardiomyocyte damage with mild lymphoplasmacytic inflammation consistent with myocarditis (**Figure 1**). Atezolizumab was permanently discontinued, and she was treated with methylprednisolone 1 g intravenously daily for 3 doses, followed by a slow taper of prednisone. In light of her depressed LVEF, she was started on carvedilol and sacubitril-valsartan. One month later, troponin I was undetectable, and NT-proBNP and hsCRP both decreased to 574 pg/ml and 17.7 mg/dl, respectively. cmRI at this time showed a persistently reduced LVEF at 21% and no evidence of LGE. The patient continued on guideline-directed HF therapy including spironolactone as well as prednisone with resolution of her HF symptoms. On a 6-month follow-up TTE, LVEF had increased to 37% and GLS improved to –8.5%.

Immunotherapy-related adverse events, including myocarditis, are uncommon, but potentially serious.



Although establishing the diagnosis of myocarditis frequently requires EMBx, cardiac biomarkers are usually elevated due to ongoing myocardial injury and may be supportive of the diagnosis. Achieving NT-proBNP <1,000 pg/ml on HF therapy has previously been associated with subsequent improvements in LVEF and more substantial reductions in LV volumes in patients with systolic HF (7). In the absence of permanent myocardial damage or ongoing exposure to cardiotoxic therapies, this patient's improved biomarker response to optimal HF treatment correlated with improved symptoms and an improved LVEF.

LEARNING POINTS

- Troponin and NPs have potential utility for the diagnosis of immunotherapy-related adverse events.

- NT-proBNP response to HF therapy has been shown to be prognostic of cardiac recovery.

CASE 3: PROGNOSIS IN THE TREATMENT OF CARDIOMYOPATHY

A 65-year-old man was diagnosed with HFpEF after presenting with worsening lower extremity edema and dyspnea. His NT-proBNP (1,060 pg/ml) and troponin I (0.22 ng/ml) levels were both elevated, and his ECG demonstrated low QRS voltages and a pseudoinfarct pattern (Figure 1) (profile IV). cMRI showed mild LVEF depression (47%), diffuse biventricular wall thickening, biatrial enlargement, and extensive subendocardial and transmural LGE. Serum lambda free light chain level was 8.0 mg/dl, kappa free light chain 0.64 was mg/dl, and the kappa/lambda ratio was

12.5. Bone marrow biopsy showed 20% lambda-restricted plasma cells, and an EMBx confirmed the diagnosis of AL cardiac amyloidosis. He was treated with 4 cycles of cyclophosphamide, bortezomib, and dexamethasone. Upon completion of therapy, NT-proBNP rose to 1,295 pg/ml and then decreased to 656 pg/ml 1 year later, whereas troponin T remained minimally elevated between 0.02 and 0.03 ng/ml (normal <0.01 ng/ml) (profile IV). Serum kappa and lambda free light chain levels normalized after chemotherapy. He remains on spironolactone and torsemide with stable New York Heart Association functional class II HF symptoms and relative hypotension since the original diagnosis of cardiac amyloidosis. No further chemotherapy is planned.

Cardiac biomarkers, specifically NT-proBNP and troponin T, have been incorporated into the prognostic staging system for AL amyloidosis since 2012 (8). Abnormal values in a patient with HFpEF and other suggestive clinical or cardiac imaging findings should prompt evaluation for cardiac amyloidosis (Figure 1). Although a complete hematologic response can be achieved with standard myeloma treatment, cardiac involvement may progress as evidenced by persistent cardiac biomarker elevation (9,10). In our experience, the decision to continue treatment for AL amyloidosis is based primarily on hematologic response. In this situation, we recommend periodic assessment of cardiac biomarkers, careful assessment and management of volume overload, and close collaboration with hematology/oncology to discuss the benefit of pursuing

additional myeloma treatment as well as consideration for advanced HF therapies, including transplantation, in patients with progressive HF.

LEARNING POINTS

- NT-proBNP and troponin T have diagnostic and prognostic utility in AL cardiac amyloidosis.
- The prognostic significance of persistent cardiac biomarker elevation in the setting of complete hematologic response to AL therapy requires further investigation.

CONCLUSIONS

In summary, the use of cardiac biomarkers as a tool for monitoring during cancer therapy has expanded greatly in recent years; however, there continues to be a need to establish the firm threshold for an abnormal value and the requisite action that should result from early detection of cardiac damage or stress.

AUTHOR DISCLOSURES

All authors have reported that they have no relationships relevant to the contents of this paper to disclose.

ADDRESS FOR CORRESPONDENCE: Dr. Daniel J Lenihan, Cardio-Oncology Center of Excellence, Cardiovascular Division, Washington University in St. Louis, 660 South Euclid Avenue, Campus Box 8086, St. Louis, Missouri 63110. E-mail: djlenihan@wustl.edu. Twitter: [@ICOSociety](#), [@kzhangmd](#), [@joshmitchellmd](#), [@vgzmd](#), [@fischmd](#).

REFERENCES

1. Curigliano G, Lenihan D, Fradley M, et al. Management of cardiac disease in cancer patients throughout oncological treatment: ESMO consensus recommendations. *Ann Oncol* 2020;31:171-90.
2. Cardinale D, Colombo A, Sandri MT, et al. Prevention of high-dose chemotherapy-induced cardiotoxicity in high-risk patients by angiotensin-converting enzyme inhibition. *Circulation* 2006;114:2474-81.
3. Buysse M, Sargent DJ, Grothey A, Matheson A, de Gramont A. Biomarkers and surrogate end points—the challenge of statistical validation. *Nat Rev Clin Oncol* 2010;7:309-17.
4. Armenian SH, Lacchetti C, Barac A, et al. Prevention and monitoring of cardiac dysfunction in survivors of adult cancers: American Society of Clinical Oncology Clinical Practice Guideline. *J Clin Oncol* 2017;35:893-911.
5. Cornell RF, Ky B, Weiss BM, et al. Prospective study of cardiac events during proteasome inhibitor therapy for relapsed multiple myeloma. *J Clin Oncol* 2019;37:1946-55.
6. Lenihan DJ, Stevens PL, Massey M, et al. The utility of point-of-care biomarkers to detect cardiotoxicity during anthracycline chemotherapy: a feasibility study. *J Cardiac Fail* 2016;22:433-8.
7. Daubert MA, Adams K, Yow E, et al. NT-proBNP goal achievement is associated with significant reverse remodeling and improved clinical outcomes in HFrEF. *J Am Coll Cardiol HF* 2019;7:158-68.
8. Kumar S, Dispenzieri A, Lacy MQ, et al. Revised prognostic staging system for light chain amyloidosis incorporating cardiac biomarkers and serum free light chain measurements. *J Clin Oncol* 2012;30:989-95.
9. Zhang KW, Mitchell J, Alvarez-Cardona J, et al. Plasma hepatocyte growth factor for diagnosis and prognosis in light chain and transthyretin cardiac amyloidosis. *J Am Coll Cardiol CardioOnc* 2020;2:56-66.
10. Palladini G, Dispenzieri A, Gertz MA, et al. New criteria for response to treatment in immunoglobulin light chain amyloidosis based on free light chain measurement and cardiac biomarkers: impact on survival outcomes. *J Clin Oncol* 2012;30:4541-9.

KEY WORDS amyloidosis, anthracyclines, biomarkers, cardiotoxicity, chemotherapy, detection