

Transcanal Endoscopic Ear Surgery for Cholesteatoma: Royal Belgian Society of Otorhinolaryngology

Stéphane Ayache¹ , Andrea Albera² 

¹Otorhinolaryngology - Head & Neck Surgery - Otolaryngology & Neurotology Unit Cannes Hospital Center Simone Veil, Cannes, France

²Division of Otorhinolaryngology, Department of Surgical Sciences University of Turin, Turin, Italy

Cite this article as: Ayache S, Albera A. Transcanal endoscopic ear surgery for cholesteatoma: Royal belgian society of otorhinolaryngology. B-ENT 30 December 2022 10.5152/B-ENT.2022.22946 [Epub Ahead of Print].

ABSTRACT

Objective: Surgery for cholesteatoma is traditionally based on microscopic approach. For several years, endoscopy developed from a combined approach as a complementary device to microscope to an exclusive transcanal approach in various fields of ear surgery. The objective of this article is to present principles, surgical techniques, and results of endoscopy in cholesteatoma surgery.

Methods: All principles of transcanal exclusive endoscopic ear surgery and combined approach as a complementary device to microscopy are presented. Surgical techniques are described through surgical videos and comments. Results are reported through a review of international literature.

Results: Endoscopic ear surgery in the treatment of cholesteatoma shows similar results to those of microscopic surgery according to residuals, recurrence, and hearing outcomes. Endoscopic surgery is a more complex 1-hand technique that requires time to be experienced and to have wide understanding of endoscopic ear anatomy, for dissection of anatomical space and ossicular chain, and for transcanal drilling techniques. Middle ear is the main surgical field for endoscopic ear surgery. Surgical strategy when cholesteatoma extends beyond posterior epitympanum depends on surgical experience in performing large atticotomy or microscope-assisted mastoidectomy.

Conclusion: The question is not to decide whether endoscopy must substitute microscopy. The ear surgeon must be able to choose the best-suited technique for the patient. The use of one or another technique depends on the surgeon's habits. Learning both endoscopy and microscopy allows the surgeon to adapt his surgical strategy.

Keywords: Endoscopy, microscopy, surgery, cholesteatoma, middle ear, mastoidectomy

Introduction

The main goal of cholesteatoma surgery is to eradicate the disease and to prevent the risk of residual cholesteatoma and recurrence while restoring the best possible hearing to the patient. This surgery is traditionally based on a microscopic approach through canal wall-up or canal wall-down surgical procedures. For the past few years, the endoscopic approach has undergone major improvement, based on progress in optics, instrumentation, and experience of surgeons. Introduced as a complementary device to microscopy,¹⁻⁴ endoscopy has more recently developed into an exclusive transcanal approach in various fields of ear surgery, particularly through the work of the International Working Group on Endoscopic Ear Surgery (IWGEES) created in 2008 by an international collaboration of otologist surgeons.⁵ Transcanal endoscopic approach represents the basis of this development, with specific indications,

techniques, and limits. Depending on cases and surgical practices, endoscopy can be used in addition to microscopy or constitutes the main technique (transcanal endoscopic ear surgery) sometimes assisted by microscopy (Reversed procedure).

Principles of Endoscopic Surgery for Cholesteatoma

Trans-canal endoscopic surgery is based on an evolution resulting from 3 issues.

The first difficulty was to introduce light into naturally hidden anatomical spaces. The work of Von Trötsch⁶ in 1855 opened the first way by the use of concave mirrors pierced with a hole. The second difficulty was to be able to magnify anatomical ear structures. The work leading to the creation of

Corresponding author: Stéphane Ayache, e-mail: ayachestef@orange.fr

Received: May 23, 2022 **Accepted:** October 21, 2022 **Publication Date:** December 28, 2022

Available online at www.b-ent.be



CC BY 4.0: Copyright@Author(s), "Content of this journal is licensed under a Creative Commons Attribution 4.0 International License."

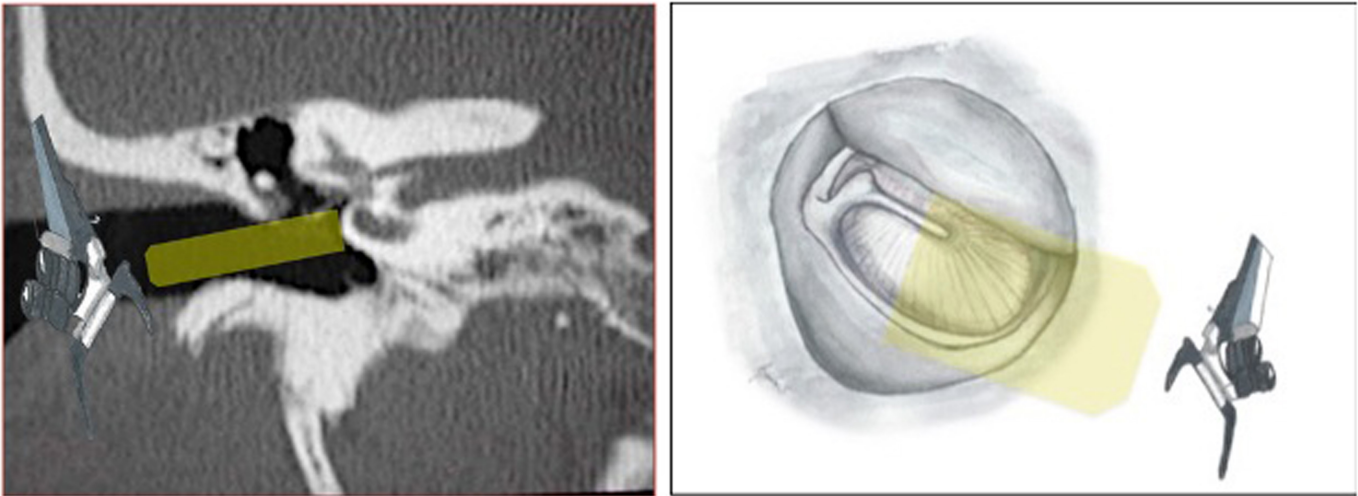


Figure 1. Straight-line microscopic view.

the operating microscope was a major turning point in ear surgery.^{7,8} A problem remained: How to reach anatomical spaces inside the ear? In spite of technical improvements concerning image quality, microscope allows only for straight-line 0° vision. Anatomical shape of external auditory canal and middle ear spaces is the limitation (Figure 1) that can limit the visualization of these spaces.^{9,10}

Total or partial scutum removal by transcanal approach opens more access to the epitympanum, where cholesteatoma typically occurs, but the microscopic field of view remains limited (Figure 2).

Retroauricular and endaural surgical approaches have been developed to overcome limited access through the external auditory canal. Association or not with antromastoid approach also requires the removal of healthy bone and tissues and, depending on the case, of the ossicular chain, opening access to the anterior epitympanum. Canal wall-down techniques are usually performed in case of difficult ear anatomy (small sclerotic mastoid, overhang of the sigmoid sinus and/or the tegmen antri and/or tegmen tympani). Retroauricular and endaural surgical approaches have been developed to overcome limited transcanal access. Combined techniques through transmastoid approach require removal of healthy bones and tissues and, depending on the case, of the ossicular chain

Main Points

- Endoscopy can be used in cholesteatoma surgery as an exclusive technique through transcanal approach or as combined technique with microscopy.
- Transcanal endoscopy provides well understanding of anatomy and ventilation pathways of the middle ear.
- Extension of cholesteatoma beyond posterior epitympanum is a key point for transcanal endoscopic approach or microscopic approach through antromastoidectomy.
- Endoscopic ear surgery in the treatment of cholesteatoma shows similar results to those of microscopic surgery according to residuals, recurrence, and hearing outcomes.
- Learning both endoscopy and microscopy allows the surgeon to adapt his surgical strategy.

opening access to the anterior epitympanum. Canal wall-down techniques can be used in case of unfavorable ear anatomy (small sclerotic mastoid, overhang of sigmoid sinus, and/or tegmen antri and/or tegmen tympani). But these techniques can expose patients to degraded living conditions (avoid any water inside the ear, otorrhea) or complications by epidermization or fistula of the lateral semicircular canal.

Visualization of retrotymppanic spaces is also limited through microscopic approach. A posterior tympanotomy certainly improves access to the facial recess but remains limited to other anatomical spaces, especially the sinus tympani.

Using a 0° endoscope in the external auditory canal provides a magnified field of view. 0° endoscope provides a better vision than microscope, because the light is coming from the tip of the endoscope, with a conical and enlarged field of view compared to the straight-line field of view provided by the microscope.

The light of the endoscope is produced from its tip. The visualization of anatomical spaces is immediately improved and extended and further improved by the use of endoscopes at 30° or 45° if necessary. This property makes this technique very suitable for transcanal approaches and for exploring the anatomical spaces of the ear (Figure 3). These techniques can, depending on the case, expose the patients to degraded living conditions (prohibition of any penetration of water into the ear, often unstable ear, and difficulties for hearing aids in the air) or complications by epidermization or even fistula of the lateral semicircular canal.

Introduction of 0° endoscope into the auditory canal offers a magnified field of view. The endoscope produces light from its tip. Visualization is immediately enlarged and can still be enhanced with the use of 30° or 45° endoscope if necessary. This characteristic makes this technique very adapted to transcanal approaches and to exploration of ear anatomical spaces (Figure 3).

The surgeon's eyes are looking at a screen and not at the operative field anymore. Any visual conflict between the surgeon's hands and eyes is therefore avoided¹¹ (Figure 4).

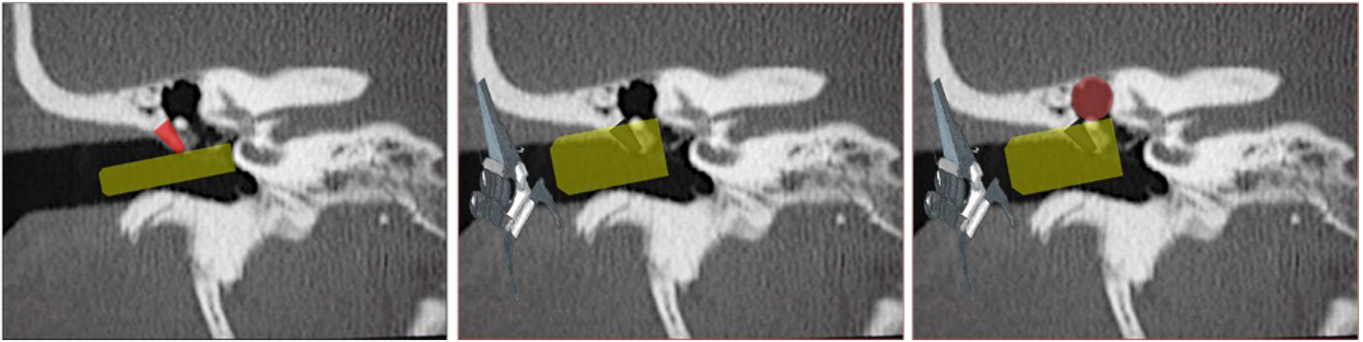

Figure 2. Microscopic transcanal approach for the epitympanum. Yellow: microscopic view, red triangle: scutum, black triangle: removed scutum, red circle: epitympanum.

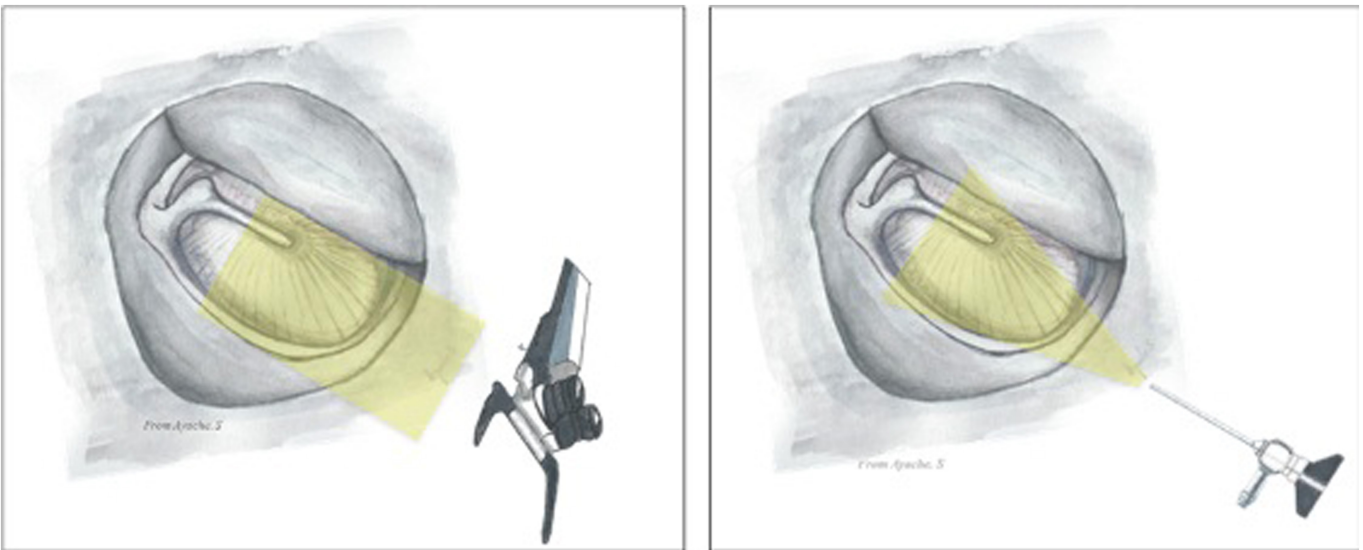


Figure 3. Comparative microscopic—endoscopic views.

These characteristics have led endoscope to be first used as an adjunct to microscope, with the aim to check anatomical spaces after cholesteatoma microscope-assisted removal.^{3,4,12-18} This approach has led to a better understanding of the ear anatomy and ventilation routes, so important in cholesteatoma surgery. With the surgeons' experience, the technique has naturally evolved toward an exclusive trans auditory canal surgical approach.

Transcanal Endoscopic Ear Surgery

This trans external auditory canal approach allows to adapt surgical strategy to the ear anatomy, to the disease and extensions, and to the middle ear ventilation routes (Figure 5).

Acquired cholesteatoma is from the tympanic membrane. Extensions in the middle ear, antrum, and mastoid follow

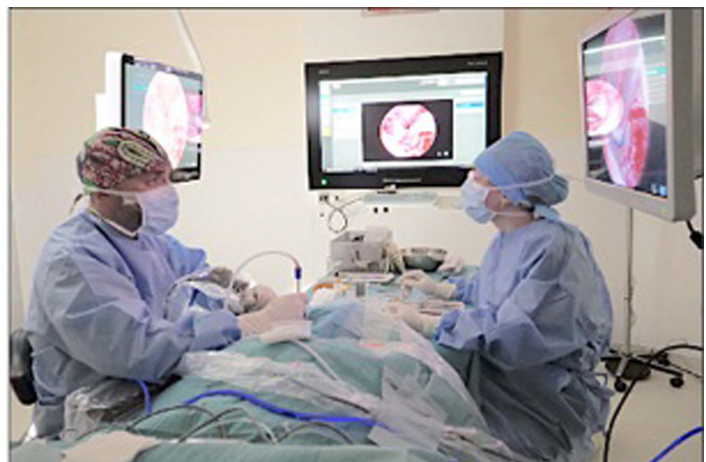
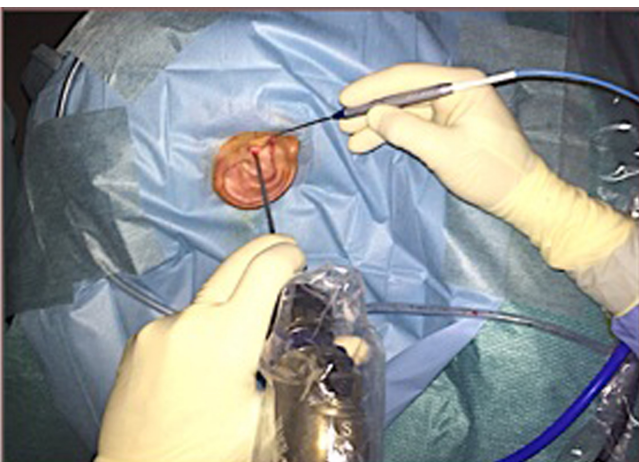


Figure 4. Relationship between endoscope, surgeon's hands, and eyes.

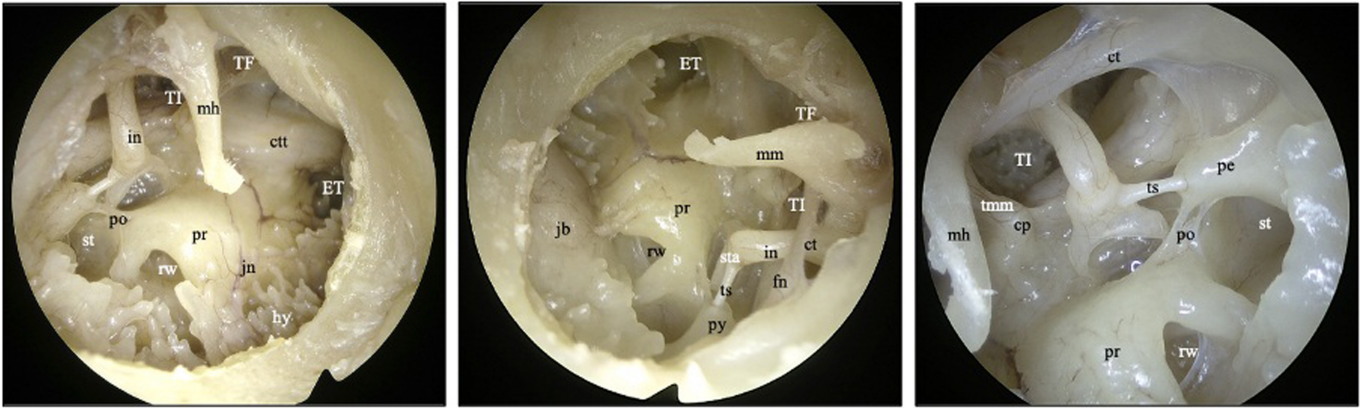


Figure 5. Endoscopic anatomy (anatomical dissection). TF, tensor fold; IT, isthme tympanique; ET, Eustachian tube; ctt, canal of the tensor tympani; ct, chorda tympani; fn, facial nerve; hy, hypotympanum; in, incus; jn, Jacobson nerve; jb, jugular bulb; mh, malleus handle; pe, pyramidal eminence; po, ponticulus; pr, promontory; rw, round window; st, sinus tympani; sta, stapes; ts, tendon of the stapes.

ventilation pathways. Transcanal endoscopy reaches directly cholesteatoma from the tympanic membrane and follows ventilation pathways from middle ear into the epitympanum, after bone removal is performed on demand and under visual control if necessary. The duration of surgery depends on each case of cholesteatoma. Duration of transcanal endoscopic surgery for limited lateral attic cholesteatoma is overall 90–120 minutes depending also on the experience of the surgeon. Duration is longer in case of extension in antrum and mastoid, requiring a combined approach with microscope, in case of extension medially to the ossicular chain, requiring an ossiculoplasty in the same time or in case of a wide removal of the scutum associated with an obliteration technique of the epitympanum. Dissection of cholesteatoma on a dehiscent facial nerve or dura with a defect of the tegmen or in case of erosion of the lateral semicircular canal will lead to a longer duration of the procedure.

Endoscopic Surgery for Epitympanic Cholesteatoma

Epitympanic cholesteatoma is the main indication of transcanal ear endoscopy.^{19–29} Anatomy of the external ear canal has to be preoperatively evaluated in all transcanal endoscopic procedures and can be classified using the preoperative Canal Endoscopy Scale classification.¹⁰ The scutum is the anatomical

limit for visualization and access to epitympanum. 0°–45° angle endoscopes can open total access to epitympanum and remove the scutum. Therefore, epitympanum is the dead end (“cul-de-sac”) of the external ear canal (Figure 6).

Tympanic isthmus and tensor fold are the ventilation routes for epitympanum and mastoid through a membranous and ligaments diaphragm that separates epitympanum and mesotympanum. Permeability of these routes has to be controlled during surgery. If needed, obstructed routes have to be opened.^{18,30}

In-office endoscopic examination and preoperative temporal bone imaging evaluate anatomy of the external auditory canal, extension of the cholesteatoma, relationship with the ossicular chain, and defect of the tegmen tympani, tegmen antri, and fallopian canal.

Cholesteatoma removal is performed from tympanic membrane and follows extension in anatomical spaces. The level of the lateral semicircular canal is usually considered as the posterior limit for a transcanal endoscopic approach (Figure 7). Beyond this limit, a combined microscopic approach with mastoidectomy is necessary. Therefore, endoscopy has a preoperative decision-making value despite preoperative temporal

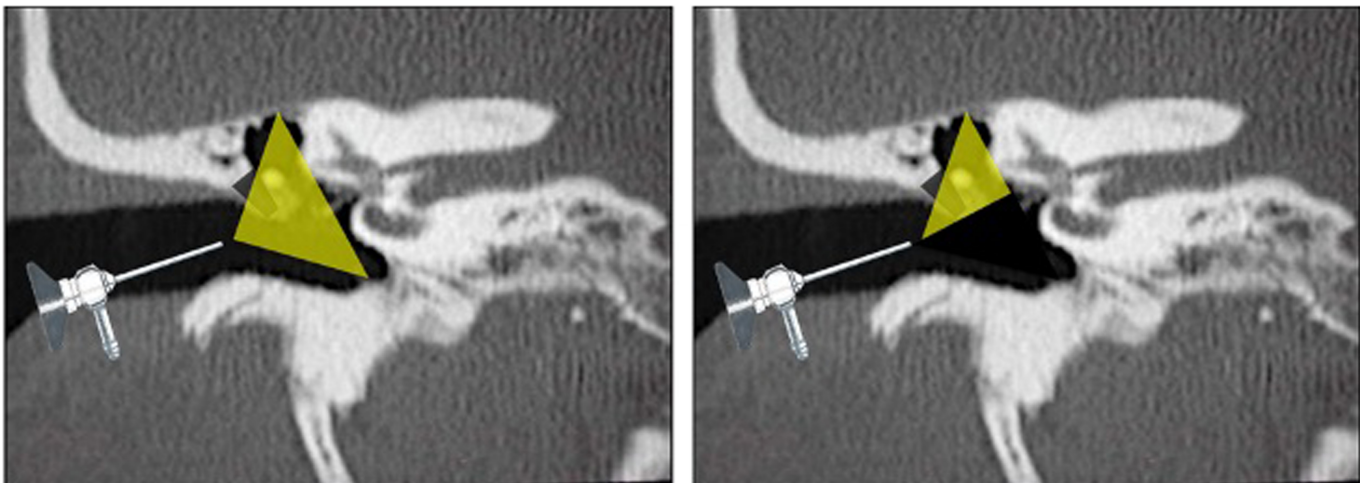


Figure 6. Transcanal endoscopic view.

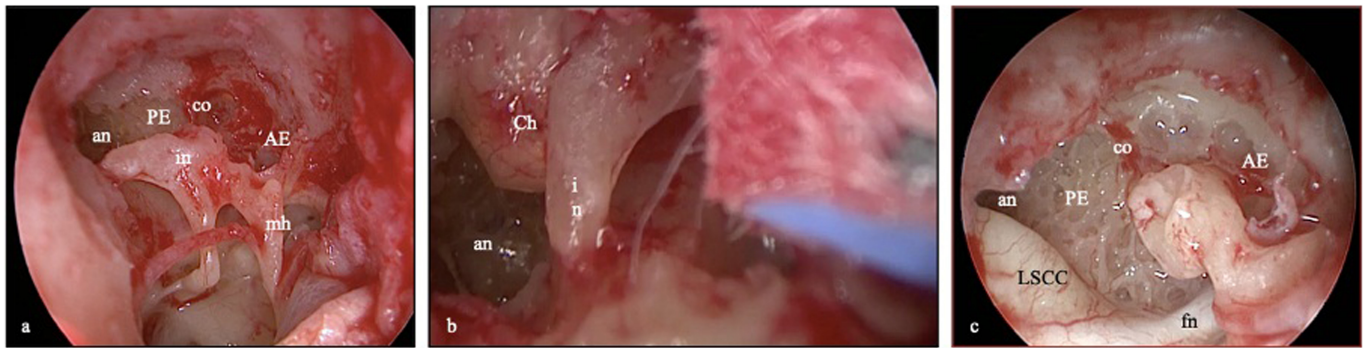


Figure 7. Anterior and posterior epitympanum. 0° endoscopy (A, C) and 45° endoscopy (B); AE, anterior epitympanum; PE, posterior epitympanum; LSCC, lateral semicircular canal; an, antrum; co, cog; Ch, cholesteatoma; fn, facial nerve; in, incus; mh, malleus handle.

bone imaging results in surgery for primary cholesteatoma (excluding surgery for residual cholesteatoma).

Video 1. Transcanal Endoscopic Ear Surgery for Epitympanic Cholesteatoma

This video illustrates a transcanal endoscopic approach for epitympanic cholesteatoma in right ear. Surgery is performed using 0°-angled, 3 mm diameter endoscope. Visualization of cholesteatoma extensions, particularly in posterior epitympanum, requires drilling of the scutum. Drilling is performed under continuous water irrigation and adapted to extension of the cholesteatoma. The ossicular chain is preserved. Checking of anatomical spaces using 45°-angled endoscope enables to exclude any residual disease. Removal of cholesteatoma including perimatrix is performed until no residual disease can be identified. Cottonoid pledgets can also be used to clean spaces where the cholesteatoma was located. Reconstruction of the scutum is performed using tragal cartilaginous and perichondrium grafts covered with perichondrium.

Decision to perform an exclusive endoscopic technique needs total visualization of posterior extension and full access to the disease using surgical instrumentation. Performing a wide atticotomy, even beyond the level of lateral semicircular canal, needs the reconstruction of the bony defect of the scutum. Bony removal can be performed using a curette, piezoelectric device, or drilling.

The reconstruction of the scutum is performed through the transcanal approach. The technique is the same as in microscopic surgery, using cartilage most of the time, very rarely using bone, depending on surgeon's habits. Some difficulties can occur in case of large atticotomy in the 1-hand endoscopic procedure. Various techniques have been suggested without reconstruction of the scutum²⁸ and with reconstruction of the scutum using 1 or several grafts,³¹ or recently through an innovative endoscopic technique of epitympanic obliteration using bioglass.³² As for ossicular chain, endoscopic dissection of facial nerve has to be performed by experienced surgeon. Lack of 3-dimensional view can make dissection difficult. Facial nerve can be evaluated through a gentle palpation using smooth instrument. Cottonoid pledgets soaked with adrenaline in contact with the facial nerve are prohibited in case of erosion of the fallopian canal.

Endoscopic Surgery for Retrotympanic Cholesteatoma

Transcanal microscopic visualization of anatomical spaces around pyramidal eminence is usually limited (Figure 5).³³ Posterior

tympanotomy allows access to the facial recess but with the risk of injury of facial nerve and limited visualization of spaces located medially to the pyramidal eminence, particularly the sinus tympani. Endoscopy allows direct access to these spaces, using 45°-angled endoscope. Depending on the surgeon's habits, exploration of the retrotympanum can be performed through a retrograde view (surgeon stays on the side of the ear, the endoscope is turned downward exposing the retrotympanum at the bottom part of the screen) or an upper view (surgeon stays on the opposite side of the ear, the endoscope is turned upward exposing the retrotympanum on top of the screen).

Video 2. Transcanal Endoscopic Ear Surgery for the Retrotympanum

This video illustrates dissection of the facial recess and sinus tympani using 45°-angled endoscope. Retrotympanic spaces are well visualized. Microscope-assisted posterior tympanotomy usually provides visualization of facial recess. Visualization of the sinus tympani located medially and above the pyramidal eminence is difficult through microscopic view. The second case illustrates 45° endoscopic view of the stapes footplate and pyramidal eminence during the dissection of tympanic retraction pocket.

Microscope-Assisted Transcanal Endoscopic Ear Surgery

This is a reversed approach to the well-known combined technique using endoscopy as a complementary device to microscopy. Transcanal endoscopic cholesteatoma removal using 0° and 45° endoscopes is performed up to the limits of visualization and access to extensions of the cholesteatoma. Beyond these limits, microscope allows a surgical work using 2 hands usually through a transmastoid approach.

Main indication for the reversed procedure is extension of epitympanic cholesteatoma into antrum with the aim to preserve the posterior canal wall, with or without bulging of the tegmen antri or dura or defect of lateral semicircular canal. In the series of Killeen et al³⁴, all patients who required transmastoid microscope-assisted approach had a cholesteatoma extended beyond limits of the epitympanum. Mastoidectomy is performed to identify posterior cholesteatoma extension and to remove the disease using 0° and 45° endoscopes.

Various surgical techniques are reported in the literature using drilling and removal of the posterior canal wall^{25,35} and modified

Table 1. Recidivism After Transcanal Endoscopic Ear Surgery

Authors	Location of Cholesteatoma	Number of Patients	Follow-Up (Months)	Recurrence Rate	Residual Rate
Bae et al ²⁰	Epitympanum	10	19.75	0	0
Magliulo et al ²³	Epitympanum	40	12.3	0	/
Imai et al ²⁵	Epitympanum	25	14	0	12%
Tarabichi et al ²⁶	Epitympanum, mésotympanum, protympanum and rétrotympa-num	158	37.5	3.2%	3.2%
Marchioni et al ²⁷	Epitympanum	23	18	8.7%	4.3%
Marchioni et al ²⁸	Epitympanum with antral extension	12	15	8.3%	8.3%
Marchioni et al ²⁹	Epitympanum	21	23	0	0
Killeen et al ³⁴	Epitympanum with or without mastoid extension	50	18	18%	17%
Alicandri-Ciufelli et al ³⁹	Epitympanum	244	63.3	12%	20%
Glikson et al ⁴⁰	Epitympanum, mésotympanum and rétrotympa-num	60	35	8.3%	10%
Presutti et al ¹⁴	Epitympanum, Mésotympanum and rétrotympa-num	517	23.4	3.1%	6.2%

canal wall down technique³¹ or using limited approach allowing introduction of the endoscope through the antrum.³⁶ Obliteration technique of the epitympanum allows to push limits of drilling of the scutum beyond the posterior epitympanum by facilitating the reconstruction procedure of the scutum without risk of grafts tipping intraoperatively over in an empty epitympanum.³²

Video 3. Transcanal Endoscopic Ear Surgery for Epitympanic Cholesteatoma (the Posterior Extension)

This video illustrates a transcanal endoscopic approach through 2 cases of epitympanic cholesteatoma. In case 1 (right ear), posterior limit of cholesteatoma is identified using 0° and 45° endoscope. There is no cholesteatoma extension to the medial part of the ossicular chain but destruction of the head of the malleus by the cholesteatoma. Ventilation routes (tympanic isthmus and tensor fold) are checked. Reconstruction of the scutum is performed using tragal cartilage grafts covered with perichondrium. Case 2 (right ear) illustrates extension of cholesteatoma to the posterior epitympanum beyond limit of the aditus ad antrum (30° endoscope). Mastoidectomy identifies extension into the mastoid and allows removal of the disease. Checking of cavities is performed using 0° endoscope.

Results of Endoscopic Ear Surgery

Recidivism (Residual and Recurrence)

Rates of residuals have to be analyzed differently depending on whether they are identified endoscopically during the primary surgery with or without mastoidectomy or during the secondary surgery. In primary surgery, endoscopy allows identification and removal of preoperative residuals, especially when cholesteatoma is located in sinus tympani, facial recess, or anterior epitympanum.^{3,4,37} Sajjadi³⁷ reports in a retrospective study a preoperative residual rate of 22%, decreasing the residual rate identified during the second surgery to 9.7% after a follow-up of 2 years. Yung³⁸ reports residual rates of 9.4% and 8.7% after using endoscope as a complementary device to microscope,

after mastoidectomy during canal wall up and canal wall down procedures, respectively. Studies about exclusive endoscopic results are limited. Table 1 shows results after transcanal endoscopic ear surgery.

During microscopic procedures, residual rates after canal wall-up mastoidectomy are reported between 10% and 43%.^{41,42} Recurrence rate is between 16% and 61% when a canal wall up is performed and between 0% and 13% with a canal wall down mastoidectomy.^{40,43,44}

Series including exclusive microscopic and endoscopic approach would be necessary for a better study of results. Such studies are difficult to perform because endoscopy is often combined with microscopy in cholesteatoma surgery.^{23,45} Only a few studies report results about recurrence after endoscopic ear surgery. Recurrence is secondary to a new retraction of tympanic membrane when there was no cartilaginous reconstruction of the scutum during primary surgery or when the reconstruction was not adapted to the extent of bone removal of the scutum

Killeen et al³⁴ compared results between 2 groups of patients in endoscopic or microscopic approach for 18 months and 50 months, respectively. No significant difference was identified (residual rate of 17% in each group). Recurrence rate was 18% (endoscopy group) and 20% (microscopy group).

In a randomized study comparing endoscopic and microscopic surgery for attic cholesteatoma without extension into mastoid, Magliulo and Iannella²³ did not report any recidivism between the 2 groups after an average follow-up of 12.3 months. The results in terms of recidivism are not reported.

As the endoscopic techniques are more recent, it is also possible that the results are biased due to a difference in follow-up after surgery.

Hearing Results

Besides the prevention of residual and recurrent disease, purpose of surgical management of cholesteatoma is to preserve or restore hearing. Average rate of total conservation of the ossicular chain is depending on series including cholesteatoma limited to epitympanum^{18,20,22,25,27-29,44,45} or into antrum.²⁶ An ossiculoplasty was performed during the same operating time as the cholesteatoma removal in 20%-100% of cases.^{19,20,22,25,26,28,29,45,46} In 2 studies, an ossiculoplasty was performed 1 year after primary surgery, bringing the rates of secondary ossiculoplasty to 15.5%.^{25,26}

Due to the lack of consensus about evaluation time of post-operative hearing results (average time: 6 months), comparison between series is difficult. Five series report hearing results with a pre and postoperative air-bone gap (ABG) of 24.6 dB and 13.9 dB, respectively.^{20,22,23,25,29} Killeen et al³⁴ do not report any significant difference between postoperative ABG after endoscopic surgery (5 dB) versus microscopic surgery (3.75 dB).³⁴

Complications

Complications of endoscopic ear surgery are diversely reported in international literature. Table 2 reports complication rates in some studies. In the study by Magliulo and Iannella,²³ a transient abnormal taste sensation occurred in 30% and 40% of the endoscopic and microscopic groups, respectively. There was no significant statistical difference between the 2 groups. Killeen et al³⁴ reported incidence of taste disturbance in 6% and 8.6% in series of endoscopic and microscopic procedures, respectively, without more information about incidence of recovery over the time.

Conclusion

Endoscopic ear surgery in the treatment of cholesteatoma shows similar results to those of microscopic surgery according

to residuals, recurrence, and hearing outcomes. Endoscopic surgery is a more complex 1-hand technique that requires time to be experienced and to have wide understanding of endoscopic ear anatomy, for dissection of anatomical space and ossicular chain and for transcanal drilling techniques. Middle ear is the main surgical field for endoscopic ear surgery. Surgical strategy when cholesteatoma extends beyond posterior epitympanum depends on surgical experience in performing large atticotomy or microscope-assisted mastoidectomy. The question is not to decide whether endoscopy must substitute microscopy. The ear surgeon must be able to choose the best-suited technique for the patient. The use of one or another technique depends on the surgeon's habits. Learning both endoscopy and microscopy allows the surgeon to adapt his surgical strategy.

Peer-review: Externally peer-reviewed.

Author Contributions: Concept – A.S., A.A.; Design –A.S., A.A.; Supervision –A.S., A.A.; Materials – A.S., A.A.; Data Collection and/or Processing –A.S., A.A.; Analysis and/or Interpretation –A.S., A.A.; Literature Review – A.S., A.A.; Writing –A.S., A.A.; Critical Review – A.S., A.A.

Declaration of Interests: The authors declare that they have no competing interest.

Funding: The authors declare that this study had received no financial support.

Video 1: Transcanal endoscopic ear surgery for epitympanic cholesteatoma

Video 2: Transcanal endoscopic ear surgery for the retrotymppanum

Video 3: Transcanal endoscopic ear surgery for epitympanic cholesteatoma (the posterior extension).

References

- Rosenberg SI, Silverstein H, Willcox TO, Gordon MA. Endoscopy in otology and neurotology. *Am J Otol.* 1994;15(2):168-172. [CrossRef]
- Thomassin JM, Duchon-Doris JM, Emram B, Rud C, Conciatori J, Vilcoq P. Endoscopic ear surgery. Initial evaluation. *Ann Otolaryngol Chir Cervicofac.* 1990;107(8):564-570.
- Ayache S, Tramier B, Strunski V. Otoendoscopy in cholesteatoma surgery of the middle ear: what benefits can be expected? *Otol Neurotol.* 2008;29(8):1085-1090. [CrossRef]
- Badr-El-Dine M. Value of ear endoscopy in cholesteatoma surgery. *Otol Neurotol.* 2002;23(5):631-635. [CrossRef]
- Ayache S. Endoscopy of the middle ear. *Rev Prat.* 2010;60(10):1345-1348.
- Von Tröltzsch AF. *Traité pratique des maladies de l'oreille.* A. Kuhn and D. M. Levi (Translation from German on the 4th edition (1868)). Paris: Delahaye, Strasbourg, Derivaux, Noiriol, Treuttel et Wurtz, A. Simon. 1870.
- Hölmgren G. Operations on the temporal bone carried out with the help of the lens and the microscope. *Acta Oto-Laryngol.* 1922;4(1):383-393. [CrossRef]
- Legent F. F. Maurice Sourdille and the operating microscope. *Ann Otolaryngol Chir Cervicofac.* 2000;117(4):210-214.
- Ayache S, Beltran M, Guevara N. Anatomy of the external auditory canal. Comparative study of microscope versus endoscope. European review of ENT. *Rev Laryngol Otol Rhinol.* 2017;138:93-98.
- Ayache S, Beltran M, Guevara N. Endoscopic classification of the external auditory canal for transcanal endoscopic ear surgery. *Eur*

Table 2. Complications of Endoscopic Ear Surgery

Authors	Complications	Rates
Magliulo et al ²³ Killeen et al ³⁴	Taste disturbance	30% (vs. 40% microscopy 6% (vs. 8.6% microscopy)
Marchioni et al ²⁹	Intraoperative excessive bleeding	14.3%
Tarabichi et al ²⁶	Failed ossicular chain reconstruction	5.1%
Marchioni et al ²⁸	Persistent otorrhea	8.3%
Imai et al ²⁵	Persistent otorrhea	4%
Magliulo et al ²³	Dizziness	5%
Killeen et al ³⁴	Residual tympanic membrane perforation	10% (vs. 8.6% micro)
Killeen et al ³⁴	External ear canal stenosis	6% (vs. 2.9% micro)
Killeen et al ³⁴	Tragal hematoma	2%
Killeen et al ³⁴	Facial weakness	2%

- Ann Otorhinolaryngol Head Neck Dis.* 2019;136(4):247-250. [\[CrossRef\]](#)
11. Ayache S. L'otoendoscopie dans la chirurgie de l'oreille moyenne. Une technique complémentaire et exclusive. *Orl Pneumo Allergo Prat.* 2009 ;228 :1-3.
 12. Thomassin JM, Korchia D, Doris JM. Endoscopic-guided otosurgery in the prevention of residual cholesteatomas. *Laryngoscope.* 1993;103(8):939-943. [\[CrossRef\]](#)
 13. Good GM, Isaacson G. Otoendoscopy for improved pediatric cholesteatoma removal. *Ann Otol Rhinol Laryngol.* 1999;108(9):893-896. [\[CrossRef\]](#)
 14. Presutti L, Gioacchini FM, Alicandri-Ciuffelli M, Villari D, Marchioni D. Results of endoscopic middle ear surgery for cholesteatoma treatment: a systematic review. *Acta Otorhinolaryngol Ital.* 2014;34(3):153-157.
 15. Thomassin JM, Korchia D, Duchon-Doris JM. Residual cholesteatoma: its prevention by surgery with endoscopic guidance. *Rev Laryngol Otol Rhinol (Bord).* 1991;112(5):405-408.
 16. Rosenberg SI, Silverstein H, Hoffer M, Nichols M. Use of endoscopes for chronic ear surgery in children. *Arch Otolaryngol Head Neck Surg.* 1995;121(8):870-872. [\[CrossRef\]](#)
 17. Presutti L, Marchioni D, Mattioli F, Villari D, Alicandri-Ciuffelli M. Endoscopic management of acquired cholesteatoma: our experience. *J Otolaryngol Head Neck Surg.* 2008;37(4):481-487.
 18. Marchioni D, Alicandri-Ciuffelli M, Molteni G, Artioli FL, Genovese E, Presutti L. Selective epitympanic dysventilation syndrome. *Laryngoscope.* 2010;120(5):1028-1033. [\[CrossRef\]](#)
 19. Chen CK, Hsieh LC, Hsu TH. Novel three-dimensional image system for endoscopic ear surgery. *Eur Arch Otorhinolaryngol.* 2018;275(12):2933-2939. [\[CrossRef\]](#)
 20. Bae MR, Kang WS, Chung JW. Comparison of the clinical results of attic cholesteatoma treatment: endoscopic versus microscopic ear surgery. *Clin Exp Otorhinolaryngol.* 2019;12(2):156-162. [\[CrossRef\]](#)
 21. Kakehata S, Furukawa T, Ito T, Kubota T, Futai K, Watanabe T. Comparison of postoperative pain in patients following transcanal endoscopic versus microscopic ear surgery. *Otol Neurotol.* 2018;39(7):847-853. [\[CrossRef\]](#)
 22. Nandyal CB, Suttrave M, Kurlle V, Harsoor PA. Mrmc Neo surgical ventilating port and Neo attic malleo-incudal complex in endoscopic management of limited attico-antral cholesteatoma. *Indian J Otolaryngol Head Neck Surg.* 2018;70(1):33-37. [\[CrossRef\]](#)
 23. Magliulo G, Iannella G. Endoscopic versus microscopic approach in attic cholesteatoma surgery. *Am J Otolaryngol.* 2018;39(1):25-30. [\[CrossRef\]](#)
 24. Patel N, Mohammadi A, Jufas N. Direct cost comparison of totally endoscopic versus open ear surgery. *J Laryngol Otol.* 2018;132(2):122-128. [\[CrossRef\]](#)
 25. Imai T, Nishiike S, Oshima K, Tanaka H, Tsuruta Y, Tomiyama Y. The resected area of the posterior wall of the external auditory canal during transcanal endoscopic ear surgery for cholesteatoma. *Auris Nasus Larynx.* 2017;44(2):141-146. [\[CrossRef\]](#)
 26. Tarabichi M, Nogueira JF, Marchioni D, Presutti L, Pothier DD, Ayache S. Transcanal endoscopic management of cholesteatoma. *Otolaryngol Clin North Am.* 2013;46(2):107-130. [\[CrossRef\]](#)
 27. Marchioni D, Alicandri-Ciuffelli M, Molteni G, Villari D, Monzani D, Presutti L. Ossicular chain preservation after exclusive endoscopic transcanal tympanoplasty: preliminary experience. *Otol Neurotol.* 2011;32(4):626-631. [\[CrossRef\]](#)
 28. Marchioni D, Villari D, Alicandri-Ciuffelli M, Piccinini A, Presutti L. Endoscopic open technique in patients with middle ear cholesteatoma. *Eur Arch Otorhinolaryngol.* 2011;268(11):1557-1563. [\[CrossRef\]](#)
 29. Marchioni D, Mattioli F, Alicandri-Ciuffelli M, Presutti L. Endoscopic approach to tensor fold in patients with attic cholesteatoma. *Acta Otolaryngol (Stockh).* 2009;129(9):946-954. [\[CrossRef\]](#)
 30. Marchioni D, Alicandri-Ciuffelli M, Molteni G, Genovese E, Presutti L. Endoscopic tympanoplasty in patients with attic retraction pockets. *Laryngoscope.* 2010;120(9):1847-1855. [\[CrossRef\]](#)
 31. Sajjadi H. Endoscopic transcanal modified canal-wall-down mastoidectomy for cholesteatoma. *World J Otorhinolaryngol Head Neck Surg.* 2017;3(3):153-159. [\[CrossRef\]](#)
 32. Ayache S. Transcanal endoscopic ear surgery for cholesteatoma with epitympanic obliteration by bioglass. *Laryngoscope.* 2022;132(2):433-435. [\[CrossRef\]](#)
 33. Abdel Baki F, El Dine MB, El Saïid I, Bakry M. Sinus tympani endoscopic anatomy. *Otolaryngol Head Neck Surg.* 2002;127(3):158-162. [\[CrossRef\]](#)
 34. Killeen DE, Tolisano AM, Kou YF, Kutz JW, Isaacson B. Recidivism after endoscopic treatment of cholesteatoma. *Otol Neurotol.* 2019;40(10):1313-1321. [\[CrossRef\]](#)
 35. Kakehata S, Watanabe T, Ito T, Kubota T, Furukawa T. Extension of indications for transcanal endoscopic ear surgery using an ultrasonic bone curette for cholesteatomas. *Otol Neurotol.* 2014;35(1):101-107. [\[CrossRef\]](#)
 36. Wu N, Wang F, Hou Z, Yang S. Improvement of otoendoscopic surgery for epitympanic cholesteatoma invading the mastoid. *Acta Otolaryngol.* 2019;139(6):492-496. [\[CrossRef\]](#)
 37. Sajjadi H. Endoscopic middle ear and mastoid surgery for cholesteatoma. *Iran J Otorhinolaryngol.* 2013 ;25(71):63-70.
 38. Yung MW. The use of middle ear endoscopy: has residual cholesteatoma been eliminated? *J Laryngol Otol.* 2001;115(12):958-961. [\[CrossRef\]](#)
 39. Wilson KF, Hoggan RN, Shelton C. Tympanoplasty with intact canal wall mastoidectomy for cholesteatoma: long-term surgical outcomes. *Otolaryngol Head Neck Surg.* 2013;149(2):292-295. [\[CrossRef\]](#)
 40. Hunter JB, Zuniga MG, Sweeney AD, et al. Pediatric endoscopic cholesteatoma surgery. *Otolaryngol Head Neck Surg.* 2016 ;154(6):1121-1127. [\[CrossRef\]](#)
 41. Presutti L, Anschuetz L, Rubini A, et al. The impact of the transcanal endoscopic approach and mastoid preservation on recurrence of primary acquired attic cholesteatoma. *Otol Neurotol.* 2018;39(4):445-450. [\[CrossRef\]](#)
 42. Kerckhoffs KG, Kommer MB, van Strien TH, et al. The disease recurrence rate after the canal wall up or canal wall down technique in adults. *Laryngoscope.* 2016 ;126(4):980-987. [\[CrossRef\]](#)
 43. Panetti G, Cavaliere M, Panetti M, Marino A, Iemma M. Endoscopic tympanoplasty in the treatment of chronic otitis media: our experience. *Acta Otolaryngol.* 2017;137(3):225-228. [\[CrossRef\]](#)
 44. Tarabichi M. Endoscopic management of limited attic cholesteatoma. *Laryngoscope.* 2004 ;114(7):1157-1162. [\[CrossRef\]](#)
 45. Marchioni D, Villari D, Mattioli F, Alicandri-Ciuffelli M, Piccinini A, Presutti L. Endoscopic management of attic cholesteatoma: a single-institution experience. *Otolaryngol Clin N Am.* 2013 ;46(2):201-209. [\[CrossRef\]](#)
 46. Migirov L, Shapira Y, Horowitz Z, Wolf M. Exclusive endoscopic ear surgery for acquired cholesteatoma: preliminary results. *Otol Neurotol.* 2011;32(3):433-436. [\[CrossRef\]](#)