



OPEN ACCESS

¹Imperial College London, London, UK

²NIHR Health Protection Research Unit in Healthcare Associated Infection and Antimicrobial Resistance, Imperial College London, London, UK

³Clinical Infection Department, Chelsea and Westminster Healthcare NHS Trust, London, UK

⁴Department of Rheumatology, Chelsea and Westminster Healthcare NHS Trust, London, UK

⁵MRC Centre for Molecular Bacteriology and Infection, Imperial College London, London, UK

⁶Respiratory and Intensive Care Medicine, Chelsea and Westminster Hospital NHS Foundation Trust, London, UK

Correspondence to

Prof Suveer Singh, Respiratory and Intensive Care Medicine, Chelsea and Westminster Hospital NHS Foundation Trust, London, London, UK; suveer.singh@imperial.ac.uk

Received 19 October 2021

Accepted 28 July 2022

Published Online First

29 September 2022

Novel inhaled antifungal for pseudomembranous *Aspergillus* tracheobronchitis complicating connective tissue disease

Shivani Singh ,¹ Luke S P Moore ,^{1,2,3} Nabeela Mughal,^{1,3} Matthew Ho,^{1,4} Darius Armstrong-James,^{1,5} Suveer Singh ^{1,6}

A 30-year-old woman was admitted with fever, lethargy, diarrhoeal illness, arthromyalgia, rash and weight loss over a few weeks. Laboratory results showed pancytopenia (neutrophils 0.4×10^9 , Hb 80, Plt 82), LDH 2500, creatine kinase 2800, ferritin >17 000, ESR >50, positive anti-dsDNA, anti-Ro, anti-La and low serum complement (C3 and C4). Systemic lupus erythematosus and concomitant haemophagocytic lymphohistiocytosis (HLH) were diagnosed. Initial induction therapy included high-dose methylprednisolone, cyclophosphamide, rituximab and anakinra (IL-1 receptor inhibitor) for HLH.

She subsequently developed type 1 respiratory failure and confusion, requiring mechanical ventilation. MRI of the brain was normal. CT chest

revealed dense patchy multilobar consolidation. Broad-spectrum empirical antibacterials, antifungals (anidulafungin then liposomal amphotericin) and ganciclovir were commenced.

Extubation after 2 weeks proceeded to reintubation 3 days later due to increased work of breathing. Thoracic CT demonstrated persisting parenchymal infiltration, without pulmonary embolism—not fully explaining the deterioration. Diagnostic bronchoscopy revealed a confluent white layer covering the tracheobronchial tree (figure 1A), with underlying mucosal erythema and ulceration (figure 1B). Pseudomembranous, ulcerative *Aspergillus* tracheobronchitis (ATB) was diagnosed clinically and confirmed by microscopy of bronchial specimens revealing branching filamentous hyphae. Culture

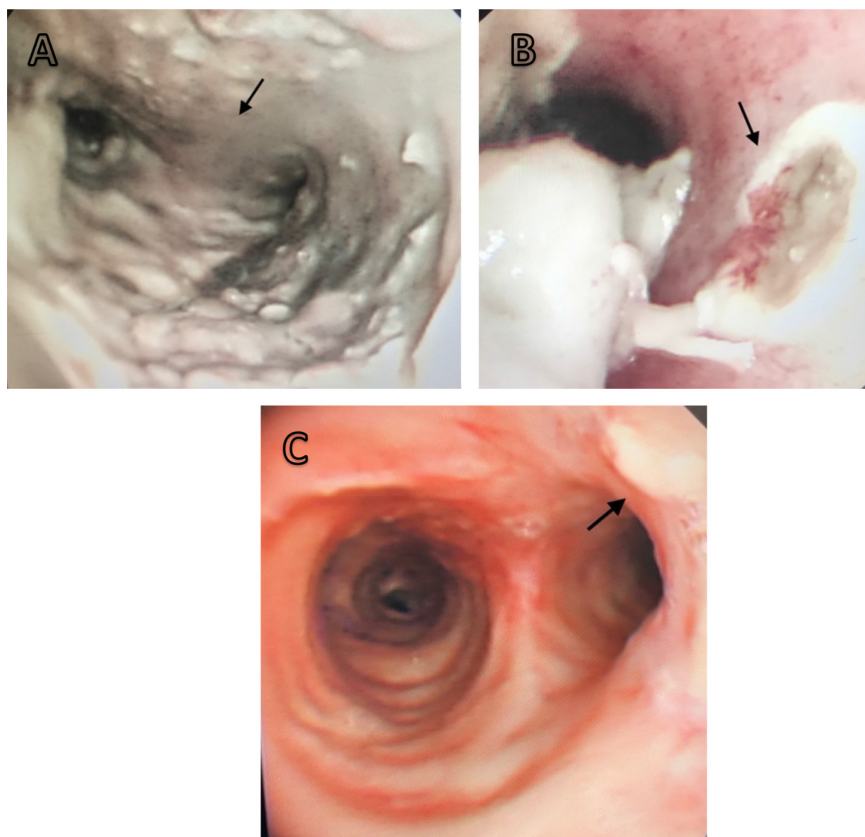
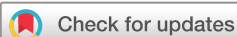

Figure 1 (A) Bronchoscopic image of distal trachea at the level of the main carina revealed a confluent white monolayer covering the tracheobronchial tree. Arrow indicating the posterior wall of the distal trachea. (B) After removal of the overlying white pseudomembrane, a mucosal ulcer was uncovered (arrow). Scrapings revealed branching hyphae, confirmed as *Aspergillus fumigatus* on culture. (C) Three weeks after commencement of the adjunctive novel nebulised triazole, PC945, bronchoscopy revealed clearing of the pseudomembrane, improving mucosal integrity and a healing mucosal ulcer (arrow).



© Author(s) (or their employer(s)) 2023. Re-use permitted under CC BY-NC. No commercial re-use. See rights and permissions. Published by BMJ.

To cite: Singh S, Moore LSP, Mughal N, et al. *Thorax* 2023;**78**:110–111.



yielded *Aspergillus fumigatus*. Serum beta-D-glucan (BDG) was highly raised and bronchoalveolar galactomannan (GM) index was >2, indicative of invasive pulmonary aspergillosis (IPA).

Failure of clinicobronchoscopic response to 5 weeks of escalating antifungal combinations including anidulafungin (before diagnosing IPA), liposomal amphotericin (intravenous and inhaled), voriconazole (limited by abnormal liver function) and isavuconazole (limited by a rash), necessitated a 6-week course of the novel nebulised triazole antifungal agent PC945 or opelconazole (Pulmocide). This has been used as salvage therapy in lung transplant patients with IPA.¹ Improvement with extubation occurred over 2 weeks. Repeat bronchoscopy 3 weeks after commencing PC945 demonstrated significant clearing of the pseudomembranes with improving mucosal integrity (figure 1C). At discharge, GM, BDG and inflammatory markers were normal. She was maintained on mycophenolate mofetil, co-trimoxazole and itraconazole. Repeat bronchoscopy at 12 months showed normal endobronchial mucosa. She remains clinically well.

ATB is an unusual, life-threatening manifestation of IPA—confined predominantly to the tracheobronchial tree.² It is classified bronchoscopically into pseudomembranous, ulcerative and obstructive forms with pathology demonstrating aspergillus hyphae invading mucosa. Predisposing conditions are those associated with severe immunosuppression.

Mortality associated with ATB is high,² likely a combination of late diagnosis and limitations of current systemic antifungal therapy—treatment-limiting side effects occur at high systemic concentrations that are often subtherapeutic in the lung or airway.

PC945, purpose-designed for inhaled administration, acts by inhibiting 14 α -demethylase, depleting ergosterol in fungal membranes, thus disrupting fungal growth.⁴ It shows potent activity against *Aspergillus* spp and *Candida* spp in vitro and is synergistic with other antifungals.³ In vivo, it maintains high concentrations in the lung with low systemic exposure, a good tolerability profile and no local irritancy.³ Here, a lack of clinical response to the local manifestation of the infection, and high toxicity associated with multiple systemic antifungal agents

necessitated the use of PC945 under the MHRA special licence as salvage therapy.

Twitter Luke S P Moore @dr_luke_moore and Suveer Singh @respitudo

Acknowledgements The patient and her family, Dr Andrew Godfrey, Dr Kinnesh Othman, Dr Louise Fearfield, Dr Alison Murray, the nursing, medical and allied health professional staff at the Intensive Care Unit, Chelsea and Westminster Hospital, London, UK.

Contributors SuS conceived the idea for the manuscript. ShS and SuS wrote the first draft. SuS, NM, LSPM and MH were involved in the clinical management of the patient. DA-J was a specialist clinical advisor in the case, and provided the PC945 through the company, Pulmocide. All authors reviewed, revised and accepted the final manuscript and provided consent for publication.

Funding The authors have not declared a specific grant for this research from any funding agency in the public, commercial or not-for-profit sectors.

Competing interests LSPM has consulted for/received speaker fees from bioMerieux (2013-2022), Eumedica (2016-2022), Pfizer (2018-2022), Umovis Lab (2020-2021), Profile Pharma (2018), Shionogi (2020-2022), Kent Pharma (2021), Sumitovant (2021-2022), DNAelectronics (2015-18), Dairy Crest (2017-2018), and received research grants from the National Institute for Health Research (2013-2019), CW+ Charity (2018-2022), LifeArc (2020-2022) and Leo Pharma (2016).

Patient consent for publication Consent obtained directly from patient(s).

Provenance and peer review Not commissioned; externally peer reviewed.

Open access This is an open access article distributed in accordance with the Creative Commons Attribution Non Commercial (CC BY-NC 4.0) license, which permits others to distribute, remix, adapt, build upon this work non-commercially, and license their derivative works on different terms, provided the original work is properly cited, appropriate credit is given, any changes made indicated, and the use is non-commercial. See: <http://creativecommons.org/licenses/by-nc/4.0/>.

ORCID iDs

Shivani Singh <http://orcid.org/0000-0002-7054-1414>

Luke S P Moore <http://orcid.org/0000-0001-7095-7922>

Suveer Singh <http://orcid.org/0000-0003-3219-8966>

REFERENCES

- Murray A, Cass L, Ito K, et al. PC945, a novel inhaled antifungal agent, for the treatment of respiratory fungal infections. *J Fungi* 2020;6:373.
- Fernández-Ruiz M, Silva JT, San-Juan R, et al. Aspergillus tracheobronchitis: report of 8 cases and review of the literature. *Medicine* 2012;91:261–73.
- Cass L, Murray A, Davis A, et al. Safety and nonclinical and clinical pharmacokinetics of PC945, a novel inhaled triazole antifungal agent. *Pharmacol Res Perspect* 2021;9:e00690.