

A Comparison of Outcomes between Finger and Pulp Replantation/Revascularization in a Single Center

Kwaku Duah-Asante, BSc (Hons)*

Murtaza Kadhum, MRCS†

Ankur Khajuria, MRCS, MSc

(Oxon), PhD*‡

Charles Nduka, FRCS†

Isao Koshima, MD, PhD‡

Ruben Y. Kannan, FRCS, PhD†

Background: Supermicrosurgery has allowed the replantation/revascularization of the pulp, but how does this currently compare with more proximal digit replantation/revascularization?

Methods: In a retrospective case study over a 5-year period at our institute, a total of 21 patients (n = 21) had either finger or pulp replantation-revascularization posttrauma. All pulp replants had a single-vessel anastomosis viz., “artery-to-artery” or “artery-to-vein” only, with venous outflow dependent on the skin-shave technique, while more proximal replants had both arterial and venous anastomoses. Age, sex, ischemic time, handedness, smoker status, and injury-replant interval were compared between the two groups, with all procedures performed by a single surgeon. The outcome parameters studied were length of hospital stay, timeline for wound healing, viability, and functional outcomes.

Results: Our patients consisted of 18 men and three women, of which 14.3% were smokers and 85.7% were right-handed. There were 11 finger replantation/revascularizations (n = 11) versus 10 pulp replantation/revascularizations (n = 10). The average age of digit replantation/revascularization patients was 44.8 years compared with 26.4 years in pulp replantation/revascularization patients (Student *t* test, *P* = 0.04). Mean ischemia time in digital replants was 67 minutes versus 32.3 minutes in pulp replantation/revascularization (Student *t* test, *P* = 0.056). Digital replantation/revascularization was viable in 72% of cases versus a 90% viability in the pulp subcohort.

Conclusions: In our patient cohort, pulp replantation/revascularizations produced better postoperative viability. Where supermicrosurgery expertise is available, pulp replantation/revascularization should be considered a worthwhile option when compared with digital replantation/revascularization. (*Plast Reconstr Surg Glob Open* 2023; 11:e4768; doi: 10.1097/GOX.0000000000004768; Published online 25 January 2023.)

INTRODUCTION

Fingertip injuries are a common presentation to the emergency department. The primary goals of fingertip replantation are to achieve stability, sensitivity, and nail preservation. Pulp replantation is not a new concept.¹ It

was first described by Komatsu and Tamai² in 1968 when it was shown to be technically possible, but due to the level of technical dexterity required, it was not popularized at the time. The first successful case of replantation was reported in 1973 with an artery-only anastomosis. Arterial or venous anastomoses are impossible in certain avulsion amputations or distal crush injuries, and circumstances where vessels are of smaller diameter. Composite grafting is an alternative to reconstructing a nonreplantable amputated pulp. Composite grafting has been widely performed for distal fingertip amputations, but variable success rates are reported in the literature. Key complications include infection and necrosis.³ Successful replantation/revascularisation can provide

From the *Department of Medicine, Imperial College London, London, UK; †Department of Plastic Surgery, Queen Victoria Hospital, East Grinstead, UK; and ‡Department of Plastic Surgery, Hiroshima University Hospital, Hiroshima, Japan.

Received for publication August 7, 2022; accepted November 16, 2022.

Kwaku Duah-Asante and Murtaza Kadhum contributed equally to this work.

Copyright © 2023 The Authors. Published by Wolters Kluwer Health, Inc. on behalf of The American Society of Plastic Surgeons. This is an open-access article distributed under the terms of the [Creative Commons Attribution-Non Commercial-No Derivatives License 4.0 \(CCBY-NC-ND\)](https://creativecommons.org/licenses/by-nc-nd/4.0/), where it is permissible to download and share the work provided it is properly cited. The work cannot be changed in any way or used commercially without permission from the journal.

DOI: 10.1097/GOX.0000000000004768

Disclosure: The authors have no financial interest to declare in relation to the content of this article.

Related Digital Media are available in the full-text version of the article on www.PRSGlobalOpen.com.

excellent aesthetic and functional outcomes for patients. Achieving such outcomes, however, is dependent on many factors, such as patient age, occupation, dominant hand, severity, and level of injury as well as clinical factors such as the stability of the patient. Thumb and multiple digital involvements are considered as strong indications for surgery.⁴ Contrarily, chronic conditions, such as diabetes mellitus, vascular diseases, and smoking, have a higher failure rate and thus may affect decisions for surgery.^{5,6} With the development of supermicrosurgery⁷ and its increasing use in the field of lymphatic surgery,⁸ a significant proportion of surgeons today can regularly perform anastomoses of up to 0.3 mm. In this setting, we ask the question of whether there is a difference in outcomes between finger and pulp replantation, with the bigger question being whether the latter is now a viable option to safely offer patients.

PATIENT AND METHODS

In a retrospective case review at a single institution (The Queen Victoria Hospital, East Grinstead, UK), we analyzed the clinical outcomes of 21 patients ($n = 21$) who presented with finger or pulp injuries, which underwent replantation/revascularization over a 5-year period (2016–2021). This case review was approved by the QVH Clinical Governance & Audit Department (Audit no. 419). We assigned our patients into two subcohorts: finger (F) and pulp (P) groups. This was decided by whether the distal segment, which was to be replanted or revascularized, was a digit or a pulp.

All cases were taken to theater at the earliest given opportunity. The senior author (R.Y.K.) personally performed all the cases to standardize the study as best as possible. The Knight's move technique⁷ was used for vessel dimensions smaller than 0.8 mm external diameter with the preferred suture being 10 of 0 S&T. Pulp replants had a single inflow vessel anastomosis, performed either as artery to artery or artery to vein while outflow was achieved by shaving pulp skin. On the other hand, those in group "F" had both arterial and venous anastomoses. Postoperatively, low-molecular weight heparin was administered as default with IV heparin infusions at 500 IU/h used for selected cases. We did not use prostaglandin infusions, as is recommended for supermicrosurgery cases,⁵ as this is not available for use in our institution.

The parameters studied were injury-replant interval, mechanism of injury, level of injury, tourniquet time, the use of arterial or vein grafts, the use of anticoagulation, length of in-hospital stay, and the outcome. Our outcome parameters were compared using the Student t test, χ^2 test, and the two-way analysis of variance (ANOVA) test by the IBM SPSS software.

RESULTS

In group F, there were 11 cases ($n = 11$), with a mean age of 44.8 years with nine men and two women, whereas in group P, there were 10 cases ($n = 10$) (Table 1). The mean age in this subcohort was 26.4 years, with nine male patients and one female patient. Thirty percent of those

Takeaways

Question: Does a difference in outcomes exist between finger and pulp replantation/revascularizations patients who underwent microsurgery by a single surgeon at Queen Victoria Hospital, England?

Findings: These groups were matched for age, sex, ischemic time, handedness, smoker status, and injury-replant interval to ensure comparability. The outcome parameters studied were the length of hospital stay, days taken to heal, viability, and functional outcomes. Digital replantation/revascularization was viable in 72% of cases versus a 90% viability in the pulp subcohort.

Meaning: If supermicrosurgery expertise is available, pulp replantation/revascularization should be performed as there is no difference compared with proximal replantation/revascularization.

Table 1. Summary of the Baseline Characteristics in This Study and Their Statistical Comparisons

Parameter	Pulp Group	Finger Group	<i>P</i>
Average Age	26.4	44.8	0.042 (*)
Gender	9 M, 1 F	9 M, 2 F	0.592
Handedness	83% Right-handed	100% Right-handed	0.197
Ischemia time	32 min	67 min	0.0564
Smoker status	0%	30%	0.0833
Injury-replant interval	14 h 55 min	10 h 4 min	0.114

A t test was used for continuous data and chi-squared was used for categorical data. (*) denotes a statistically significant difference ($P < 0.05$).

in group F were smokers while none of the patients in group P were smokers. There was a significant difference in terms of age between both groups (Student t test, $P = 0.04$), but no statistical difference with reference to sex and smoking status (χ^2 test, $P = \text{ns}$). The average ischemia time was 67 minutes in group F and 32 minutes in group P. This difference was statistically insignificant (Student t test, $P = 0.056$). A representative sample of patients from both groups is illustrated in the following.

Case 1 (Finger Group)

A 35-year-old man sustained an avulsion injury of the thumb, just distal to the metacarpophalangeal joint, following a work-related injury. He presented for replantation at over 5 hours after injury. This necessitated K-wire fixation and reversed vein grafts for both arterial and venous anastomoses. The tourniquet time was 40 minutes, and the patient was given an infusion of unfractionated heparin at 500 IU/h for 5 days, before being discharged at 1 week postoperatively. The image at 10 days postoperatively shows a well-vascularized thumb, and the patient was subsequently discharged from the follow-up clinics at 3 months postoperatively. (See figure, Supplemental Digital Content 1, which shows a clinical photograph of the thumb 10 days after replantation, <http://links.lww.com/PRSGO/C350>.)

Case 21 (Pulp Group)

A 48-year-old man was presented with a crush injury to the tip of this right thumb at the Tamai type 1 level as a result of a work-related accident. He presented at 9 hours after injury and underwent a pulp replantation, wherein a 0.5-mm central pulp artery was repaired using 10-0 S&T sutures under regional anesthesia. Postoperatively, the patient only received daily 5000 IU of low-molecular-weight heparin. The very distal 5 mm tip of the thumb sustained superficial necrosis, first noted at 2 weeks postoperatively. This was managed conservatively, and by 8 weeks postoperatively, the patient had regained full thumb function. (See Video [online], which illustrates the outcome of thumb pulp replantation at 8 weeks postoperatively.)

The mean injury-to-replant time was 604 minutes in group F against 895 minutes in group P. The predominant mechanism of injury in group F was avulsion (45%), followed by guillotine-type injuries (36%). In group P, crush injury (50%) was the most common, with avulsion as the cause in 30%. Of 11 patients (n = 11) in group F, the level of the injury was the middle phalanx in five cases (n = 5), proximal phalanx in four cases (n = 4), and the distal phalanx in two cases (n = 2) (Fig. 1).

Intraoperatively, the mean tourniquet time was 72.4 minutes in the finger group versus 32.3 minutes in the pulp replantation group. Four patients in group F needed either an arterial or a venous graft: three because of an avulsion injury and one due to a degloving injury. In group P, there was no correlation as a reversed vein graft was necessary in one case each of avulsion, crush, and guillotine injury. Nine percent of patients in group F had a single arterio-venous anastomosis versus 30% in group P. This was statistically not significant (χ^2 test).

Group P had an average hospital stay of 6 days, whereas group F had an average hospital stay of 3.4 days. This difference was statistically insignificant (Student *t* test, *P* = 0.128). The average time between injury and replant was 10 hours 4 minutes in group P and 14 hours 55 minutes in group F. This difference was also statistically insignificant (Student *t* test, *P* = 0.114).

In terms of viability, there were three failed replants in group F, out of 11 patients (72% success) as compared with 90% success in group P. There was no statistically significant difference for viability, using the two-way ANOVA test. Of the eight replants that survived in group F, three developed partial necrosis that was managed conservatively, whereas three of the nine patients in group P with viable replants developed partial necrosis (Fig. 2; Table 2).

DISCUSSION

Since the first finger replantation in the 1960s by Komatsu and Tamai,² subsequent studies by Weiland et al⁹ and Morrison et al¹⁰ have highlighted its disadvantages as compared with amputations. Urbaniak et al's¹¹ subsequent work in the 1980s justified finger replantation distal to the flexor digitorum superficialis as a long-term viable option, but still not replantation proximal to the flexor digitorum superficialis. Gradually, consensus again shifted to recommend proximal replantation as well. This was because a higher proportion of those with replanted fingers used their injured digit as compared with amputated digital segments.¹² This may be attributable to improved hand rehabilitation regimens since the 1970s. As for terminal digit replantation/revascularization, provided that supermicrosurgical expertise is available, single inflow vessel anastomosis of up to 0.5mm diameter can provide optimal results.¹³

Replantation is not indicated for all patients. For example, in trauma patients, priority is given to life-threatening injuries over digital replantation. The decision to replant depends upon many psychosocial factors in addition to the health of the patient, the stump, and the amputated parts. Indications for digital replantation include amputated thumbs, amputations of multiple digits, any digit in the pediatric population, and single digital injuries, which occur distal to the flexor digitorum superficialis tendon. Contraindications include severe crushing injuries, massive contamination, severe atherosclerotic disease, prolonged warm

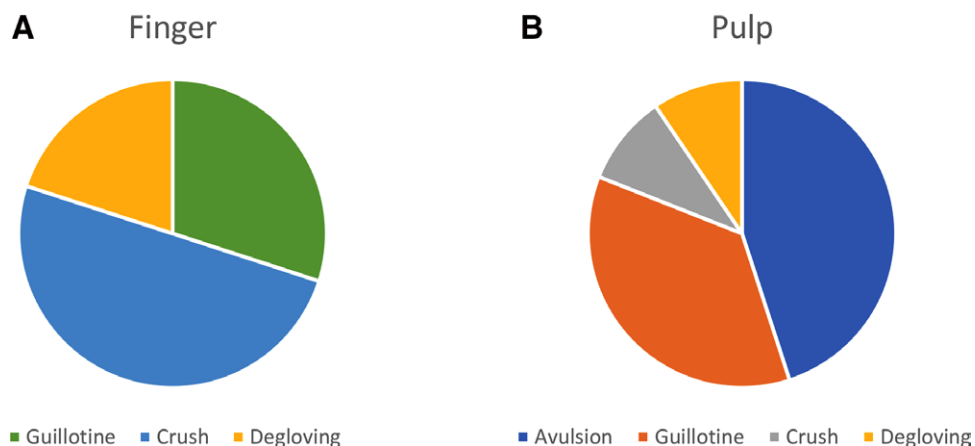
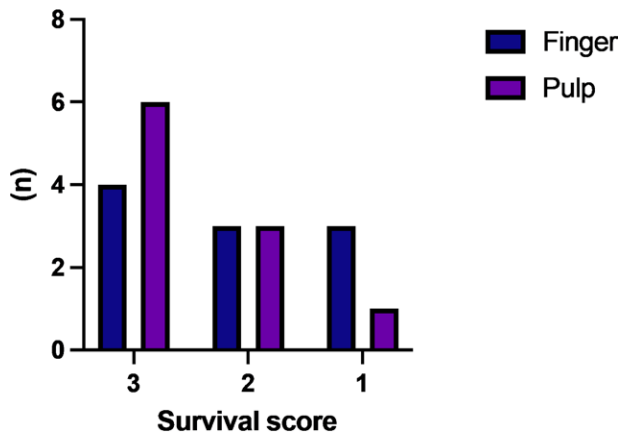


Fig. 1. Figure depicting the mechanisms of injury. A, Finger injuries. B, Pulp injuries.



(3 – totally viable; 2 – partially viable; 1 – necrotic)

Fig. 2. Graph illustrating survival scores for pulp and finger replantation.

Table 2. Summary of the Studied Perioperative Factors and Outcome Parameters in This Study and Their Statistical Comparisons

Parameter	Finger Group	Pulp Group	P
In-hospital stay	6 d	3.4 d	0.128
Injury-replant interval	10 h	14.6 h	0.113
Anastomosis time	72.4 min	32.3 min	0.57
Viability	72%	90%	ns

A *t* test was used for continuous data, and two-way ANOVA was used for categorical data.

ischemia frozen amputations, and injuries to multiple levels of the same digit.^{14,15}

This study represents the first direct comparison between the more proximal finger replantation/revascularisations with distal pulp replantation/revascularisations in a single-center, single-surgeon setting, specifically to look at its survival. Mechanisms of trauma from guillotine amputations to severe degloving injuries were also included in the study.

Based on this study design, we were able to selectively compare whether current microsurgical and supermicrosurgical techniques were intrinsically comparable, and we found that they are. There was no difference between finger and pulp replantation/revascularization when using a single inflow vessel technique¹⁶ and the skin crater method.¹⁷ In fact, although it did not reach statistical significance, pulp replantation/revascularization performed better than finger replants. We postulate that this may be due to an inherent “composite graft” effect, but further studies are necessary to confirm this. When comparing our results with similar studies on pulp replantation/revascularizations, we found that our results (90% viability) are comparable to the 73%–91% viability rates, quoted in the literature.^{17–19} When treating complex replantation/revascularization cases with an intervening soft tissue defect, flow-through free flaps provide the best single-stage option to both act as a vascular conduit

and provide cover. Our preference is the arterio-venous flow-through flap, which was used in one patient in the pulp group, as it is an easy free flap to plan and raise using near infra-red technology.²⁰ Alternative flow-through flaps may also be considered.²¹

LIMITATIONS

Our study consisted of 21 patients, which may limit the reproducibility of our results. To improve the study, we would like to recruit more patients for a larger patient population. Furthermore, confounding variables that may affect the assessed outcomes, such as age, smoking, ischemia time, tourniquet time, and time between injury and replant, differed between our patient populations and could potentially confound our results. In our study, the only statistically significant differences were in age (Student *t* test, $P = 0.04$), Hospital stay (Student *t* test, $P = 0.128$), injury-replant interval (Student *t* test, $P = 0.113$), anastomosis time (Student *t* test, $P = 0.57$), and viability (two-way ANOVA, $P = ns$) were all statistically insignificant.

FUTURE SCOPE

To further our research, we would like to incorporate further data regarding patient complications, such as sensitivity issues and cold intolerance. Moreover, we would like to conduct a cost-effectiveness analysis comparing the costs of procedures based on theater time and equipment used to further compare efficiency and outcomes.

CONCLUSIONS

In summary, supermicrosurgery can now be utilized in the wider clinical setting, with the technical distinction between microsurgery and supermicrosurgery now becoming blurred. There was no difference between finger and pulp replantation/revascularization of our perioperative factors. Moreover, pulp replantation/revascularization was performed better than finger replants.

Kwaku Duah-Asante, BSc (Hons)

Imperial College London

E-mail: kwaku.duah-asante17@imperial.ac.uk

REFERENCES

- Nakajima Y, Iwasawa M, Mishima Y, et al. Fingertip replantation using artery-only anastomosis with a pulp tissue reduction method. *Ann Plast Surg.* 2020;85:266–271.
- Komatsu S, Tamai S. Successful replantation of a completely cut-off thumb. *Plast Reconstr Surg.* 1968;42:374375–374377.
- Landin M, Borrelli M, Sinha V, et al. Composite grafts for fingertip amputations: a systematic review. *IJS Short Rep.* 2021;6:e17–e17.
- Chung K, Alderman A. Replantation of the upper extremity: Indications and outcomes. *J Am Soc Surg Hand.* 2002;2:78–94.
- Kleinert HE, Juhala CA, Tsai TM, et al. Digital replantation-selection, technique, and results. *Orthop Clin North Am.* 1977;8:309–318.

6. Dec W. A meta-analysis of success rates for digit replantation. *Tech Hand Up Extrem Surg.* 2006;10:124–129.
7. Koshima I. Atypical arteriolar anastomoses for fingertip replantations under digital block. *J Plast Reconstr Aesthet Surg.* 2008;61:84–87.
8. Yamamoto T, Koshima I. Neo-valvuloplasty for lymphatic supermicrosurgery. *J Plast Reconstr Aesthet Surg.* 2014;67:587–588.
9. Weiland AJ, Villarreal-Rios A, Kleinert HE, et al. Replantation of digits and hands: analysis of surgical techniques and functional results in 71 patients with 86 replantations. *J Hand Surg.* 1977;2A:1–12.
10. Morrison WA, O'Brien BM, MacLeod AM. Evaluation of digital replantation—a review of 100 cases. *Orthop Clin North Am.* 1977;8:295–308.
11. Urbaniak JR, Roth JH, Nunley JA, et al. The results of replantation after amputation of a single finger. *J Hand Surg.* 1985;67A:611–619.
12. Hattori Y, Doi K, Ikeda K, et al. A retrospective study of functional outcomes after successful replantation versus amputation closure for single fingertip amputations. *J Hand Surg Am.* 2006;31:811–818.
13. Merle M, Dautel G. Advances in digital replantation. *Clin Plast Surg.* 1997;24:87–105.
14. Maricevich M, Carlsen B, Mardini S, et al. Upper extremity and digital replantation. *Hand (NY).* 2011;6:356–363.
15. Pet M, Ko J. Indications for replantation and revascularization in the hand. *Hand Clin.* 2019;35:119–130.
16. Kendir M, Ismayilzade M, Ince B, et al. Fingertip replantation using artery-only anastomosis with pulp tissue reduction methods. *Ann Plast Surg.* 2021;87:114–115.
17. Kayalar M, Gunturk OB, Gurbuz Y, et al. Survival and comparison of external bleeding methods in artery-only distal finger replantations. *J Hand Surg Am.* 2020;45:256.e1–256.e6.
18. Braig D, Thiele JR, Penna V, et al. Results after distal digital replantation—is it worth the effort? *Handchir Mikrochir Plast Chir.* 2017;49:29–36.
19. Koshima I, Soeda S, Moriguchi T, et al. The use of arteriovenous anastomoses for replantation of the distal phalanx of the fingers. *Plast Reconstr Surg.* 1992;89:710–714.
20. Khajuria A, Sethu A, Kannan RY. The use of a neurotized arterio-venous flow-through flap for concurrent pulp revascularization and reconstruction. *Plast Reconstr Surg Global Open.* 2021;9:e3894.
21. Lee DC, Kim JS, Roh SY, et al. Flap coverage of dysvascular digits including venous flow-through flaps. *Hand Clin.* 2019;35:185–197.