

## Somatosensory and motor representations following bilateral transplants of the hands: A 6-year longitudinal case report on the first pediatric bilateral hand transplant patient

W. Gaetz<sup>a,b,\*</sup>, C. Dockstader<sup>c</sup>, P.L. Furlong<sup>d</sup>, S. Amaral<sup>e</sup>, A. Vossough<sup>a,b,f</sup>, E.S. Schwartz<sup>a,b,f</sup>, T.P.L. Roberts<sup>a,b</sup>, L. Scott Levin<sup>g,h,i</sup>

<sup>a</sup> Lurie Family Foundations' MEG Imaging Center, Department of Radiology, Children's Hospital of Philadelphia, Philadelphia PA, USA

<sup>b</sup> Department of Radiology, Children's Hospital of Philadelphia, Perelman School of Medicine, University of Pennsylvania, Philadelphia, PA, USA

<sup>c</sup> Human Biology Program, University of Toronto, Toronto ON, Canada

<sup>d</sup> Institute of Health and Neurodevelopment, Aston University, Birmingham, UK

<sup>e</sup> Department of Pediatrics, Division of Nephrology, The Children's Hospital of Philadelphia, University of Pennsylvania, Perelman School of Medicine, 3401 Civic Center Blvd, Philadelphia, PA 19104, USA

<sup>f</sup> Division of Neuroradiology, Department of Radiology, The Children's Hospital of Philadelphia, University of Pennsylvania, Perelman School of Medicine, Philadelphia, PA 19104, USA

<sup>g</sup> Department of Orthopaedic Surgery, University of Pennsylvania, Perelman School of Medicine, Philadelphia, PA 19104, USA

<sup>h</sup> Division of Plastic and Reconstructive Surgery, The Children's Hospital of Philadelphia, 3401 Civic Center Blvd, Philadelphia, PA 19104, USA

<sup>i</sup> Department of Orthopaedic Surgery, The Children's Hospital of Philadelphia, PA 19104, USA

### ARTICLE INFO

#### Keywords:

Magnetoencephalography (MEG)  
Cortical reorganization  
Allotransplantation  
Neural plasticity  
Pediatrics  
Sensorimotor oscillations  
Vascularised composite allotransplants (VCA)

### ABSTRACT

A vascularized composite tissue allotransplantation (VCA) was performed at the Children's Hospital of Philadelphia (CHOP), on an 8-year-old patient in 2015, six years after bilateral hand and foot amputation. Hand VCA resulted in reafferentation of the medial, ulnar, and radial nerves serving hand somatosensation and motor function. We used magnetoencephalography (MEG) to assess somatosensory cortical plasticity following the post-transplantation recovery of the peripheral sensory nerves of the hands. Our 2-year postoperative MEG showed that somatosensory lip representations, initially observed at "hand areas", reverted to canonical, orthotopic lip locations with recovery of post-transplant hand function. Here, we continue the assessment of motor and somatosensory responses up to 6-years post-transplant. Magnetoencephalographic somatosensory responses were recorded eight times over a six-year period following hand transplantation, using a 275-channel MEG system. Somatosensory tactile stimuli were presented to the right lower lip (all 8 visits) as well as right and left index fingers (visits 3-8) and fifth digits (visits 4-8). In addition, left and right-hand motor responses were also recorded for left index finger and right thumb (visit 8 only). During the acute recovery phase (visits 3 and 4), somatosensory responses of the digits were observed to be significantly larger and more phasic (i.e., smoother) than controls. Subsequent measures showed that digit responses maintain this atypical response profile (evoked-response magnitudes typically exceed 1 picoTesla). Orthotopic somatosensory localization of the lip, D2, and D5 was preserved. Motor beta-band desynchrony was age-typical in localization and response magnitude; however, the motor gamma-band response was significantly larger than that observed in a reference population. These novel findings show that the restoration of somatosensory input of the hands resulted in persistent and atypically large cortical responses to digit stimulation, which remain atypically large at 6 years post-transplant; there is no known perceptual correlate, and no reports of phantom pain. Normal somatosensory organization of the lip, D2, and D5 representation remain stable following post-recovery reorganization of the lip's somatosensory response.

\* Corresponding author at: Department of Radiology, Children's Hospital of Philadelphia, 34th St. And Civic Center Boulevard, Philadelphia, PA 19104, USA.  
E-mail address: [gaetz@email.chop.edu](mailto:gaetz@email.chop.edu) (W. Gaetz).

<https://doi.org/10.1016/j.brainres.2023.148262>

Received 11 November 2022; Received in revised form 19 January 2023; Accepted 21 January 2023

Available online 24 January 2023

0006-8993/© 2023 The Authors. Published by Elsevier B.V. This is an open access article under the CC BY-NC-ND license (<http://creativecommons.org/licenses/by-nc-nd/4.0/>).

## 1. Introduction

Hand amputations, from a traumatic event or medical intervention, result in the complete loss of afferent tactile input (i.e., deafferentation) from the corresponding hand to the human contralateral primary sensorimotor cortex. This absence of input results in a *massive cortical reorganization* where neighboring regions of the somatosensory homunculus infiltrate topographically, creating new, reorganized somatosensory maps consistently depicted in adult amputees (Elbert et al., 1994; Flor, 2002; Makin et al., 2015; Yang et al., 1994). In non-human primates, much of the massive cortical reorganization that follows therapeutic amputation of the hand reflects new atypical connections from the dorsal horn of the spinal cord, the cuneate nucleus of the brainstem and ventroposterior nucleus of the thalamus (VPN) related to the amputated hand (Florence and Kaas 1995; Florence et al 2000; Jain et al 2008). These new connections allow nerve function from the remaining forelimb to activate deprived cortical regions. In upper limb amputees, lip stimulation activates cortex superior and medial to the conventional lip area – and more typically associated with sensorimotor hand cortical function (Elbert et al., 1994; Yang et al., 1994; Florence and Kaas, 1995). Thus, hand amputation and resultant deafferentation results in consistent peripheral and central nervous system connection sequelae.

Vascularized composite tissue allotransplantation (VCA, i.e., hand *transplant*) surgery offers amputee patients functional donor hand grafts that can potentially restore tactile sensation and a naturalistic hand movement capacity more than that of conventional prosthetic wearers (Frey et al., 2022), and improve their quality of life (QoL). Following VCA, a new circumscribed nerve regeneration must successfully relay sensory input to the corresponding regions of the primary somatosensory cortex and output from the motor cortices to the intrinsic muscles of the hand. With recovery of sensation and motor function, the post-amputation cortical reorganization begins to revert to the *original* orthotopic representation, effectively reversing the massive cortical reorganization (Gaetz et al., 2018). If the VCA procedure is successful, this orthotopic representation can be restored even years after amputation and cortical reorganization in adults (Hernandez-Castillo et al., 2016) and has recently been shown for the first time by our group involving a single pediatric bilateral hand transplant case (Gaetz et al., 2018). The reversal in cortical reorganization may underlie the improved experience of sensorimotor function in VCA patients (compared to prosthetics); however, the time course, the persistence and the magnitude of neural responses secondary to these brain functional organizational changes remains unknown.

Magnetoencephalography (MEG) provides an exquisite quantitative window into the spatiotemporal (and spectral) aspects of cortical neuronal activity, allowing depiction of spatial reorganization, assessment of latency variation and characterization of neural oscillatory activity, presumed to subserve function. While previous MEG studies have depicted massive cortical reorganization post-amputation, few studies have examined post-transplant changes and, importantly, the persistence over time of changes in spatial organization and magnitude of neural activity. However, since long-term, longitudinal measures of the neurophysiological aspects of the recovery process are needed to assess the specific neural changes that underlie permanent and effective adaptation to human allotransplantation, serial MEG studies over several years are called for. Such information could be invaluable for predictions of QoL and long-term outcomes, to inform patient care.

Perhaps because of the lack of these insights hitherto, pediatric musculoskeletal allotransplantation remains uncommon due, in part, to concerns over potential life-long and life-threatening need for anti-rejection medications which suppress immune activity, for what is a non-lifesaving procedure (Lanzetta, 2017). However, QoL considerations can potentially justify these risks in some cases if substantial and sustained recovery of function can be predicted.

In the present study, we used MEG to continue to characterize

primary somatosensory (SI) and motor (MI) cortical responses in our pediatric allotransplant patient (Gaetz et al., 2018). Throughout eight visits across six years, we implemented a repeated-measures design of tactile stimulation of the right lower lip and left and right index fingers (Digit 2: LD2, RD2, as well as Digit 5: RD5, LD5), and characterized motor cortical oscillations six years post-transplant (only on the most recent visit, visit 8). In a previous study of patients with finger replantation, atypically large somatosensory responses were observed using MEG - possibly due to common reports of phantom pain sensations (Blume et al., 2014). Given that our patient had no history of phantom pain associated with his transplanted hands, we hypothesized that his atypically large somatosensory evoked-response amplitudes might normalize over time (relative to a recently published pediatric dataset from our group (Gaetz et al., 2017)). As there is currently no published data on the effect of VCA on motor cortical oscillations, we adopted no hypothesis about how VCA would affect motor cortical oscillations. The present results provide first-time insights into the long-term sensorimotor cortical adaptations in pediatric hand allotransplant underlying sustained functional recovery and a favorable QoL.

## 2. Methods

### 2.1. Patient

A pediatric bilateral hand allotransplant was conducted on an 8-year-old boy in 2015 (Amaral et al., 2017). This individual was already receiving anti-rejection medications following a renal transplant several years prior, and therefore no additional immune suppression risk was added by hand transplantation. Behaviorally, by 18 months post-transplant, the patient reported no pain or phantom limb sensation and achieved sensory and motor milestones including pain and touch sensations, as well as fine and gross motor hand movements (Amaral et al., 2017). Cortical reorganization in response to the amputation restored to an orthotopic organization; however, neurophysiological responses were atypical (Gaetz et al., 2018). Specifically, the somatosensory (SI) evoked responses amplitudes were atypically large relative to controls (Gaetz et al., 2018), again, without any reports of phantom limb sensations or pain.

At five-year follow-up, the patient demonstrated increased motor dexterity and independence, including regular participation in age-appropriate activities, and a favorable QoL overall (Levy et al., 2022), providing strong, anecdotal evidence that pediatric allotransplantation can lead to functional sensorimotor recovery and improved QoL. The neural correlates thereof, however, remained unknown.

#### 2.1.1. MEG/MRI data acquisition

Whole-head MEG recordings were acquired using a CTF-Omega 275 channel system (CTF MEG International Services), sampled at 1200 Hz (0–300 Hz band-pass) with our patient seated in an upright position. Prior to data acquisition, 3 localization fiducial coils were placed at the nasion and pre-auricular locations and used for co-registration with his brain MRI, recorded after each MEG data acquisition. To identify eye-blink activity, an electrooculogram (EOG) was collected. Electrodes were also applied over the left and right clavicles for electrocardiogram (ECG) recording. EOG/ECG artifacts were manually rejected per trial (>1pT) off-line. All recorded signals (EOG, ECG, and MEG) were digitized at 600 Hz with 3rd order gradiometer environmental noise reduction applied to the MEG data.

Somatosensory tactile stimuli were presented to the right lower lip on each of the 8 visits, as well as right and left index fingers (RD2, LD2, visits 3 to 8) and fifth digits (RD5, LD5, visits 4 to 8). In addition, left and right-hand motor (i.e., button-press) responses were also recorded for the left index finger and right thumb. A summary denoting the number of months post-transplant each visit corresponded to is shown in Table 1.

**Table 1**  
MEG Somatosensory and Motor Tests over 8 Functional Imaging Visits.

- 8 consecutive (repeated) measures of right Lower Lip somatosensory responses over the last 6 years
- 6 consecutive (repeated) measures of LD2 & RD2 somatosensory responses over the last 5.5 years
- 4 consecutive (repeated) measures of RD5 & LD5 somatosensory responses over the last 4.5 years
- 1 assessment of RD2 & LD1 (Thumb) motor responses (button-press) on Visit 8 only

### 2.1.2. Medication status

Commonly administered anti-rejection (and related) medications (min/max) included: tacrolimus 4 mg-6.5 mg, sirolimus (0 mg-2.5 mg), prednisone (4 mg-6 mg) and mycophenolate mofetil (160 mg-500 mg) and continued to be taken on most MEG/MRI imaging visits.

## 2.2. Somatosensory stimuli

Somatosensory stimuli were presented to the right lower lip (Visits 1–8), RD2 & LD2 (Visits 3–8) and RD5 & LD5 (Visits 4–8) separately, using pneumatic pulses of compressed air (30 p.s.i.) delivered via clip-on balloon diaphragms. Stimulation duration was 35 ms, and the inter-stimulus interval (ISI) was jittered between 0.5 and 0.7 s. Data was collected in epochs of 0.4 s (–0.1 to 0.3 s) for a total of 500 trials with a third order synthetic gradiometer applied for noise rejection. The averaged somatosensory evoked field (SEF) was then filtered between 1 and 40 Hz with DC offset removed (using the pre-stimulus period) and trials with >1 cm (cm) of head motion were excluded. All data analysis was performed using vendor provided software, CTF DataEditor version 5.3.

### 2.3. Equivalent current dipole analysis

A 'P50m' evoked-response component was observed over contralateral somatosensory cortex for each stimulation site. A spherical conductor model was manually fit to the inner skull surface of our patient's MRI. A single dipole model was fit to the time point of maximum field reversal for the P50m using a least-squares minimization algorithm and co-registered on our patient's T1-weighted (3D MP-RAGE) MRI images. Dipole location (cartesian coordinates: x, y, z), moment (nano-ampere meters, nAm), residual variance, (R.V. %) and orientation were recorded separately for each stimulation site's evoked response. Sensor montage included 143 sensors for left SEF and 143 sensors for right SEF which were selected to cover the maximum and minimum field topographies (visually confirmed). This approach was generally preferred to using a strictly left or right hemisphere sensor montage as SEF field maxima/minima may (depending on head size and position within the MEG dewar) occasionally cross the midline.

### 2.4. Button press motor response Stimuli: Right D2 and left D1 (Visit 8)

Visually cued button press responses were controlled using 'Presentation' software (<https://www.neurobs.com/>). A red "+" was presented continuously on a translucent screen for fixation. Color change to a green '+' occurred once every 4 s ( $\pm 0.5$  s ISI). The continuously recorded MEG data was re-epoched around each button-press response (4 s duration: 2 s pre 2 s post). The synthetic aperture magnetometry (SAM) beamformer algorithm was used for source localization (Robinson and Vrba, 1999). Noise-normalized differential power values were calculated (integrated across a narrow-band and brief spectro-temporal "active" window compared to a "baseline" window) at the location of the largest response and expressed as the pseudo-t statistic, hereafter abbreviated as "pseudo-t" (Nichols and Holmes, 2002). Here, SAM results are reported as increases or decreases of noise-normalized differential source power in units of pseudo-t. Using SAM, we assessed motor cortical oscillations associated with the button-press response;

differential source activity in the beta band (14–30 Hz) (i.e., beta band event-related desynchrony; B-ERD) was assessed using a 500 ms active window (–0.3 s to 0.2 s) relative to a 500 ms pre-movement baseline time period locked to the button press response (–1.8 s to –1.3 s). In addition, movement-related gamma band synchrony (MRGS; 60–90 Hz) was assessed using a 300 ms active window (–0.1 s to 0.2 s) relative to the button press and referenced to a 300 ms (–1.8 s to –1.5 s) pre-movement baseline period. These baseline and active windows are consistent with those chosen in previous MEG work on the motor system (Gaetz et al., 2011; Gaetz et al., 2020).

Finally, to assess the structural integrity / typicality of our patient's brain, brain volumetry was performed on our patient's T1-weighted gradient-echo (MP-RAGE) volumetric MRI using a previously established pipeline which included image denoising, inhomogeneity correction, registration, hemispheric segmentation, tissue classification, and cortical thickness measurement, and referenced to age and sex matched normal values (Coupe et al., 2017; Manjon and Coupe, 2016; Manjon et al., 2010; Romero et al., 2015; Tustison et al., 2014).

## 3. Results

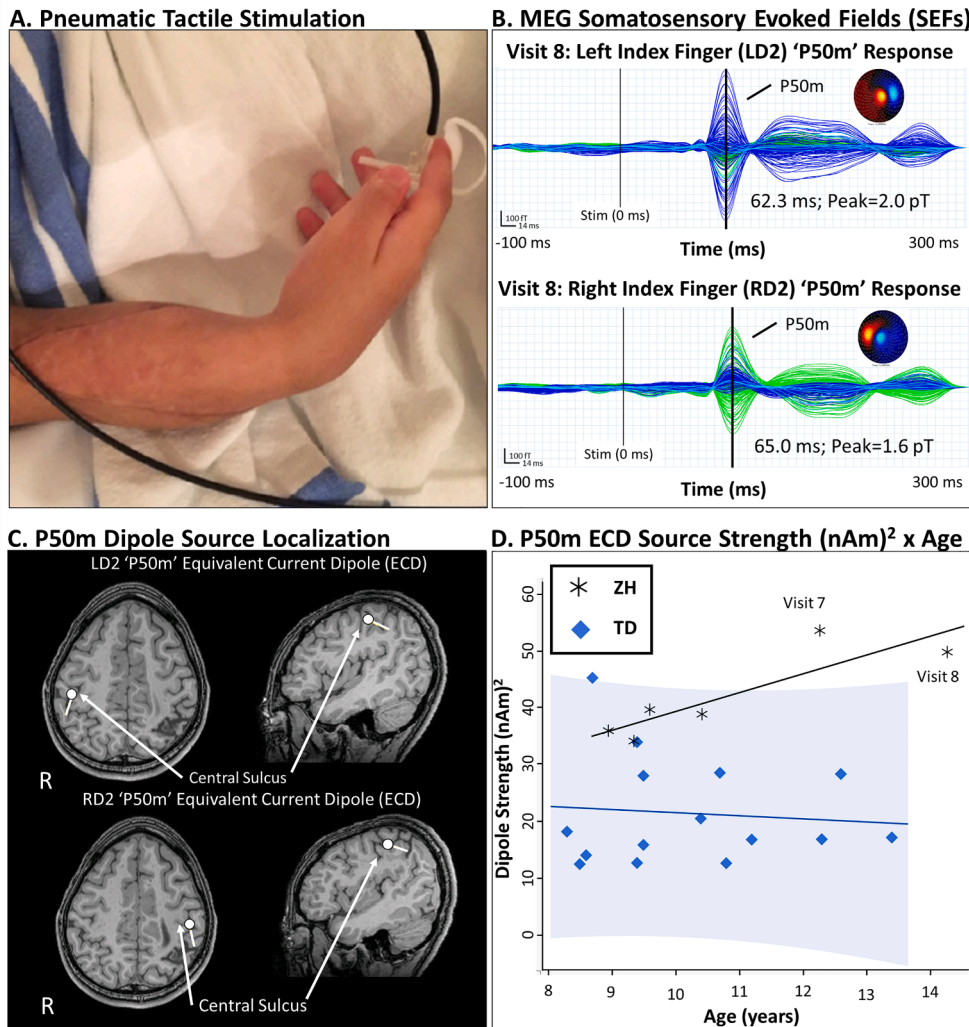
Brain volumetry showed that there was ventriculomegaly of the lateral and third ventricles, with the lateral ventricles occupying 8.38 % of the total intracranial volume (typical age and sex 95 % CI = 0.0 %–2.58 %). In addition, there were previous areas of sepsis-related brain injury on MRI, most prominently to the right parietal lobe, with small areas of encephalomalacia in the right inferior and superior parietal lobules. However, assessment of cortical volumes of the precentral and postcentral gyri revealed cortical volume within normal range, including the medial segments of the bilateral precentral and postcentral gyri.

A recent publication summarizes our patient's functional ability (Levy et al., 2022). In brief, our patient continues to maintain his independence in all self-care domains and continues to use his hands for a wide variety of daily activities (Levy et al., 2022). It should be noted, however, that somatosensation of our patient's fingers remains course (at or around the protective sensation threshold using Semmes Weinstein monofilament tests), and while our Patient continues to use his hands to accomplish many activities of daily living independently, his motor hand function continues to score below age norms (Levy et al., 2022).

### 3.1. MEG imaging results

The somatosensory P50m response to RD2 and LD2 stimulation remains atypically large (>95th percentile on Visits 7 and 8) and atypically smooth (less structured) relative to controls (even when unfiltered). Our patient's Visit 7 and 8 exceed the 95th percentile (see Fig. 1D (shaded blue)). These robust responses are of typical cortical location, latency, and dipole orientation. These results show that the post-surgical median nerve can govern the conduction of tactile mechanical stimulation from the transplanted fingers and relay robust, somesthetic activity to the typically activated regions of somatosensory cortex. In Gaetz et al, Neuroimage Clin 2017, we report (amongst other findings) bilateral latencies elicited by identical painless pneumatic stimulation of the index fingers in typically developing controls. While the current patient's latency values are slightly greater than the mean from the TD cohort (but within 2SD's of the mean), it is worth noting that the range of latencies observed in typical development extended to 65 ms in the LH and 66.7 ms in the RH, indicating that our patient is by no means an extreme latency outlier.

In addition, somatotopic representations for Lip, RD2 and RD5 were assessed using tactile stimulation. Relative positions of each body part were orthotopically represented in SI across the study visits (results from Visit 8 shown in Fig. 2). We note that these three stimulation sites are connected via independent nerve bundles to the somatosensory cortex



**Fig. 1.** Measurement of somatosensory evoked responses using MEG. (A) Evoked responses to tactile pneumatic stimulation of the left and right index fingers were recorded separately using MEG. (B) Somatosensory evoked fields from the averaged evoked response showed large amplitude dipolar cortical responses at about 60–65 ms, (i.e., the 'P50m' somatosensory evoked response). The leftmost line (grey) shows the time of stimulus onset, and the rightmost line (black) indicates the timepoint of the P50m peak (and associated topographical field patterns). (C) Dipole analysis of the P50m response showed the source to be localized to the posterior bank of the central sulcus of the contralateral primary somatosensory cortex, posterior to the motor hand knob. (D) Average of LD2 and RD2 ECD strength for our patient is consistently large relative to a published normative dataset of TD children using identical hardware, stimulation and ECD analysis methods (Gaetz et al., 2017). MEG = magnetoencephalography SEFs = Somatosensory Evoked Fields LD2 = left digit 2; RD2 = right digit 2 ECD = Equivalent Current Dipole fT = femtoTesla; pT = picoTesla R = left hemisphere.

(D2 – median nerve, D5 – ulnar nerve, lip – trigeminal nerve) and thus 'within nerve bundle' orthotopic somatotopy is maintained post-transplant.

Button-press motor responses (right thumb and LD2 on Visit 8 only) were assessed for B-ERD and motor gamma-band MRGS. A previously published data set from Gaetz et al., (2022) was used as reference for the MRGS amplitude. Sixty-three typically developing people (aged 8–24) participated in a visually cued button-press task. Results from this study showed a significant decrease of MRGS power with age ( $R^2 = 0.16$ ,  $p < 0.01$ ). After subtracting the linear fit of MRGS vs age, the SD of the residuals are 1.1876. Since our Patient had an MRGS of 7.85 on average, and the fit line passes through approximately 2.0 for a 15yo, he is 5.85 units above the mean ( $p(Z > 4.93) < 0.001$  (See Fig. 3), indicating their gamma power to be an outlier, extremely unlikely by chance alone.

In Gaetz et al, ASD Paper 2020, we report (amongst other findings) bilateral button-press response latencies elicited on an identical visually cued button-press task in typically developing controls. Our patient's reaction times (RTD1: 324.9+/-80.9 ms; LTD2: 392.3+/-117.8 ms) were not apparently different from typically developing controls (355.2+/-67.8 ms, Gaetz et al., 2020).

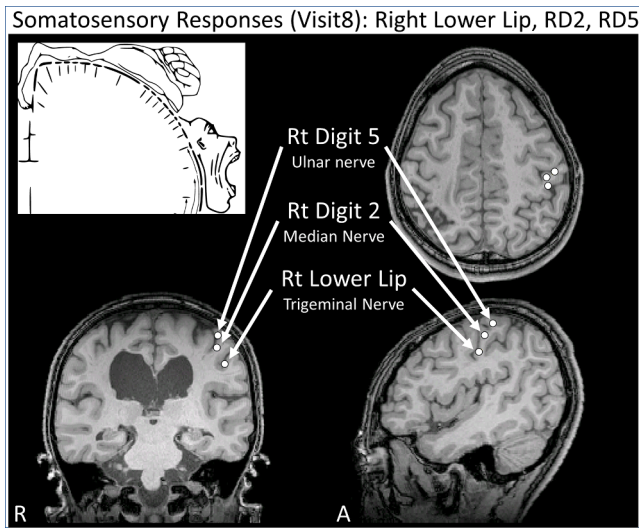
#### 4. Discussion

In our previous repeated measures case study on this patient (Gaetz et al., 2018), sensory deafferentation after limb amputation led to changes in cortical somatotopic maps which were reversed after

transplantation and restoration of sensory input. This follow-up repeated measures case study in the same individual has provided the following additional insights:

- The canonical orthotopic homuncular representation of the digits and lip in primary somatosensory cortex remain entirely preserved over the six years of follow-up.
- The larger than normal SEFs observed initially following transplantation and restoration of sensory input did not normalize over time. The index finger's SEF remains significantly elevated six years post-operation, perhaps even increasing in amplitude over time.
- Both B-ERD and MRGS motor cortical responses localized to the expected neuroanatomic motor cortex substrates, however, only B-ERD demonstrated age-typical power on our conventional button press task. The associated magnitude of MRGS was profoundly large (by almost 5 SDs compared to a pediatric control group).
- Significant functional adaptation of the transplanted hands continues to afford independent living (feeding, dressing etc.) and improvements in quality of life without pain or phantom limb sensations.

Nerve regeneration is an essential component of the functional success of VCA, with complete transection of donor and recipient nerves requiring repair to restore function. Following amputation, axons will have degenerated back to the nearest node of Ranvier to the amputation. In a donor limb, the peripheral nerve undergoes Wallerian degeneration



**Fig. 2.** Homuncular organization of somatosensory cortex post-surgery is shown. Consistent with Penfield’s homunculus (top left cartoon), localization of somatosensory sources of fields elicited by stimulation of the digits 2 and 5, as well as lip, (right sided stimulation shown) shows a medio-lateral and superior-inferior organization (with lip most inferior and lateral). Inset graphic from Wikipedia; after Penfield and Rasmussen (1950), *The Cerebral Cortex of Man* (Penfield & Rasmussen, 1950).

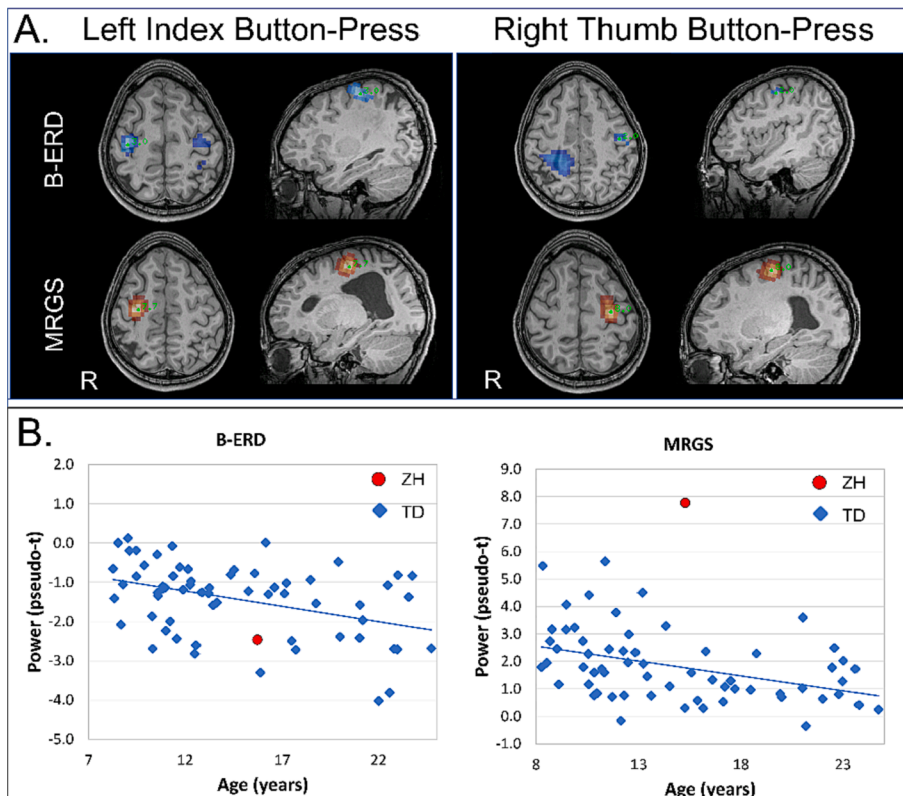
from the transection point to its distal motor or sensory receptor (Suchyta et al., 2016). VCA requires surgical reconnection of the severed nerves by suturing them together where the fascicles of the nerve are each reconnected. Following successful surgical reconnection, Schwann cells clear debris, create scaffolding, and release growth factors to stimulate nerve regeneration (Grinsell and Keating, 2014). Although the amount of axonal regeneration may be high, axons are often misdirected

and reinnervate incorrect targets (Grinsell and Keating, 2014). This lack of selectivity of axon-target reconnection can lead to poor functional recovery. Only a low percentage of adult patients regain normal function after complete transection of a major peripheral nerve (Allodi et al., 2012).

For our patient, reconnection of median (digit 2), and ulnar nerves (digit 5) yielded orthotopic responses in the cortex to stimulation of digits 2 and 5 as well as the lip. These observations of a “normal” orthotopic organization as well as restoration of SEF responses that were maintained over a six-year period strongly suggest that despite years without sensory input from the hands, the human somatosensory cortex, once organized during early development, retains the capacity to resume functional activity very much as originally instantiated once sensory input was restored. The level of specificity *within* nerve bundles during regeneration was not assessed in our patient. It is possible non-specific connectivity within the median nerve branches of the transplanted hand (e.g., thumb neurons re-connecting with index finger mechanoreceptors, and vice versa) limits post-transplant tactile sensitivity and may help to explain the relatively poor fidelity of post-surgical tactile sensations and limited (below average) hand dexterity (Levy et al., 2022).

Our patient reported neither pain nor phantom limb phenomena at any point, even though around 80 % of amputees experience persistent pain in the deafferented body part. These sensations are attributed to plastic changes in the cortex (Flor, 2002) and the degree of phantom limb pain often correlates with the magnitude of this displacement (Florence and Kaas, 1995; Karl et al., 2001) though others have been unable to identify a relationship between the two (Makin et al., 2015). Our findings contradict the notion that cortical reorganization observed post amputation, namely the expansion of the cortical representation of the lip area into cortical hand area, is inherent to aberrant sensory perceptions.

Additionally, we assessed our patient’s movement-related cortical responses on a button-pressing task. We observed that movement-related B-ERD and MRGS was clearly measurable and orthotopically



**Fig. 3.** Motor functional localization for our patient post-surgery (Visit 8) (A) Beta band (14–30 Hz) ERD and motor gamma (60–90 Hz) MRGS was assessed for right thumb and left index finger button press responses (Visit 8 only). B-ERD peak activity for left index and right thumb activated contralateral motor cortex adjacent to the hand motor knob. Movement-related gamma band synchrony associated with these movements was similarly localized to contralateral motor cortex near the hand motor knob as typically observed. (B) Our patient’s LD2 and RD1 averaged B-ERD and MRGS power (from A) was plotted with a reference dataset involving motor responses from TD children using the same experimental methods, response hardware, and analysis methods (Gaetz et al., 2020). Our patient’s B-ERD peak values appear in line with those observed typically using identical hardware and analysis methods. However, our patient’s MRGS peak values are significantly greater than those observed typically. These atypically large MRGS responses were unexpected, and the functional significance remains unknown at present. Blue Peak Activity: Beta Band (14–30 Hz) Event Related Desynchronization (B-ERD) Red Peak Activity: Movement Related Gamma-Band (60–90 Hz) Synchrony (MRGS). (For interpretation of the references to color in this figure legend, the reader is referred to the web version of this article.)

localized six years following allotransplantation. Earlier reports of motor cortex localizations in amputees and transplantation are mixed. A systematic review by (Gunduz et al., 2020) describe pooled lateral cortical mapping shifts in upper limb amputees and a medial shift in lower limb, with the functional cortical representation of the missing limb being larger and more widespread than the non-affected one. Other studies support preservation and stability of motor cortex representation following amputation (van den Boom et al., 2021; Bruurmijn et al., 2017). Orthotopic restoration of sensory motor cortex activation has also been described in a lower limb transplant in a child (Fattah et al., 2011). While the amplitude of MI B-ERD was like that of responses from typically developing controls and maintained this typical response power for the six-year follow-up, the power of MRGS exceeded a typical range by a striking magnitude which persisted across the post-transplantation period. The functional ramifications of this observation remain to be elucidated, as does the mechanism leading to it, but it is tempting to speculate that either local inhibitory activity is diminished due to biases in the nature and type of cells that re-establish successful connection in the muscles of the hand. Alternatively, the reconnected system may have inherent inefficiencies of neural transmission and require compensatory gain upregulation. This latter consideration that, upon transplantation, motor neurons reconnect motor muscle cells to motor cortex, in addition to somatosensory neurons reconnecting somatosensory receptors to primary somatosensory cortex, suggests an innate affinity of the peripheral and central nervous systems that might be “taken for granted” in typical healthy development.

Overall, for our patient, SI and MI responses from orthotopically restored cortical regions post-transplant revealed sensorimotor evoked and induced activity that were notably larger than age matched control groups (Gaetz et al., 2018), and sustained in this six-year follow-up. Several studies have reported similar findings; (Blume et al., 2014), described stimulation of the replanted D1 that provoked a considerably higher ECD strength than stimulation of the non-affected thumb (>40 %), despite the presumably poorer afferent transmission in the replanted arm. Chen et al., (2006) observed that even though functional recovery was characterized as moderate, fair, or poor in their subject cohort, on both motor and tactile sensory tasks, the activated volumes from the transplanted toes were significantly greater than those from the non-transplanted fingers (Chen et al., 2006). Frey et al., (2008) also observed that despite limited sensation to palmer stimulation in the hand, unexpectedly large ipsilateral sensory SI responses were obtained in their unilateral replantation case study (Frey et al., 2008). The functional significance of these post-recovery large cortical responses remains unclear, as well as their persistence; however, it has been speculated that large somatosensory responses may reflect a neural correlate of pain and/or phantom pain (Blume et al., 2014).

Blume et al. (2014) considered the elevated ECD strength following VCA as a gain in cortical resources for the processing of the remaining input and might be attributed to recruitment of neurons whose afferent input was yet to be restored (Blume et al., 2014). These authors also argued that the phenomena of enlarged cortical responses may be related to the experience of pain widely reported in amputee and transplantation patients. Some authors considered this phenomenon to be an example of cortical recruitment to re-establish function, such as (Chen et al., 2006) and (Frey et al., 2008), who argue that this may be due to persistence of enlargement of cortical representation due to cortical intrusion from neighboring tissue areas post denervation, as proposed by (Wall et al., 1986).

Frey et al. (2008) considered that cortical recruitment and/or changes in interhemispheric inhibition may contribute to functional recovery of the restored limbs (Frey et al., 2008). Given the evidence of changes in subcortical structures due to sprouting or expansion from afferents from the amputated limb (Florence and Kaas, 1995; Florence et al., 2000; Jain et al., 2008), might conceivably lead to cortical magnification of additional afferent input projected from the transplanted limb. Whatever the underlying mechanisms, enlarged responses

clearly reflect a notable degree of reconnection of sensory innervation and should be considered a positive indication in replantation patients.

**Limitations of the Study:** Given the youth of our participant (age 8 on first visit) and consequently the limited time to probe somatosensory and motor organization/reorganization, we could not exhaustively assess all aspects of somatomotor function on each visit. Practical time constraints limited our ability to fully document the peripheral and central nervous system changes to bilateral transplants of the hands. Future work should attempt to establish nerve function of the wrist and forearm using conventional nerve conduction studies, in addition to TMS as performed in our patient (not described in the current ms). However, both the normalcy of the SEF latency and the normalcy of the motor reaction time argue against significant peripheral conduction delays.

In summary, for our patient, hand transplants restored connections of the cutaneous mechanoreceptors of the hands to orthotopic somatosensory cortex in the brain (and done so for both median (D2) and ulnar (D5) nerve bundles). In addition, the intrinsic muscles of the hands also reconnected with conventionally organized motor cortical brain areas. This case study is the first to explicitly demonstrate this concept in a bilateral, pediatric, in-vivo human setting. While the extant function is rudimentary, it is nonetheless remarkable. We speculate that improvements in the fidelity of *peripheral* reconnections will directly improve functional eloquence of the hands, as the brain is resilient – and apparently remains poised for resumption of its somatomotor roles – even after prolonged (6 years) deafferentation. This circuit level resilience of the brain offers considerable hope for future transplantations, and a possible mechanism for achieving better responses with transplants than with prosthetics, even after an extended period of absent sensory input.

#### CRediT authorship contribution statement

**W. Gaetz:** Conceptualization, Data curation, Formal analysis, Investigation, Methodology, Project administration, Validation, Visualization, Writing – original draft, Writing – review & editing. **C. Dockstader:** Writing – review & editing. **P.L. Furlong:** Writing – review & editing. **S. Amaral:** Writing – review & editing. **A. Vossough:** Formal analysis, Writing – review & editing. **E.S. Schwartz:** Project administration, Writing – review & editing. **T.P.L. Roberts:** Formal analysis, Investigation, Methodology, Writing – original draft, Writing – review & editing. **L. Scott Levin:** Conceptualization, Project administration, Writing – review & editing.

#### Declaration of Competing Interest

The authors declare that they have no known competing financial interests or personal relationships that could have appeared to influence the work reported in this paper.

#### Data availability

Data will be made available on request.

#### Acknowledgments

The authors would like to acknowledge our patient and supportive family, who endured hours of tedious experimentation at our MEG lab and to whom we are extremely grateful for their commitment to this study. We thank the members of our transplantation team involved in providing ongoing medical care and rehabilitation: Ashley Binkowski, Benjamin Chang, Kelly Ferry, Chris Feudtner, Deb Humpl, Michelle Hsia, Sudha Kilaru Kessler, Scott Kozin, Todd Levy, Debra Lefkowitz, Sonya Lopez, Chrissy Mcandrew, and Callie Tyner. We would also like to thank MEG/MRI Technologists; John Dell, Rachel Golemski, Peter Lam, Shivani Patel, Na'Keisha Robinson, and Erin Verzella for technical

assistance. Finally, we thank Charlotte Birnbaum for thorough edits to an earlier version of this manuscript.

## References

- Allodi, I., Udina, E., Navarro, X., 2012. Specificity of peripheral nerve regeneration: interactions at the axon level. *Prog. Neurobiol.* 98 (1), 16–37. <https://doi.org/10.1016/j.pneurobio.2012.05.005>.
- Amaral, S., Kessler, S.K., Levy, T.J., Gaetz, W., McAndrew, C., Chang, B., Lopez, S., Braham, E., Humpl, D., Hsia, M., Ferry, K.A., Xu, X., Elder, D., Lefkowitz, D., Feudtner, C., Thibaudeau, S., Lin, I.C., Kovach, S.J., Schwartz, E.S., Bozentka, D., Carrigan, R., Steinberg, D., Kanchwala, S., Zlotolow, D.A., Kozin, S., Jensen, F.E., Bryant, P.R., Shaked, A., Levine, M.H., Levin, L.S., 2017. 18-month outcomes of heterologous bilateral hand transplantation in a child: a case report. *Lancet Child Adolesc. Health* 1 (1), 35–44.
- Blume, K.R., Dietrich, C., Huonker, R., Gotz, T., Sens, E., Friedel, R., ... Weiss, T. (2014). Cortical reorganization after macroreplantation at the upper extremity: a magnetoencephalographic study. *Brain*, 137(Pt 3), 757–769. doi:10.1093/brain/awt366.
- Bruurmijn, M., Pereboom, I.P.L., Vansteensel, M.J., Raemaekers, M.A.H., Ramsey, N.F., 2017. Preservation of hand movement representation in the sensorimotor areas of amputees. *Brain* 140 (12), 3166–3178. <https://doi.org/10.1093/brain/awx274>.
- Chen, C.J., Liu, H.L., Wei, F.C., Chu, N.S., 2006. Functional MR imaging of the human sensorimotor cortex after toe-to-finger transplantation. *AJNR Am. J. Neuroradiol.* 27 (8), 1617–1621.
- Coupe, P., Catheline, G., Lanuza, E., Manjon, J.V., Alzheimer's Disease Neuroimaging, I., 2017. Towards a unified analysis of brain maturation and aging across the entire lifespan: a MRI analysis. *Hum. Brain Mapp.* 38 (11), 5501–5518. <https://doi.org/10.1002/hbm.23743>.
- Elbert, T., Flor, H., Birbaumer, N., Knecht, S., Hampson, S., Larbig, W., Taub, E., 1994. Extensive reorganization of the somatosensory cortex in adult humans after nervous system injury. *Neuroreport* 5 (18), 2593–2597. <https://doi.org/10.1097/00001756-199412000-00047>.
- Fattah, A., Cypel, T., Donner, E.J., Wang, F., Alman, B.A., Zuker, R.M., 2011. The first successful lower extremity transplantation: 6-year follow-up and implications for cortical plasticity. *Am. J. Transplant.* 11 (12), 2762–2767. <https://doi.org/10.1111/j.1600-6143.2011.03782.x>.
- Flor, H., 2002. Phantom-limb pain: characteristics, causes, and treatment. *Lancet Neurol.* 1 (3), 182–189. [https://doi.org/10.1016/s1474-4422\(02\)00074-1](https://doi.org/10.1016/s1474-4422(02)00074-1).
- Florence, S.L., Hackett, T.A., Strata, F., 2000. Thalamic and cortical contributions to neural plasticity after limb amputation. *J. Neurophysiol.* 83 (5), 3154–3159. <https://doi.org/10.1152/jn.2000.83.5.3154>.
- Florence, S.L., Kaas, J.H., 1995. Large-scale reorganization at multiple levels of the somatosensory pathway follows therapeutic amputation of the hand in monkeys. *J. Neurosci.* 15 (12), 8083–8095.
- Frey, S.H., Bogdanov, S., Smith, J.C., Watrous, S., Breidenbach, W.C., 2008. Chronically deafferented sensory cortex recovers a grossly typical organization after allogenic hand transplantation. *Curr. Biol.* 18 (19), 1530–1534. <https://doi.org/10.1016/j.cub.2008.08.051>.
- Frey, S., Motawar, B., Buchanan, K., Kaufman, C., Stevens, P., Cirstea, C., Morrow, S., 2022. Greater and more natural use of the upper limbs during everyday life by former amputees versus prosthesis users. *Neurorehabil. Neural Repair* 36 (3), 227–238. <https://doi.org/10.1177/15459683211062889>.
- Gaetz, W., Edgar, J.C., Wang, D.J., Roberts, T.P., 2011. Relating MEG measured motor cortical oscillations to resting gamma-aminobutyric acid (GABA) concentration. *Neuroimage* 55 (2), 616–621. <https://doi.org/10.1016/j.neuroimage.2010.12.077>.
- Gaetz, W., Jurkiewicz, M.T., Kessler, S.K., Blaskey, L., Schwartz, E.S., Roberts, T.P.L., 2017. Neuromagnetic responses to tactile stimulation of the fingers: evidence for reduced cortical inhibition for children with Autism Spectrum Disorder and children with epilepsy. *Neuroimage Clin.* 16, 624–633. <https://doi.org/10.1016/j.nicl.2017.06.026>.
- Gaetz, W., Kessler, S.K., Roberts, T.P.L., Berman, J.I., Levy, T.J., Hsia, M., Humpl, D., Schwartz, E.S., Amaral, S., Chang, B., Levin, L.S., 2018. Massive cortical reorganization is reversible following bilateral transplants of the hands: evidence from the first successful bilateral pediatric hand transplant patient. *Ann. Clin. Transl. Neurol.* 5 (1), 92–97.
- Gaetz, W., Rhodes, E., Bloy, L., Blaskey, L., Jackel, C.R., Brodtkin, E.S., Waldman, A., Embick, D., Hall, S., Roberts, T.P.L., 2020. Evaluating motor cortical oscillations and age-related change in autism spectrum disorder. *Neuroimage* 207, 116349.
- Grinsell, D., & Keating, C. P. (2014). Peripheral nerve reconstruction after injury: a review of clinical and experimental therapies. *Biomed Res Int*, 2014, 698256. doi: 10.1155/2014/698256.
- Gunduz, M.E., Pinto, C.B., Saleh Velez, F.G., Duarte, D., Pacheco-Barrios, K., Lopes, F., Fregni, F., 2020. Motor cortex reorganization in limb amputation: a systematic review of TMS motor mapping studies. *Front. Neurosci.* 14, 314. <https://doi.org/10.3389/fnins.2020.00314>.
- Hernandez-Castillo, C.R., Aguilar-Castaneda, E., Iglesias, M., Fernandez-Ruiz, J., 2016. Motor and sensory cortical reorganization after bilateral forearm transplantation: four-year follow-up fMRI case study. *Magn. Reson. Imaging* 34 (4), 541–544. <https://doi.org/10.1016/j.mri.2015.12.025>.
- Jain, N., Qi, H.X., Collins, C.E., Kaas, J.H., 2008. Large-scale reorganization in the somatosensory cortex and thalamus after sensory loss in macaque monkeys. *J. Neurosci.* 28 (43), 11042–11060. <https://doi.org/10.1523/JNEUROSCI.2334-08.2008>.
- Karl, A., Birbaumer, N., Lutzenberger, W., Cohen, L.G., Flor, H., 2001. Reorganization of motor and somatosensory cortex in upper extremity amputees with phantom limb pain. *J. Neurosci.* 21 (10), 3609–3618.
- Lanzetta, M., 2017. Hand transplantation in children: is it too early or too late? *Lancet Child Adolesc Health* 1 (1), 4–6. [https://doi.org/10.1016/S2352-4642\(17\)30035-4](https://doi.org/10.1016/S2352-4642(17)30035-4).
- Levy, T.J., Tyner, C.E., Amaral, S., Lefkowitz, D.S., Kessler, S.K., Levin, L.S., 2022. 5-year activity and participation outcomes of the first successful pediatric bilateral hand transplantation: a case report. *Phys. Occup. Ther. Pediatr.* 42 (6), 663–679. <https://doi.org/10.1080/01942638.2022.2057210>.
- Makin, T.R., Scholz, J., Henderson Slater, D., Johansen-Berg, H., Tracey, I., 2015. Reassessing cortical reorganization in the primary sensorimotor cortex following arm amputation. *Brain* 138 (Pt 8), 2140–2146. <https://doi.org/10.1093/brain/awv161>.
- Manjon, J.V., Coupe, P., 2016. volBrain: an online MRI brain volumetry system. *Front. Neuroinf.* 10, 30. <https://doi.org/10.3389/fninf.2016.00030>.
- Manjon, J.V., Tohka, J., Robles, M., 2010. Improved estimates of partial volume coefficients from noisy brain MRI using spatial context. *Neuroimage* 53 (2), 480–490. <https://doi.org/10.1016/j.neuroimage.2010.06.046>.
- Nichols, T.E., Holmes, A.P., 2002. Nonparametric permutation tests for functional neuroimaging: a primer with examples. *Hum. Brain Mapp.* 15 (1), 1–25. <https://doi.org/10.1002/hbm.1058>.
- Penfield, W., Rasmussen, T., 1950. The cerebral cortex of man; a clinical study of localization of function. Macmillan.
- Robinson, S. E., & Vrba, J. (1999). Functional neuroimaging by synthetic aperture magnetometry (SAM) In e. Yoshimoto T. (Ed.), *Recent Advances in Biomagnetism*. Sendai, Japan: Tohoku University.
- Romero, J.E., Manjon, J.V., Tohka, J., Coupe, P., Robles, M., 2015. NABS: non-local automatic brain hemisphere segmentation. *Magn. Reson. Imaging* 33 (4), 474–484. <https://doi.org/10.1016/j.mri.2015.02.005>.
- Suchyta, M.A., Sabbagh, M.D., Morsy, M., Mardini, S., Moran, S.L., 2016. Advances in peripheral nerve regeneration as it relates to VCA. *Vascularized Compos. Allografts* 3 (1-2), 75–88.
- Tustison, N.J., Cook, P.A., Klein, A., Song, G., Das, S.R., Duda, J.T., Kandel, B.M., van Strien, N., Stone, J.R., Gee, J.C., Avants, B.B., 2014. Large-scale evaluation of ANTs and FreeSurfer cortical thickness measurements. *Neuroimage* 99, 166–179.
- van den Boom, M., Miller, K.J., Gregg, N.M., Ojeda Valencia, G., Lee, K.H., Richner, T.J., Ramsey, N.F., Worrell, G.A., Hermes, D., 2021. Typical somatomotor physiology of the hand is preserved in a patient with an amputated arm: An ECoG case study. *Neuroimage Clin.* 31, 102728.
- Wall, J.T., Kaas, J.H., Sur, M., Nelson, R.J., Felleman, D.J., Merzenich, M.M., 1986. Functional reorganization in somatosensory cortical areas 3b and 1 of adult monkeys after median nerve repair: possible relationships to sensory recovery in humans. *J. Neurosci.* 6 (1), 218–233.
- Yang, T.T., Gallen, C.C., Ramachandran, V.S., Cobb, S., Schwartz, B.J., Bloom, F.E., 1994. Noninvasive detection of cerebral plasticity in adult human somatosensory cortex. *Neuroreport* 5 (6), 701–704. <https://doi.org/10.1097/00001756-199402000-00010>.