

# Early and long-term results of pectoralis muscle flap reconstruction versus sternal rewiring following failed sternal closure<sup>†</sup>

Jacob Zeitani<sup>a,\*</sup>, Eugenio Pompeo<sup>b</sup>, Paolo Nardi<sup>a</sup>, Gianluigi Sergiacomi<sup>c</sup>, Mattia Scognamiglio<sup>a</sup>,  
Giovanni Chiariello<sup>a</sup>, Costantino Del Giudice<sup>c</sup>, Chiara Arganini<sup>c</sup>, Giovanni Simonetti<sup>c</sup> and Luigi Chiariello<sup>a</sup>

<sup>a</sup> Division of Cardiac Surgery, Fondazione Policlinico Tor Vergata, Tor Vergata University of Rome, Rome, Italy

<sup>b</sup> Division of Thoracic Surgery, Fondazione Policlinico Tor Vergata, Tor Vergata University of Rome, Rome, Italy

<sup>c</sup> Department of Diagnostic Imaging, Molecular Imaging, Interventional Radiology, Fondazione Policlinico Tor Vergata, Tor Vergata University of Rome, Rome, Italy

\* Corresponding author. Tor Vergata University of Rome, Viale Oxford 81, 00133 Rome, Italy. E-mail: zeitani@hotmail.com (J. Zeitani).

Received 13 September 2012; received in revised form 19 November 2012; accepted 26 November 2012

## Abstract

**OBJECTIVES:** The aim of the study was to compare early and long-term results of pectoralis muscle flap reconstruction with those of sternal rewiring following failed sternal closure. Primary outcomes of the study were survival and failure rate. Respiratory function, chronic pain and quality of life were also evaluated.

**METHODS:** In a propensity-score matching analysis, of 94 patients who underwent sternal reconstruction, 40 were selected; 20 underwent sternal reconstruction with bilateral pectoralis muscle flaps (Group 1) and 20 underwent sternal rewiring (Group 2). Survival and failure rates were evaluated by in-hospital records and at follow-up. Respiratory function measures, including vital capacity (VC), were evaluated both by spirometry and computed tomography (CT) volumetry. Chronic pain was evaluated by the visual analogue pain scale.

**RESULTS:** At 85 ± 24 months of follow-up, survival and procedure failure were 95 and 90% in Group 1 and 60 and 55% in Group 2, respectively ( $P < 0.01$ , for both comparisons). Based on CT-scan volumetry, in Group 1, severe non-union and hemisternal paradoxical movement occurred less frequently (2 vs 7,  $P = 0.01$ ). At spirometry assessment, postoperative VC was greater in Group 1 ( $3220 \pm 290$  vs  $3070 \pm 290$  ml,  $P = 0.04$ ). The same trend was detected by CT-scan in-expiratory measures ( $4034 \pm 1800$  vs  $3182 \pm 862$  mm<sup>3</sup>,  $P < 0.05$ ). Correspondingly, in Group 1, less patients presented in NYHA Class III ( $P < 0.05$ ), and both chronic persistent pain score and physical health quality-of-life score were significantly better in the same group.

**CONCLUSIONS:** In our study, muscle flap reconstruction guaranteed better early and late-term results as shown by lower rates of mortality, procedure failure and hemisternum stability. Moreover, Group 1 patients had greater postoperative VC, lower NYHA class and better quality of life. These results suggest that, in patients with multiple bone fracture, the rewiring approach does not promote physiological bone consolidation, whereas the muscle flap reconstruction can assure more physiological ventilatory dynamics.

**Keywords:** Sternal wound dehiscence • Pectoralis muscles • Respiratory function

## INTRODUCTION

Sternal wound dehiscence following cardiac surgery occurs in ~10% [1–3] if all complications are taken into account, including persisting chest pain, superficial and deep wound dehiscence and mediastinitis, where the latter is characterized by high morbidity and mortality rates [4–5]. The risk of such complications appears to increase seriously in patients with known risk factors, such as diabetes mellitus, obesity or chronic obstructive pulmonary disease [6–10]. The persistent incidence of wound-healing problems is likely to be related to the profile of the patients undergoing cardiac surgery procedures today when compared with that of earlier periods. Indeed, the average age of patients

undergoing cardiac surgery procedures has risen steadily; mostly characterized by more known risk factors. The European Association for Cardio-Thoracic Surgery Database Report, published in 2005, (period of the current study) highlights this trend of progressively increasing age and concomitant risk factors. According to the report, the proportion of all patients over the age of 75 has risen from 4.8 in 1994 to 18.7% in 2003, almost a 3-fold increase; where the mean age of patients who underwent coronary artery bypass procedures in 1994 was 61 years, increasing to 66 years in the year 2003; in the same period, the percentage of patients who suffered from diabetes mellitus increased from 12 to 28% (European Adult Cardiac Surgical Database Report; [www.e-dendrite.com](http://www.e-dendrite.com)). This trend appears to continue according to the European data base published in 2010 (EACTS Adult Cardiac Surgical Database Report 2010; [www.e-dendrite.com](http://www.e-dendrite.com)). Moreover, respiratory motion and particularly

<sup>†</sup>Presented at the 26th Annual Meeting of the European Association for Cardio-Thoracic Surgery, Barcelona, Spain, 27–31 October 2012.

coughing contribute additionally unfavourably to the patient's condition and slow the wound-healing process.

Several surgical techniques have been proposed to treat sternal dehiscence, including rewiring, titanium plates and sternum reconstruction, by means of muscles or omental flaps [11–15]. However, the impact of those techniques on early and late mortality, incidence of failure and respiratory function were poorly investigated.

The purpose of the study was to compare event-free survival, respiratory function, any worsening of sternal dehiscence and clinical outcome in patients who underwent either rewiring or muscle flap reconstruction for deep sternal wound dehiscence following cardiac surgical procedures performed in a 5-year period.

## MATERIALS AND METHODS

Between January 2002 and December 2006, 4420 patients underwent midline sternotomy for cardiac procedures. Of the operated patients (2652 CABG, 1105 valves, 663 others, procedures), 94 (2.1%) experienced sternum healing complications (45 patients with positive cultures, 1.1%) requiring surgical management by rewiring (66 patients) or muscle flap reconstruction (28 patients). For the study purpose, we selected, using the propensity score matching analysis (considering: age, gender, chronic obstructive pulmonary disease (COPD), body mass index, diabetes, preoperative left ventricular ejection fraction, infection and type of primary surgical procedure), a cohort of 40 patients to assess comprehensive results. Twenty patients underwent sternal reconstruction with bilateral pectoralis muscle flaps (Group 1) and 20 underwent sternal rewiring (Group 2). The outcomes evaluated included assessment of freedom from early and late mortality, freedom from failure of surgical repair and respiratory function by spirometry and computed tomography (CT) with cineticloop programme.

Instability of chest closure was defined as instability of the two rewired halves detected at palpation over the sternum during a brief alternating-arm extension exercise; additional deep-wound infection was diagnosed, according to the Guidelines for Prevention of Surgical Site Infection of the Hospital Infection Control Practices Committee [16]. In case of visual evidence of mediastinitis, isolation of an organism from culture of mediastinal tissue or fluid, fever or instability of the sternum associated with purulent drainage from the mediastinum, all patients underwent Vacuum Assisted Closure (VAC) therapy (KCI, Copenhagen, Denmark) and specific antibiotics therapy before wound reconstruction.

Chronic pain was defined as pain that persisted for >3 months beyond the time of the procedure and was evaluated by Visual Analogue pain Scale. Quality of life was also assessed by the short form-36 (SF-36) health survey questionnaire [17].

The study was approved by the Ethic Committee of the Tor Vergata University, and all patients gave a written informed consent.

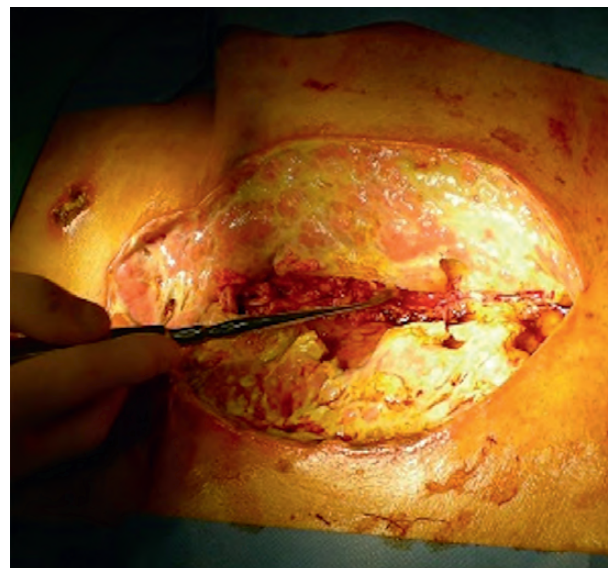
## Surgical procedure

The primary cardiac surgical procedure was performed after skin disinfection with 10% povidone-iodine and intravenous antibiotic prophylaxis with 2 g of Ceftriaxone, and sternotomy was

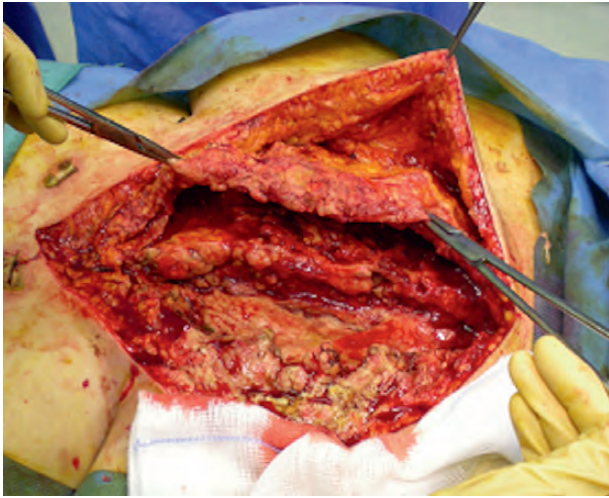performed with an oscillating saw. In patients who underwent CABG surgery with both internal thoracic arteries (ITAs), the conduits were harvested in a skeletonized fashion. Re-approximation of the sternum was then achieved by means of 6–10 (~1 for each 10 kg of patient weight) single interrupted stainless-steel wires, 2–3 through the manubrium and the others in the peristernal position at the intercostal spaces. The fascia and the subcutaneous layers were routinely closed with two continuous absorbable 0 polyglycolic acid (Dexon) suture lines and the skin with an intradermic absorbable 4-0 polyglycolic acid (Dexon) suture line.

In both study groups, wound reconstruction consisted in the resection of all devascularized and necrotic cutaneous, subcutaneous, bone and cartilage tissues. Wounds were then cleaned and rinsed with hydrogen peroxide, 10% povidone-iodine and saline water. In Group 1, pectoralis major muscles were partially mobilized. Briefly, the pectoralis major muscles were sectioned from their insertion to the sternum margins using electrocautery, and the internal mammary artery perforators branches were isolated and clipped. Then dissection of the muscle from the subcutaneous layer in the relatively avascular plane and from the chest wall until the midclavicle line was done so that the flap could be advanced to the mid-sternum without significant tension. Haemostasis should be carefully done to avoid excessive postoperative bleeding, particularly in patients who have received antiplatelets and or anticoagulation therapy. The two muscles flaps were then advanced to the midline, and the free margins were attached by means of interrupted absorbable 0 polyglycolic acid suture lines. However, if the gap between the two hemisternums was wide, to avoid dead space, at least one of the free flap margins should be advanced into the mediastinum. Two drains are placed in each hemisternum, one under the muscle flap and one under the subcutaneous layer. Another drain was placed between the hemisternums (Figs 1–3). In Group 2, to allow rewiring, adhesions between the chest wall and the heart were dissected. In this group, 6 patients underwent sternum reinforcement according to the Robicsek technique because of multiple bone fractures.

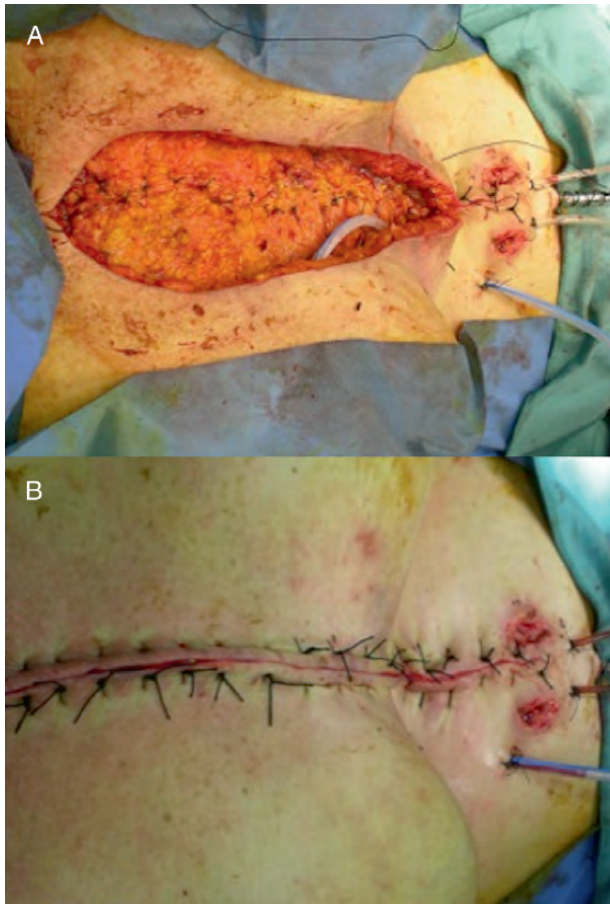
In all patient groups, direct closure of the subcutaneous and superficial layers was achieved by interrupted unabsorbable



**Figure 1:** Preoperative aspect of the wound showing sternum diastasis and extensive loss of tissue.



**Figure 2:** Detachment of the pectoralis muscle from the chest wall and from the subcutaneous layer.



**Figure 3:** Complete bilateral muscle flaps approximation and drainages placement in the mediastinum and subcutaneous layer spaces (A) and complete wound closure by means of interrupted silk sutures (B).

number 2 silk sutures. Intravenous antibiotic prophylaxis with 2 g daily of Ceftizoxime for 48 h, or specific antibiotics, based on antibiogram was given and administered for a 4- to 6-week course postoperatively.

## Data collection

All patient in-hospital files were reviewed. Operative mortality included deaths occurring during hospitalization or within 30 days after sternal reconstruction. Patients were followed for  $85 \pm 24$  (range, 60–118 months). No patients were lost at follow-up. Late outcomes considered were survival, freedom from re-sternal reconstruction, respiratory function and quality of life, and data were recorded at the outpatient clinic visit or by telephone interview.

## Functional pulmonary tests during follow-up

In all surviving patients, respiratory function assessment included timed spirometry and plethysmography, with single-breath diffusing capacity for carbon monoxide (Vmax22; Sensor Medics, Yorba Linda, CA, USA) to evaluate forced expiratory volume in 1 s (FEV<sub>1</sub>), vital capacity (VC), FEV<sub>1</sub>/VC ratio and total lung capacity (TLC). Respiratory function tests were performed on the same day as the CT volumetry.

## Computed tomography assessment

Patients underwent a chest CT scan with a 64-row multidetector CT scanner (GE LightSpeed-64 row, Milwaukee, WI, USA) in the helical mode without intravascular administration of contrast medium. The patient also underwent a dynamic study with a cine-scan mode, standard reconstruction algorithm, with the display field of view focused on the sternum with a continuous scanning time set to evaluate sternum excursion during normal respiratory cycles.

## Post-processing and data analysis

Images were postprocessed using a thoracic volume computer-assisted reading in a dedicated suite (GE, Milwaukee, WI, USA). Dynamic study with a cine-scan mode analysis was performed by an experienced radiologist to describe sternum stability evaluating the presence of dehiscence, pseudoarthrosis and asymmetry.

Anterior-to-posterior rib cage excursion was employed as a measure of chest mechanical elasticity. It was calculated by subtracting the distance between the anterior wall of the T8 vertebra and the posterior face of the sternum evaluated in maximum expiration to that obtained at maximum inspiration.

An evaluation of the diaphragm dynamic was performed calculating the dome excursion during a deep breath.

In the assessment of lung dynamics, the lung volume calculated at end-inspiration was considered to reflect TLC, whereas that calculated at end-expiration was deemed to reflect the residual volume. VC was thus estimated also radiologically by subtracting the residual volume to the TLC.

## Statistical analysis

Statistical analysis was performed using the StatView 4.5 software package (Abacus Concepts, Berkeley, CA, USA). Categorical

variables were presented as frequencies and percentages, and continuous variables were expressed as means with standard deviations. To reduce the effect of treatment selection bias and potential confounding factors, we performed adjustments for the differences in the baseline characteristics by the use of propensity score matching. The propensity scores were estimated with multiple logistic regression analysis. For the development of the propensity score-matched pairs (a 1:1 match), the greedy 5-to-1 digit matching algorithm was used. After propensity score matching, the data of the two groups were compared with the paired *t*-test or the Mann-Whitney test for continuous variables. Categorical data were compared by means of  $\chi^2$  or Fisher's exact tests as appropriate. The relationship between variables has been assessed by the Spearman *R*.

Propensity score matching yielded 20 matched pairs of patients in whom there were no significant differences in baseline characteristics between the muscle flap group and sternum rewiring group.

Variables were presented as mean  $\pm$  1 standard deviation. Differences were considered significant at values of  $P < 0.05$ .

## RESULTS

Preoperative patient characteristics were not different for the two groups with similar incidences of deep sternal wound infection (Table 1).

Despite similar baseline characteristics, outcomes were more favourable for the muscle flap group (Table 2) with a significantly shorter hospitalization. Ten (50%) of the 20 patients treated by

**Table 1:** Preoperative patient characteristics

Variables	Pectoralis muscle flaps (Group 1, N = 20)	Rewiring (Group 2, N = 20)	P-value
Age, years, mean $\pm$ SD	65.7 $\pm$ 9.3	66.6 $\pm$ 8.8	0.7
Male gender, n (%)	18 (90)	16 (80)	0.5
BMI, kg/m <sup>2</sup> $\pm$ SD	28.4 $\pm$ 5.9	29.8 $\pm$ 3.5	0.7
COPD, n (%)	16 (80)	12 (60)	0.3
Smoke, n (%)	8 (40)	8 (40)	1
Hypertension, n (%)	12 (60)	14 (70)	0.6
Diabetes, n (%)	10 (50)	7 (35)	0.4
Chronic renal failure, n (%)	4 (20)	2 (10)	0.3
LVEF, mean value	53 $\pm$ 12	54 $\pm$ 10	0.7
LVEF $\leq$ 35%, n (%)	3 (15)	2 (10)	0.3
Primary surgical procedure, n (%)			
Isolated CABG	15 (75)	16 (80)	0.7
Bilateral ITA	7 (35)	9 (45)	0.4
Grafts per patient	2.8 $\pm$ 0.9	3.0 $\pm$ 0.8	0.1
Positive cultures, n (%)	9 (45)	10 (50)	0.6
<i>Staphylococcus aureus</i> , n	4	2	
<i>Staphylococcus epidermidis</i> , n	3	5	
Others, n	2	3	

BMI: body mass index; COPD: chronic obstructive pulmonary disease; LVEF: left ventricular ejection fraction; CABG: coronary artery bypass grafting; ITA: internal thoracic artery.

**Table 2:** Intra- and postoperative data<sup>a</sup>

Variables	Pectoralis muscle flaps (Group 1, n = 20)	Rewiring (Group 2, n = 20)	P-value
Window to revision, days	70 $\pm$ 127	52 $\pm$ 92	0.06
Operative time, min	54.3 $\pm$ 28.3	57.6 $\pm$ 24.2	0.5
Postoperative blood transfusion (no. units/patients)	1.8 $\pm$ 1.5	2.3 $\pm$ 3.5	0.2
Re-revision, n (%)	1 (5)	6 (30)	0.04
Postoperative stay, days	6.3 $\pm$ 6.8	11.3 $\pm$ 11.2	0.03
In-hospital mortality, n (%)	0	4 (20)	0.05
Procedural failure, n (%)	1 (5)	6 (30)	0.04

<sup>a</sup>The mean duration of follow-up: 86  $\pm$  25 in Group 1 vs 84  $\pm$  24 months in Group 2 ( $P = 0.8$ ).

**Table 3:** Postoperative respiratory function data

	Group 1	Group 2	P-value
FEV <sub>1</sub> (ml)	1560 $\pm$ 410	1425 $\pm$ 320	0.25
FEV <sub>1</sub> %	55 $\pm$ 18	49 $\pm$ 20	0.06
VC (ml)	3220 $\pm$ 290	3070 $\pm$ 290	0.04
VC%	86 $\pm$ 7.0	83 $\pm$ 9.0	0.07
FEV <sub>1</sub> /VC (%)	47 $\pm$ 9.0	46 $\pm$ 10	0.44
TLC (ml)	6590 $\pm$ 570	6780 $\pm$ 760	0.49
TLC%	103 $\pm$ 5.0	106 $\pm$ 6.0	0.20
DLCO%	65 $\pm$ 13	60 $\pm$ 14	0.30

FEV<sub>1</sub>: forced expiratory volume in 1 s; VC: forced vital capacity; TLC: total lung capacity; DLCO: diffusion for carbon monoxide.

rewiring had early major complications, including 4 deaths and 6 procedures failure. Operating time was similar.

The mean duration of follow-up was 86  $\pm$  25 in Group 1 vs 84  $\pm$  24 months in Group 2 ( $P = 0.8$ ). At the end of follow-up, cumulative actual survival and sternal procedure failure (including in-hospital outcomes) were 95 (1 death) and 90% (2 patients experienced procedure failure) in Group 1 and 60 (8 deaths) and 55% (9 patients required reoperation) in Group 2 ( $P < 0.01$ , for both comparisons). In Group 1, cause of death was congestive heart failure and in Group 2, sudden death ( $n = 3$ ), septic shock ( $n = 2$ ) and congestive heart failure ( $n = 3$ ).

Results of postoperative respiratory function assessment have shown similar results in FEV<sub>1</sub>, FEV<sub>1</sub>/VC, TLC and diffusion for carbon monoxide, whereas VC was found to be better in Group 1 patients (Table 3). In a similar manner, CT scan-estimated VC was also found to be greater in Group 1 (4034  $\pm$  1800 vs 3182  $\pm$  862 mm<sup>3</sup>,  $P < 0.05$ ), and a linear correlation was found when matching CT scan-estimated VC with respiratory function tests data ( $R = 0.82$ ,  $P < 0.00001$ ).

The mean values of the anterior-to-posterior rib cage, and diaphragmatic excursions, during breathing were not statistically different among study groups (Table 4).

In Group 2, severe non-union and hemisternal paradoxical movement was higher ( $P = 0.01$ ; Fig. 4).

In Group 1, fewer patients presented in NYHA Class III-IV (2 vs 7 patients,  $P < 0.05$ ), chronic persistent chest pain was lower (2 vs 7 patients,  $P < 0.05$ ) and physical health score was better ( $67 \pm 17$  vs  $45 \pm 10$ ,  $P < 0.05$ ).

## DISCUSSION

Successful management of the dehiscenced sternum requires an appreciation of the underlying causes, particularly if infection has occurred. For complicated cases characterized by multiple bone fractures and wound contamination, the optimal management remains controversial, and several techniques have been reported [11–14]. Of those, sternum re-approximation and muscle, or omentum, flaps are the most commonly used [11–15, 18].

To rewire the sternum, often adhesions should be dissected, increasing the risk of right ventricular injury, grafts lesions particularly when the right ITA is used in cross-over method to the left anterior descending artery. Moreover, adhesion dissection is time consuming and may increase chest wall instability. Frequently, the hemisternums present complete and partial fractures, making it more difficult to obtain sternum stability. In severe multiple sternum fractures, sternal reinforcement is often required. Indeed, in the current study, in the rewiring group, 6 (30%) patients underwent Robicsek reinforcement. However, in a biomechanical test of different sternal closure techniques

performed by Losanoff *et al.* [19], the Robicsek technique failed to guarantee stability and increased lateral displacement when compared with unreinforced models. Quality of the bone (i.e. osteoporosis), and eventually paramedian sternotomy previously performed, might negatively affect rewiring repair [20]. Excessive hemisternums instability might result in flail chest. In our study, the incidence of hemisternal paradoxical movement was higher in the rewiring group with worse NYHA class. Considering the patient population with high incidence of COPD, this additional unfavourable condition may have a detrimental effect on respiratory function.

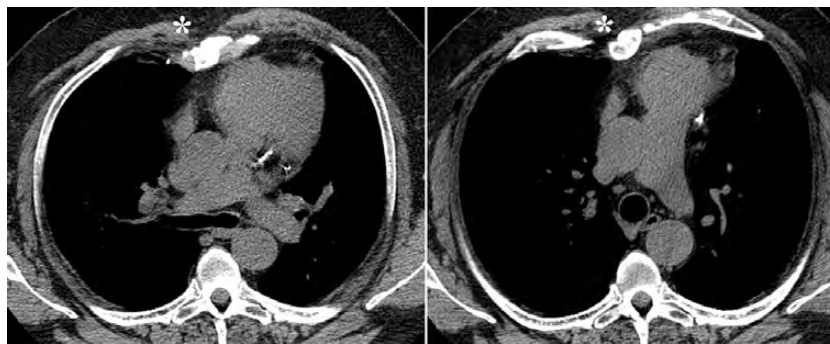Also, persistence of foreign materials and, in particular, sternal wires might favour bacterial colonization, and difficult eradication increases the risk of late infection and procedure failure. In our study, failure of sternal wound repair was significantly related to the persistence of infection. It should be emphasized that all patients with positive cultures were previously treated by VAC therapy and at the time of sternal wound closure, were considered, based on laboratory data and clinical status, free from active infection [21, 22].

In comparison with the rewiring technique, the use of flaps and, in particular, muscles presents several advantages. There is no need for adhesions dissection and thus, no risk for vital structures and sternum instability is avoided. Also, dead space between the hemisternums bone is filled by vascularized tissue, promoting wound healing. Milano *et al.* [23] compared the omental flap and pectoralis flap for post-sternotomy mediastinitis with specific regard to obtaining a healed wound. They found that the omentum flap had a lower mortality and improved the early outcome; it seemed to be a more effective therapy with no flap failure or local recurrence. The use of the omental flap in reconstructing the dehiscenced median sternotomy can be highly advantageous, because of its resistance to infection and its ability to fill large spaces. However, the use of the omentum requires a laparotomy with the possible risk of peritoneal cavity infection, late bowel obstruction and risk of hernia formation.

Latissimus dorsi or rectus abdominis muscles can also be used. These large muscles flap have an excellent blood supply and can be used to cover large defects. However, the procedure is more demanding and, therefore, less frequently performed [24]. Partial pectoralis muscles mobilization avoids the reported complications when the omentum or other muscles flaps have been used. In particular, this muscle flap might be used also in patients who underwent myocardial revascularization using one or both thoracic mammary arteries, because blood supply is

**Table 4:** Chest dynamic evaluation during breathing

Variables	Pectoralis muscle flaps (Group 1, n = 19)	Rewiring (Group 2, n = 12)	P-value
Antero-posterior rib cage excursion, mm	$5.4 \pm 3.8$	$4.9 \pm 8.2$	0.5
Left diaphragmatic excursion, mm	$18.6 \pm 15.1$	$20.3 \pm 16.4$	0.8
Right diaphragmatic excursion, mm	$27.2 \pm 15.0$	$22.8 \pm 14.0$	0.6
Hemisternal paradoxical movement, n (%)	2 (10)	7 (58)	0.01



**Figure 4:** Dynamic study with a cine-scan mode in axial view, during normal breath, on operated patient, showing the asymmetric movement of the chest and the sternum (\*).

preserved by the thoracoacromial artery. The surgical site remains localized in the chest, the procedure is not time consuming, and as reported in our experience, the surgical time was acceptable and was not different from the rewiring repair with satisfactory wound healing and long-term results.

Theoretically, the use of thoracic muscles for wound reconstruction might lead to impaired respiratory function due to greater chest rigidity. However, so far, the impact of different surgical techniques to repair the sternal wound dehiscence on chest motion and respiratory function had been poorly investigated. Kohman *et al.* [25] investigated the effects of pectoralis flap closure on pulmonary function, and they demonstrated that exercise tolerance and pulmonary function may not differ from a control group of cardiac surgical patients who did not experience wound complications.

In the present study, respiratory function measures were assessed postoperatively both by respiratory function tests and CT-scan volumetry. It is worth noting that the postoperative VC measure was better in the muscle flap group, and that radiologically calculated measures correlated linearly with those obtained by respiratory function tests. Although the lack of preoperative respiratory function data denied us the possibility of assessing pre- to postoperative changes in lung volumes, our study results suggest that better ventilatory dynamics were achieved following pectoralis muscle flap repair. Furthermore, as far as clinical results are concerned, Group 1 patients had better NYHA class and referred less chest pain and minor discomfort, which were reflected in a better quality of life.

Less chest pain and discomfort, as well as better respiratory function, might be related to superior chest stability since the incidence of severe non-union and hemisternum paradoxical movement was higher in the rewired group. Also, the muscle flaps are placed in the gap between the two hemisternums, avoiding bone friction, which can be the reason for less pain and discomfort, globally resulting in a better quality of life.

The study presents some limitations, including retrospective data collection, however, to limit the bias, a propensity match score 1:1 was used to select the patient groups. This method of selection guaranteed homogeneous preoperative characteristics, but reduced the sample size. Nevertheless, in our analysis, we have found significant differences in several outcome measures, which suggest a superior efficacy of the muscle flap repair in comparison with the rewiring method.

Considering that the positive culture could be the predominant risk factor for negative early and late outcomes, the incidence was similar in both groups.

In conclusion, our study suggests that partial pectoralis muscle flap to treat delayed sternal dehiscence can be performed safely with satisfactory early and late results. Apparently, the use of pectoralis muscle to repair sternal dehiscence not only had a minor impact on overall lung dynamics, but also improved chest stability in comparison with the rewiring technique. The latter should be carefully considered when infection is detected.

**Conflict of interest:** none declared.

## REFERENCES

- [1] Julian OC, Lopez-Belio M, Dye WS, Javid H, Grove WJ. The median sternal incision in intracardiac surgery with extracorporeal circulation: a general evolution of its use in heart surgery. *Surgery* 1957;42:753-61.
- [2] The Parisian Mediastinitis Study Group. Risk factors for deep sternal wound infection after sternotomy: a prospective multicenter study. *J Thorac Cardiovasc Surg* 1996;111:1200-7.
- [3] Ridderstolpe L, Gill H, Granfeldt H, Ahlfeldt H, Rutberg H. Superficial and deep sternal wound complications: incidence, risk factors and mortality. *Eur J Cardiothorac Surg* 2001;20:1168-75.
- [4] Loop FD, Lytle BW, Cosgrove DM, Mahfood S, McHenry MC, Goormastic M *et al.* Sternal wound complications after isolated coronary artery bypass grafting: early and late mortality, morbidity, and cost of care. *Ann Thorac Surg* 1990;49:179-87.
- [5] Kouchoukos NT, Wareing TH, Murphy SF, Pelate C, Marshall WG. Risks of bilateral internal mammary artery bypass grafting. *Ann Thorac Surg* 1990;49:210-19.
- [6] Jonkers D, Elenbaas T, Terporten P, Nieman F, Stobberingh E. Prevalence of 90-days postoperative wound infections after cardiac surgery. *Eur J Cardiothorac Surg* 2003;23:97-102.
- [7] De Paulis R, de Notaris S, Scaffa R, Nardella S, Zeitani J, Del Giudice C *et al.* The effect of bilateral internal thoracic artery harvesting on superficial and deep sternal infection: The role of skeletonization. *J Thorac Cardiovasc Surg* 2005;129:536-43.
- [8] Seyfer AE, Shriver CD, Miller GM, Graeber GM. Sternal blood flow after median sternotomy and mobilization of the internal mammary arteries. *Surgery* 1988;104:899-904.
- [9] El Oakley RM, Wright JE. Postoperative mediastinitis: classification and management. *Ann Thorac Surg* 1996;61:1030-6.
- [10] Bitkover CY, Gardlund B. Mediastinitis after cardiovascular operations: a case-control study of risk factors. *Ann Thorac Surg* 1998;65:36-40.
- [11] Klesius AA, Dzembali O, Simon A, Kleine P, Abdel-Rahman U, Herzog C *et al.* Successful treatment of deep sternal infections following open heart surgery by bilateral pectoralis major flaps. *Eur J Cardiothorac Surg* 2004;25:218-23.
- [12] Graeber GM, Langenfeld J. Chest wall resection and reconstruction. In: Franco H, Putman JB (eds). *Advanced Therapy in Thoracic Surgery*. London: BC Decker, Inc., 1998, 175-85.
- [13] Monsour KA, Mellitt RJ. Optimal management of sternal wound infection. In: Franco H, Putman JB (eds). *Advanced Therapy in Thoracic Surgery*. London: BC Decker, Inc., 1998, 186-9.
- [14] Graeber GM. Chest wall resection and reconstruction. *Semin Thorac Cardiovasc Surg* 1999;11:251-63.
- [15] van Wingerden JJ, Lapid O, Boonstra PW, de Mol JA. Muscle flaps or omental flap in the management of deep sternal wound infection. *Interact CardioVasc Thorac Surg* 2011;13:179-88.
- [16] Mangram AJ, Horan TC, Pearson ML, Silver LC, Jarvis WR. Guideline for prevention of surgical site infection, 1999. hospital infection control practices advisory committee. *Infect Control Hosp Epidemiol* 1999;20:250-78.
- [17] Ware JE, Sherbourne CD. The MOS 36-item short-form health survey (SF-36). I. Conceptual framework and item selection. *Med Care* 1992;30:473-83.
- [18] Merrill WH, Akhter SA, Wolf RK, Schneeberger EW, Flege JB Jr. Simplified treatment of postoperative mediastinitis. *Ann Thorac Surg* 2004;78:608-12.
- [19] Losanoff JE, Collier AD, Wagner-Mann CC, Richman BW, Huff H, Hsieh F *et al.* Biomechanical comparison of median sternotomy closures. *Ann Thorac Surg* 2004;77:203-9.
- [20] Zeitani J, Penta de Peppo A, Moscarelli M, Guerrieri Wolf L, Scafuri A, Nardi P *et al.* Influence of sternal size and inadvertent paramedian sternotomy on stability of the closure site: a clinical and mechanical study. *J Thorac Cardiovasc Surg* 2006;132:38-42.
- [21] Gustafsson R, Johnsson P, Algotsson L, Blomquist S, Ingemansson R. Vacuum-assisted closure therapy guided by C-reactive protein level in patients with deep sternal wound infection. *J Thorac Cardiovasc Surg* 2002;123:895-900.
- [22] Sjogren J, Malmsjo M, Gustafsson R, Ingemansson R. Poststernotomy mediastinitis: a review of conventional surgical treatments, vacuum-assisted closure therapy and presentation of the Lund University Hospital mediastinitis algorithm. *Eur J Cardiothorac Surg* 2006;30:898-905.
- [23] Milano CA, Georgiade G, Muhlbaier LH, Smith PK, Wolfe WG. Comparison of omental and pectoralis flaps for poststernotomy mediastinitis. *Ann Thorac Surg* 1999;67:377-80.
- [24] Dejesus RA, Paletta JD, Dabb RW. Reconstruction of the median sternotomy wound dehiscence using the latissimus dorsi myocutaneous flap. *J Cardiovasc Surg* 2001;42:359-64.
- [25] Kohman LJ, Auchincloss JH, Gilbert R, Beshara M. Functional results of muscle flap closure for sternal infection. *Ann Thorac Surg* 1991;52:102-6.

## APPENDIX. CONFERENCE DISCUSSION

**Dr P. Rajesh** (Birmingham, UK): This study deals with a fairly debilitating condition, which is sternal infection and sternal dehiscence. From your manuscript, I noticed that 94 patients, which is 2.1% of your patient population, had sternal healing problems. Have you learned from this study whether there are any other factors that have contributed to this sternal problem in your patient population, i.e. any preoperative factors, any variation in theatre preparations, any problems with surgeons? What you haven't told us is whether this study has been done looking at only one surgeon or whether there were two or more surgeons involved in the operative strategy. As a result of this, have you changed your strategy in trying to close the sternum to reduce that 2.1% infection rate? That's my first question.

The second question, you chose 40 patients, 20 in each arm, for your propensity matching, but do you have any data on the other 54 patients as to what happened to them?

**Dr Zeitani:** First, we are an academic university centre in Rome, therefore there are several surgeons and also assistants who are in their learning curve. There is no doubt that the patients who are undergoing surgery nowadays are older, sicker, and they have more comorbidities, which might increase the risk for sternal wound dehiscence.

**Dr Rajesh:** Have you changed any strategy? For instance, have you looked at a group of surgeons having more infection compared to another group of surgeons? Is there anything colonized, anybody having anything growing by doing any swabs?

**Dr Zeitani:** Well, the total infection rate in our experience is less than 1%.

**Dr Rajesh:** In short, 2.1%.

**Dr Zeitani:** That was the global group with sternal healing complications, but not all of them had infection. Around 50% in the matched population were in both groups. However, the total infection, not the total sternal dehiscence, is less than 1%.

**Dr Rajesh:** The other 54 patients, what did you do with them?

**Dr Zeitani:** Eventually they went home.

**Dr Rajesh:** That's true, but what I want to know is whether there were any other treatment strategies. Did you use VAC pump? Did you just use antibiotics? What did you do with them?

**Dr Zeitani:** By the propensity score match, we had to exclude most of the patients. As you can see, there were more patients at the beginning who underwent rewiring and fewer patients who had the muscle flap; so we remained with the most important reason for wound dehiscence, infection, which affected 50% of the patients in both groups. Most of the other patients who were excluded from this study, I presume that they had no infection and therefore they were excluded by reason of not matching and they experienced wound healing following the treatment.

**Dr J.M. Wihlm** (Strasbourg, France): One word we didn't hear during all of your presentation is the word 'osteosynthesis.' It's strange, because the basis for joining two half-sternums, with or without infection, is to stabilize the horizontal distraction forces of these disrupted sternums, and there are many means of doing this. In other presentations and other papers we may read now, the muscle flaps and the wiring are not in opposition. The muscle flaps can add something to the wiring or to the osteosynthesis and do not represent an opposite alternative. So I don't clearly see the message you want to give us.

**Dr Zeitani:** If I understand you correctly, most patients who experience wound complications of the sternum will have partial or complete fractures of the bone; therefore, they should undergo reinforcement of the sternum in order to be able to rewire it, otherwise it would be difficult to do so. Losanoff in one of his biomechanical studies could show that the Robicsek technique, although well established, as well as different reinforcement techniques which were published by others, doesn't guarantee a complete or better reinforcement, and still allows the lateral displacement of the sternum. When we already rewired the sternum, I wouldn't see the sense of mobilizing the muscle flaps, which can also be done. However, in this work we could show that sternal fixation *per se* does not guarantee better respiratory function. On the contrary, we could see that the percentage of flail chest, which led later on to worse inspiratory and expiratory function, was higher in the rewiring group.

**Dr Wihlm:** Again, I was told when I was a very young student that when you have a fracture, you do an osteosynthesis, but I think things change with time.