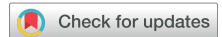

## NEW TECHNOLOGY

# A Dual-Lumen Extracorporeal Membrane Oxygenation Cannulation Technique Using a Mobile X-Ray Device



Thomas Schweiger, MD, PhD, Florian Ponholzer, MD, Daria Kifjak, MD, Stefan Schwarz, MD, Alberto Benazzo, MD, György Lang, MD, PhD, Edda Tschernko, MD, Klaus Markstaller, MD, and Konrad Hoetzenecker, MD, PhD

Department of Thoracic Surgery, Medical University of Vienna, Vienna, Austria; Department of Visceral, Transplant, and Thoracic Surgery, Center of Operative Medicine, Medical University of Innsbruck, Innsbruck, Austria; Department of Biomedical Imaging and Image-Guided Therapy, Medical University of Vienna, Vienna, Austria; Division of Cardiac, Thoracic, and Vascular Anesthesia and Intensive Care Medicine, Department of Anesthesia, Intensive Care Medicine, and Pain Medicine, Medical University of Vienna, Vienna, Austria; Division of General Anesthesia and Intensive Care Medicine, Department of Anesthesia, Intensive Care Medicine, and Pain Medicine, Medical University of Vienna, Vienna, Austria; and Department of Radiology, University of Massachusetts Chan Medical School/UMass Memorial Health Care, Worcester, Massachusetts

## ABSTRACT

**PURPOSE** Dual-lumen extracorporeal membrane oxygenation (ECMO) cannulation is considered technically challenging and harbors the risk of potential life-threatening complications during cannulation. Dual-lumen cannula insertion is performed under either ultrasound or fluoroscopy guidance. Both techniques have significant disadvantages, such as examiner dependence or the necessity for transportation of the patient from the intensive care unit to the operating room.

**DESCRIPTION** Digital, mobile x-ray devices provide a novel, examiner-independent imaging modality for bedside dual-lumen ECMO cannulation.

**EVALUATION** From November 2019 to November 2021, 23 dual-lumen cannulations were performed in 20 patients at the Department of Thoracic Surgery, Medical University of Vienna. Twelve of 23 (52.2%) were inserted in the intensive care unit using a mobile x-ray device. The remaining patients (47.8%) were cannulated in the operating room with conventional fluoroscopy guidance. In none of the procedures did cardiovascular injuries occur. Insertion site bleeding was the most common ECMO-related complication (n = 2).

**CONCLUSIONS** Dual-lumen cannulation using sequential x-rays can be performed safely. Especially for infectious patients or patients who require an awake ECMO, this technique overcomes disadvantages of established imaging modalities.

(Ann Thorac Surg 2022;114:1050-4)

© 2022 The Authors. Published by Elsevier Inc on behalf of The Society of Thoracic Surgeons.  
This is an open access article under the CC BY license (<http://creativecommons.org/licenses/by/4.0/>).

## TECHNOLOGY

Dual-lumen cannulas are today part of the standard armamentarium at most major extracorporeal membrane oxygenation (ECMO) centers.<sup>1-4</sup> That is especially true for lung transplantation centers, as the single-site, dual-lumen

cannulation facilitates mobilization and an awake or ambulatory ECMO bridge-to-transplant setting. However, the cannulation procedure itself is considered more challenging compared with standard, single-lumen cannulas. Rare, but severe complications such as cardiac perforation and pericardial tamponade have been

Accepted for publication Apr 10, 2022.

Address correspondence to Dr Hoetzenecker, Department of Thoracic Surgery, Medical University of Vienna, Waehringer Guertel 18-20, Vienna 1090, Austria; email: [konrad.hoetzenecker@meduniwien.ac.at](mailto:konrad.hoetzenecker@meduniwien.ac.at).

reported in the literature as well as to the Extracorporeal Life Support Organization database and the Food and Drug Administration.<sup>5,6</sup> Two techniques have been described to guide the introduction of a dual-lumen cannula. Fluoroscopy provides an excellent overview but its availability is limited to the operating room or angiography suite. Transthoracic or transesophageal sonography can be performed at the patient's bedside but is highly examiner dependent. Both techniques with their inherent advantages and disadvantages appear to be feasible and safe in experienced hands (Table 1).<sup>7,8</sup> However, the ubiquitous availability of digital bedside x-ray devices at our institution fostered the development of a novel bedside cannulation technique that overcomes most disadvantages of the originally described techniques.

Herein, we describe the technique of bedside, dual-lumen ECMO cannulation guided by sequential x-rays in the intensive care unit (ICU) and the first clinical experience with this procedure.

## TECHNIQUE

Cannulation using the Crescent cannula (Medtronic) and a digital, mobile x-ray device (MobileDaRt Evolution [Shimadzu Corporation] or DR-XD 1000 [Fujifilm Corporation]) was carried out in Seldinger technique in the ICU (Figure 1). Ideally, the team consisted of two surgeons, an ICU physician, a scrub nurse, a perfusionist, and a radiology technologist. General measures for reducing radiation exposure were applied. The team was equipped with radiation protection aprons.

After washing and draping the neck, the right internal jugular vein was punctured and a guidewire (Back-up Meier J-Tip, 0.035 inch diameter, 185 cm length; Boston Scientific) was introduced. In awake patients, infiltration with local anesthesia (lidocaine 2%) at the puncture site was performed. In addition, sedoanalgesia was administered to anxious patients during the cannulation procedure. In case of a previously inserted central venous line in the right internal jugular vein, the central venous line was used to introduce the guidewire. The guidewire should traverse the superior vena cava, the right atrium, and the inferior vena cava. Usually, this was characterized by a smooth introduction of approximately 35 cm without the slightest resistance. Furthermore, ventricular complexes in the electrocardiogram might indicate a dislocation of the guidewire to the ventricle. The correct position of the guidewire was then confirmed by the first x-ray film (Figure 2A). Any loops or malpositioning of the guidewire in the heart or the hepatic veins were excluded. After that, 50 units/kg bodyweight heparin was administered. Making an appropriately sized skin incision, either serial dilations with increasing dilator

sizes or the unisize dilator included in the cannulation set was used. Before introducing the cannula, the position of the guidewire was once again confirmed using the x-ray device. This final confirmation is of utmost importance as the guidewire might have dislocated during the dilations.

The dual-lumen cannula was then introduced. During introduction of the cannula, special care was taken not to retrieve the guidewire or to push the guidewire together with the cannula. The correct position and depth were then confirmed by assessing the orientation of the radiopaque markers in relation to anatomic landmarks (Figure 2B). After removal of the guidewire and the introducer, the cannula was connected to the ECMO circuit and secured with three sutures and a head bandage. A final chest x-ray film was obtained to confirm the final position of the cannula (Figure 2C). In most cases, a total of four or five sequential x-ray films were sufficient for the whole cannulation procedure.

## CLINICAL EXPERIENCE

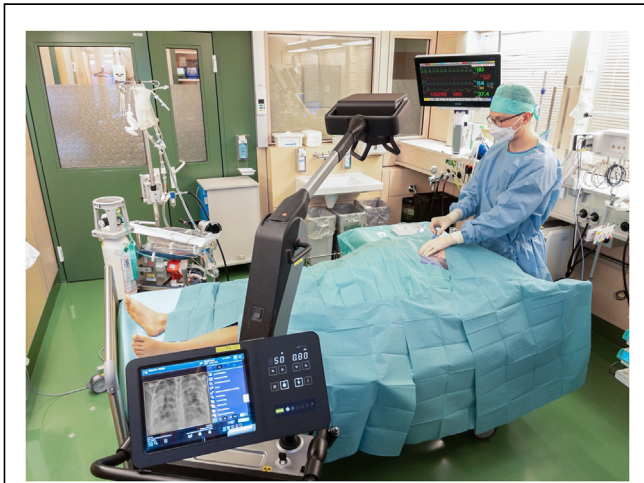Between November 2019 and November 2021, a total of 23 dual-lumen cannulation procedures were performed in 20 patients (Table 2). In 12 procedures (52.2%), the novel bedside technique using a mobile x-ray device was applied. In the majority of cases, the indication for ECMO was a bridge to transplantation (65.2%). That was followed by acute respiratory distress syndrome (21.7%); of those, 2 patients had COVID-19 acute respiratory distress syndrome. All of the cannulation procedures using the mobile x-ray device were performed bedside in the ICU, whereas all fluoroscopy-guided procedures required transportation of the patient to the operating room. Of note, 47.8% of ECMO runs were in a non-intubated setting. The median time on ECMO support was 8 days (range, 0-44).

Minor complications occurred in 21.5% of the ECMO runs (Table 3), with similar incidence in both

**TABLE 1 Possible Advantages and Disadvantages of Various Imaging Techniques for Dual-Lumen Cannulation**

Variables	TTE	TEE	Fluoroscopy	Mobile X-Ray Device
Anatomic overview	No	No	Yes	Yes
Avoidance of radiation	Yes	Yes	No	No
Cannulation in awake patient	Yes	No	Yes	Yes
Cannulation in intensive care unit	Yes	Yes	No	Yes
Continuous visual feedback	Yes	Yes	Yes	No
Independent of examiner skills	No	No	Yes	Yes
Visualization of cannula outflow	Yes	Yes	Yes/no	Yes

TEE, transesophageal echocardiography; TTE, transthoracic echocardiography.



**FIGURE 1** Dual-lumen cannulation using mobile x-ray device in intensive care unit. The x-ray device display is usually turned to the operating team.

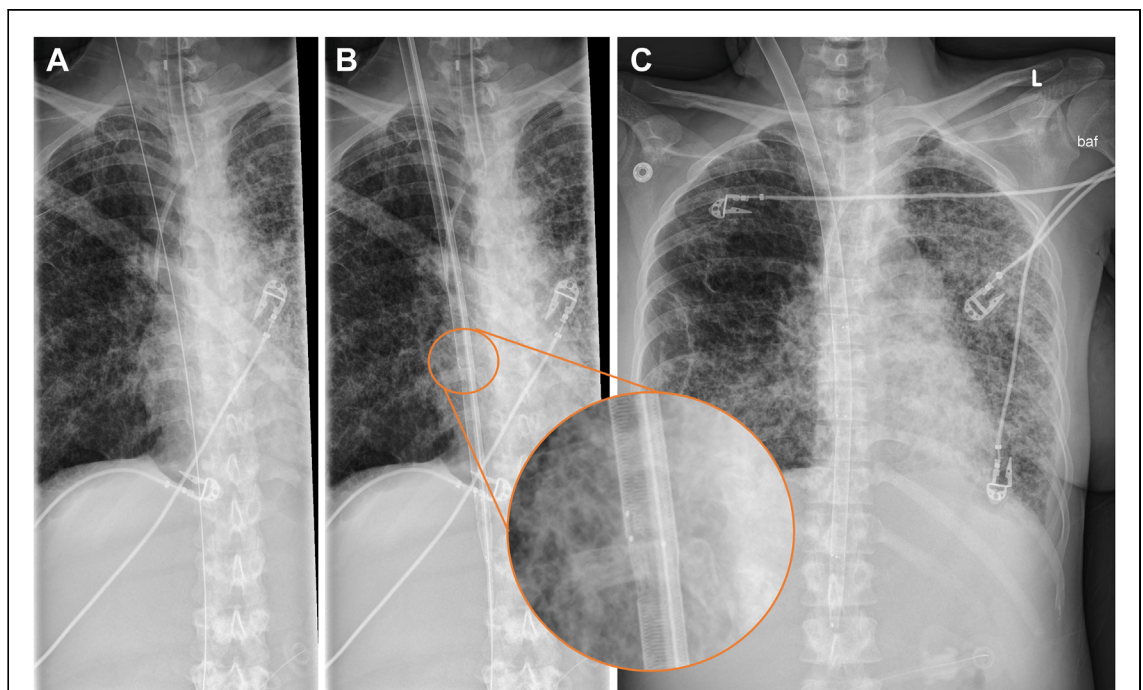
patients died of multiorgan failure during ECMO support. No cannulation-related deaths occurred.

#### COMMENT

In our opinion, the herein described technique using a mobile x-ray device has several advantages and allows a safe bedside insertion of a dual-lumen cannula in the ICU.

A repeatedly reported, potentially fatal error is an intracardiac loop of the guidewire despite verification of the guidewire in the inferior vena cava by sonography. There is a very high likelihood that introduction of the cannula leads to a cardiac injury in this situation. We believe, so far, only fluoroscopy is capable of fully excluding this error. Using fluoroscopy or x-ray films, the correct placement of the guidewire and the cannula in their entire continuity can be objectified, documented, and stored by the surgical team (Table 1). In contrast to ultrasound-guided techniques, that supersedes any dependency on the skills of the examiner and thereby removes a major potential pitfall in dual-lumen cannulation. In comparison with fluoroscopy, which is usually not available in the ICU, the wide-spread use of digital, mobile x-ray devices avoids transportation of these highly critically ill and sometimes infectious

cannulation groups ( $n = 2$  for fluoroscopy, and  $n = 3$  for mobile x-ray device). One major ECMO complication was a hepatic vein thrombosis despite correct cannula position. Cardiovascular injury or cardiac tamponade did not occur in any of 23 cannulation procedures. Three



**FIGURE 2** Sequentially obtained x-ray films during dual-lumen cannulation. (A) Correct placement of guidewire in inferior vena cava without loops is confirmed. (B) Depth and orientation of dual-lumen cannula is verified by radiopaque markers (insert). (C) Final x-ray film confirms correct position of cannula after fixation and excludes pneumothorax.

**TABLE 2 Clinical Characteristics of 23 Cannulation Procedures in 20 Patients**

Characteristics	Total Procedures (n = 23)	Fluoroscopy (n = 11)	Mobile X-Ray Device (n = 12)	P Value
Age, y	48 (20-67)	56 (20-67)	43 (22-63)	.060
Sex				1
Male	13 (56.5)	6 (54.5)	7 (58.3)	
Female	10 (43.5)	5 (45.5)	5 (41.7)	
Indication				.184
Bridge-to-transplant	15 (65.2)	8 (72.7)	7 (58.3)	
ARDS	5 (21.7)	1 (9.1)	3 (25)	
Airway surgery	2 (8.7)	2 (18.2)	0 (0)	
Acute rejection after LTx	1 (4.3)	0 (0)	1 (8.3)	
Implantation				<.001
Intensive care unit	12 (52.2)	0 (0)	12 (100)	
Operating room	11 (47.8)	11 (100)	0 (0)	
ECMO bridging				.220
Intubated	12 (52.2)	4 (36.4)	8 (66.6)	
Not intubated	11 (47.8)	7 (63.6)	4 (33.3)	
Cannula type				.684
Crescent 28F	12 (52.2)	5 (45.5)	7 (58.3)	
Crescent 30F	11 (47.8)	6 (54.5)	5 (41.7)	
Insertion site				1
Right jugular	20 (87)	10 (90.9)	10 (83.3)	
Left jugular	3 (13)	1 (9.1)	2 (16.6)	
Study period				.027
First year	7 (30.4)	6 (54.5)	1 (8.3)	
Second year	16 (69.6)	5 (45.5)	11 (91.7)	
Duration ECMO support, d	8 (0-44)	6 (0-15)	12 (1-44)	.079

Values are median (interquartile range) or n (%). ARDS, acute respiratory distress syndrome; ECMO, extracorporeal membrane oxygenation; LTx, lung transplantation.

patients from the ICU to the operating room. Therefore, this novel technique proved to be especially valuable for patients with COVID-19 acute respiratory distress syndrome.

In our cohort, 65.2% of our patients were in a bridge-to-transplantation setting. Moreover, the vast majority of these patients were in an awake,

nonintubated state. In these nonintubated patients, transesophageal sonographic guidance is not possible. Moreover, transportation to the operating room for fluoroscopy-guided cannulation can be avoided. An advantage of ultrasound-guided insertions is still the visualization of the lateral outflow jet. However, using the latest generation of dual-lumen cannulas with

**TABLE 3 Extracorporeal Membrane Oxygenation-related Complications and Outcomes of 23 Cannulation Procedures in 20 Patients**

Complications and Outcomes	Total Procedures (n = 23)	Fluoroscopy (n = 11)	Mobile X-Ray Device (n = 12)	P Value
Major ECMO complication	1 (4.3)	1 (9.1)	0 (0)	.478
Cardiac tamponade	0 (0)	0 (0)	0 (0)	
Cardiovascular injury	0 (0)	0 (0)	0 (0)	
Thrombosis	1 (4.3)	1 (9.1)	0 (0)	
Minor ECMO complication	5 (21.7)	2 (18.2)	3 (25)	1
Insertion site bleeding	2 (8.7)	0 (0)	2 (16.6)	
Repositioning of cannula	1 (4.3)	0 (0)	1 (8.3)	
ECMO oxygenator clotting	1 (4.3)	1 (9.1)	0 (0)	
Other	1 (4.3)	1 (9.1)	0 (0)	
Death during ECMO support	3 (13)	0 (0)	3 (25)	.217
Multiorgan failure	3 (13)	0 (0)	3 (25)	

Values are n (%). ECMO, extracorporeal membrane oxygenation.

radiopaque markers, the visualization of these markers by fluoroscopy or chest x-ray film aids the correct positioning of the lateral jet. Supporting this, only one of dual-lumen cannula in the overall cohort required repositioning.

A rather theoretical limitation of both fluoroscopy and mobile x-ray devices compared with sonographic techniques is the exposure to radiation. Considering the number of radiologic examinations a patient with lung failure in the ICU receives, the exposure during cannulation is almost negligible. Lastly, the mobile x-ray technique does not provide continuous visual feedback. Retrieving the guidewire during introduction of the cannula or pushing the guidewire together with the cannula might result in dislocation or kinking. Additional x-ray films or simultaneous ultrasonography might be considered. However, in our experience, the visualization and confirmation of the key steps during cannulation makes any visual feedback between these steps obsolete.

In summary, we believe that the advantages and the safety provided by the mobile x-ray technique are superior to the other described techniques. Consequently, at our department, the mobile x-ray technique has

evolved to be the primary strategy for dual-lumen ECMO cannulation.

#### FREEDOM OF INVESTIGATION

The tested equipment was purchased for the study. The authors had full control of the design of the study, methods used, outcome parameters, analysis of data, and production of the written report.

#### DISCLAIMER

The Society of Thoracic Surgeons, the Southern Thoracic Surgical Association, and *The Annals of Thoracic Surgery* neither endorse nor discourage the use of the new technology described in this article.

#### FUNDING SOURCES

The Department of Thoracic Surgery, Medical University Vienna, received an unrestricted research grant from Medtronic.

#### DISCLOSURES

Konrad Hoetzenecker and Thomas Schweiger serve as consultants for Medtronic.

#### REFERENCES

- Zwischenberger JB, Toomasian JM, Drake K, Andrews AF, Kolobow T, Bartlett RH. Total respiratory support with single cannula venovenous ECMO: double lumen continuous flow vs single lumen tidal flow. *Trans Am Soc Artif Intern Organs*. 1985;31:610-615.
- Benazzo A, Schwarz S, Frommlet F, et al. Twenty-year experience with extracorporeal life support as bridge to lung transplantation. *J Thorac Cardiovasc Surg*. 2019;157:2515-2525.e2510.
- Hakim AH, Ahmad U, McCurry KR, et al. Contemporary outcomes of extracorporeal membrane oxygenation used as bridge to lung transplantation. *Ann Thorac Surg*. 2018;106:192-198.
- Tipograf Y, Gannon WD, Foley NM, et al. A dual-lumen bicaval cannula for venovenous extracorporeal membrane oxygenation. *Ann Thorac Surg*. 2020;109:1047-1053.
- Johnson SM, Itoga N, Garnett GM, Kilcommons M, Puapong DP, Woo RK. Increased risk of cardiovascular perforation during ECMO with a bicaval, wire-reinforced cannula. *J Pediatr Surg*. 2014;49:46-49 [discussion: 49-50].
- Rubino A, Vuylsteke A, Jenkins DP, Fowles JA, Hockings L, Valchanov K. Direct complications of the Avalon bicaval dual-lumen cannula in respiratory extracorporeal membrane oxygenation (ECMO): single-center experience. *Int J Artif Organs*. 2014;37:741-747.
- Hemamalini P, Dutta P, Attawar S. Transesophageal echocardiography compared with fluoroscopy for Avalon bicaval dual-lumen cannula positioning for venovenous ECMO. *Ann Card Anaesth*. 2020;23:283-287.
- Fleet D, Morris I, Faulkner G, Harvey C. Experience with the Crescent<sup>®</sup> cannula for adult respiratory VV ECMO: a case series. *Perfusion*. Published online July 13, 2021. <https://doi.org/10.1177/02676591211031462>