

Myocardial Fibrosis Assessment Using T1 and ECV Mapping With Histologic Validation in Chronic Dilated Cardiomyopathy

Citation for published version (APA):

Raafs, A. G., Adriaans, B. P., Henkens, M. T. H. M., Verdonschot, J. A. J., Ramaekers, M. J. F. G., Gommers, S., Hamid, M. A. A., Schalla, S., Knackstedt, C., van Empel, V. P. M., Hans-Peter, B., Wildberger, J. E., Bekkers, S. C. A. M., & Hazebroek, M. R. (2022). Myocardial Fibrosis Assessment Using T1 and ECV Mapping With Histologic Validation in Chronic Dilated Cardiomyopathy. *JACC-Cardiovascular Imaging*, 15(10), 1828-1830. <https://doi.org/10.1016/j.jcmg.2022.05.002>

Document status and date:

Published: 01/10/2022

DOI:

[10.1016/j.jcmg.2022.05.002](https://doi.org/10.1016/j.jcmg.2022.05.002)

Document Version:

Publisher's PDF, also known as Version of record

Document license:

Taverne

Please check the document version of this publication:

- A submitted manuscript is the version of the article upon submission and before peer-review. There can be important differences between the submitted version and the official published version of record. People interested in the research are advised to contact the author for the final version of the publication, or visit the DOI to the publisher's website.
- The final author version and the galley proof are versions of the publication after peer review.
- The final published version features the final layout of the paper including the volume, issue and page numbers.

[Link to publication](#)

General rights

Copyright and moral rights for the publications made accessible in the public portal are retained by the authors and/or other copyright owners and it is a condition of accessing publications that users recognise and abide by the legal requirements associated with these rights.

- Users may download and print one copy of any publication from the public portal for the purpose of private study or research.
- You may not further distribute the material or use it for any profit-making activity or commercial gain
- You may freely distribute the URL identifying the publication in the public portal.

If the publication is distributed under the terms of Article 25fa of the Dutch Copyright Act, indicated by the "Taverne" license above, please follow below link for the End User Agreement:

www.umlib.nl/taverne-license

Take down policy

If you believe that this document breaches copyright please contact us at:

repository@maastrichtuniversity.nl

providing details and we will investigate your claim.

progression in patients with in-stent neoatherosclerosis. *Circ J.* 2020;84:1826-1836.

14. Kita Y, Watanabe M, Kamon D, et al. Effects of fatty acid therapy in addition to strong statin on coronary plaques in acute coronary syndrome: an optical coherence tomography study. *J Am Heart Assoc.* 2020;9:e015593.

15. Nishio R, Shinke T, Otake H, et al. Stabilizing effect of combined eicosapentaenoic acid and statin therapy on coronary thin-cap fibroatheroma. *Atherosclerosis.* 2014;234:114-119.

Myocardial Fibrosis Assessment Using T1 and ECV Mapping With Histologic Validation in Chronic Dilated Cardiomyopathy



Dilated cardiomyopathy (DCM) is a multifactorial disease characterized by myocardial fibrosis caused by genetic and environmental injuries. Fibrosis consists of: 1) focal, replacement fibrosis, as depicted by late gadolinium enhancement (LGE) cardiovascular magnetic resonance (CMR); and 2) diffuse, reactive fibrosis, which can be detected by T1 mapping.¹ Both LGE and T1 mapping indicate vulnerability to outcome.² The general belief is that focal fibrosis is irreversible whereas diffuse fibrosis is reversible, thereby making it an interesting treatment target.¹

Recent studies aiming to validate T1 mapping with histologic fibrosis show conflicting results regarding its utility.^{3,4} Because there is need for a noninvasive method to assess diffuse fibrosis, we evaluated the diagnostic accuracy of T1 and extracellular volume (ECV) measurements with diffuse histologic fibrosis in a large sample of well characterized, chronic, non-end-stage DCM patients.

The Maastricht Cardiomyopathy Registry is an ongoing registry that prospectively includes patients who meet the universal definition of DCM (excluding ischemic, valvular, hypertensive, congenital, hypertrophic, restrictive, peripartum, and arrhythmogenic cardiomyopathy, acute myocarditis, and presence of storage diseases). All patients gave written informed consent. From 2016 to 2019, 88 patients (mean age 54 ±12 years, 64 male) underwent CMR and endomyocardial biopsy (EMB) within a 3-month timespan. Each patient underwent 6 right ventricular biopsies. Histologic collagen volume fraction (CVF) was quantified as percentage of tissue positive for Picosirius red of the total myocardial area, excluding sub-endocardial and perivascular areas. The CMR protocol included LGE and pre- and post-contrast T1 mapping using a 3(2)3(2)5 modified look-locker inversion recovery sequence at 1.5-T. Regions of interest (ROIs) were drawn in the septum on mid-cavity short-axis maps, areas with LGE were excluded, and error maps

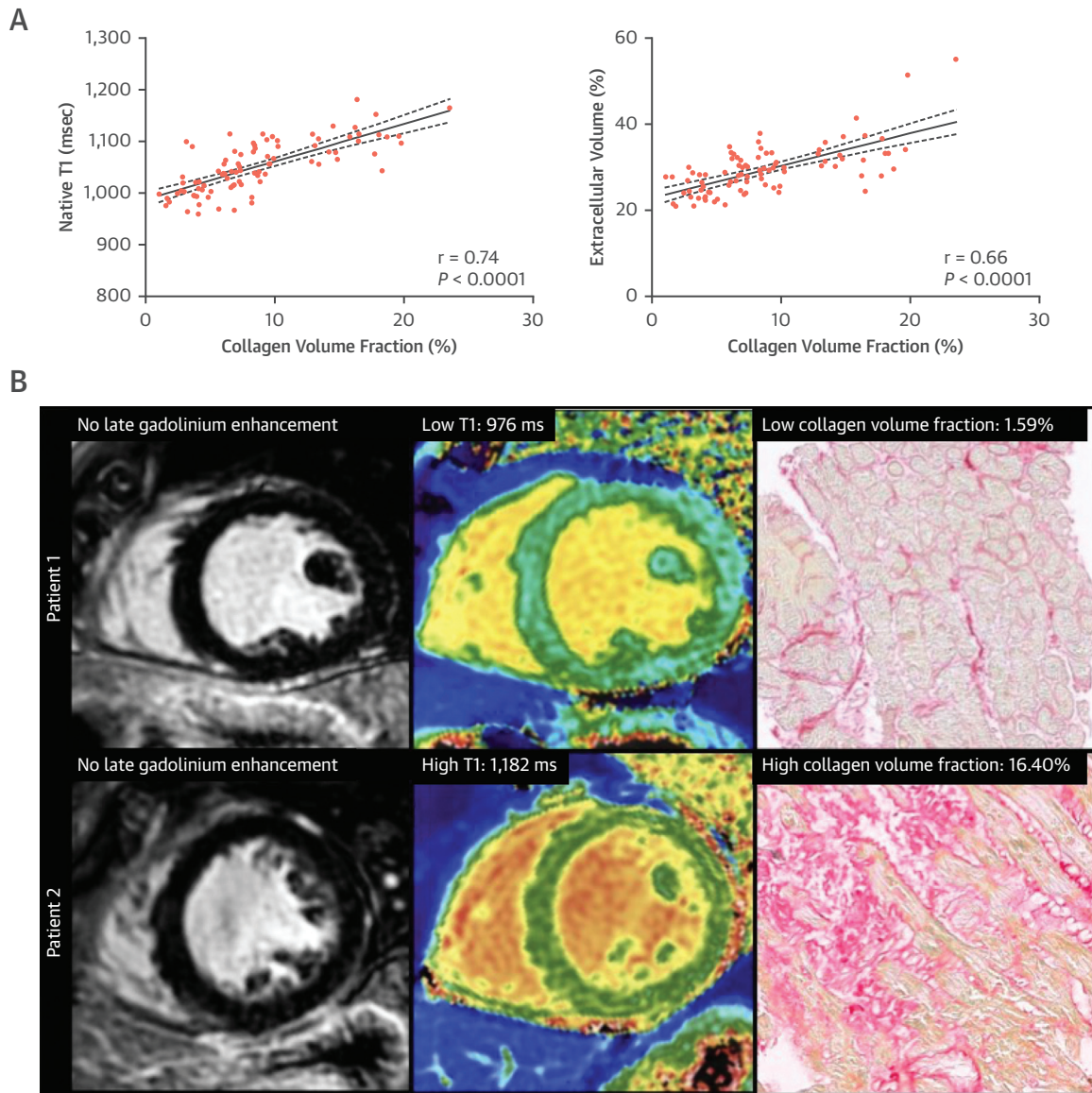
were used to ensure T1 quality based on the latest consensus statement.⁵ The study protocol was approved by the local medical committee, and all patients provided written informed consent.

Approximately one-third presented with New York Heart Association (NYHA) functional class ≥3, and 53% had a left ventricular ejection fraction (LVEF) <35%. The median duration of symptoms was 6 months (IQR: 4-9 months). Mean native T1 and ECV were 1,051 ± 50 ms and 29% ± 6%, respectively. Thirty-two patients (36%) had increased T1 based on the center-specific cutoff of >1,052 (local reference value 1,012 ms +2 SD).⁵ A nonischemic LGE pattern was observed in 39 patients (44%). Median CVF was 7.4% (IQR: 4.6%-12%). Native T1 correlated strongly with CVF, and ECV correlated moderately with CVF (Figure 1A). Similar correlation coefficients between T1 and CVF were found in more severe HF patients (LVEF <35%: $r = 0.69$; NYHA ≥3: $r = 0.70$; both: $r = 0.74$; all $P < 0.001$). The correlation between ECV and CVF in these groups was weaker compared with the total study population (LVEF <35%: $r = 0.46$; $P = 0.001$; NYHA ≥3: $r = 0.43$; $P = 0.023$; both: $r = 0.36$; $P = 0.114$). The strengths of the correlations between CVF, T1, and ECV were similar in patients with (+) and without (-) LGE (T1: LGE+ $r = 0.70$; LGE- $r = 0.77$, ECV: LGE+ $r = 0.72$; LGE- $r = 0.64$; all $P < 0.0001$).

According to the Youden index, the diagnostic accuracy for a moderate level of histologic fibrosis (defined as CVF >10%)⁴ for T1 was 0.91 (95% CI: 0.85-0.97; $P < 0.0001$) with an optimal cutoff of 1,056 ms (sensitivity 96%, specificity 77%) and for ECV was 0.82 (95% CI: 0.73-0.91; $P < 0.0001$) with an optimal cutoff of 28.9% (sensitivity 88%, specificity 64%). When T1 and ECV were combined (with the use of logistic regression), the area under the curve increased to 0.95.

To the best of our knowledge, this is the largest study evaluating the value of T1 and ECV mapping for the detection of diffuse myocardial fibrosis in chronic DCM patients. Both T1 and ECV correlated with CVF, which confirms previous findings from smaller studies in DCM patients,^{3,4} with an overall slightly better accuracy of T1, regardless of LGE presence and disease severity. Of note, EMB samples only reflect a part of the myocardium, possibly resulting in sampling error. Underlying etiologies should be assessed, because T1 mapping measures longitudinal relaxation time, which is altered by fibrosis, edema, and infiltrative diseases. Also, because of limited voxels across the thin LV wall in DCM patients, T1 mapping should

FIGURE 1 Diffuse (Native T1) and Focal (Late Gadolinium Enhancement) Myocardial Fibroses Are Distinct Features in Dilated Cardiomyopathy Patients That Can Be Observed in Parallel



(A) T1 mapping and extracellular volume show strong and moderate correlations with collagen volume fraction (CVF). **(B)** Two patients without late gadolinium enhancement. Patient 1 has low T1 and CVF values, whereas patient 2 has high T1 and CVF values.

be performed with caution. Despite this, the correlations of T1 and with CVF were strong.

T1 mapping provides a quantifiable marker which directly relates to prognosis² and may monitor treatment response to antifibrotic therapy. Both diffuse and focal fibrosis are common findings in

DCM, albeit with variable degrees of severity. Our results demonstrate that diffuse (T1 and ECV) and focal (LGE) myocardial fibrosis seem to be distinct features in DCM patients that may or may not be observed simultaneously in one patient. T1 and LGE act as independent yet complementary imaging

measures and should be used together to synergize the detection and distinction of diffuse and focal myocardial fibrotic disease.

Anne G. Raafs, MD
Bouke P. Adriaans, MD
Michiel T.H.M. Henkens, MD
Job A.J. Verdonchot, MD, PhD
Mitch J.F.G. Ramaekers, MD
Suzanne Gommers, MD
Myrurgia A. Abdul Hamid, MD, PhD
Simon Schalla, MD, PhD
Christian Knackstedt, MD, PhD
Vanessa P.M. van Empel, MD, PhD
Hans-Peter Brunner-la Rocca, MD
J.E. Wildberger, MD, PhD
Sebastiaan C.A.M. Bekkers, MD, PhD
Mark R. Hazebroek, MD, PhD*

*Department of Cardiology
Cardiovascular Research Institute Maastricht
Maastricht University Medical Center
P. Debyelaan 25
6229 HX Maastricht, the Netherlands
E-mail: mark.hazebroek@mumc.nl
<https://doi.org/10.1016/j.jcmg.2022.05.002>

© 2022 by the American College of Cardiology Foundation. Published by Elsevier.

The authors have reported that they have no relationships relevant to the contents of this paper to disclose.

The authors attest they are in compliance with human studies committees and animal welfare regulations of the authors' institutions and Food and Drug Administration guidelines, including patient consent where appropriate. For more information, visit the [Author Center](#).

REFERENCES

- López B, Ravassa S, Moreno MU, et al. Diffuse myocardial fibrosis: mechanisms, diagnosis and therapeutic approaches. *Nat Rev Cardiol*. 2021;18:479-498.
- Puntmann VO, Carr-White G, Jabbour A, et al. T1-mapping and outcome in nonischemic cardiomyopathy: all-cause mortality and heart failure. *J Am Coll Cardiol Img*. 2016;9:40-50.
- Nakamori S, Dohi K, Ishida M, et al. Native T1 mapping and extracellular volume mapping for the assessment of diffuse myocardial fibrosis in dilated cardiomyopathy. *J Am Coll Cardiol Img*. 2018;11:48-59.
- Sibley CT, Noureldin RA, Gai N, et al. T1 Mapping in cardiomyopathy at cardiac MR: comparison with endomyocardial biopsy. *Radiology*. 2012;265:724-732.
- Messroghli DR, Moon JC, Ferreira VM, et al. Clinical recommendations for cardiovascular magnetic resonance mapping of T1, T2, T2* and extracellular volume: a consensus statement by the Society for Cardiovascular Magnetic Resonance (SCMR) endorsed by the European Association for Cardiovascular Imaging (EACVI). *J Cardiovasc Magn Reson*. 2017;19:75.

Relationship Between Unrecognized Myocardial Infarction and Underlying Coronary Plaque Characteristics on Optical Coherence Tomography



A non-negligible proportion of myocardial infarction (MI) occurs in the absence of clinical manifestations.

The prevalence of unrecognized myocardial infarction (UMI) is reportedly associated with a worse prognosis.¹ Cardiac magnetic resonance (CMR) imaging can detect even a small myocardial scar represented by late gadolinium enhancement (LGE) and estimate the infarct size. The aim of our analysis was to investigate the underlying coronary plaque characteristics of the vessel subtending the CMR-derived UMI territory by using optical coherence tomography (OCT).

This retrospective analysis included patients from the institutional OCT registry database enrolled between November 2012 and December 2020 at Tsuchiura Kyodo General Hospital. The analysis included a total of 147 patients with stable coronary artery disease and no history of known MI, percutaneous coronary intervention, and/or coronary artery bypass grafting who underwent the first elective percutaneous coronary intervention for de novo lesions with pre-intervention LGE-CMR and OCT imaging of the target lesion. Representative images of a case with UMI at the target vessel territory are shown in **Figures 1A to 1C**. Our analysis was conducted in compliance with the Declaration of Helsinki for investigation in human beings and approved by the institutional ethics committee on human research of Tsuchiura Kyodo General Hospital.

CMR image acquisition was performed by using a 1.5-T scanner with 32-channel cardiac coils (Achieva, Philips Medical Systems). The presence of UMI was assessed on the LGE-CMR images by identifying regions of contrast enhancement with an ischemic distribution pattern.¹ OCT examination was performed by using frequency-domain OCT systems (Ilumien OPTIS, Abbott Vascular; Lunawave, Terumo Corporation). OCT-defined plaque characteristics were analyzed using previously established criteria.² Layered plaque was identified by the presence of one or more signal-rich layers of different optical density and a clear demarcation from underlying plaque components.³ Categorical data were compared by using the chi-square test. Continuous variables are expressed as median (IQR) for non-normally distributed variables and were compared by using the Mann-Whitney test. A value of $P < 0.05$ was considered statistically significant.

In a total of 147 patients, the median age was 69 years, and 74.8% were male. UMI at the target vessel territory was detected in 26 patients (17.7%). Patients with UMI at the target territory had higher levels of baseline high-sensitivity cardiac troponin I (11 [IQR: 8-19] ng/L vs 5 [IQR: 3-11] ng/L; $P = 0.007$) and N-terminal pro-B-type natriuretic peptide (272 [IQR: 187-904] pg/mL vs 113 [IQR: 57-236] pg/mL; $P = 0.004$)