

<https://helda.helsinki.fi>

Tattoo aftercare management with a dermo-cosmetic product : Improvement in discomfort sensation and skin repair quality

Fauger, Aurelie

2022-03

Fauger , A , Sonck , S , Kluger , N , Chavagnac-Bonneville , M & Sayag , M 2022 , ' Tattoo aftercare management with a dermo-cosmetic product : Improvement in discomfort sensation and skin repair quality ' , Journal of Cosmetic Dermatology , vol. 21 , no. 3 , pp. 1051-1056 . <https://doi.org/10.1111/jocd.14157>

<http://hdl.handle.net/10138/353101>

<https://doi.org/10.1111/jocd.14157>

cc_by

publishedVersion

Downloaded from Helda, University of Helsinki institutional repository.



This is an electronic reprint of the original article.

This reprint may differ from the original in pagination and typographic detail.

Please cite the original version.

ORIGINAL CONTRIBUTION

Tattoo aftercare management with a dermo-cosmetic product: Improvement in discomfort sensation and skin repair quality

Aurélie Fauger¹ | Säde Sonck² | Nicolas Kluger MD, PhD^{3,4}  |
 Marlène Chavagnac-Bonneville PhD¹  | Michèle Sayag MD¹

¹NAOS; Research and Development Department, Lyon, France

²Unique Art Tattoo, Hämeenlinna, Finland

³Helsinki University Hospital; Department of Dermatology, Helsinki, Finland

⁴Department of Dermatology, Bichat-Claude Bernard Hospital, Assistance Publique-Hôpitaux de Paris, Paris, France

Correspondence

Aurélie Fauger, NAOS; Research and Development Department, 75 cours Albert Thomas, 69003 Lyon, France.
 Email: aurelie.fauger@naos.com

Funding information

NAOS

Abstract

Background: A moisturizer application during the healing process after a tattoo session is a common practice to help wound healing and to reduce discomfort sensations. This practice was recently recommended by the standard European guidelines on tattoos, with the use of an adapted ointment to keep the site moist.

Aims: To assess the efficacy and the tolerability of a specific dermo-cosmetic product (Cicabio Pommade, Laboratoire Bioderma, NAOS, France) in tattoo aftercare.

Patients/Methods: Thirty subjects included in this survey applied the product immediately after the tattoo session for 14 days. The objective symptoms (redness, edema, skin repair quality) were assessed by the tattooist and the subjects. The subjective symptoms, discomfort sensations (pain, itching, burning sensations, tingling), soothing, moisturizing, and undesirable effects were assessed by the tattooed individuals.

Results: After 14 days of application, redness was absent for 100% and 96% of subjects according to the tattoo artist and the subjects, respectively, and edema had completely disappeared for both assessors. Most of the subjects rated the skin quality repair and the aesthetic outcomes as very good to excellent. Soothing and moisturizing effects were observed as early as the first day. The effects were maintained over 14 days. Discomfort sensations were judged absent to slight in 96%–100% of cases after 7 days. They were assessed as absent to slight in all cases for pain, itching, and tingling, and in 96% for burning sensations after 14 days. The product was very well tolerated by 87% of the subjects.

Conclusions: Our survey demonstrates that this dermo-cosmetic product is suitable for tattooed skin aftercare as it reduced skin discomfort as soon as the first day and led to a good skin quality repair while being well tolerated.

KEYWORDS

aftercare, dermo-cosmetic, discomfort, repair, tattooing

This is an open access article under the terms of the Creative Commons Attribution-NonCommercial License, which permits use, distribution and reproduction in any medium, provided the original work is properly cited and is not used for commercial purposes.

© 2021 NAOS. *Journal of Cosmetic Dermatology* published by Wiley Periodicals LLC.

1 | INTRODUCTION

The number of people getting tattoos has increased in recent years, particularly with younger generations.¹ The prevalence of tattoos ranges from 10% to 32% depending on the country.^{1–3} After tattoo completion, commonly observed cutaneous reactions comprise skin inflammation with slight local edema, and sensitivity to touch, as well as sometimes a painful sensation and itching.⁴ Tattoo healing is usually complete after 2–3 weeks.^{4,5} Unfortunately, according to a number of European surveys, immediate adverse tattoo reactions can occur in 15%–68% of cases.⁶ The most frequent acute tattoo cutaneous reactions are irritation, infection, delay in healing, itching, and stinging,^{3,7} which can potentially adversely affect the aesthetic appearance of the tattoo. Therefore, proper tattoo aftercare with a specifically devised product is essential to limit uncomfortable symptoms and to relieve pain, as well as to improve the skin repair quality and consequently enhance the aesthetic appearance of the tattoo.

Until recently, there were no official guidelines for tattoo aftercare.⁸ The European standard NF EN 17169 published in January 2020 recommends various options after a tattoo session, one of which involves the application of a dressing on the tattoo associated with the application of a thin layer of a specific tattoo aftercare ointment 2 or 3 times a day over 2–3 days, after cleaning the tattoo.⁹ Application of the ointment is recommended until the crust disappears, as it maintains a moist environment for the tattoo. The recommendations specify continued moisturization of the tattoo by the application of a non-perfumed moisturizing lotion several times a day for 2 or 3 weeks to avoid the tattoo drying out.

In light of these new recommendations for tattoo aftercare, this study investigated the effects and the tolerability of a dermo-cosmetic product, Cicabio Pommade (Laboratoire Bioderma, NAOS, France), in tattoo aftercare, based on evaluations by a tattoo artist and the subjects themselves.

2 | MATERIALS AND METHODS

2.1 | Targeted population and instructions for use

Thirty subjects aged 18 years or older were recruited at the Unique Art Tattoo studio in Hämeenlinna, Finland, by a tattoo artist. Subjects with a history of allergic reaction to cosmetic products or allergies to tattoo ink were excluded, as were women who were pregnant or who were breastfeeding. The dermo-cosmetic product was applied immediately after the tattoo session (under cellophane) by the tattoo artist. The subjects then applied it to their tattoo at least twice a day for 14 days after having previously cleaned the area with their usual hygiene product. No other care product could be applied to the tattoo for the entire duration of the survey. The dermo-cosmetic product is a water-in-oil formula (Cicabio Pommade, Laboratoire Bioderma, NAOS, France) containing active ingredients with repairing (sodium hyaluronate, *Vitis vinifera* (grape) vine extract, copper sulfate, *Centella asiatica* extract titrated in asiaticoside, madecassic acid, asiatic acid), soothing (Antalgicine®), and anti-bacterial (zinc sulfate, copper sulfate) properties (Table 1).

2.2 | Survey methodology and assessment by the subjects

The subjects were included by the tattoo artist between April and June of 2019, and they were asked to complete the survey form. The survey was a self-assessment questionnaire validated by the tattoo artist and the dermatologist in charge of the survey coordination. It was designed to evaluate the tolerability and the effect of the dermo-cosmetic product in tattoo aftercare. On Day 1, Day 7, and Day 14, the subjects filled out a daily log to assess objective

Ingredient	Action
Sodium hyaluronate	Moisturizing and wound healing properties by enhancing keratinocyte proliferation and migration ^{10,11}
Glycerin	Moisturizing properties
Antalgicine®	Soothing properties by kyotorphin-like lasting analgesic effects ^{12,13}
<i>Vitis vinifera</i> (grape) vine extract	Repairing properties via its titration in resveratrol, contributing to increasing the rate of wound contraction and closing ¹⁴
<i>Centella asiatica</i> extract	Repairing properties via its titration asiaticoside promoting fibroblast proliferation and increasing collagen synthesis ¹⁵
Copper sulphate	Anti-bacterial ¹⁸ and repairing properties by facilitating the dermal contraction of wounds ^{16,17}
Zinc sulphate	Anti-bacterial properties ¹⁹

TABLE 1 Ingredients and key activities of Cicabio Pommade^a

^aFull list of components: aqua, glycerin, mineral oil, caprylic/capric triglyceride, fructooligosaccharides, polyglyceryl-4 diisostearate/polyhydroxystearate/sebacate, propanediol, xylitol, zinc stearate, sodium citrate, butylene glycol, capryloyl glycine, copper sulfate, sodium hydroxide, sodium hyaluronate, zinc sulfate, *V. vinifera* (grape) vine extract, laureth-3, asiaticoside, madecassic acid, asiatic acid, *Laminaria ochroleuca* extract, hydroxyethylcellulose, acetyl dipeptide-1 cetyl ester, mannitol, potassium sorbate, rhamnose.

(redness, edema, and the presence of crusts) and subjective signs (pain, pruritis, a burning sensation, tingling, soothing, and moisturizing effect) using the following scale: absent =0, slight =1, moderate =2, and important =3. On Day 14, the subjects evaluated the quality of their tattoo repair (absent, mediocre, mild, good, very good, or excellent), the aesthetic appearance of their tattoo (rated from 0 to 10), and their satisfaction with the product (Yes/No). Pictures of the subjects' tattoos were taken on Day 0 and Day 14. An authorization form was signed by the subjects, stating that they consented to publication of the pictures of their tattoos. In regard to compliance, the subjects recorded the number of times they applied the product to their tattoo in a daily log. Tolerability was evaluated by the subjects on Day 14 (presence or absence of undesirable effects after product applications).

2.3 | Assessment by the tattoo artist

The tattoo artist assessed the redness and edema on Day 0 and Day 14, and the skin repair quality (nil, mediocre, average, good, or excellent) on Day 14.

3 | RESULTS

Thirty subjects were included in this survey and analyzed in terms of the tolerability of the dermo-cosmetic product. Twenty-five of them complied with the survey indications and were analyzed based on the assessment of objective and subjective clinical signs by the tattoo artist and by the subjects themselves. The subjects ranged from 20 to 68 years of age (median age 36.0 years) and 64% were women and 36% were men. The level of compliance was good for all subjects.

3.1 | Objective signs assessment by the tattoo artist and the subjects

Redness and edema were deemed to be present (slight to important) after the tattoo completion for 80% and 44% of the subjects,

respectively, according to the tattoo artist on Day 0 (data not shown), and for 96% and 64% of the subjects, respectively, according to the subjects themselves on Day 1 (Figure 1A–B). After 14 days, the redness and the edema had fully disappeared for all the subjects according to the tattoo artist (data not shown, illustration in Figure 2) and for 96% and 100% of the subjects, respectively, according to the subjects themselves (Figure 1A–B). Crusts were reported by only 8% of subjects on Day 1 and were absent for 68% of subjects on Day 14 according to the subjects (data not shown). Moreover, the skin repair quality on Day 14 was rated as good to excellent by the tattoo artist for 88% of the subjects, while this was 100% when rated by the subjects themselves (data not shown), and the aesthetic appearance of the tattoo was rated very good to excellent for all the subjects (mean of $9.6 \pm 0.6/10$, data not shown).

3.2 | Subjective signs assessment

On Day 1, pain, itching, a burning sensation, and tingling were considered to be absent or slight in 88%, 96%, 88%, and 84% of the subjects, respectively (Figure 3). Pain and itching were absent or slight in 100% of subjects on Day 7 and fully disappeared on Day 14 (Figure 3A–B). A burning sensation and tingling were absent or slight in 96% of the subjects on Day 7, and 96% and 100%, respectively, on Day 14 (Figure 3C–D), even if a burning sensation and tingling persisted for 4% (moderate improvement) and 8% (slight improvement) of the subjects, respectively. Moreover, after its application to the tattoo on Day 1, the soothing effect and the moisturizing effect were rated as moderate to important in 60% and 76% of the subjects, respectively, (data not shown), and remained stable on Day 7 and Day 14 (Figure 4). After 14 days, 92% of the subjects were satisfied with the performance of the dermo-cosmetic product.

3.3 | Tolerability assessment

Eighty-seven percent of the subjects (26/30) found that the dermo-cosmetic product was very well tolerated. Four subjects reported

FIGURE 1 Evaluation of the clinical objective signs by the subjects from Day 1 to Day 14: redness (A) and edema (B)

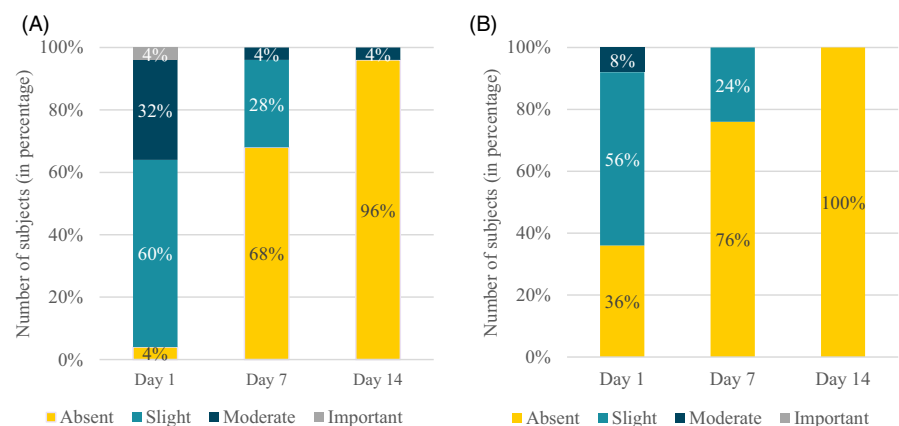

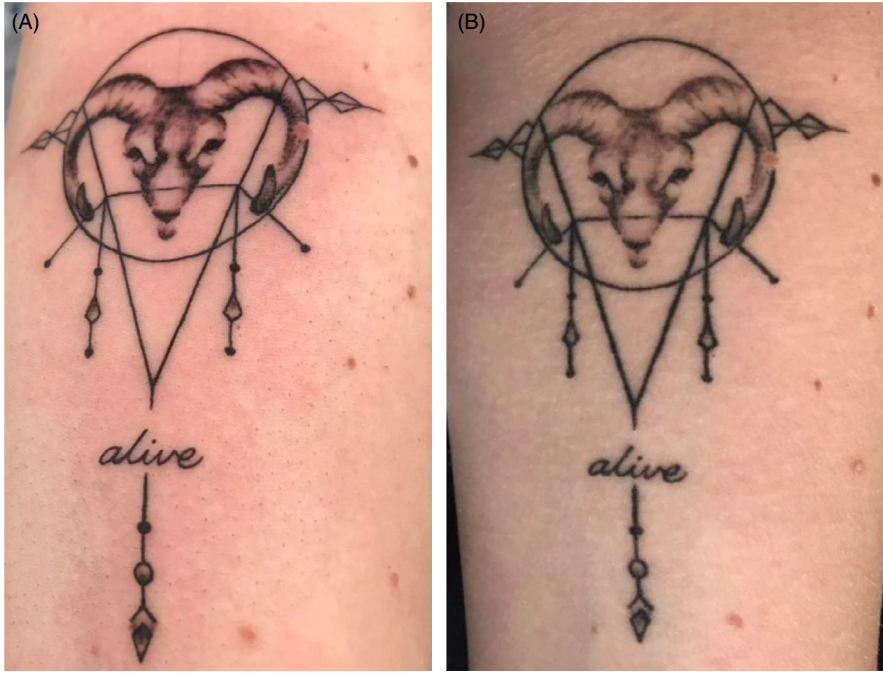


FIGURE 2 A fresh tattoo with redness at Day 0 (A) and the same tattoo at Day 14 (B)

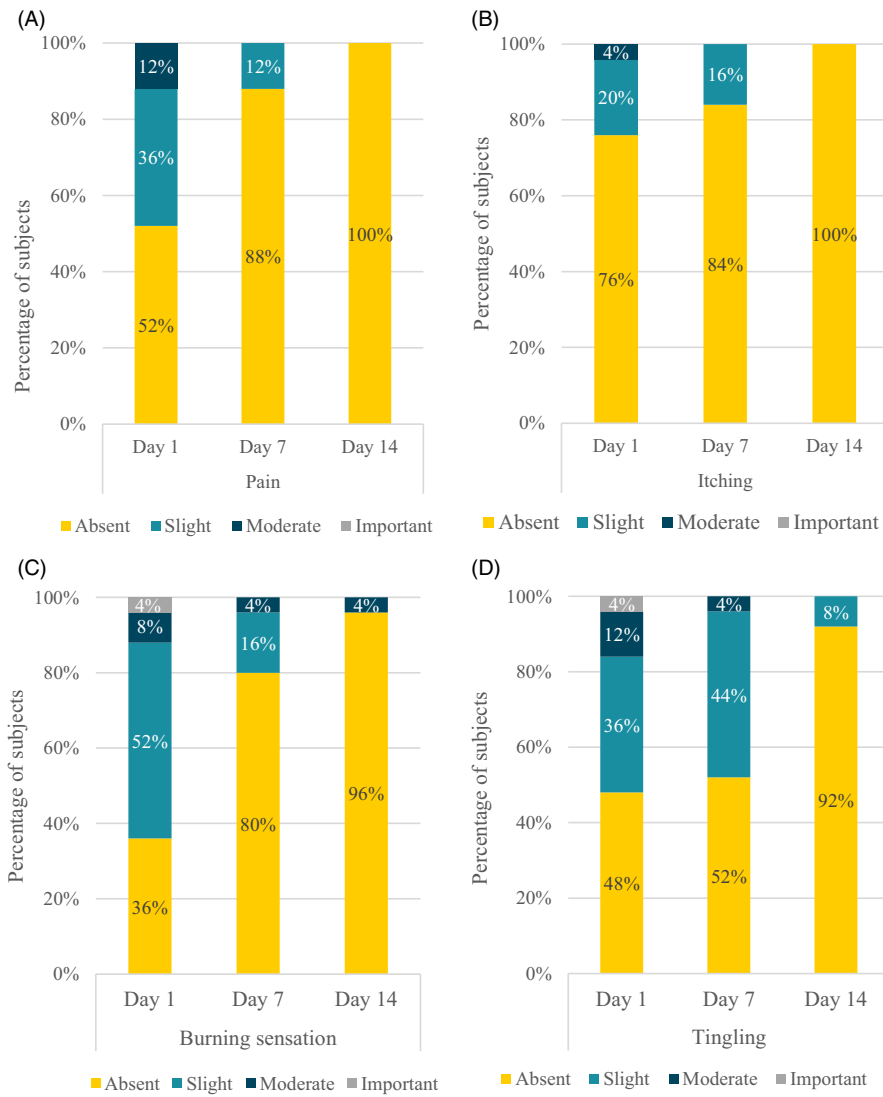

FIGURE 3 Progression of the clinical subjective signs according to the subjects from Day 1 to Day 14: pain (A), itching (B), a burning sensation (C), and tingling (D)

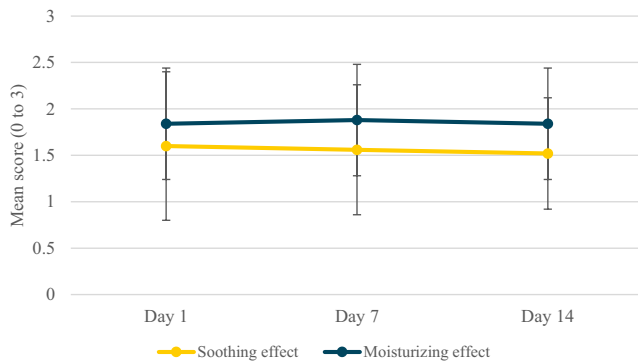


FIGURE 4 Stability of the soothing effect and the moisturizing effect of the product evaluated by the subjects from Day 1 to Day 14

undesirable effects, primarily a burning sensation and stinging. One of the subjects stopped the applications because of these symptoms.

4 | DISCUSSION

This study shows that the dermo-cosmetic product reduced skin discomfort (pain, itching, a burning sensation, and tingling) after seven days of application while providing efficient soothing and a moisturizing effect for 14 days after tattoo completion. In addition, the product application led to a good skin repair quality after 14 days and it was well tolerated.

The good moisturizing effect of the product is due to its formulation as a water-in-oil emulsion, for which the oily phase mainly consists of Vaseline® and triglycerides, and because it contains moisturizing active ingredients such as glycerin and hyaluronic acid. Hyaluronic acid is known to act as a water reservoir, and its degradation products have substantial wound healing properties. It particularly enhances keratinocyte proliferation and migration.^{10,11} This formula has a rich and protective consistency that has a soothing effect on tattooed skin. This moisturizing effect keeps new tattoos well hydrated, thereby exerting a soothing effect and preventing itching. The soothing effect is also due to the presence of Antalgicine®, which is a dipeptide with a structure similar to kyotorphin that exerts lasting analgesic effects.¹² Kyotorphin has an analgesic effect by stimulation of the release of an opioid neuromediator, Met-enkephalin, in nerve cells.¹³ By moisturizing, soothing, and eliminating itching, the product optimized skin repair, as noted by both the tattoo artist and the subjects. The repair properties are also optimized by the presence of three active ingredients that play a role in many biological processes involved in wound healing: (i) a *V. vinifera* (grape) vine extract titrated in resveratrol, which has been described as contributing to increasing the rate of wound contraction and closing¹⁴; (ii) a *C. asiatica* extract, for which the main active ingredient is asiaticoside, which is known in particular to promote fibroblast proliferation and to increase collagen synthesis¹⁵; and (iii) copper, which facilitates the dermal contraction of wounds.^{16,17} Copper also has a purifying

action,^{16,18} and in combination with zinc,¹⁹ it is well-known and widely used in dermatology for Dalibour's preparation. Therefore, the Cu/Zn association helps to prevent and limit the risk of infection of the tattoo.

Two clinical studies have evaluated the efficacy of other dermo-cosmetic products in tattoo aftercare. The first study was a randomized, controlled, double-blind clinical trial involving 25 subjects that compared the effects of two specific topical products applied twice daily after tattoo completion for 28 days.²⁰ Both products led to the dissipation of erythema (Day 21) and edema (Day 14), very little scabbing (Day 28), and improvement of the dryness grading associated with improvement of hydration and transepidermal water loss (TEWL). The second study was a single-blind prospective study involving 54 subjects with freshly tattooed skin to intra-individually compare two products applied 4–8 times daily by assessment of the cosmetic performance and also the TEWL for 14 days.²¹ Both products performed favorably in terms of their cosmetic properties and efficacy, and they are considered to be suitable for the aftercare of tattooed skin. Interestingly both studies noted a substantial increase in the TEWL after the tattoo session, which is almost fully reestablished 14 days after the tattoo session, thus confirming the importance of aftercare of skin tattoos in the restoration of the skin barrier.

The limitations of our study include the small sample size and the lack of comparison with a reference product since the absence of a placebo or non-treated area is unethical. Further investigations should be conducted to confirm the efficacy of the product in a larger study under dermatological control. In conclusion, this dermo-cosmetic product is suitable for the aftercare of tattooed skin and may contribute to reducing tattoo complications. This is in accordance with the recent guidelines for tattooing,⁹ but further investigation of the management of tattoo healing should be undertaken to establish and validate the dermatological recommendations for tattoo aftercare.

AUTHOR CONTRIBUTION


Aurélien Fauger contributed to the concept and the design of the study, wrote the questionnaire of the study (survey), supervised the study, performed the analysis and interpretation of data, revised the manuscript, and gave the approval on the final version. Sade Sonck validated the questionnaire, conducted the study, revised the manuscript, and gave the approval on the final version. Nicolas Kluger contributed to the concept and the design of the study, validated the questionnaire of the study (survey), supervised the study, performed the data acquisition, contributed to the data interpretation, revised the manuscript, and gave the approval on the final version. Marlène Chavagnac-Bonneville contributed to the data analysis and interpretations, wrote and submitted the manuscript, and gave the approval on the final version. Michèle Sayag contributed to the concept and the design of the study, validated the questionnaire of the study (survey), supervised the study, contributed to the data interpretation, revised the manuscript, and gave the approval on the final version.

DATA AVAILABILITY STATEMENT

The data that support the findings of this study are available from the corresponding author upon reasonable request.

ORCID

Nicolas Kluger  <https://orcid.org/0000-0002-5225-8316>

Marlène Chavagnac-Bonneville  <https://orcid.org/0000-0002-2954-5798>

REFERENCES

1. Kluger N. Epidemiology of tattoos in industrialized countries. *Curr Probl Dermatol.* 2015;48:6-20.
2. Kluger N, Seité S, Taieb C. The prevalence of tattooing and motivations in five major countries over the world. *J Eur Acad Dermatol Venereol.* 2019;33(12):484-486.
3. Kluger N, Misery L, Seité S, Taieb C. Tattooing: a national survey in the general population of France. *J Am Acad Dermatol.* 2019;81(2):607-610.
4. Kluger N. Acute complications of tattooing presenting in the ED. *Am J Emerg Med.* 2012;30(9):2055-2063.
5. Sperry K. Tattoos and tattooing: part II: gross pathology, histopathology, medical complications, and applications. *Am J Forensic Med Pathol.* 1992;13(1):7-17.
6. Rosenbaum BE, Milam EC, Seo L, Leger MC. Skin care in the tattoo parlor: a survey of tattoo artists in New York City. *Dermatology.* 2016;232(4):484-489.
7. Carlsen KH, Serup J. Chronic tattoo reactions cause reduced quality of life equaling cumbersome skin diseases. *Curr Probl Dermatol.* 2015;48:71-75.
8. Liszewski W, Jagdeo J, Laumann AE. The need for greater regulation, guidelines, and a consensus statement for tattoo aftercare. *JAMA Dermatology.* 2016;152(2):141-142.
9. NF EN 17169-2020 - Tattooing – Safe and Hygienic Practice. 2020.
10. Price RD, Myers S, Leigh IM, Navsaria HA. The role of hyaluronic acid in wound healing: assessment of clinical evidence. *Am J Clin Dermatol.* 2005;6(6):393-402.
11. Karvinen S, Pasonen-Seppänen S, Hyttinen JMT, et al. Keratinocyte growth factor stimulates migration and hyaluronan synthesis in the epidermis by activation of keratinocyte hyaluronan synthases 2 and 3. *J Biol Chem.* 2003;278(49):49495-49504.
12. Dzambazova E, Bocheva A. The unique brain dipeptide kyotorphin - from discovery to nowadays. *J Biomed Clin Res.* 2010;3(1):3-11.
13. Takagi H, Shiomi H, Ueda H, Amano H. A novel analgesic dipeptide from bovine brain is a possible Met-enkephalin releaser. *Nature.* 1979;282:410-412.
14. Khanna S, Venojarvi M, Roy S, et al. Dermal wound healing properties of redox-active grape seed proanthocyanidins. *Free Radic Biol Med.* 2002;33(8):1089-1096.
15. Bylka W, Znajdek-Awizeń P, Studzińska-Sroka E, Dańczak-Pazdrowska A, Brzezińska M. Centella asiatica in dermatology: an overview. *Phyther Res.* 2014;28(8):1117-1124.
16. Kornblatt AP, Nicoletti VG, Travaglia A. The neglected role of copper ions in wound healing. *J Inorg Biochem.* 2016;161:1-8.
17. Sen CK, Khanna S, Venojarvi M, et al. Copper-induced vascular endothelial growth factor expression and wound healing. *Am J Physiol - Hear Circ Physiol.* 2002;282(5):H1821-H1827.
18. Borkow G, Gabbay J, Dardik R, et al. Molecular mechanisms of enhanced wound healing by copper oxide-impregnated dressings. *Wound Repair Regen.* 2010;18(2):266-275.
19. Söderberg T, Hallmans G, Ågren M, Tengrup I, Banck G. The effects of an occlusive zinc medicated dressing on the bacterial flora in excised wounds in the rat. *Infection.* 1989;17(2):81-85.
20. White R. Tattoos as wounds: a clinical efficacy study of two skin aftercare preparations. *Wounds UK.* 2012;8(4):32-40.
21. Olsavszky R, Nanu EA, Macura-Biegun A, Kurka P, Trapp S. Skin barrier restoration upon topical use of two 5% dexpanthenol water-in-oil formulations on freshly tattooed skin: results from a single-blind prospective study. *Wounds Int.* 2019;10(1):33-39.

How to cite this article: Fauger A, Sonck S, Kluger N, Chavagnac-Bonneville M, Sayag M. Tattoo aftercare management with a dermo-cosmetic product: Improvement in discomfort sensation and skin repair quality. *J Cosmet Dermatol.* 2022;21:1051-1056. <https://doi.org/10.1111/jocd.14157>