



Endoscopic Diverticulectomy with Platelet-Rich Plasma of Intraluminal Duodenal Diverticulum

Vicente Lorenzo-Zúñiga^{1*}, Vicente Moreno de Vega² and Jaume Boix Valverde³

¹Endoscopy Unit, Hospital Universitari i Politècnic La Fe, Valencia, Spain

²Endoscopy Unit, Hospital Universitari Germans Trias i Pujol, Badalona, Spain

³Endoscopy Unit, Hospital HM Sant Jordi, Barcelona, Spain

*Corresponding Author: Vicente Lorenzo-Zúñiga, Endoscopy Unit, Hospital Universitari i Politècnic La Fe, Valencia, Spain.

Received: March 25, 2021

Published: May 06, 2021

© All rights are reserved by Vicente Lorenzo-Zúñiga, et al.

Abstract

Background: Procedure-related bleeding remains a common complication after endoscopic diverticulectomy of intraluminal duodenal diverticulum (IDD). The optimal endoscopic approach to IDD has not been established. Platelet-rich plasma (PRP) has proven biological properties to reduce risk of bleeding.

Materials and Methods: The authors describe a novel technique in which endoscopic diverticulectomy was performed with prior submucosal injection of PRP (IRB approval PT-16-002).

Case Report: A 62-year-old woman with a large IDD like a “windsock” underwent endoscopic diverticulectomy with PRP obtained from a sample of patient’s blood. IDD was resected with EMR technique using a standard polypectomy snare. No immediate or delayed bleeding was noted. Follow-up endoscopy 3 months later revealed complete mucosal healing and open communication to the distal duodenum.

Conclusion: Endoscopic diverticulectomy with PRP is an option in patients with IDD.

Keywords: Intraluminal Duodenal Diverticulum (IDD); Platelet-Rich Plasma (PRP); Endoscopic Diverticulectomy

Introduction

Intraluminal duodenal diverticulum (IDD), also known as “windsock” diverticulum, is a rare entity with lack of specific symptoms, but most patients use to present nausea, vomiting and epigastric abdominal pain. Incomplete recanalization of the embryonic duodenum with years of peristaltic contractions develops a diverticulum lined on both sides with duodenal mucosa, with a larger communication through the duodenal diaphragm to the distal duodenum [1].

The optimal endoscopic approach to IDD has not been established. Endoscopic diverticulectomy of IDD was first reported in 1979 using snare excision [2] and over the past 40 years, just few cases have been published [3,4] and most of them with immediate or delayed bleeding as adverse event. Platelet-rich plasma (PRP) is

an easy to-obtain solution with proven favorable biological activities that can be applied as submucosal injection or like a coverage agent to reduce the incidence of adverse events, as has been demonstrated by our group [5,6]. Endoscopic diverticulectomy with PRP is an option in patients with IDD (IRB approval PT-16-002).

Case Report

A 62-year-old woman presented with epigastric abdominal pain and acute pancreatitis. On abdominal CT scan a diaphragm that crosses the duodenal lumen and forms the intraluminal septum-like rim of the diverticulum was described. Using a standard upper endoscope (Olympus GIF-H180) a large IDD like a “windsock” was observed (Figure 1). The episode of pancreatitis was attributed to the presence of IDD. Endoscopic diverticulectomy

with submucosal injection of PRP was planned to solve duodenal obstruction. Forward-viewing dual channel therapeutic endoscope (Olympus GIF-2T160) was inserted. PRP was obtained from a sample of patient's blood (18 mL) drawn at the time of endoscopy with OLIN-1 kit (a single-use sterile product). Submucosal PRP injection on the top of the diverticulum was performed to reduce the risk of bleeding, with the aid of a clip to stabilize the diverticulum. IDD was resected with EMR technique using a standard polypectomy snare. No immediate or delayed bleeding was noted. Follow-up endoscopy 3 months later revealed complete mucosal healing and open communication to the distal duodenum. Endoscopic diverticulectomy with PRP is an option in patients with IDD.

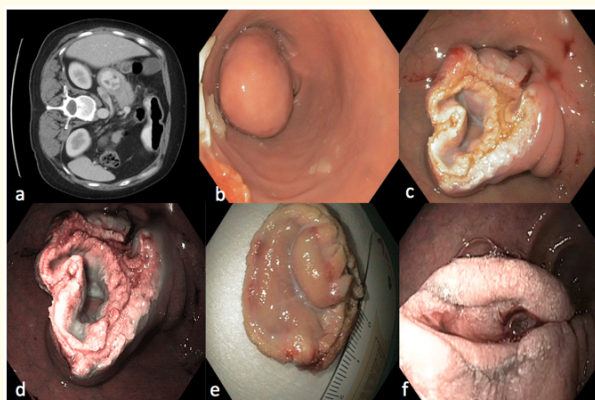


Figure 1: Endoscopic diverticulectomy with platelet-rich plasma of intraluminal duodenal diverticulum (IDD) (a) Abdominal CT scan with IDD. (b) Windssock diverticulum. (c) Mucosal defects with PRP cushion. (d) NBI of the resected area. (e) Retrieval tissue after EMR. (f) Follow-up endoscopy at 3 months.

Conclusion

The optimal endoscopic approach to IDD has not been established. Procedure-related bleeding remains a common complication after endoscopic diverticulectomy. PRP has proven biological properties to reduce risk of bleeding. Endoscopic diverticulectomy with PRP is an option in patients with IDD.

Conflict of Interest and Funding Support

Authors declare no conflict of interest and none funding.

Bibliography

1. Oukachbi N and Brouzes SJ. "Management of complicated duodenal diverticula". *Journal of Visceral Surgery* 150.3 (2013): 173-179.
2. Hajiro K., et al. "Endoscopic diagnosis and excision of intraluminal duodenal diverticulum". *Gastrointestinal Endoscopy* 25.4 (1979): 151-154.
3. Ito T., et al. "Intraluminal duodenal diverticulum with refractory pancreatitis successfully treated by endoscopic diverticulectomy". *Digestive Endoscopy* 25.3 (2013): 336-337.
4. Law R., et al. "Endoscopic treatment of intraluminal duodenal ("windssock") diverticulum: varying technique from five cases". *Endoscopy* 44.12 (2012): 1161-1164.
5. Lorenzo-Zúñiga V., et al. "Submucosal injection of platelet-rich plasma in endoscopic resection of large sessile lesions". *World Journal of Gastrointestinal Endoscopy* 10.11 (2018): 348-353.
6. Lorenzo-Zúñiga V., et al. "Endoscopic shielding with platelet-rich plasma after resection of large colorectal lesions". *Surgical Laparoscopy Endoscopy and Percutaneous Techniques* (2020).

Volume 4 Issue 6 June 2021

© All rights are reserved by Vicente Lorenzo-Zúñiga, et al.