



Infectious disease

Fatal gastritis and enterocolitis due to concurrent *Helicobacter pylori* and *Campylobacter jejuni* infection in a captive cheetah (*Acinonyx jubatus*)

Tatiana Zingre ^{a,*}, Stefano Bagatella ^a, Christian Wenker ^b, Sonja Kittl ^c, Marina L. Meli ^d, Fabia Wyss ^b, Llorenç Grau-Roma ^a

^a Institute of Animal Pathology, Vetsuisse Faculty, University of Bern, Bern, Switzerland

^b Zoo Basel, Basel, Switzerland

^c Institute of Veterinary Bacteriology, Vetsuisse Faculty, University of Bern, Bern, Switzerland

^d Clinical Laboratory, Department of Clinical Diagnostics and Services, and Center for Clinical Studies, Vetsuisse Faculty, University of Zurich, Zurich, Switzerland

ARTICLE INFO

Article history:

Received 14 December 2022

Accepted 31 December 2022

Keywords:

Campylobacter jejuni
cheetah
enterocolitis
gastritis
Helicobacter pylori

ABSTRACT

A 3.5-year-old female cheetah (*Acinonyx jubatus*) died after a 10-day history of anorexia, regurgitation and diarrhoea despite symptomatic therapy. At gross post-mortem examination, the stomach was blood-filled with mucosal thickening and multifocal ulcerations. The intestinal mucosa was thickened and reddened, and the intestinal lumen was filled with dark red to black pasty content. Gastric histological lesions were compatible with gastritis due to *Helicobacter* infection, which was confirmed by polymerase chain reaction. Histology of the intestines revealed a severe necrotizing neutrophilic enterocolitis with abundant intralumenal curved to spiral bacteria, corresponding to *Campylobacter jejuni*, which were subsequently isolated from both small and large intestinal contents. No other intestinal pathogens were detected despite thorough investigations. These findings suggest that *C. jejuni* may have played an aetiological role in the enterocolitis. Such an association has not been previously reported in non-domestic felids.

© 2023 The Author(s). Published by Elsevier Ltd. This is an open access article under the CC BY license (<http://creativecommons.org/licenses/by/4.0/>).

Campylobacter spp are gram-negative bacilli frequently isolated from the intestinal tract of many farmed animals including poultry, pigs and cattle [1,2]. In these species, they rarely cause severe gastrointestinal disease and their major relevance is sanitary, as several species including *Campylobacter jejuni* and *Campylobacter coli* are known as the main cause of human infectious food-borne gastroenteritis [3]. In addition to food-producing animals, *Campylobacter* spp have been isolated from dogs and cats, although association with disease is rare [4]. In zoos, *Campylobacter* spp have been detected in birds, marine and terrestrial mammals and reptiles [5–9]. Only few data are available on the presence of *Campylobacter* spp in captive felids. Among several studies investigating the presence of *Campylobacter* spp in various zoological parks worldwide, only one healthy leopard has tested positive by polymerase chain reaction (PCR) [10]. These studies included

leopards (*Panthera pardus*), tigers (*Panthera tigris*), lions (*Panthera leo*), jaguars (*Panthera onca*), black-footed-cats (*Felis nigripes*), Asian golden cats (*Catopuma temminckii*) and a leopard cat (*Prionailurus bengalensis*) [7,9–11]. To our knowledge, this is the first report of enterocolitis associated with *C. jejuni* in a captive large felid.

A 3.5-year-old primiparous female cheetah (*Acinonyx jubatus*) with a 10-day history of gastrointestinal disease was submitted for necropsy to the Institute of Animal Pathology of the University of Bern, Switzerland. The cheetah had been kept in the same enclosure as her healthy 10-month-old cubs and their main daily food item was whole carcass chicken with or without organs or feathers. Depending on availability (approximately once weekly), other whole-body carcasses (roe deer, rabbit, antelope) were offered. All food items were dusted with a carnivore supplement (Fleischfresser 3,750; Granovit, www.granovit.ch) at a rate of 5% of meat weight. Clinical signs commenced with loss of appetite, vomiting, decreased activity and dark diarrhoea 3 days after general anaesthesia for a lameness examination, during which complete blood testing (haematology, and serum chemistry including blood urea

* Corresponding author.

E-mail address: tatiana.zingre@unibe.ch (T. Zingre).

nitrogen [BUN] and creatinine) revealed no anomalies. Faecal examination was negative for parasites, but high amounts of *C. jejuni* were isolated in bacterial culture. The clinical signs did not improve after 7 days of antibiotic and antiemetic therapy and the cheetah was by then completely refusing food. Therefore, gastroscopy and colonoscopy were performed under general anaesthesia. The cheetah had lost 4 kg during the 10 days between the first and second general anaesthetics and blood analysis revealed severe uraemia (BUN: 62.9 mmol/L, reference interval [RI] 8.9–20 mmol/L; creatinine: 526 $\mu\text{mol/L}$, RI 88–320 $\mu\text{mol/L}$), hyperbilirubinaemia (15.3 $\mu\text{mol/L}$; RI 0.0–5.1 $\mu\text{mol/L}$), leucocytosis ($25.7 \times 10^3/\mu\text{l}$; RI $5.6\text{--}18.0 \times 10^3/\mu\text{l}$) and monocytosis ($2.59 \times 10^9/\text{L}$; RI $0.067\text{--}0.960 \times 10^9/\text{L}$).

Gastroscopy and colonoscopy revealed gastric and colonic ulcers, which were biopsied and submitted for histological examination. Histological lesions comprised mild, multifocal fibrosis with loss of crypts and occasional neutrophilic infiltration in the colonic lamina propria. Therapy was continued without improvement and the cheetah was found dead 3 days later in its enclosure with evidence of melena.

Necropsy revealed a reduced body condition, both eyes were moderately sunken and the conjunctival mucosa had moderate pallor. The perianal region was smeared with dark red to black faeces and the oral cavity contained bright red, viscous fluid compatible with blood. The tongue had a mild diffuse bluish discoloration. The oesophagus contained some bloody fluid while the stomach was filled with approximately 30 ml of blood and a

$10.0 \times 7.0 \times 3.0$ cm blood clot. The mucosa of the gastric fundus and pylorus was diffusely reddened, moderately thickened, with a cobblestone-like appearance (Fig. 1). A focal, deep ulcer (1 cm diameter) was present approximately 5 cm caudal to the cardia and there was a mild adhesion between the mesentery and serosa subjacent to that area. A few ulcers (2–5 cm diameter) were present in the gastric fundus. The small and large intestines were filled with dark red to black pasty content and the mucosa was diffusely moderately thickened and multifocally moderately reddened (Fig. 2). The rectum contained unformed, pasty dark red to black faeces. Other findings included a few multifocal (5–10 mm diameter) white subpleural nodules on the lungs and a diffuse, moderate light brown discolouration of the liver. All other examined organs, including the kidneys and musculoskeletal system, were grossly unremarkable.

Samples from the stomach, small and large intestines, liver, lungs, kidneys and spleen were fixed in 4% neutral buffered formalin and routinely processed for histopathological examination. Slides were stained with haematoxylin and eosin (HE). A Warthin–Starry (WS) silver stain was also performed on stomach and intestine sections, and a Congo red stain on liver sections.

Histological examination of the stomach revealed perforation of the deepest ulcer with transmural infiltration of large numbers of neutrophils and fewer other leucocytes, with immature granulation tissue formation. The remaining non-ulcerated mucosa had moderate multifocal infiltration of lymphocytes and plasma cells in the lamina propria. Abundant, narrow, helicoidal rods (up to

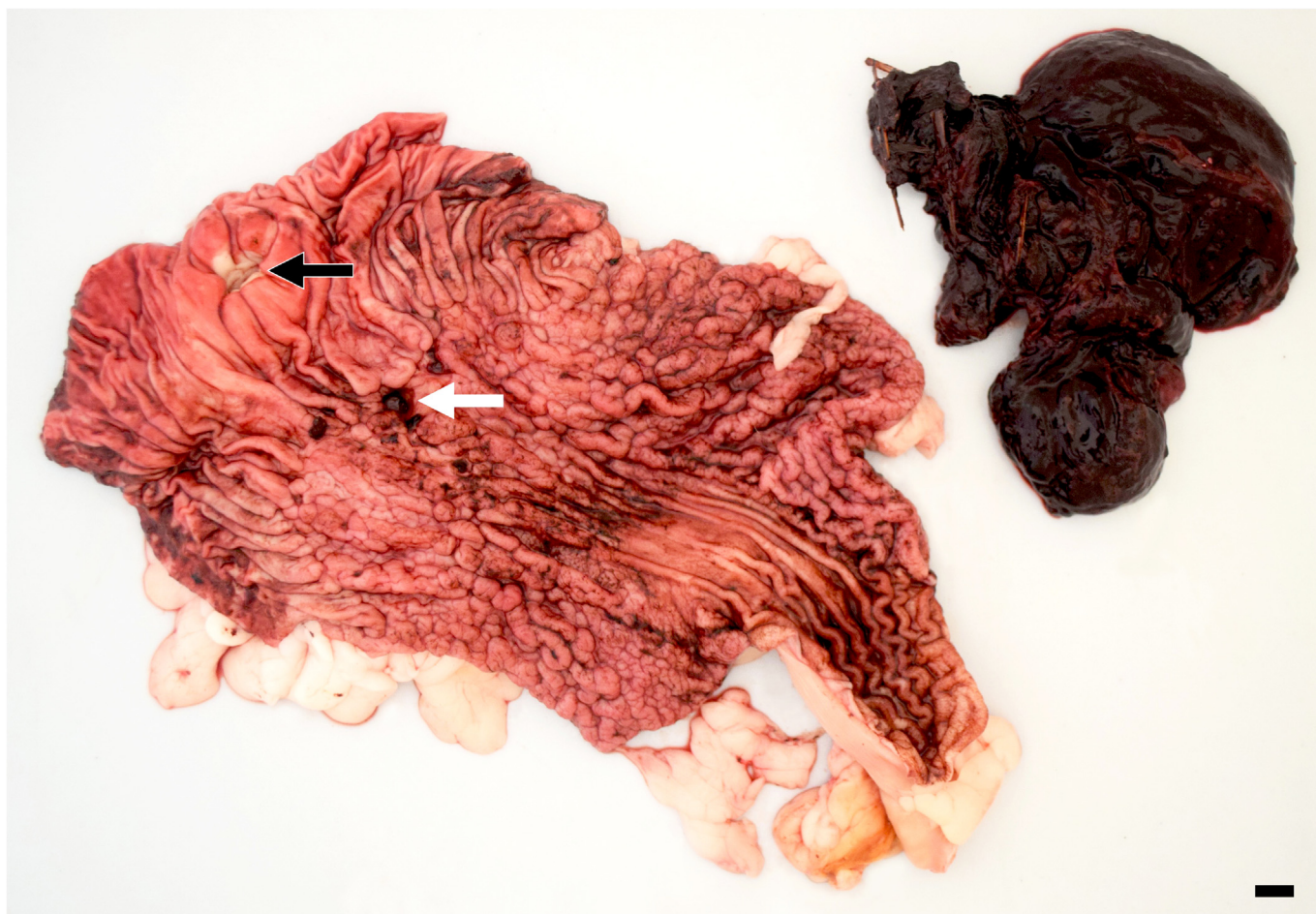

Fig. 1. Gastritis, *Helicobacter pylori*, stomach, cheetah. Diffuse, moderate thickening and reddening of gastric mucosa with a 1 cm diameter perforating ulcer (white arrow) 5 cm caudal to the cardia (black arrow). Blood clot (upper right) removed from gastric lumen measured $10.0 \times 7.0 \times 3.0$ cm. Bar, 1 cm.

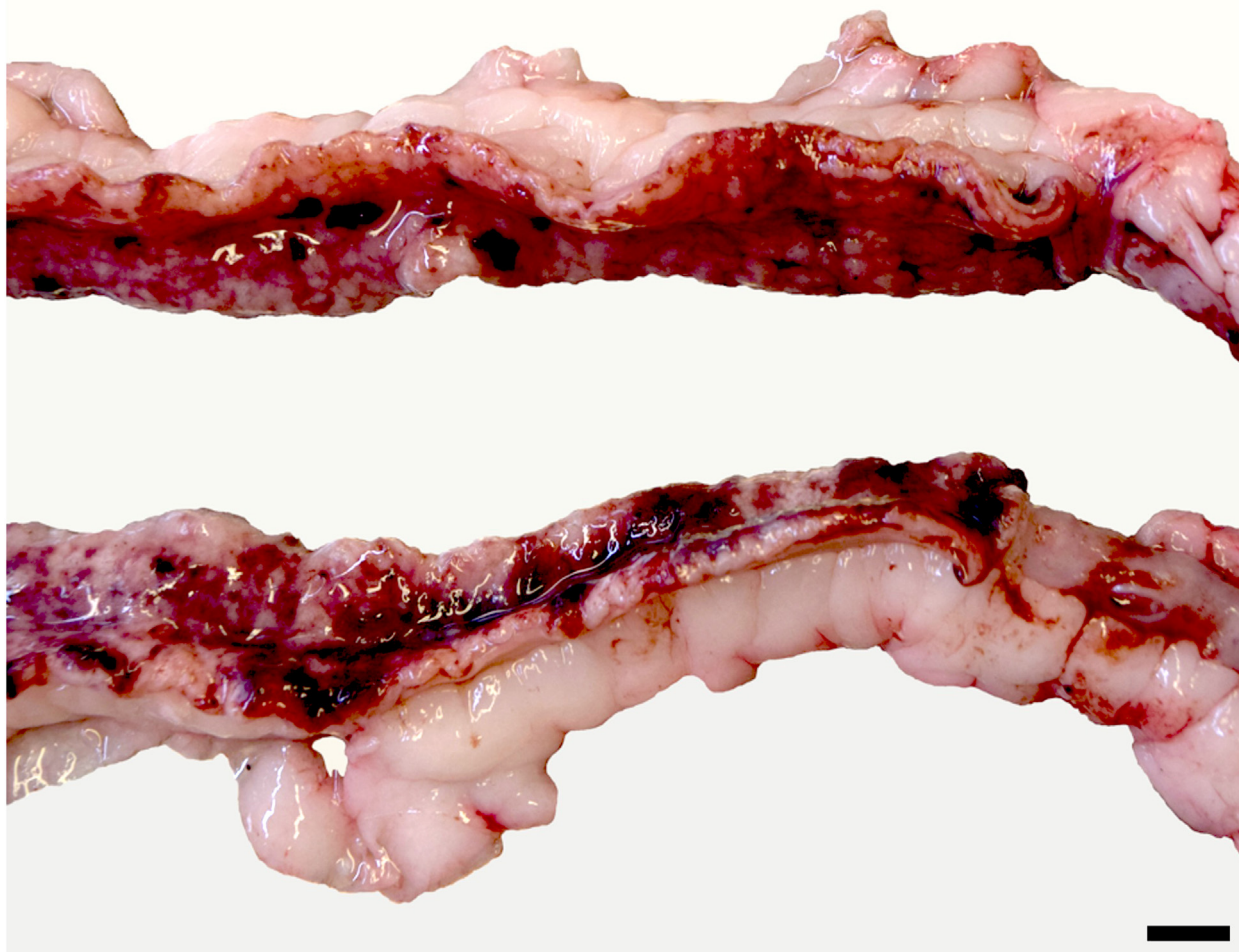

Fig. 2. Enteritis, *Campylobacter jejuni*, small intestine, cheetah. Moderate diffuse thickening and multifocal reddening of mucosa. Bar, 1 cm.

6.0 × 1.0 μm), staining dark brown to black with WS stain and morphologically compatible with *Helicobacter* spp, were present on the mucosal surface and in the lumen of gastric glands. The small and large intestines had numerous multifocal areas of necrosis with flattening and loss of enterocytes, loss of crypts and infiltration with numerous neutrophils as well as fewer lymphocytes and plasma cells (Fig. 3). The remaining mucosal and crypt epithelial cells were often hyperplastic and the crypt lumina were dilated and filled with cell debris and neutrophils, forming crypt abscesses. Numerous curved, spiral or gull-wing-shaped rods (up to 4.0 μm × 0.5 μm), stained dark brown to black with WS stain and were present multifocally on the mucosal surface and in crypt lumina (Fig. 4). The morphology of these bacteria was consistent with *Campylobacter* spp. Based on the pathomorphological findings, the following main diagnoses were made: (1) moderate to severe, necrotizing and neutrophilic enterocolitis with intralesional curved to spiral bacteria (compatible with *Campylobacter* spp); (2) moderate, focally-extensive, chronic gastritis with intralesional helicoidal bacteria (compatible with *Helicobacter* spp) and multifocal ulcerations, focal gastric perforation and subsequent focal

peritonitis. Additionally, the liver had mild to moderate multifocal amyloidosis with atrophy of hepatocytes, and there were lesions of mild multifocal endogenous lipid pneumonia, moderate multifocal vacuolar degeneration of renal tubules with mild regeneration, and multiple foci of extramedullary haematopoiesis in the spleen. The cause of death was considered to be a combination of blood loss and peritonitis originating from the gastric ulcers, together with dehydration secondary to the intestinal lesions and anorexia.

Causes of enteritis and colitis in cheetahs and other captive felids often correspond to those in domestic cats [12], including viral infections (eg, feline parvovirus and feline coronavirus) [13–15], bacterial enteritis or enterotoxigenesis [16,17] and endoparasitism [17,18]. Chronic gastritis with secondary amyloidosis is common in cheetahs, and an association with *Helicobacter* spp, although controversial, has been reported [19,20]. In the present case, quantitative PCR testing for *Helicobacter pylori* on formalin-fixed paraffin-embedded gastric tissue (modified from Sainsus *et al*, 2008 [21]) was positive. Further ancillary tests for specific pathogens including *Carnivore protoparvovirus 1* (PCR and immunohistochemistry [IHC]), canine distemper virus (PCR), *Salmonella* spp

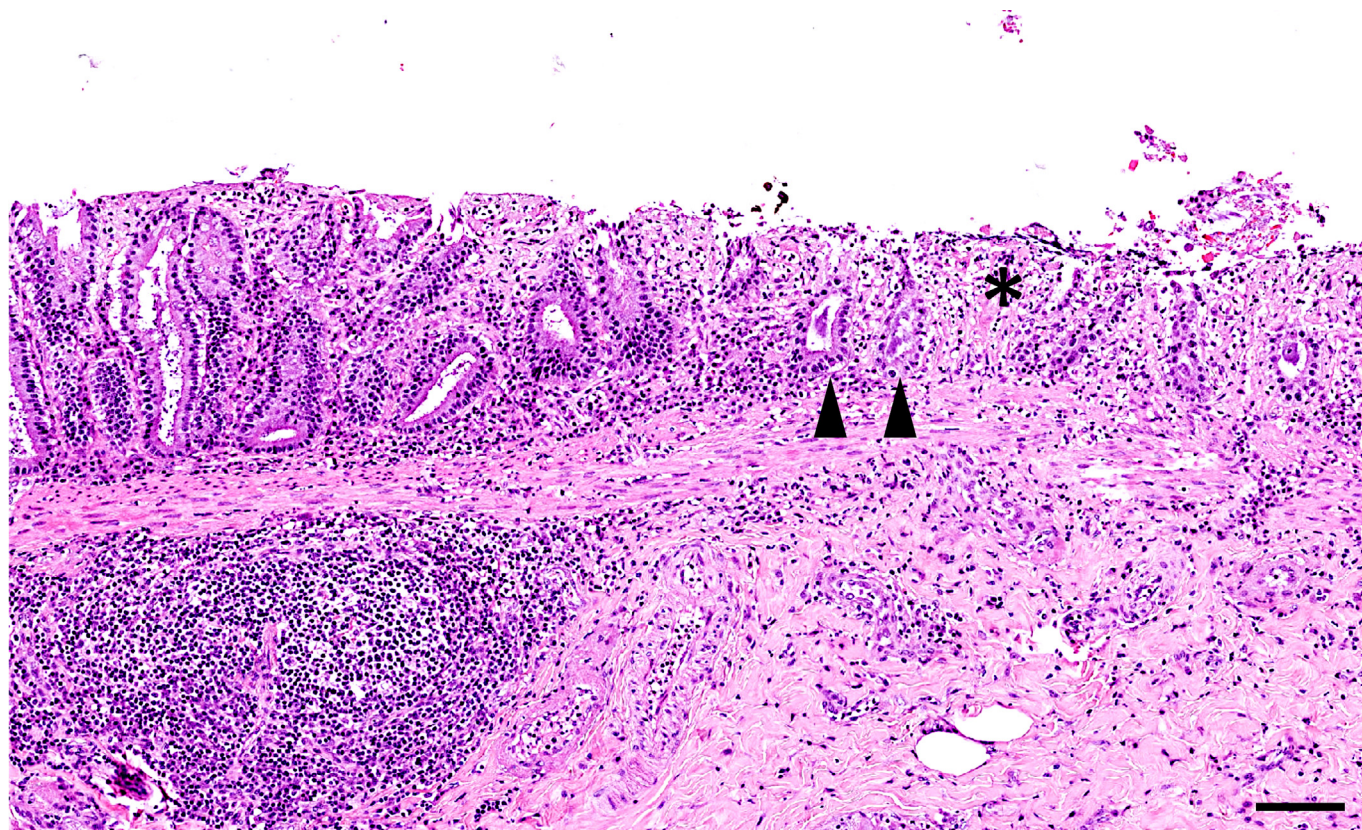


Fig. 3. Necrotizing neutrophilic colitis, *Campylobacter jejuni*, cheetah. Lamina propria and submucosa infiltrated by leucocytes, chiefly neutrophils. Area of mucosal necrosis and crypt loss (*). Some remaining crypts mildly dilated and filled with abundant basophilic material corresponding to bacteria (arrowheads). HE. Bar, 100 μ m.

(selective culture) and *Lawsonia intracellularis* (IHC) were all negative. No parasites were found macroscopically, histologically or by parasitological examination of intestinal content using the flotation method. Bacteriological culture of the small and large intestines revealed large numbers of *Campylobacter* spp, subsequently identified as *C. jejuni* by MALDI-TOF MS (Bruker, MBT Compass Library, Revision L [2020], www.bruker.com). These findings correlate with the ante-mortem faecal examination findings and the histologically observed bacteria. The pathogenetic role of *Campylobacter* infection in the cheetah is unclear and a causal association cannot be definitively proven without further investigations. However, the high numbers of *C. jejuni* isolated ante mortem and post mortem from faeces and intestinal contents, the observation of intralésional bacteria with morphology compatible with *Campylobacter* spp and the negative results for other common intestinal pathogens strongly suggest a role for *C. jejuni* in the pathogenesis of the enterocolitis.

Between 2017 and 2022, the presence of *Campylobacter* spp has regularly been investigated in routine faecal examinations or tissue cultures of exotic felids at the Basel Zoo, including a serval (*Leptailurus serval*), a lion (*Panthera leo*) and two snow leopards (*Panthera uncia*) with negative results, whereas three out of five tested cheetahs were positive in faecal culture. One cheetah (December 2017) was healthy, the second (February 2018) presented with inappetence and regurgitation and the third is the present case (February 2022). Gastric samples of the second cheetah revealed a moderate to severe erosive mixed cell gastritis with a positive *C. jejuni* gastric tissue culture. This cheetah, however, recovered after antibiotic treatment (marbofloxacin and amoxicillin-clavulanic acid) and omeprazole and was subsequently transferred to another zoo in a state of normal health.

Among captive felids, cheetahs seem to be more susceptible to gastrointestinal disease such as chronic gastritis (mostly *Helicobacter*-associated) [22–26]. This susceptibility seems to be linked to a variety of cheetah-specific factors, including lack of genetic diversity, chronic stress and diet [19,27]. Therefore, it can be hypothesized that captive cheetahs may have an increased susceptibility to *Campylobacter* infections compared with other felid species.

In humans, campylobacteriosis is the main cause of food-borne gastroenteritis and is histologically characterized by epithelial damage, neutrophilic infiltration of the glandular epithelium and hypercellularity of the lamina propria [28]. Neutrophilic crypt abscessation can also be present but crypt architecture typically remains intact. Although human campylobacteriosis frequently is a self-limiting disease and antibiotic therapy is controversial, several studies seem to indicate an association between *Campylobacter* infections and subsequent development of inflammatory bowel disease and more severe complications such as Guillain-Barré syndrome and reactive arthritis [29–33]. The intestinal lesions in this cheetah were very similar to those of human campylobacteriosis, supporting the potential association between the enterocolitis and the isolated *C. jejuni*. In addition, the gastritis with intralésional *H. pylori* in this case is compatible with *Helicobacter*-associated gastritis as described in captive cheetahs [25], representing a factor detrimental to the cheetah's general health status, which may have acted as a precursor and exacerbated the *C. jejuni* infection or vice versa.

The source of the *C. jejuni* infection in our case may be attributable to the chicken in the diet. It is probable that captive felids fed chicken frequently come in contact with *Campylobacter* spp without developing overt disease, as in domestic cats [4]. However, animals

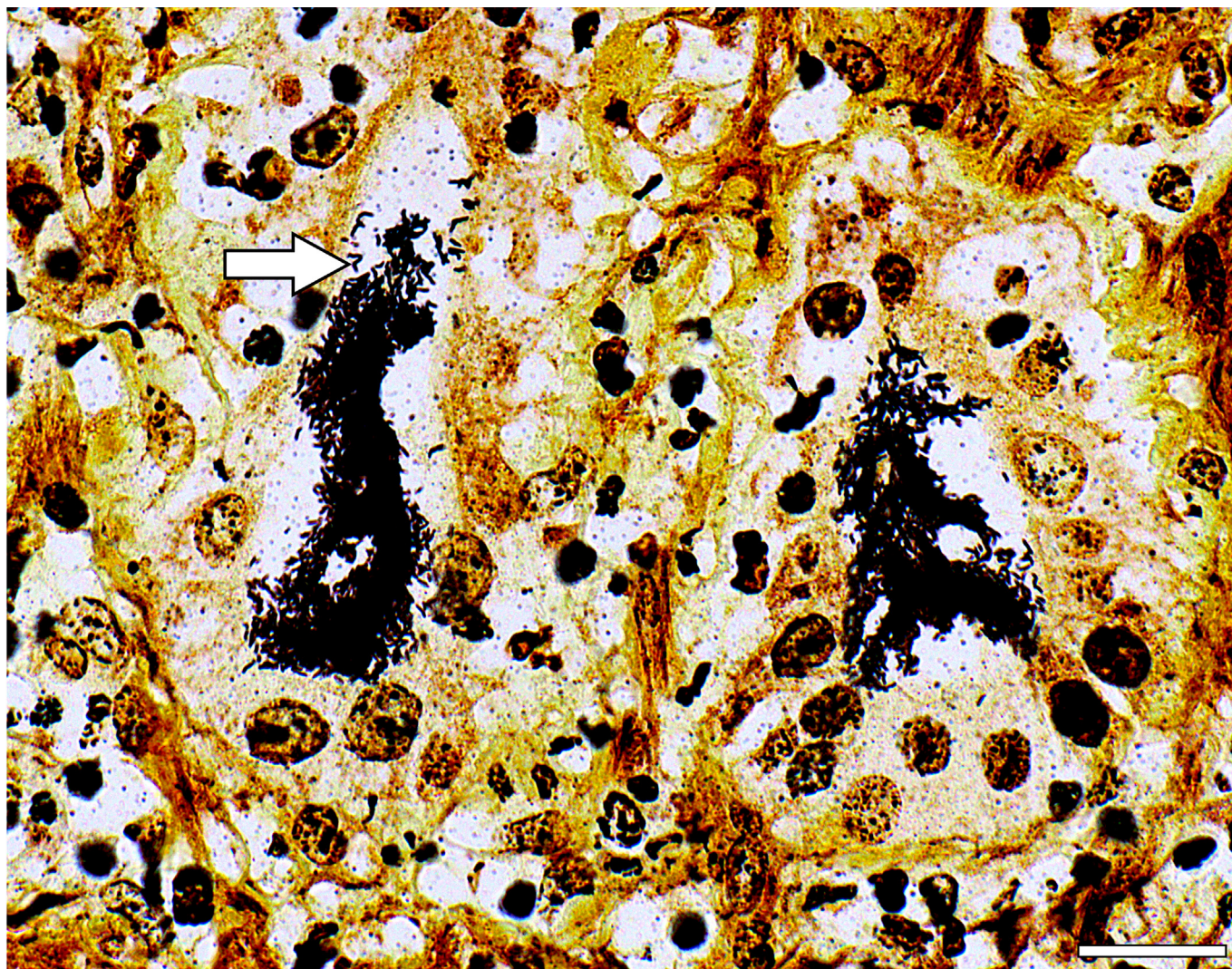


Fig. 4. Necrotizing neutrophilic colitis, *Campylobacter jejuni*, cheetah. Crypts filled with dark brown to black stained curved, gull-wing-shaped (arrow) or spiral organisms, consistent with *Campylobacter* spp. WS. Bar, 20 μ m.

with concurrent illnesses might be more susceptible to infection. As captive cheetahs are prone to gastrointestinal disease, they would benefit from a reduction in the amount of potential enteric pathogens in their diet. Due to the relevance of *Campylobacter* spp as human pathogens and since broiler chicken meat is one of the main sources for infection [3], several studies are focused on methods of carcass decontamination [34–36]. Freezing of carcasses has been shown to be very efficient against *Campylobacter* contamination in many studies [35]. A recent study in a Swiss poultry abattoir found a prevalence of 16.7% for *Campylobacter* spp, and the bacterial load was satisfactorily decreased to under 1,000 colony forming units/g after washing and air chilling [37]. A potential practical method for decontamination at zoo level would be to eviscerate, thoroughly wash and subsequently freeze the chicken carcasses, and this has been shown to be more efficient than air chilling [38].

In conclusion, campylobacteriosis should be considered in the list of potential differential aetiologies, particularly in cases presenting with concurrent vomiting, diarrhoea and melena. Given their zoonotic potential, *Campylobacter* infections should be taken seriously, especially in zoological environments where close contact with animals can occur and where prevalence and host range are unclear.

Declaration of competing interests

The authors declared no conflicts of interest with regard to the research, authorship or publication of this article.

References

- [1] Zbrun MV, Rossler E, Romero-Scharpen A, Soto LP, Berisvil A, Zimmermann JA, et al. Worldwide meta-analysis of the prevalence of *Campylobacter* in animal food products. *Res Vet Sci* 2020;132:69–77.
- [2] Zweifel C, Scheu KD, Keel M, Renggli F, Stephan R. Occurrence and genotypes of *Campylobacter* in broiler flocks, other farm animals, and the environment during several rearing periods on selected poultry farms. *Int J Food Microbiol* 2008;125:182–7.
- [3] EFSA and ECDC (European Food Safety Authority and European Centre for Disease Prevention and Control). The European Union One Health 2020 Zoonoses Report. *EFSA J* 2021;19:e06971.
- [4] Acke E. Campylobacteriosis in dogs and cats: a review. *N Z Vet J* 2018;66:221–8.
- [5] Clayton JB, Danzeisen JL, Johnson TJ, Trent AM, Hayer SS, Murphy T, et al. Characterization of *Campylobacter jejuni*, *Campylobacter upsaliensis*, and a novel *Campylobacter* sp. in a captive non-human primate zoological collection. *J Med Primatol* 2019;48:114–22.
- [6] De Luca C, Iraola G, Apostolakis I, Boetto E, Piccirillo A. Occurrence and diversity of *Campylobacter* species in captive chelonians. *Vet Microbiol* 2020;241:108567.

- [7] De Witte C, Lemmens C, Flahou B, De Laender P, Bouts T, Vercammen F, et al. Presence of *Helicobacter* and *Campylobacter* species in faecal samples from zoo mammals. *Vet Microbiol* 2018;219:49–52.
- [8] Kalashnikova VA, Dzhikidze EK, Stasilevich ZK, De Laender P, Bouts T, Vercammen F, et al. Detection of *Campylobacter jejuni* in healthy monkeys and monkeys with enteric infections by PCR. *Bull Exp Biol Med* 2002;134:299–300.
- [9] Misawa N, Shinohara S, Satoh H, Itoh H, Shinohara K, Shimomura K, et al. Isolation of *Campylobacter* species from zoo animals and polymerase chain reaction-based random amplified polymorphism DNA analysis. *Vet Microbiol* 2000;71:59–68.
- [10] Prince Milton AA, Agarwal RK, Priya GB, Saminathan M, Aravind M, Reddy A, et al. Prevalence of *Campylobacter jejuni* and *Campylobacter coli* in captive wildlife species of India. *Iran J Vet Res* 2017;18:177–82.
- [11] Stirling J, Griffith M, Blair I, Cormican M, Dooley JSG, Goldsmith CE, et al. Prevalence of gastrointestinal bacterial pathogens in a population of zoo animals. *Zoonoses Public Health* 2008;55:166–72.
- [12] Lamberski N. Felidae. In: Miller RE, Fowler ME, editors. *Fowler's zoo and wild animal medicine*. Vol 8. St Louis: WB Saunders; 2014. p. 467–76.
- [13] Gaffney PM, Kennedy M, Terio K, Gardner I, Lothamer I, Coleman K, et al. Detection of feline coronavirus in cheetah (*Acinonyx jubatus*) feces by reverse transcription-nested polymerase chain reaction in cheetahs with variable frequency of viral shedding. *J Zoo Wildl Med* 2012;43:776–86.
- [14] Heeney JL, Evermann JF, McKeirnan AJ, Marker-Kraus L, Roelke ME, Bush M, et al. Prevalence and implications of feline coronavirus infections of captive and free-ranging cheetahs (*Acinonyx jubatus*). *J Virol* 1990;64:1964–72.
- [15] Steinel A, Munson L, van Vuuren M, Truyen U. Genetic characterization of feline parvovirus sequences from various carnivores. *J Gen Virol* 2000;81:345–50.
- [16] Citino SB. Chronic, intermittent *Clostridium perfringens* enterotoxigenesis in a group of cheetahs (*Acinonyx jubatus jubatus*). *J Zoo Wildl Med* 1995;26:279–85.
- [17] Whitehouse-Tedd KM, Lefebvre SL, Janssens GPJ. Dietary factors associated with faecal consistency and other indicators of gastrointestinal health in the captive cheetah (*Acinonyx jubatus*). *PLoS One* 2015;10:e0120903.
- [18] Mény M, Schmidt-Küntzel A, Marker LL. Diagnosis-based treatment of helminths in captive and wild cheetahs (*Acinonyx jubatus*). *J Zoo Wildl Med* 2012;43:934–8.
- [19] Mangiaterra S, Marker L, Cerquetella M, Galosi L, Marchegiani A, Gavazza A, et al. Chronic stress-related gastroenteric pathology in cheetah: relation between intrinsic and extrinsic factors. *Biology (Basel)* 2022;11:606.
- [20] Munson L, Nesbit JW, Meltzer DG, Colly LP, Bolton L, Kriek NP. Diseases of captive cheetahs (*Acinonyx jubatus jubatus*) in South Africa: a 20-year retrospective survey. *J Zoo Wildl Med* 1999;30:342–7.
- [21] Sainsus N, Cattori V, Lepadatu C, Hofmann-Lehmann R. Liquid culture medium for the rapid cultivation of *Helicobacter pylori* from biopsy specimens. *Eur J Clin Microbiol Infect Dis* 2008;27:1209–17.
- [22] Metz O, Williams J, Nielsen RK, Masters N. Retrospective study of mortality in Asiatic lions (*Panthera leo persica*) in the European breeding population between 2000 and 2014. *Zoo Biol* 2017;36:66–73.
- [23] Napier JE, Lund MS, Armstrong DL, McAloose D. A retrospective study of morbidity and mortality in the North American amur leopard (*Panthera pardus orientalis*) population in zoologic institutions from 1992 to 2014. *J Zoo Wildl Med* 2018;49:70–8.
- [24] Norton BB, Tunseth D, Holder K, Brigga M, Hayek L-AC, Murray S. Causes of morbidity in captive African lions (*Panthera leo*) in North America, 2001–2016. *Zoo Biol* 2018;37:354–9.
- [25] Terio KA, Munson L, Moore PF. Characterization of the gastric immune response in cheetahs (*Acinonyx jubatus*) with *Helicobacter*-associated gastritis. *Vet Pathol* 2012;49:824–33.
- [26] Womble M, Georoff TA, Helmick K, Carpenter NA, Joslin J, Tupa L, et al. Mortality review for the North American snow leopard (*Panthera uncia*) zoo population from January 1999 to December 2019. *J Zoo Wildl Med* 2021;52:145–56.
- [27] Munson L, Terio KA, Worley M, Jago M, Bagot-Smith A, Marker L. Extrinsic factors significantly affect patterns of disease in free-ranging and captive cheetah (*Acinonyx jubatus*) populations. *J Wildl Dis* 2005;41:542–8.
- [28] Lamps LW. Update on infectious enterocolitides and the diseases that they mimic. *Histopathology* 2015;66:3–14.
- [29] Gradel KO, Nielsen HL, Schönheyder HC, Ejlersen T, Kristensen B, Nielsen H. Increased short- and long-term risk of inflammatory bowel disease after *Salmonella* or *Campylobacter* gastroenteritis. *Gastroenterology* 2009;137:495–501.
- [30] Kaakoush NO, Mitchell HM, Man SM. Role of emerging *Campylobacter* species in inflammatory bowel diseases. *Inflamm Bowel Dis* 2014;20:2189–97.
- [31] Mahendran V, Riordan SM, Grimm MC, Tran TAT, Major J, Kaakoush NO, et al. Prevalence of *Campylobacter* species in adult Crohn's disease and the preferential colonization sites of *Campylobacter* species in the human intestine. *PLoS One* 2011;6:e25417.
- [32] Pope JE, Krizova A, Garg AX, Thiessen-Philbrook H, Ouimet JM. *Campylobacter* reactive arthritis: a systematic review. *Semin Arthritis Rheum* 2007;37:48–55.
- [33] Yuki N, Susuki K, Koga M, Nishimoto Y, Odaka M, Hirata K, et al. Carbohydrate mimicry human ganglioside GM1 and *Campylobacter jejuni* lipooligosaccharide causes Guillain-Barré syndrome. *Proc Natl Acad Sci USA* 2004;101:11404–9.
- [34] Gürbüz M, İrem Omurtag Korkmaz B. The anti-campylobacter activity of eugenol and its potential for poultry meat safety: a review. *Food Chem* 2022;394:133519.
- [35] Loretz M, Stephan R, Zweifel C. Antimicrobial activity of decontamination treatments for poultry carcasses: a literature survey. *Food Control* 2010;21:791–804.
- [36] Vetchapitak T, Shinki T, Sasaki S, Taniguchi T, Luangtongkum T, Misawa N, et al. Evaluation of chemical treatment combined with vacuum and ultrasonication with a water resonance system for reducing *Campylobacter* on naturally contaminated chicken carcasses. *Food Control* 2020;112:107087.
- [37] Buess S, Zurfluh K, Stephan R, Guldimann C. Quantitative microbiological slaughter process analysis in a large-scale Swiss poultry abattoir. *Food Control* 2019;105:86–93.
- [38] Boysen L, Rosenquist H. Reduction of thermotolerant *Campylobacter* species on broiler carcasses following physical decontamination at slaughter. *J Food Prot* 2009;72:497–502.