



Lameness Localization in Dogs: An Exploratory Study of the Translation of the Equine Flexion Test to Canine Orthopaedics

Diane Grosjean¹  Evelien De Bakker¹  Amélie Mugnier² Francis Verschooten³ Ulrich Rytz³ 
Franck Forterre³  Yves Samoy¹  Bernadette Van Ryssen¹

¹Department of Medical Imaging and Small Animal Orthopedics, Ghent University – Faculteit Diergeneeskunde, Merelbeke, Belgium

²NeoCare – Néonatalogie des Carnivores, Reproduction et Elevage, Université de Toulouse, ENVT, Toulouse Cedex 3, France

³Department of Large Animal Surgery and Anesthesia, Ghent University – Faculteit Diergeneeskunde, Merelbeke, Belgium

⁴Department für Klinische Veterinärmedizin – Kleintierklinik – Chirurgie, Universität Bern – Vetsuisse-Facultät, Bern, Switzerland

Address for correspondence Diane Grosjean, DVM, Department of Medical Imaging and Small Animal Orthopedics, Ghent University – Faculteit Diergeneeskunde, Salisburylaan 133, 9820 Merelbeke, Belgium (e-mail: diane.grosjean@ugent.be).

VCOT Open 2022;5:e116–e122.

Abstract

Objectives The aim of this study was to describe the method and feasibility of the flexion test (FT) as a diagnostic tool to localize lameness on dogs.

Study Design Canine FT was designed and based on the FT routinely used on horses. In dogs, the test consisted in a flexion of a joint to its full range of motion for 1 minute. Eventual increased lameness was then evaluated. The gait was evaluated using a visual analogue scale. An increase in the lameness score compared with the baseline score was considered as a positive result.

The method was described for every major joint of the appendicular skeleton and was evaluated in sound and lame dogs. To evaluate the feasibility, the FT was applied for 3 minutes in eight healthy dogs on all joints. On 27 clinically lame dogs, flexion was applied for 1 minute on the joints with a suspected pathology and on their contralateral side used as a control.

Results The FT was feasible and well tolerated by the sound dogs on all joints and no positive results were recorded. On clinically lame dogs, lameness increased in 81.5% of dogs. These cases were afterwards diagnosed with an orthopaedic-related disorder and then defined as true positives. False negative results occurred in 18.5% of the lameness cases.

Conclusion The FT is safe and easy to perform. It did not produce any false positive results. False negatives might occur in a minor number of cases, implying that a negative result does not exclude a joint pathology.

Keywords

- ▶ lameness evaluation
- ▶ orthopaedic examination
- ▶ joint pain
- ▶ diagnostic tool
- ▶ locomotor system

Introduction

Lameness is a common complaint in small animal veterinary medicine. The orthopaedic examination is performed by visual and manual evaluation of the patient. In most cases,

the affected limb is identified, but the exact origin within this limb can remain unclear and challenging.

In equine veterinary practice, a specific physical exam was developed for orthopaedic health and locomotion evaluation. This test is called ‘flexion test’ (FT) and is routinely

received
September 3, 2021
accepted after revision
March 29, 2022

DOI <https://doi.org/10.1055/s-0042-1750036>.
ISSN 2625-2325.

© 2022. The Author(s).
This is an open access article published by Thieme under the terms of the Creative Commons Attribution License, permitting unrestricted use, distribution, and reproduction so long as the original work is properly cited. (<https://creativecommons.org/licenses/by/4.0/>)
Georg Thieme Verlag KG, Rüdigerstraße 14, 70469 Stuttgart, Germany

performed during gait assessment, lameness evaluation and pre-purchase examinations.¹⁻³

The FT in the horse is defined by a pain response triggered after the flexion of a joint to its physiological maximum range of motion for a defined period.^{3,4} This position creates a compression of the joint structures and a stretching of its surrounding soft tissues, such as ligaments and tendons, which can trigger a pain reaction.^{5,6} Directly after applying this technique, the horse is walked on a hard surface on a straight line to evaluate his gait, immediately graded according to its duration expressed in meters.^{7,8}

Previous research in horses' orthopaedics agrees on this tool's sensitivity to assess pain in a joint area, but not on its specificity to diagnose a joint pathology.^{5,9} The controlled parameter to apply a FT on all joints in this species is test duration when a combination with force application is only described for the lower limb.⁸

In human medicine, different types of FT have been described and some were developed for specific purposes. For example, to assess neck pain, a craniocervical FT is performed to evaluate the neuromotor control of the neck-deep flexors muscles,¹⁰ when the use of a passive neck FT aims to be more precise for meningitis and spinal disorders.¹¹ Other tests were developed to diagnose a specific pathology, such as the shoulder internal rotation test and the elbow FT for cubital tunnel syndrome¹²⁻¹⁴; Phalen's wrist FT for carpal tunnel syndrome¹⁵; Mill's test (extension of the wrist) for lateral epicondylitis¹⁴; and finally, to diagnose the De Quervain's disease: Finkelstein's, Eichhoff's and wrist hyperflexion and abduction of the thumb tests can be performed.^{14,16}

The purpose of those tests in human medicine has a different goal compared with the use in veterinary medicine, where it is only described for pain evaluation in a region and is non-specific for a pathology.

The theoretics behind the FT are based on the pain response to a flexed position and continuous tension and compression of a joint including the surrounding soft tissues.⁸ Different types of mechanoreceptors are described in the joint, muscle and skin.^{17,18} Ruffini receptors and free nerve endings appear as the major receptors in the shoulder and knee joint structures, including capsule, muscle tendons, intra-articular and collateral ligaments.^{19,20} Other mechanoreceptors are described at the musculotendinous junction such as the Golgi-organ tendon and muscle spindles.¹⁷ Furthermore, specialized Schwann cells present nociceptive perception ability in the skin.²¹ During the FT, the blood pressure in the subchondral bone vessels may increase.^{6,8} Then, the mechanoreceptors of the joint area can detect a modification in their own stretching or in their adjacent tissues. The consecutive mechanical deformation on the cell membrane allows entrance of Na⁺ ions into the cell creating a depolarization and generation of a nerve receptor potential.¹⁷ This can create a pain response observed as a temporary lameness.⁴

To the author's knowledge, the FT applied to dogs is not described in the literature yet.

The aim of this study is to evaluate the FT applied on canine lameness cases as an additional technique to find the painful area source of orthopaedic problems. Our hypothesis is that dogs would easily allow a FT and that lameness might increase when the FT is applied to an affected joint.

Technique, Materials, and Methods

Technique

Based on a complete standard orthopaedic evaluation consisting of history, inspection at walk and trot, joint palpation and subjective muscle mass evaluation to look for atrophy,²² the most suspected joint, or joints, are determined. Every suspected joint is separately subjected to the FT. To evaluate the test a hard, even, homogeneous, and non-slippery surface of 10 to 15 m should be available. After the orthopaedic examination and immediately before the FT, the dog is walked in trot on a straight line back and forth. The lameness score of this walk is used as the reference to interpret the FT.

Two people are required to perform the test: a veterinarian to flex the joint, while the other person holds the head. For uncooperative animals, a third person might be necessary to hold the patient's body and prevent the dog from moving away. The veterinarian performing the FT should hold the joint into the flexed position for one minute. The flexed position is a complete flexion of the joint to its maximum range of motion. With one hand a constant pressure is maintained on the limb to hold and lock the position. The second hand is applied as counterpressure. Attention should be paid for correct manipulation and positioning (see ►Fig. 1). For the front leg toes, one hand pushes the dorsal surface of the toes towards the palmar surface of the carpus. Counterpressure with the other hand is given on the carpus and metacarpi (►Fig. 1A, B). For hind leg toes, in the case of a full toes flexion test, one hand pushes the dorsal surface of the toes towards the palmar surface of the metatarsi. The other hand maintains the metacarpi and tarsal bones (►Fig. 1C, D). Alternative option using the same positioning to perform a single toe flexion test (►Fig. 1E). For the carpus, one hand pushes on the dorsal surface of the toes and metacarpi towards the palmar surface of the front arm. Counterpressure is given with the other hand on the dorsal surface of the front arm (►Fig. 1F, G). For the elbow, a vertical force is applied to flex the elbow by holding the carpi and metacarpi in one hand like a door handle. Counterpressure is applied by the second hand on the dorsal border of the scapula (►Fig. 1H, I). For the shoulder, a vertical force is applied to flex the shoulder by holding in one hand the distal and cranial aspect of the humerus just above the elbow joint. Counterpressure is applied by the second hand on the dorsal border of the scapula (►Fig. 1J, K). For the tarsus, option more stressful on the tarsal joint with the stifle in moderate flexion: the plantar surface of the foot is pushed towards the cranial aspect of the tibia. Counterpressure is given on the femur by pushing in the direction of the tibial bone (►Fig. 1L, M). Option less stressful for the stifle area when sensitive: same technique is performed except for the counterpressure applied directly on the caudal aspect of the tibia




Fig. 1 Technique to apply the flexion test on dogs. *Blue arrow*: direction of the force applied to flex the joint. *Orange arrow*: direction of the counterpressure force applied to stabilize the position.

and talus (►Fig. 1N, O). For the stifle, a vertical force is applied towards the tuber ischium to flex the knee by holding the tarsus and metatarsi in one hand like a door handle. Counterpressure is given on the other side of the pelvis pushing latero-medially on the gluteus muscle and ilium wing (►Fig. 1P, Q). The flexion test of the hip is performed by applying a vertical force on the caudal surface of the femur. The stifle level should pass above the dorsal line. Counterpressure is given on the other side of the pelvis pushing latero-medially and dorso-ventrally on the gluteus muscle and ilium wing (►Fig. 1R, S). Specific recommendations apply to the tarsus and toe FTs. The FT of the tarsus should always start first with a stifle FT to exclude a positive test. Then the tarsus can be tested. A concomitant flexion of the stifle joint due to the extensor digitorum longus of minor importance will occur. Indeed, pain of the stifle joint area was previously excluded. Same advice applies to the toes:

considering the high level of difficulty to keep the dog calm with a completely extended limb during the FT of the toes, this test should be only performed once all the other tests from this limb are confirmed as negative. Then the FT can be safely performed on the toe area, even if the patient is keeping his limb retracted.

The force applied is adapted to the size of the animal. Ideally, a third assistant should manage the chronometer for timing and camera for filming the gait immediately after releasing the test.

During the test, signs of discomfort and pain should be noted.

After 1 minute of constant flexion, the limb is released, and the dog is immediately walked in trot on a straight line back and forth. The pace should be similar as the reference walk performed before the test and the speed is evaluated subjectively by the evaluator.

To interpret the FT, lameness score was evaluated using the four points visual analogue scale (VAS) described by Brunberg.²³ The four scores possibly given are not lame (0), mild lameness,¹ moderate lameness,² and severe lameness.³ The first steps should be especially considered to evaluate the starting stiffness. This score should be compared with the initial lameness score. An increased lameness score of at least one point indicates a positive FT.

Materials and Methods

To perform this study two groups were created. All dogs were evaluated by an ECVSMR diplomate. None of the dogs underwent an invasive procedure according to ethical animal care and use applicable regulation. An informed consent document relative to this study procedure was provided to the owners. All dogs were included in the present study with their owner's consent.

The control group consisted of clinically eight sound adult client-owned dogs. These dogs of random breed and age had no lameness complaints and had a normal orthopaedic examination. Those dogs underwent medical imaging testing (radiographs of major joints) to exclude any orthopaedic abnormalities and define them as sound dogs. All dogs of this group underwent a FT of every major joint of the appendicular skeleton (carpi, elbows, shoulders, tarsi, stifles, hips, and toes) with an interval of at least 1 minute between each test. To evaluate the feasibility and tolerance of the method, the FT was prolonged to 3 minutes. This prolonged test also aims to test the hypothesis that the FT does not create false positive results even on a longer application.

The clinical group consisted of 27 client-owned dogs presented with complaints of unilateral lameness but not necessarily at the moment of the clinical examination. In all cases, the affected joint was identified on clinical examination. These dogs were from random breed and age. In this group, a FT of 1 minute was performed immediately after the orthopaedic examination. As a control, a FT was first applied on the contralateral sound joint before testing the suspected joint. On all dogs, the return to the baseline lameness was timed after the end of the test. The results of the FT of the clinical group were compared with the final diagnostic based on the history, physical examination and complementary investigations. These include all medical imaging results (radiographic images, computed tomography scanners and arthroscopic pictures when available). In all cases, the contralateral joint was investigated using the identical medical imaging diagnostic technique.

Definitions used for the results classification are 'true positive' if the lameness increased after the FT and joint pathology was present; when no orthopaedic diagnostic could be found, the test was considered 'false positive' for that joint. 'False negative' results imply that there was no increase of lameness after the test, but there was an orthopaedic diagnostic supported by medical imaging results. Descriptive percentages will be used to characterize the findings of this protocol.

Statistical Analysis

A Wilcoxon signed rank test was used to compare the lameness scores before and after performing the FT. A *p*-value less than 0.05 was considered significant.

Results

The control group consisted of eight dogs of various breeds, from medium size as an English cocker spaniel (12 kg) to large breed as a cane corso italiano (43 kg) (median weight: 24.6 kg). The age varied between 6 months and 8 years (median: 5 years). Four (50%) of them were female and four male (50%). All dogs presented a normal clinical and orthopaedic examination and were defined as healthy dogs after performing medical imaging testing to screen them for orthopaedic pathologies. The FT was performed on 128 joints. None of the dogs showed any lameness or gait abnormalities after performing the FT. The FT in the sound dogs was thus considered negative in 100% of the cases.

In the clinical group, a total of 27 dogs of various size, from Jack Russel Terrier (7 kg) to Rottweiler (52 kg) (median: 30.9 kg), were included in this study. Age varied from 7 months to 10 years (median: 4 years), and 14 (51%) were females and 13 (49%) were males. Seventeen dogs (63%) were lame on a forelimb (11 left and 6 right) and 10 (37%) were lame on a hindlimb (6 on the left and 4 on the right). The control FT of the sound contralateral side was negative on all 27 dogs (specificity 100%). This means the clinical examinations did not show any abnormalities on those joints and there were no indications for a pathology on available imaging techniques either. The 27 dogs were then tested with the FT on their contralateral side suspected of a pathology based on the clinical evaluation. FT of the suspected joints showed an increased lameness in 22 dogs (81.48%). In those cases, the lameness was specifically observed during the first 5 to 20 steps after releasing the test (median: 10 steps). The increase in lameness was fading away after a minimum of 1 minute, to a maximum of 5 minutes after ending the FT (median: 2 minutes). The VAS lameness score after the FT was compared with the initial VAS lameness score. The Wilcoxon signed rank test performed showed a significant increase in the lameness scores recorded before compared with after performing the FT on this group ($p < 0.001$) as shown in **►Fig. 2. ►Fig. 3** shows that five dogs were not lame, but revealed an abnormal palpatory examination suggestive of an orthopaedic pathology before the evaluation with the FT. Two of them revealed a mild lameness after the FT, while three of them remained lame-free. Fourteen dogs were presented with a mild lameness before the FT: in 11 dogs the lameness score increased with one point after the test—from mild to moderate and in 2 dogs with two points—from mild to severe. In one dog, lameness had not deteriorated. All the seven dogs with moderate lameness showed an increased lameness after performing the FT—from moderate to severe. One dog with severe (non-weight bearing) lameness remained the same after the test. None of the tested dogs became non-weight bearing after the FT.

Based on the orthopaedic examination and medical imaging records, these 27 joints were evaluated and diagnosed with orthopaedic pathology.

Among these, 13 presented with elbow dysplasia, 6 had a cruciate ligament rupture, 3 had tarsal osteochondrosis

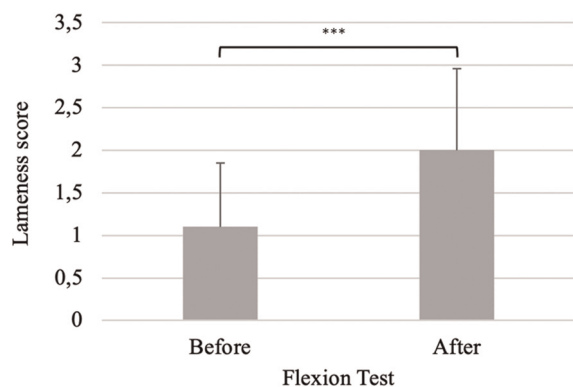


Fig. 2 Comparison of the lameness score before and after performing the flexion test using a Wilcoxon signed-rank test. The histogram represents the mean of lameness scores and the T bar indicates the standard deviation. The statistical difference is mentioned on the horizontal bar. *** indicates a highly significant difference ($p < 0.001$).

dissecans (OCD) and 2 suffered from shoulder OCD. Three dogs presented random musculoskeletal conditions such as osteoarthritis, cushion wound and surgical implant reaction.

Based on the observations mentioned above, 22 true positive results (81.48%) were recorded after the use of a FT on this sample population. Those 22 cases were afterwards confirmed to have an orthopaedic-related diagnostic on medical imaging results or clinical examination. Five false negative results occurred (18.52%): those patients were negative because their lameness did not increase after applying the test. However, these patients had an abnormal orthopaedic examination suggestive of a pathology. This was later confirmed by medical imaging evidence of orthopaedic lesions. Four of them were later diagnosed with an elbow pathology (all presented a fissure of the medial coronoid process). One was a partial cruciate ligament rupture. Prevalence of true positives and false negative is detailed in **Table 1**.

Discussion

Orthopaedic diagnostic on the canine species remains a challenging task, even in times where medical imaging diagnostic increases in performance and reliability. Over the last years, several orthopaedic publications focus on

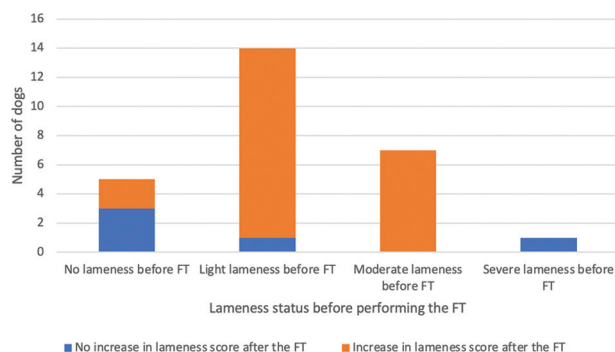


Fig. 3 Outcome of the flexion test (FT) performed on dogs with a suspected orthopaedic disease.

Table 1 Flexion test outcome compared with the definitive orthopaedic diagnosis in the lame group

	True positive	False negative
Shoulder	2	0
Stifle	6	1
Elbow	9	4
Tarsus	3	0
Carpus	1	0
Toe	1	0

clinical joint evaluation, indicating that there is still a need for improvement.²⁴⁻²⁶ Therefore, increasing the diversity of tools at our disposal for joint examination is opportune. This article aims to expand the orthopaedic clinical examination in small animal veterinary medicine. Since the described FT does not require extra equipment and only takes a few minutes, it can be easily incorporated in the standard canine orthopaedic examination.

The FT was adapted from the one described in equine medicine.^{3,8} The FT method is quite alike in horses and dogs, but the first steps are interpreted differently. On horses, the first three steps are not included because of the mechanoreceptors response to the non-physiological tension,⁸ while in the dog the first five steps were considered as important as the others as described in the results above. When the articular flexion of canine joints is performed within physiological borders, the increase in lameness induced by the FT is not permanent. Equine studies demonstrated that a weekly FT applied on a horse did not induce permanent lameness.^{4,8} This correlates with the observation of this study: the increase in lameness was fading away after a maximum of 5 minutes following the FT.

In the clinical group, the use of the FT could temporarily enhance lameness in 81.5% of the cases with confirmed pathologic joints on medical imaging records. The significant difference found between the lameness scores recorded before and after the test confirms the ability of the FT to enhance lameness when applied to a joint with pathologic features. No false positive results were recorded among the control group that underwent even a 3-minute FT nor on the contralateral healthy joints in the clinical group that were flexed for 1 minute. This strengthens the believe that a normal joint flexed for 1 minute will not result in a false positive test. Furthermore, duration has been studied in the equine species concluding a shorter time of flexion resulted into a lower probability of a positive FT.^{8,27} However, one equine proceeding reports no correlation between radiographic abnormalities and positive FT on sound horses.⁹ This highlights the importance of the use of the FT in addition to the complete orthopaedic examination (gait assessment, muscle symmetry, joint effusion, pain and range of motion²²).

The use of the FT also revealed false negative results in 18.5% of the patients. This means that lameness had not increased after applying the test on a suspicious joint, while

the presence of a joint pathology was afterwards confirmed by medical imaging diagnostic. One explanation could be the lack of force applied to the joint. Further research is necessary to define if the false negative results could drop by applying a standardized force during the FT or with a longer duration. However, feasibility of such measurements is difficult. Another explanation can be the type of structures involved and severity of the pathology. Mechanoreceptors are present in joint structures and surrounding soft tissue.¹⁸ In our results, we observed positive FTs on cases diagnosed with soft tissue-related conditions such as a flexor enthesopathy and a toe cushion wound. The response to the FT for soft tissue-related pathologies was similar as the response observed for joint pathologies.

The results in the clinical group suggest that the reaction to the FT is influenced by the severity of the lameness. Furthermore, the FT response observed was similar in all tested joints areas.

Observations can be described on the population of this study. First, the non-lame dogs at presentation are likely to give false negative results in cases (the FT was only positive on 2 cases out of 5). A possible explanation to this observation is the inflammation of the joint is so minimal that the application of the FT does not induce enough stress on the affected joint. Second, most dogs with a mild or moderate lameness reacted to the FT with an increase of one or two lameness grades (Only two dogs from the mild lameness group were negative after the test, while all dogs from the moderate group showed a positive FT). This supports the hypothesis for the FT to temporarily worsen a lameness on joints that are painful or inflamed. Furthermore, the FT accentuates a lameness so that no doubt remains and the lameness appears more clearly. A third observation: on dogs with severe lameness upon presentation (grade 4/4), the FT could not report any worsening of the lameness based on the four points VAS even if lameness had increased. This appears like a misleading conclusion that the FT is negative on those patients, when using a scoring system that is not sensitive enough to report subtle changes in severe lameness. This specific point highlights the potential weakness of the four points scale. Although it has been intensively used to score the FT in several equine lower limb studies, it might not be the ideal way to score canine lameness.^{7,8} Suggestion for further research would be a combination with pressure plate evaluation to precise the way of scoring.^{28,29} In equine medicine, objective means of gait evaluation with the use of inertial sensors has been explored to this purpose,^{30,31} but are prone to further research on dogs.

There are some limitations to this study. The first one is the limited number of animals included in this pilot study. The effect of the FT should be repeated in a larger cohort of dogs to provide an accurate evaluation of the reliability of this test. The second limitation is the application of the test on selected unilateral lameness cases which does not represent a random population. The third limitation is the lack of a standardized force evaluation as suggested on equine lower limb studies. However, force measurement would be practically difficult to perform on dogs. Equine studies showed that

the force applied during the flexion may influence the outcome of the test.^{7,8,23} A force of 100 N is mentioned in the equine species⁸ however, it is not measured routinely in practice. Further research is needed to determine exact force determination and support the repeatability of this test but this might not be possible on dogs. Inter- and intra-observer reliability of the VAS is described to score canine lameness.³² This leads to the last limitations of this study: the subjectivity of the VAS and the non-blinded status of the evaluator in this clinical environment. Finally, a lead of improvement is to correlate the FT result with the intra-articular inflammation using a synovial analysis.

Conclusion

This exploratory study confirms that the application of the FT to allocate pain in a joint area on dogs is a valid concept. Thus, the FT should be considered as an additional tool to the orthopaedic examination in dogs. Further large-scale studies are necessary to evaluate the reliability of this test.

Conflict of Interest

None.

References

- Davidson EJ. Lameness evaluation of the athletic horse. *Vet Clin North Am Equine Pract* 2018;34(02):181–191
- Mantell JA. Use of the flexion test in the pre-purchase examinations in horses. 1998;142(12):314
- Verschooten F. The locomotory system of the purchase examination in the horse. *Equine Pract.* 1992;14(08):8–16
- Busschers E, van Weeren PR. Use of the flexion test of the distal forelimb in the sound horse: repeatability and effect of age, gender, weight, height and fetlock joint range of motion. *J Vet Med A Physiol Pathol Clin Med* 2001;48(07):413–427
- Kearney CM, van Weeren PR, Cornelissen BP, den Boon P, Brama PA. Which anatomical region determines a positive flexion test of the distal aspect of a forelimb in a nonlame horse? *Equine Vet J* 2010;42(06):547–551
- Keg PR, van Weeren PR, Schamhardt HC, Barneveld A. Variations in the force applied to flexion tests of the distal limb of horses. *Vet Rec* 1997;141(17):435–438
- Keg PR, van Weeren PR, Back W, Barneveld A. Influence of the force applied and its period of application on the outcome of the flexion test of the distal forelimb of the horse. *Vet Rec* 1997;141(18):463–466
- Verschooten F, Verbeeck J. Flexion test of the metacarpophalangeal and interphalangeal joints and flexion angle of the metacarpophalangeal joint in sound horses. *Equine Vet J* 1997;29(01):50–54
- Ramey DW. Prospective Evaluation of Forelimb Flexion Tests in Practice: Clinical Response, Radiographic Correlations, and Predictive Value for Future Lameness. Proceeding presented at: Annual Convention of the American Association of Equine Practitioners, Vol 43; 1997
- Jull GA, O'Leary SP, Falla DL. Clinical assessment of the deep cervical flexor muscles: the craniocervical flexion test. *J Manipulative Physiol Ther* 2008;31(07):525–533
- López-de-Uralde-Villanueva I, Acuyo-Osorio M, Prieto-Aldana M, La Touche R. Reliability and minimal detectable change of a modified passive neck flexion test in patients with chronic nonspecific neck pain and asymptomatic subjects. *Musculoskeletal Sci Pract* 2017;28:10–17

- 12 Ochi K, Horiuchi Y, Nakamichi N, Morita K, Okada E, Hasegawa T. Association between the elbow flexion test and extraneural pressure inside the cubital tunnel. *J Hand Surg Am* 2011;36(02):216–221
- 13 Ochi K, Horiuchi Y, Tanabe A, Morita K, Takeda K, Ninomiya K. Comparison of shoulder internal rotation test with the elbow flexion test in the diagnosis of cubital tunnel syndrome. *J Hand Surg Am* 2011;36(05):782–787
- 14 Valdes K, LaStayo P. The value of provocative tests for the wrist and elbow: a literature review. *J Hand Ther* 2013;26(01):32–42, quiz 43
- 15 Meek MF, Dellon AL. Modification of Phalen's wrist-flexion test. *J Neurosci Methods* 2008;170(01):156–157
- 16 Goubau JF, Goubau L, Van Tongel A, Van Hoonacker P, Kerckhove D, Berghs B. The wrist hyperflexion and abduction of the thumb (WHAT) test: a more specific and sensitive test to diagnose de Quervain tenosynovitis than the Eichhoff's test. *J Hand Surg Eur Vol* 2014;39(03):286–292
- 17 Ergen E, Bülent U. *Clinical sports medicine Chapter 18 Proprioception and Coordination*. Saunders Elsevier; 2007:17 p
- 18 Ellenbecker TS, Davies GJ, Bleacher J. Proprioception and Neuromuscular Control. In: *Physical Rehabilitation of the Injured Athlete* [Internet]. Elsevier; 2012 [cited 2021 Aug 2]. p. 524–47. Available from: <https://linkinghub.elsevier.com/retrieve/pii/B9781437724110000241>
- 19 Kholinne E, Kim D, Kwak J-M, et al. Topography of sensory receptors within the human glenohumeral joint capsule. *J Shoulder Elbow Surg* 2021;30(04):779–786
- 20 Çabuk H, Kuşku Çabuk F. Mechanoreceptors of the ligaments and tendons around the knee. *Clin Anat* 2016;29(06):789–795
- 21 Abdo H, Calvo-Enrique L, Lopez JM, et al. Specialized cutaneous Schwann cells initiate pain sensation. *Science* 2019;365(6454):695–699
- 22 DeCamp CE, Johnston SA, Déjardin LM, Schaefer SL. Brinker, Piermattei, and Flo's Handbook of Small Animal Orthopedics and Fracture Repair. Fifth edition. St. Louis, Missouri: Elsevier; 2016:688 p.
- 23 Koch D, Fischer MS. *Diagnosing Canine Lameness*. Stuttgart: Thieme; 2020:249 p.
- 24 Clarke E, Aulakh KS, Hudson C, et al. Effect of sedation or general anesthesia on elbow goniometry and thoracic limb circumference measurements in dogs with naturally occurring elbow osteoarthritis. *Vet Surg* 2020;49(07):1428–1436
- 25 Formenton MR, de Lima LG, Vassalo FG, Joaquim JGF, Rosseto LP, Fantoni DT. Goniometric assessment in French bulldogs. *Front Vet Sci* 2019;6:424
- 26 Chong TE, Davies HMS. Investigating canine elbow joint stabilisation through mechanical constraints of the deep fascia and other soft tissues. *J Anat* 2018;232(03):407–421
- 27 Armentrout AR, Beard WL, White BJ, Lillich JD. A comparative study of proximal hindlimb flexion in horses: 5 versus 60 seconds. *Equine Vet J* 2012;44(04):420–424
- 28 Moreira JPL, Tichy A, Bockstahler B. Comparison of the vertical force distribution in the paws of dogs with coxarthrosis and sound dogs walking over a pressure plate. *Animals (Basel)* 2020;10(06):986
- 29 Schnabl-Feichter E, Tichy A, Bockstahler B. Evaluation of a pressure plate for detection of hind limb lameness in cats. *PLOS ONE*. 2020 Apr 22;15(4)
- 30 Starke SD, Willems E, Head M, May SA, Pfau T. Proximal hindlimb flexion in the horse: effect on movement symmetry and implications for defining soundness. *Equine Vet J* 2012;44(06):657–663
- 31 Marshall JF, Lund DG, Voute LC. Use of a wireless, inertial sensor-based system to objectively evaluate flexion tests in the horse: Sensor-based system to objectively evaluate flexion tests in horses. *Equine Vet J* 2012;44:8–11
- 32 Aulakh KS, Dongaonkar KR, Barnes K, et al. Influence of orthopedic examination on lameness scores and interobserver and intraobserver agreement in dogs with naturally occurring elbow osteoarthritis. *Vet Surg* 2020;49(03):455–462