



Neoplastic disease

Osteopontin and Ki-67 expression in World Health Organization graded canine meningioma

Janina Janssen ^{a,*}, Anna Oevermann ^b, Ingrid Walter ^c, Alexander Tichy ^d, Stefan Kummer ^e, Gabriele Gradner ^a

^a Department of Small Animal Surgery, Ophthalmology, Dentistry and Physiotherapy, University of Veterinary Medicine Vienna, 1210 Vienna, Austria

^b Division of Neurological Sciences, DCR-VPH, Vetsuisse Faculty, University of Bern, 3012 Bern, Switzerland

^c Department of Pathobiology, Institute of Morphology, Vetmeduni Vienna, 1210 Vienna, Austria

^d Platform Bioinformatics and Biostatistics, University of Veterinary Medicine Vienna, 1210 Vienna, Austria

^e VetCORE Facility, University of Veterinary Medicine Vienna, 1210 Vienna, Austria



ARTICLE INFO

Article history:

Received 20 July 2022

Received in revised form

20 October 2022

Accepted 22 December 2022

Keywords:

Allred score

Ki-67

MIB-1

osteopontin

ABSTRACT

Osteopontin (OPN) is a matrix protein involved in tumour initiation and progression. In human meningioma, OPN has been correlated with World Health Organization (WHO) grade, brain invasion and recurrence. The aim of this study was to investigate OPN as a possible malignancy marker in canine meningioma by correlating its expression to WHO grade and proliferative activity as measured by the Ki-67 labelling index (LI). Thirty-five formalin-fixed, paraffin-embedded canine meningioma samples were classified according to the current human WHO classification. Evaluation of OPN expression was performed by immunohistochemical (IHC) labelling and calculation of the OPN intensity score (IS), OPN IHC score and Allred score. The scores were compared with WHO grades, Ki-67 LI, location and invasiveness. Nineteen meningiomas were graded as WHO grade I (54.3%), nine as grade II (25.7%) and seven as grade III (20.0%). Twenty-six tumours were located intracranially, four were retrobulbar and five were spinal meningiomas. In all specimens OPN expression was detected in moderate to high degrees. Neither the OPN scores nor the Ki-67 LIs were correlated with WHO grades. However, the OPN IS and OPN IHC score were significantly higher in WHO grade I samples compared with grade II samples ($P < 0.05$). The OPN IS and OPN IHC score were significantly lower in meningioma samples that invaded surrounding tissues ($P = 0.01$ and 0.019 , respectively). The results indicate a generally high expression of OPN in canine meningioma independent of WHO grade. Further research into the role of OPN as a possible therapeutic target or predictor of recurrence is warranted.

© 2022 The Author(s). Published by Elsevier Ltd. This is an open access article under the CC BY license (<http://creativecommons.org/licenses/by/4.0/>).

1. Introduction

Canine meningiomas are extra-axial tumours that originate from arachnoid cap cells of the dura within the cranial cavity and vertebral canal. The meninges develop by contributions of the mesoderm and neural crest, which may explain the diversity of histopathological appearance of meningiomas. Due to their dual provenance, arachnoid cells have the ability to undergo epithelial and mesenchymal differentiation [1,2].

The estimated incidence of central nervous system tumours in dogs is approximately 26 per 100,000 [3] with meningioma being

the most common primary intracranial neoplasia, accounting for 40.0–50.9% of canine intracranial tumours [4–6].

The latest World Health Organization (WHO) histological classification system of canine meningiomas was published in 1999 and categorizes them into two main groups: benign and anaplastic tumours [7]. This classification system has not been updated since then. More recent studies rely on the human WHO classification system for categorization of canine meningiomas [8–10]. Using the human classification, approximately 47–63% of canine intracranial meningiomas are benign (grade I), 23–45% are atypical (grade II) and 1–9% are malignant (grade III) [11–14]. The high incidence of higher-grade meningioma in dogs, compared with human meningioma, makes this species especially interesting for research into its malignant behaviour and recurrence [15,16].

* Corresponding author.

E-mail address: Janina.Janssen@vetmeduni.ac.at (J. Janssen).

It is unclear if classifying canine meningioma according to the human classification is comparable when predicting clinical outcomes. Therefore, additional parameters to assess malignancy are warranted. Immunohistochemical (IHC) labelling is a valuable tool for histopathological decision making. Ki-67 is an established proliferation marker for various types of cancer and is commonly used to estimate the malignancy of human meningiomas. Expression of Ki-67, a nuclear non-histone protein and proliferation marker, correlates with WHO grade, brain invasion, recurrence and poor outcome of human meningioma [17–19]. Data on Ki-67 in canine meningioma are few and contradictory with some authors having identified a correlation with grade, while others not finding any association of Ki-67 expression and survival [20–25].

More recently, research has been directed to osteopontin (OPN), an integrin-binding matrix protein, which is involved in many processes. Apart from regulating physiological bone mineralization, it is a proinflammatory cytokine and participates in neoplastic processes. In cancer, it acts as a signalling agent and is involved in apoptosis, proliferation, migration, adhesion, invasion, metastasis and angiogenesis and, therefore, tumour progression [26,27]. In meningioma, OPN has been related to the formation of psammoma bodies, a typical feature of a common meningioma subtype [28]. OPN is also referred to as secreted phosphoprotein 1, as it can be detected in blood plasma and cerebrospinal fluid and may serve as a marker for early cancer detection and monitoring [29]. Additionally, its role as a proinflammatory cytokine renders it a valuable biomarker in inflammatory diseases such as multiple sclerosis or for use as a monitoring marker in Duchenne muscular dystrophy [30–32].

Studies of human meningiomas found a high correlation between OPN score and Ki-67 labelling index (LI), as well as with WHO grade and recurrence [33,34]. Additionally, higher OPN expression was reported in meningiomas invading the brain and bone [18,35]. Aside from its potential as a malignancy marker, research is directed towards OPN as a therapeutic target. Strategies include RNA silencing and blocking OPN activity by use of small-molecule inhibitors or specific antibodies [36].

To the authors' knowledge, there are no published studies on the role of OPN in canine meningioma. As the dog is a suitable model for various types of neoplasia common in humans, there are data on other neoplasms. Recent studies on canine osteosarcoma, canine mammary tumours and thyroid neoplasia investigated OPN as a possible malignancy marker and future therapeutic target [37–39].

The aim of this study was to investigate OPN expression as a possible malignancy marker in canine meningioma, with a special focus on correlation with WHO grading and proliferation, as measured by the Ki-67 LI. It was hypothesized that OPN measurements would positively correlate with WHO grades, Ki-67 LI and invasive growth.

2. Material and methods

The electronic database of the Institute of Pathology at the University of Veterinary Medicine Vienna, Austria, was searched for canine meningioma cases recorded from 2001 to 2018. Included specimens were harvested via surgery, biopsy or post-mortem examination. Samples of insufficient quality or very small size were excluded. Clinical data were retrieved from cases that had been treated at the Clinic for Small Animals. Data collected included age at presentation, sex, breed and bodyweight. Anatomical location of the tumour was recorded as intracranial, spinal or retrobulbar.

Formalin-fixed, paraffin-embedded sections (FFPE), cut at 4 µm and layered on glass slides, were used for haematoxylin and eosin

(HE) staining and IHC labelling. The HE-stained meningioma samples were reviewed by a board certified pathologist and classified according to the WHO classification for human meningioma [9]. Subtypes were set according to the dominant cell type and brain invasion was recorded if discernible.

2.1. Immunohistochemical labelling

IHC labelling for Ki-67 was performed with a mouse monoclonal anti-Ki-67 antibody (clone MIB-1; Dako, www.agilent.com). OPN immunolabelling was performed with a rabbit polyclonal anti-OPN antibody (PA5-16821; Invitrogen/Thermo Fisher Scientific, www.thermofisher.com) with proven immunoreactivity for canine OPN [40]. Ki-67 and OPN IHC runs were performed the same day to guarantee similar immunolabelling conditions.

Sections (2.5 µm) were cut from each paraffin block and placed on glass slides coated with 3-aminopropyltriethoxysilane (APTES; Carl Roth GmbH + Co. KG, www.carlroth.com). FFPE sections of canine tonsil tissue served as positive control for Ki-67. FFPE sections of osteosarcoma were used as positive control for OPN. Negative controls consisted of omission of primary antibody or substitution of primary antibody by isotype-matched antibody (rabbit IgG 3,900; Cell Signalling Technology, www.cellsignal.co.uk) (**Supplementary Fig. 1**). Western blotting was carried out to verify the specificity of the applied anti-OPN antibody for canine tissue. For this purpose, canine kidney tissue was lysed, separated on a 10% SDS PAGE gel and blotted on PVDF membrane (**Supplementary Fig. 2**).

Endogenous peroxidase activity was blocked with 0.6% hydrogen peroxide in 80% methanol. The sections immunolabelled for Ki-67 underwent an epitope retrieval step in 0.01M citrate buffer at pH 6 in a steamer for 30 min. Sections were then incubated with primary anti-Ki-67 (diluted 1:1000 in phosphate buffer) or anti-OPN (diluted 1:300 in phosphate buffer) antibodies. As secondary antibody the respective BrightVision Poly-HRP Anti-Mouse or Anti-Rabbit antibody (Immunologic, www.immunologic.nl) was used. Diaminobenzidine (DAB Quanto; Thermo Fisher Scientific) was used as chromogen to visualize the signal. Slides were counterstained with haematoxylin and mounted with dibutylphthalate polystyrene xylene (DPX; Sigma–Aldrich, www.sigmaaldrich.com).

2.2. Image analysis

For digitization, the Panoramic Scan II slide scanner was used (3DHISTECH Ltd, www.3dhistotech.com), equipped with a ×20 objective. Image analysis was performed with self-made scripts, as published (Ki67 [41] and osteopontin [42]), using FIJI (<https://imagej.net/software/fiji>) [43] and machine learning algorithms using the ilastik interactive learning and segmentation toolkit (<https://www.ilastik.org>) [44]. Tumour tissue on the digitized slides was outlined by a trained veterinarian (JJ), using a lasso cut-out tool. This ensured that only areas of neoplastic tissue underwent image analysis.

2.2.1. Ki-67

The scanned slides were digitally analysed for Ki-67 labelling with FIJI. After separating the Ki-67-positive signal and Ki-67-negative (counterstained) nuclei by colour deconvolution with preset values for haematoxylin and DAB, the background was automatically reduced with a rolling ball radius of 50 and contrast was enhanced to obtain a normalized signal with similar maximum intensities. Both positive and negative nuclei were segmented and analysed, excluding very small (<13 µm²) and very large (>130 µm²) particles to remove staining-sprinkles and other artefacts. These filtered particles were counted and set into relation,

and the Ki-67 LI was expressed as a percentage. After processing the images with FIJI, the resulting labels were assessed visually as a check on accuracy.

2.2.2. Osteopontin

For OPN analysis, a combination of machine learning algorithms with the ilastik program and image analysis with the FIJI program was used. First, ilastik was trained to differentiate between background around the tissue, background within the tissue (eg, vessels and other spaces), OPN-positive areas and OPN-negative areas. The data were then analysed using the FIJI program and the percentage area of OPN labelling (percentage of immunopositive to immunonegative areas) calculated with exclusion of background area. To assess cytoplasmic immunoreactivity, the intensity and the extent of OPN labelling intensity were evaluated [33]. Two methods of evaluation combining these values were used for definition of OPN expression: the OPN IHC score and the Allred score.

2.2.2.1. OPN IHC score. OPN labelling intensity was scored visually by one of the authors (JJ) as OPN intensity score (OPN IS) on a scale of 0–3. Completely negative cases were scored 0. Scores 1, 2 and 3 were attributed to weak, moderate and strong labelling, respectively (Supplementary Fig. 3). Additionally, the extent of labelling was calculated, with the aid of ilastik, as the percentage of the immunolabelled area for each case. For calculation of the OPN IHC score, the OPN IS was multiplied by the percentage of immunolabelled areas. This score had a possible range of 0–300.

2.2.2.2. OPN Allred score. The Allred evaluation system was used as a second method for evaluation of immunoreactivity, as used in previous studies for assessment of OPN immunolabelling [33,45,46]. The slides were grouped according to their OPN positivity percentage, as determined by ilastik, into an OPN percentage score (no staining = 0, staining of ≤1% of cells = 1, 1–10% = 2, 11–33% = 3, 34–67% = 4, 68–100% = 5). The Allred score was then calculated as the sum of the OPN percentage score and the OPN IS. Possible scores were 0 and 2–8.

Statistical analysis was performed with SPSS software (version 27 for windows; IBM, www.ibm.com). Quantitative data were expressed as means, standard deviation and ranges (lowest–highest). Correlation was tested via Pearson test. Statistical comparison among subgroups was performed by use of ANOVA. Statistical significance was set as P < 0.05.

3. Results

Of the 68 archival meningiomas, 35 were entered into the study after the exclusion process. The cases and corresponding data are shown in Tables 1 and 2. Twenty-six tumours were located intracranially, four were retrobulbar and five were spinal meningiomas.

Nineteen meningiomas were graded as WHO grade I (54.3%), nine as grade II (25.7%) and seven as grade III (20.0%). Subtypes of grade I tumours were microcystic (n = 8), transitional (n = 5), psammomatous (n = 3) and meningothelial (n = 3). Grade II tumours were either atypical (n = 6) or chordoid (n = 3). Grade III tumours were rhabdoid (n = 6) or papillary (n = 1). All four retrobulbar meningiomas were grade III rhabdoid tumours. All the spinal meningiomas were histopathological grades I and II.

Seventy-eight percent (7/9) of WHO grade II meningiomas had evidence of brain invasion, while one of seven grade III tumours had invaded the brain or surrounding tissues. However, for two of the seven grade III samples, invasiveness could not be determined due to inadequate sample size.

Table 1 History and clinical data in investigated meningioma cases

Case no.	Year	Breed	Age (years)	Weight (kg)	Sex
Case 01	2001	German Shepherd Dog	8	37	m
Case 02	2002	Boxer	9	35	m
Case 03	2002	German Shepherd Dog	10	40	m
Case 04	2002	German Shepherd Dog	10	41	fn
Case 05	2002	Bearded Collie	10	26	m
Case 06	2002	German Shepherd Dog	7	46	m
Case 07	2003	Spaniel	9	17	f
Case 08	2003	Mixed breed	6	26	fn
Case 09	2003	Boston Terrier	7	10	mk
Case 10	2003	Rottweiler	12	28	fn
Case 11	2004	German Wirehaired Pointer	13	23	f
Case 12	2005	Belgian Shepherd	13	34	m
Case 13	2005	Mixed breed	11	34.2	fn
Case 14	2005	Golden Retriever	11	45.8	m
Case 15	2005	Maltese	n.a.	4.8	f
Case 16	2006	Mixed breed	9	40	mk
Case 17	2007	German Shepherd Dog	9	46	m
Case 18	2007	Mixed breed	13	20	fn
Case 19	2007	Mixed breed	9	10.8	m
Case 20	2007	Mixed breed	7	n.a.	f
Case 21	2009	Yorkshire Terrier	11	2.6	mk
Case 22	2009	Bavarian Mountain Dog	12	26.6	m
Case 23	2010	Mixed breed	4	11.8	mk
Case 24	2010	Golden Retriever	n.a.	n.a.	n.a.
Case 25	2011	Tervueren	9	22	m
Case 26	2012	Mixed breed	5	9.1	f
Case 27	2013	Mixed breed	16	4.9	fn
Case 28	2015	Havanese	13	4.9	fn
Case 29	2015	Mixed breed	10	28	fn
Case 30	2015	Golden Retriever	9	30.5	fn
Case 31	2015	German Shepherd Dog	8	37.4	m
Case 32	2016	Maltese	12	3.4	fn
Case 33	2016	Golden Retriever	13	30	m
Case 34	2017	Shetland Sheepdog	11	6.4	fn
Case 35	2017	Mixed breed	7	31	mk

m, male; mc, male castrated; f, female; fn, female neutered; n.a., not available.

The female:male ratio of meningioma bearing patients was 48:52%. The average age at presentation was 10 years (range 4–16) and the average bodyweight was 25 kg (range 2.6–46 kg). While dogs with intracranial and spinal meningiomas presented with a similar mean age of 10 years, dogs with retrobulbar meningiomas presented at an average age of 7 years. Breeds represented in this study were German Shepherd Dog (n = 6), Golden Retriever (n = 4), Maltese (n = 2) and one case each of Bavarian Mountain Hound, Bearded Collie, Belgian Shepherd Dog, Boston Terrier, Boxer, German Wirehaired Pointer, Havanese, Rottweiler, Shetland Sheepdog, Spaniel, Tervueren and Yorkshire Terrier. Eleven cases originated from non-pedigree dogs.

Results of statistical analysis of OPN scores, immunolabelling percentages and Ki-67 indices are summarized in Table 3. Representative examples of OPN and Ki-67 expression in meningiomas of different WHO grades are presented in Fig. 1.

The mean OPN labelling percentage, as determined by the ilastik program, was 66.6 ± 26.5 (range 7.4–92.6). The application detected labelling in all meningioma samples, while visually, two samples were graded as OPN IS negative due to very weak immunolabelling (both WHO grade II). The mean visual OPN IS was 1.9 ± 0.9 (range 0–3). The mean OPN IHC score was 142 ± 93 (range 0–278) and the mean OPN Allred score was 4 ± 1 (range 2–5). The mean Ki-67 LI was 4.5 ± 2.9 (range 0.8–13.1).

Ki-67 expression ranged from 0 to 13.1 (mean 4.5) and varied markedly in relation to tumour location without reaching statistical significance (Fig. 2). While intracranial meningioma expressed a lower mean Ki-67 LI of 3.93 (±3.02), retrobulbar and spinal

Table 2
Immunohistochemical findings in investigated meningioma cases

Case no.	WHO grade	Subtype	Location	Tissue invasion	Ki67 LI	Osteopontin positive	OPN IS	OPN IHC score	OPN percentage score	Allred score
Case 01	1	Microcystic	Intracranial	No	5.1	89.8%	2	180	5	7
Case 02	1	Transitional	Intracranial	No	2.2	65.0%	2	130	4	6
Case 03	1	Psammomatous	Intracranial	No	6.5	73.8%	2	148	5	7
Case 04	1	Transitional	Intracranial	No	1.9	90.3%	3	271	5	8
Case 05	3	Papillary	Intracranial	No	1.6	19.0%	1	19	3	4
Case 06	3	Rhabdoid	Intracranial	No	5.7	80.8%	2	162	5	7
Case 07	1	Transitional	Intracranial	No	5.5	73.7%	2	147	5	7
Case 08	1	Psammomatous	Intracranial	No	2.8	85.9%	2	172	5	2
Case 09	2	Atypical	Intracranial	Yes	0.8	7.4%	1	7	2	3
Case 10	3	Rhabdoid	Intracranial	Yes	1.2	76.7%	3	230	5	8
Case 11	1	Microcystic	Intracranial	No	1.7	42.8%	1	43	4	5
Case 12	1	Microcystic	Intracranial	No	4.8	92.1%	3	276	5	8
Case 13	1	Transitional	Intracranial	No	1.7	91.4%	3	274	5	8
Case 14	1	Microcystic	Intracranial	No	3	92.6%	3	278	5	8
Case 15	2	Chordoid	Spinal	No	3.1	66.6%	1	67	4	5
Case 16	2	Atypical	Intracranial	Yes	3	33.9%	1	34	5	6
Case 17	1	Transitional	Intracranial	No	4.8	85.7%	3	257	5	8
Case 18	2	Atypical	Intracranial	Yes	12.5	57.1%	1	57	4	5
Case 19	3	Rhabdoid	Retrolubar	N.a.	3.6	86.2%	3	259	5	8
Case 20	3	Rhabdoid	Retrolubar	N.a.	9.1	87.4%	3	262	5	8
Case 21	1	Psammomatous	Intracranial	No	4.4	91.2%	2	182	5	7
Case 22	1	Microcystic	Intracranial	No	2.3	17.6%	1	18	3	4
Case 23	2	Chordoid	Spinal	No	4.2	85.7%	2	171	5	7
Case 24	2	Chordoid	Intracranial	Yes	3.5	17.1%	0	0	3	3
Case 25	2	Atypical	Intracranial	Yes	3.1	65.6%	1	66	4	5
Case 26	3	Rhabdoid	Retrolubar	No	6.5	82.7%	2	165	5	7
Case 27	1	Meningothelial	Intracranial	No	13.1	14.4%	1	14	3	4
Case 28	1	Meningothelial	Spinal	No	8.5	88.6%	3	266	5	8
Case 29	1	Microcystic	Intracranial	No	4	54.4%	1	54	4	5
Case 30	1	Meningothelial	Spinal	No	5.9	80.4%	2	161	5	7
Case 31	1	Microcystic	Intracranial	No	1.6	76.8%	2	154	5	7
Case 32	1	Microcystic	Spinal	No	7.7	83.3%	2	167	5	7
Case 33	2	Atypical	Intracranial	Yes	2.8	82.8%	2	166	5	7
Case 34	2	Atypical	Intracranial	Yes	2.6	35.1%	0	0	4	4
Case 35	3	Rhabdoid	Retrolubar	No	5.7	55.3%	2	111	5	7

WHO, World Health Organization; LI, labelling index; OPN, osteopontin; IS, intensity score; IHC, immunohistochemical; N.a., not available.

meningioma expressed a higher mean of 6.23 (±2.27) and 5.88 (±2.28), respectively.

OPN scores and Ki-67 LIs did not consistently increase with WHO grade. However, differences among groups were observed. Fig. 3 shows the distribution of the OPN IHC score according to meningioma grade. The OPN IHC score and OPN IS were significantly lower in WHO grade II meningiomas than in grade I meningiomas (P = 0.021 and 0.041, respectively). All OPN measurements had a similar tendency of equally high levels in grades I and III meningiomas and lower levels in grade II. For OPN labelling percentage and OPN Allred score, these trends did not reach statistical significance.

Table 3
Osteopontin immunolabelling and Ki-67 labeling index in meningiomas in relation to WHO grade

	Grade I (n = 19)	Grade II (n = 9)	Grade III (n = 7)
OPN labelling (%)			
Mean ± SD	73.2 ± 24.2	52.0 ± 29.4	65.4 ± 26.1
OPN IS			
Mean ± SD	2.1 ± 0.7	1.1 ± 0.6	2.0 ± 1.1
OPN IHC score			
Mean ± SD	168 ± 88.5	71 ± 65.2	151 ± 101.7
OPN Allred score			
Mean ± SD	6.5 ± 1.7	5.1 ± 1.6	6.6 ± 1.7
Ki-67 LI (%)			
Mean ± SD	4.6 ± 2.9	4.1 ± 3.5	4.5 ± 2.7

WHO, World Health Organization; OPN, osteopontin; SD, standard deviation; IS, intensity score; IHC, immunohistochemical; LI, labelling index.

A similar trend could also be observed in the levels of Ki-67 LI in relation to WHO grades (Fig. 4). While grade I meningiomas expressed a mean Ki-67 LI of 4.6, grade II tumours expressed a mean of 4.1 and grade III tumours a mean Ki-67 LI of 4.5. However, these values were not significantly different (P = 0.931). Additionally, Ki-67 LIs and OPN scores were not significantly correlated, although they had similar tendencies in relation to WHO grading.

As depicted in Fig. 5, OPN IS and OPN IHC scores were negatively correlated with brain invasion (P = 0.01 and P = 0.019, respectively). Samples without brain invasion had significantly higher mean OPN ISs and OPN IHC scores of 2 and 155.5, respectively, compared with mean scores of 1.1 and 70, respectively, for samples that had evidence of invasion. Examples of OPN immunolabelling in samples of invasive and non-invasive neoplasms are depicted in Supplementary Fig. 4.

4. Discussion

OPN is a cytokine-like protein that exerts multiple functions in tumour initiation and progression. To our knowledge, OPN expression has not been studied in canine meningioma. In this study we aimed to investigate the expression of OPN in relation to meningioma grading and Ki-67 labelling in order to assess the value of OPN as a possible malignancy marker and therapeutic target.

The ilastik program detected OPN labelling in all meningioma samples, most of which had a high percentage area of labelled tissue (mean 66.6 ± 26.5). Irrespective of tumour grade, some samples reached values of 93% labelling. OPN expression in human

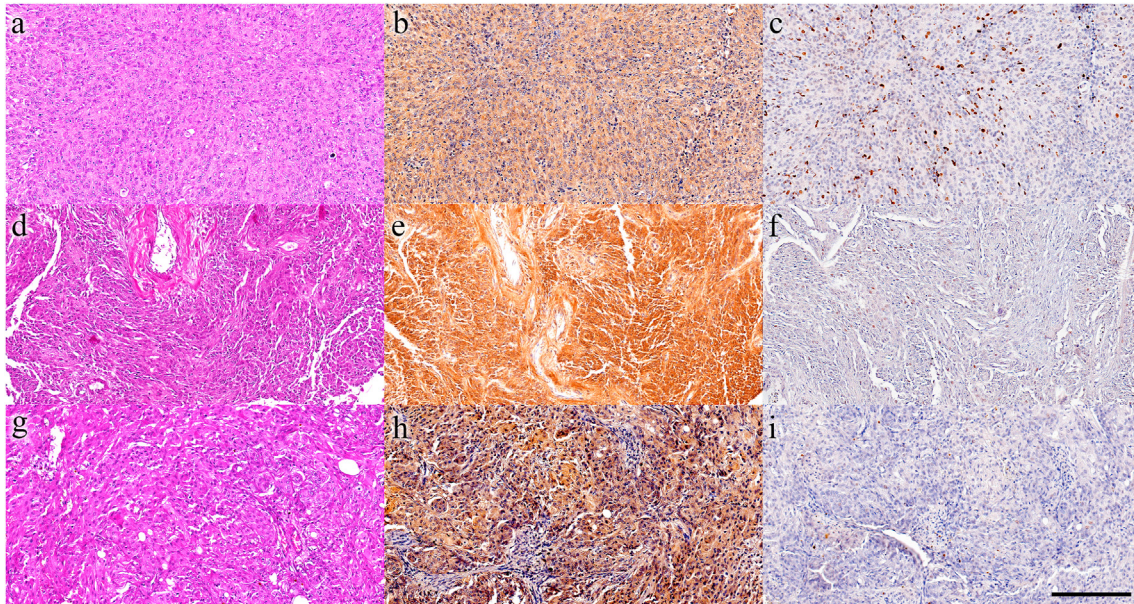


Fig. 1. Meningiomas, dogs. Left column: HE staining; middle column: osteopontin (OPN) IHC; right column: Ki-67 IHC. (a–c) WHO grade I meningothelial, spinal. Intense homogeneous OPN expression and high Ki-67 immunopositivity (d–f) WHO grade II atypical, intracranial. Very intense OPN immunolabelling and low Ki-67 expression (g–i) WHO grade III rhabdoid, retrobulbar. Intense irregular OPN labelling, low Ki-67 expression. Bar, 200 μ m.

meningioma, as reported by Arikök *et al* [33]; was comparably high with a mean of 35.6% in WHO grade I, 80.0% in grade II and 64.6% in grade III tumours.

The generally high proportion of OPN expression, as detected in this study, renders this protein an attractive target for possible therapeutic approaches. Currently, human research is directed at blocking OPN with its specific aptamer, a single stranded RNA (ssRNA) that blocks surface binding of OPN to its receptor, CD44 and integrin [47]. Other therapeutic approaches include OPN suppression via specific antibodies, small-molecule inhibitors or small RNAs [48].

Ki-67 expression was detected in all samples in this study. The increase in proliferation, as indicated by an elevated Ki-67 LI, is a key event in the progression of tumours and can occur early during tumour development. This may explain why some WHO grade I tumours had a relatively high Ki-67 LI. The range of Ki-67 LIs, from

0.8 to 13.1, is consistent with other studies of canine meningioma [20,25]. Ki-67 labelling did not correlate significantly with WHO grading and there was a relatively small variation in mean Ki-67 LI when comparing WHO grades, as grades I, II and III had means of 4.6, 4.1 and 4.5, respectively. Matiasek *et al* [25] found that the majority of their canine meningioma samples expressed a Ki-67 LI of <4, and there was no correlation between Ki-67 LI and survival. In their samples, 9% were Ki-67 negative. Mandara *et al* [23] found no Ki-67 labelling in 10/51 cases, even though four were malignant meningiomas. This overall low correlation of Ki-67 expression in canine meningioma with negative prognostic factors may be an indicator that proliferation is not as important for canine meningioma malignancy and recurrence as it is in human meningioma [18,19]. However, as all the studies investigating Ki-67 expression in canine meningioma have been conducted on relatively small case numbers, larger and multicentre studies are warranted.

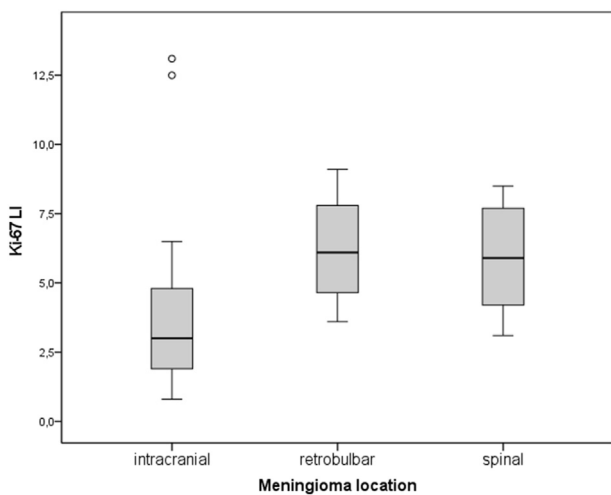


Fig. 2. Ki-67 LI in relation to meningioma location. Overall lower Ki-67 LI in intracranial tumours compared with meningiomas originating from a retrobulbar or spinal location, but not statistically significant.

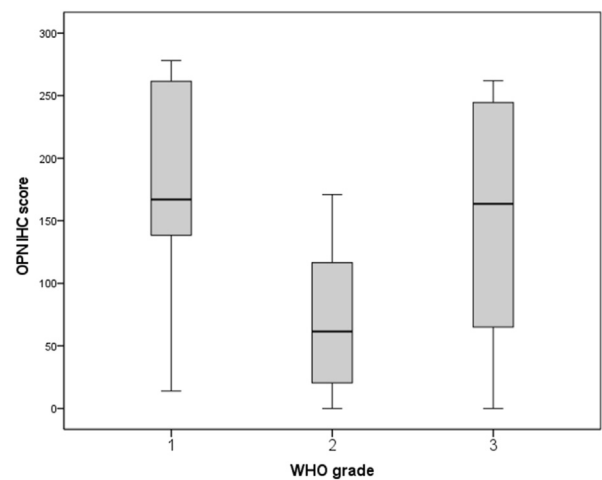


Fig. 3. Distribution of OPN immunolabelling scores according to meningioma WHO grade. OPN IHC score significantly lower ($P = 0.021$) in WHO grade II meningiomas than in grade I meningiomas.

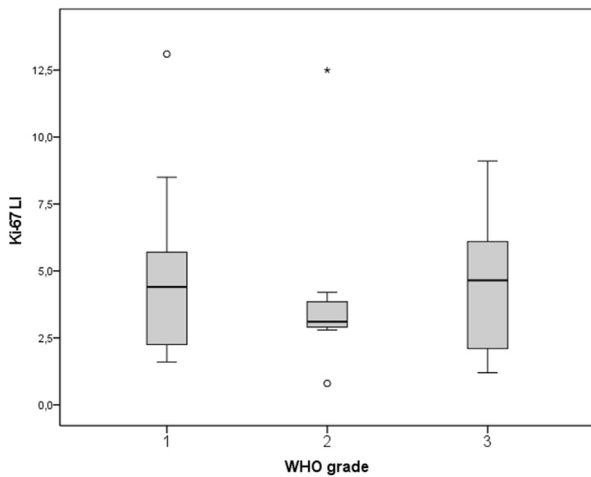


Fig. 4. Distribution of Ki-67 LIs according to WHO grade. Ki-67 LI is lower in WHO grade II meningiomas compared with WHO grades I and III meningiomas, but not statistically significant.

Neither the Ki-67 indices nor the OPN scores significantly increased with WHO grade. Consequently, we had to reject our hypothesis. However, among tumour grades, marked but not significant differences in OPN expression were observed. While WHO grade I and grade III tumours had comparably high mean OPN IHC scores of 168 and 151, respectively, grade II tumours had lower mean OPN IHC scores of 71. Between WHO grades I and II tumours, this difference was significant for OPN IHC score ($P = 0.041$) and OPN IS ($P = 0.021$). Positive correlations between OPN immunostaining and WHO grades have been found in human meningioma [26,33,34,49]. Additionally, two studies found significantly higher OPN IHC scores in recurring meningioma compared with non-recurring meningioma [33,34]. A possible explanation for the differing results between our study and the human studies is that OPN may in fact be differently expressed in canine meningioma. Another possibility is that the WHO grades in this study, as determined with the aid of the 2016 human WHO classification, cannot be entirely applied to canine meningioma.

The human WHO classification system for central nervous system tumours released in 2016 made only one, but major, change to the former guidelines. This was to automatically grade invasive

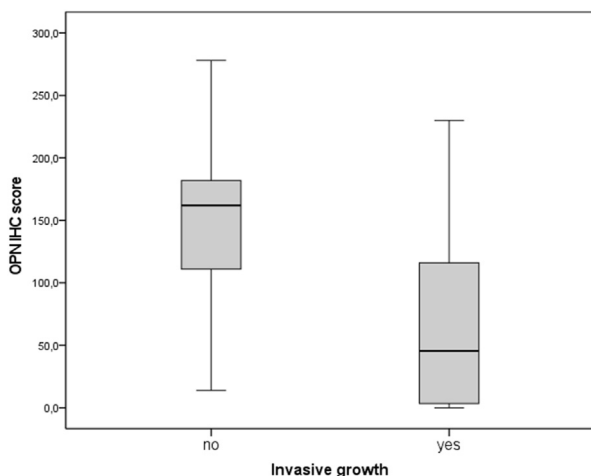


Fig. 5. Distribution of OPN immunolabelling and invasive meningioma growth. Negative correlation between OPN IHC score and tissue invasion of tumour ($P = 0.019$).

meningiomas as grade II tumours, even though they might otherwise exhibit benign features. In this study, 19 tumours were grade I (54.2%), nine were grade II (25.7%) and seven were grade III (20.0%). This allocation of cases among WHO grades concurs with previous studies on canine meningioma [12–14]. Aggressive behaviour and recurrence of meningiomas are more commonly observed in dogs than in humans [12,14], which is reflected in the distribution of human meningiomas, in which 80% are grade I tumours, 10–15% are grade II and 2–5% are grade III [50].

Although most human meningiomas are considered benign, the unpredictable behaviours of malignant variants result in ongoing efforts to improve the WHO grading scheme. The demand to include other than solely histopathological criteria in the decision-making process is increasing. Many human institutions take IHC labelling (eg, for Ki-67) into consideration when predicting future meningioma behaviour and likelihood of recurrence [15]. Recently, a new edition of the WHO classification for tumours of the central nervous system has been released. Regarding meningioma, no changes at the histopathological level have been made, but morphological subtypes are no longer strictly linked to a specific WHO class. Hence, the advice is to give more importance to criteria of aggressiveness than to cell morphology. A major change in the new WHO classification edition is the addition of acknowledged biomarkers and methylome profiling for decision making in difficult cases [10].

In our data, the OPN IS and OPN IHC score were negatively correlated with brain invasion ($P = 0.01$ and $P = 0.019$, respectively). This contrasts with studies on humans, which found a positive correlation between OPN expression and tumour invasiveness [35,49]. Seven out of nine WHO grade II meningiomas had histopathological evidence of tissue invasion, while only one in seven WHO grade III tumours was invasive. The negative correlation of invasive growth with OPN expression might be an explanation as to why OPN IHC scores were significantly lower in WHO grade II meningiomas. Based on the results in this study, OPN may not be critically involved in facilitating tissue invasion in canine meningioma, or tumours containing higher levels of OPN may even be less likely to become invasive. However, the generally high levels of OPN expression indicate that it has an important role in the development of this tumour.

There are no reports on OPN expression in canine meningioma and only a few on other canine neoplasms. Guim *et al* [37] reported OPN immunolabelling in canine osteosarcoma and found mild to marked intensities but no correlation with survival. However, they observed a tendency to increased OPN expression in higher tumour grades. Klopffleisch *et al* [38] investigated OPN mRNA expression in canine mammary tumours. They reported increased expression in carcinomas compared with adenomas, but statistical significance was not reached. These results indicate a relationship between OPN expression and malignancy, but a concrete influence on canine tumours has yet to be determined.

The relatively high proportion of WHO grade III meningiomas in the present series can partly be attributed to the high proportion of retrolubar meningiomas in our study population. All four specimens originating from the orbital region in this study were classified as rhabdoid meningiomas. This is an uncommon tumour variant at the intracranial location, histologically defined by plump rhabdoid cells with open chromatin and other features of malignancy [8]. Canine meningiomas with rhabdoid features have rarely been described [51,52]. Interestingly, the most common histopathological types of retrolubar meningioma identified in other studies were meningothelial, followed by fibrous and transitional. Larger case series frequently included areas of myxomatous, cartilaginous or osseous metaplasia [53–55]. Based on these findings, Montoliou *et al* [55] regarded canine orbital meningioma as a

totally separate meningioma entity. Mauldin *et al* [53] mentioned a recurrence in six of 22 canine retrobulbar meningiomas, which may indicate a more aggressive behaviour at this location. Studies of retrobulbar meningiomas in dogs utilized the domestic animal classification scheme, for which the rhabdoid type is not defined. It is therefore unknown if certain samples in these studies would have been categorized as rhabdoid tumours had they been classified according to the human classification scheme.

All spinal meningioma in our investigation were histopathological grade I or II. This is in accordance with previous studies, although reports on spinal meningioma are scarce [56,57]. Petersen *et al* [57] did not have any grade III spinal meningiomas in their study population of 34 dogs and neither did José-López *et al* [58] when investigating eight cases. In the study by Lacassange *et al* [56], survival time for post-resection meningiomas ranged from 66 to 881 days (2.2–29.0 months) with a median survival time of 306 days (10.1 months). Post-surgery survival times for spinal meningiomas in the study by Petersen *et al* [57] ranged from 4 to 47 months, which is within the range of post-surgical survival times of 1.5–3 years for intracranial meningioma and does not indicate a more benign behaviour for spinal tumours in the context of the tendency of a lower tumour grade. However, it must be considered that the ability of nervous system tissue to compensate for tumour growth in the vertebral canal is considerably more limited than in the calvarium, and clinical deterioration must be expected at an earlier stage [13]. Mandara *et al* [24] found that spinal meningiomas had much higher Ki-67 expression compared with intracranial meningiomas, but investigated only two spinal specimens, one of which was malignant according to the canine WHO classification system. Nevertheless, this finding is supported by our data, as a higher Ki-67 LI is expressed in spinal and retrobulbar meningiomas compared with the intracranial type.

One limitation of this study is the retrospective collection of data, which does not allow for reasonable evaluation of clinical outcome. Secondly, the limited case numbers might be one reason why some results were not statistically significant. The study population, however, was similar to those used in previous canine meningioma studies. Mean age and bodyweight, male to female ratio and predominantly dolichocephalic breeds were similar to those of other studies [6,13].

As the samples were collected over 17 years, differences in sample preparation and storage may have influenced our results. Due to the retrospective nature of the study, the duration of formalin fixation before embedding in paraffin was not standardized. Therefore, we cannot verify if this aspect has influenced our IHC results. However, as no statistical correlation between sample age and immunolabelling percentage or intensity was found, there appears to be no relevant influence of sample age on IHC labelling affinity.

Another limiting factor of the study may be the availability of canine-specific anti-OPN antibodies. The antibodies used in this study have been used previously in canine studies and were robustly tested with appropriate controls to ensure binding specificity [40]. However, influences of sample processing or storage time on the immunolabelling cannot be excluded. The MIB-1 antibody used for Ki-67 immunolabelling has long been established for application to FFPE tissues [59,60]. Yet another limitation may be the use of a human grading scheme for canine meningioma, although this has commonly been applied in recent studies, as the canine grading scheme has not been updated since 1999 [7,11].

5. Conclusion

Firstly, although OPN and Ki-67 LI immunolabelling did not correlate with WHO grades in our study population, generally high

OPN expression was found, indicating that OPN may be a valuable therapeutic target in canine meningioma. Secondly, OPN may be used as a post-surgical predictor of recurrence, as a negative correlation of OPN labelling with tissue invasion was found in this population. However, prospective studies with larger case numbers are warranted to establish the role of OPN in canine meningioma.

Funding

Funding for this study was provided by the Department of Small Animal Surgery, Ophthalmology, Dentistry and Physiotherapy located at the University of Veterinary Medicine Vienna, Austria.

Acknowledgments

Special thanks are extended to the Department of Pathology at the Vetmeduni Vienna, particularly to Dr Simone Tangermann and Dr Sandra Högl.

Declaration of competing interests

The authors declared no conflicts of interest regarding the research, authorship or publication of this article.

Appendix A. Supplementary data

Supplementary data to this article can be found online at <https://doi.org/10.1016/j.jcpa.2022.12.011>.

References

- [1] Kepes JJ. Presidential address: the histopathology of meningiomas. A reflection of origins and expected behavior? *J Neuropathol Exp Neurol* 1986;45:95–107.
- [2] O'Rahilly R, Müller F. The meninges in human development. *J Neuropathol Exp Neurol* 1986;45:588–608.
- [3] Dobson JM, Samuel S, Milstein H, Rogers K, Wood JLN. Canine neoplasia in the UK: estimates of incidence rates from a population of insured dogs. *J Small Anim Pract* 2002;43:240–6.
- [4] Courtoy-Cahen C, Platt SR, Risio L de, Starkey MP. Preliminary analysis of genomic abnormalities in canine meningiomas. *Vet Comp Oncol* 2008;6:182–92.
- [5] Kishimoto TE, Uchida K, Chambers JK, Kok MK, Son NV, Shiga T, et al. A retrospective survey on canine intracranial tumors between 2007 and 2017. *J Vet Med Sci* 2019;82:77–83.
- [6] Snyder JM, Shofer FS, van Winkle TJ, Massicotte C. Canine intracranial primary neoplasia: 173 cases (1986–2003). *J Vet Intern Med* 2006;20:669–75.
- [7] Koestner A. Histological classification of tumors of the nervous system of domestic animals. Washington DC: Armed Forces Institute of Pathology; 1999.
- [8] Louis DN, Ohgaki H, Wiestler OD, Cavenee WK, Burger PC, Jouvet A, et al. The 2007 WHO classification of tumours of the central nervous system. *Acta Neuropathol* 2007;114:97–109.
- [9] Louis DN, Perry A, Reifenberger G, Deimling A von, Figarella-Branger D, Cavenee WK, et al. The 2016 World Health Organization classification of tumors of the central nervous system: a summary. *Acta Neuropathol* 2016;131:803–20.
- [10] Louis DN, Perry A, Wesseling P, Brat DJ, Cree IA, Figarella-Branger D, et al. The 2021 WHO classification of tumors of the central nervous system: a summary. *Neuro Oncol* 2021;23:1231–51.
- [11] Belluco S, Marano G, Baiker K, Beineke A, Oevermann A, Seehusen F, et al. Standardisation of canine meningioma grading: inter-observer agreement and recommendations for reproducible histopathologic criteria. *Vet Comp Oncol* 2022;20:509–20.
- [12] Mandara MT, Pavone S, Brunetti B, Mandrioli L. A comparative study of canine and feline meningioma classification based on WHO histological classification system in humans. *Proceedings 22nd Symposium ESVN-ECVN. Bologna; s.n. 2009. p. 41–2.*
- [13] Sturges BK, Dickinson PJ, Bollen AW, Koblik PD, Kass PH, Kortz GD, et al. Magnetic resonance imaging and histological classification of intracranial meningiomas in 112 dogs. *J Vet Intern Med* 2008;22:586–95.
- [14] Thomas R, Duke SE, Wang HJ, Breen TE, Higgins RJ, Linder KE, et al. 'Putting our heads together': insights into genomic conservation between human and canine intracranial tumors. *J Neuro-Oncol* 2009;94:333–49.

- [15] Bruna J, Brell M, Ferrer I, Gimenez-Bonafe P, Tortosa A. Ki-67 proliferative index predicts clinical outcome in patients with atypical or anaplastic meningioma. *Neuropathology* 2007;27:114–20.
- [16] Hicks J, Platt S, Kent M, Haley A. Canine brain tumours: a model for the human disease? *Vet Comp Oncol* 2017;15:252–72.
- [17] Abry E, Thomassen IØ, Salvesen ØO, Torp SH. The significance of Ki-67/MIB-1 labeling index in human meningiomas: a literature study. *Pathol Res Pract* 2010;206:810–5.
- [18] Li J, Liang R, Song C, Xiang Y, Liu Y. Prognostic value of Ki-67/MIB-1 expression in meningioma patients: a meta-analysis. *Crit Rev Eukaryot Gene Expr* 2019;29:141–50.
- [19] Liu N, Song S-Y, Jiang J-B, Wang T-J, Yan C-X. The prognostic role of Ki-67/MIB-1 in meningioma: a systematic review with meta-analysis. *Medicine* 2020;99:e18644.
- [20] Ide T, Uchida K, Suzuki K, Kagawa Y, Nakayama H. Expression of cell adhesion molecules and doublecortin in canine anaplastic meningiomas. *Vet Pathol* 2011;48:292–301.
- [21] Johnson GC, Coates JR, Wininger F. Diagnostic immunohistochemistry of canine and feline intracranial tumors in the age of brain biopsies. *Vet Pathol* 2014;51:146–60.
- [22] Long S, Argyle DJ, Nixon C, Nicholson I, Botteron C, Olby N, et al. Telomerase reverse transcriptase (TERT) expression and proliferation in canine brain tumours. *Neuropathol Appl Neurobiol* 2006;32:662–73.
- [23] Mandara MT, Pavone S, Mandrioli L, Bettini G, Falzone C, Baroni M. Matrix metalloproteinase-2 and matrix metalloproteinase-9 expression in canine and feline meningioma. *Vet Pathol* 2009b;46:836–45.
- [24] Mandara MT, Ricci G, Rinaldi L, Sarli G, Vitellozzi G. Immunohistochemical identification and image analysis quantification of oestrogen and progesterone receptors in canine and feline meningioma. *J Comp Pathol* 2002;127:214–8.
- [25] Matiasek LA, Platt SR, Adams V, Scase TJ, Keys D, Miller J, et al. Ki-67 and vascular endothelial growth factor expression in intracranial meningiomas in dogs. *J Vet Intern Med* 2009;23:146–51.
- [26] Lin C-K, Tsai W-C, Lin Y-C, Hueng D-Y. Osteopontin predicts the behaviour of atypical meningioma. *Histopathology* 2012;60:320–5.
- [27] Shevde LA, Samant RS. Role of osteopontin in the pathophysiology of cancer. *Matrix Biol* 2014;37:131–41.
- [28] Hirota S, Nakajima Y, Yoshimine T, Kohri K, Nomura S, Hayakawa T, et al. Expression of bone-related protein messenger RNA in human meningiomas: possible involvement of osteopontin in development of psammoma bodies. *J Neuropathol Exp Neurol* 1995;54:698–703.
- [29] Weber GF, Lett GS, Haubein NC. Categorical meta-analysis of osteopontin as a clinical cancer marker. *Oncol Rep* 2011;25:433–41.
- [30] Agah E, Zardoui A, Saghazadeh A, Ahmadi M, Tafakhori A, Rezaei N. Osteopontin (OPN) as a CSF and blood biomarker for multiple sclerosis: a systematic review and meta-analysis. *PLoS One* 2018;13:e0190252.
- [31] Kuraoka M, Aoki Y, Takeda S. Development of outcome measures according to dystrophic phenotypes in canine X-linked muscular dystrophy in Japan. *Exp Anim* 2021;70:419–30.
- [32] Kuraoka M, Kimura E, Nagata T, Okada T, Aoki Y, Tachimori H, et al. Serum osteopontin as a novel biomarker for muscle regeneration in Duchenne muscular dystrophy. *Am J Pathol* 2016;186:1302–12.
- [33] Arikök AT, Onder E, Seçkin H, Kaçar A, Fesli R, Oğuz AS, et al. Osteopontin expressions correlate with WHO grades and predict recurrence in meningiomas. *Brain Tumor Pathol* 2014;31:94–100.
- [34] Hashemi F, Babaheidarian P, Dabiran S. Are osteopontin and Ki67 expressions different in various histologic grades of meningioma? An Iranian experience. *Iran J Pathol* 2015;10:253–7.
- [35] Salehi F, Jalali S, Alkins R, Lee J-I, Lwu S, Burrell K, et al. Proteins involved in regulating bone invasion in skull base meningiomas. *Acta Neurochir* 2013;155:421–7.
- [36] Bandopadhyay M, Bulbule A, Butti R, Chakraborty G, Ghorpade P, Ghosh P, et al. Osteopontin as a therapeutic target for cancer. *Expert Opin Ther Targets* 2014;18:883–95.
- [37] Guim TN, Bianchi MV, Lorenzo C de, Gouvêa AS, Gerardi DG, Driemeir D, et al. Relationship between clinicopathological features and prognosis in appendicular osteosarcoma in dogs. *J Comp Pathol* 2020;180:91–9.
- [38] Klopffleisch R, Klose P, Gruber AD. The combined expression pattern of BMP2, LTP4, and DRL1 discriminates malignant from benign canine mammary tumors. *Vet Pathol* 2010;47:446–54.
- [39] Metivier KS, Deitz K, Xu WW, Conzemius M, Wilke VL. Gene expression profiling demonstrates differential expression of osteopontin in follicular thyroid carcinomas compared to normal thyroid tissue in dogs. *Vet Comp Oncol* 2014;12:181–97.
- [40] Nakamura A, Kobayashi M, Kuraoka M, Yuasa K, Yugeta N, Okada T, et al. Initial pulmonary respiration causes massive diaphragm damage and hyperCKemia in Duchenne muscular dystrophy dog. *Sci Rep* 2013;3:2183.
- [41] Kummer S. *VetBiobank/VTB_P44_Ki67*. Zenodo. 2021.
- [42] Kummer S. *VetBiobank/VTB_P44_osteopontin*: VTB_P44_osteopontin. Zenodo. 2021.
- [43] Schindelin J, Arganda-Carreras I, Frise E, Kaynig V, Longair M, Pietzsch T, et al. Fiji: an open-source platform for biological-image analysis. *Nat Methods* 2012;9:676–82.
- [44] Berg S, Kutra D, Kroeger T, Straehle CN, Kausler BX, Haubold C, et al. ilastik: interactive machine learning for (bio)image analysis. *Nat Methods* 2019;16:1226–32.
- [45] Coppola D, Szabo M, Boulware D, Muraca P, Alsarraj M, Chambers AF, et al. Correlation of osteopontin protein expression and pathological stage across a wide variety of tumor histologies. *Clin Cancer Res* 2004;10:184–90.
- [46] Tseng K-Y, Chung M-H, Sytwu H-K, Lee H-M, Chen K-Y, Chang C, et al. Osteopontin expression is a valuable marker for prediction of short-term recurrence in WHO grade I benign meningiomas. *J Neuro-Oncol* 2010;100:217–23.
- [47] Wei J, Marisetty A, Schrand B, Gabrusiewicz K, Hashimoto Y, Ott M, et al. Osteopontin mediates glioblastoma-associated macrophage infiltration and is a potential therapeutic target. *J Clin Invest* 2019;129:137–49.
- [48] Ahmed M, Behera R, Chakraborty G, Jain S, Kumar V, Sharma P, et al. Osteopontin: a potentially important therapeutic target in cancer. *Expert Opin Ther Targets* 2011;15:1113–26.
- [49] Li HZ, Gong HD, Wang C, Li JK. The role of osteopontin and its receptor in meningioma development and progression. *J Biol Regul Homeostat Agents* 2018;32:69–74.
- [50] Cahill KS, Claus EB. Treatment and survival of patients with nonmalignant intracranial meningioma: results from the surveillance, epidemiology, and end results program of the national cancer Institute. *Clinical article. J Neurosurg* 2011;115:259–67.
- [51] Schöniger S, Woolford L, Jutras L, Head E, Lahunta A de, Summers BA. Unusual features in four canine meningiomas. *J Comp Pathol* 2013;149:237–41.
- [52] Tabaran A-F, Armién AG, Pluhar GE, O'Sullivan MG. Meningioma with rhabdoid features: pathologic findings in dogs. *Vet Pathol* 2022;59:759–67.
- [53] Mauldin EA, Deehr AJ, Hertzke D, Dubielzig RR. Canine orbital meningiomas: a review of 22 cases. *Vet Ophthalmol* 2000;3:11–6.
- [54] Mazzucchelli S, DeLombaert M, Lieber K, Dubielzig RR. Abstracts: annual meeting of the European College of Veterinary Ophthalmologists, Trieste, Italy, May 24–27, 2012. *Vet Ophthalmol* 2012;15:1–12.
- [55] Montoliu P, Añor S, Vidal E, Pumarola M. Histological and immunohistochemical study of 30 cases of canine meningioma. *J Comp Pathol* 2006;135:200–7.
- [56] Lacassagne K, Hearon K, Berg J, Séguin B, Hoyt L, Beyer B, et al. Canine spinal meningiomas and nerve sheath tumours in 34 dogs (2008–2016): distribution and long-term outcome based upon histopathology and treatment modality. *Vet Comp Oncol* 2018;16:344–51.
- [57] Petersen SA, Sturges BK, Dickinson PJ, Pollard RE, Kass PH, Kent M, et al. Canine intraspinal meningiomas: imaging features, histopathologic classification, and long-term outcome in 34 dogs. *J Vet Intern Med* 2008;22:946–53.
- [58] José-López R, La Fuente C de, Pumarola M, Añor S. Spinal meningiomas in dogs: description of 8 cases including a novel radiological and histopathological presentation. *Can Vet J* 2013;54:948–54.
- [59] Cattoretti G, Becker MH, Key G, Duchrow M, Schlüter C, Galle J, et al. Monoclonal antibodies against recombinant parts of the Ki-67 antigen (MIB 1 and MIB 3) detect proliferating cells in microwave-processed formalin-fixed paraffin sections. *J Pathol* 1992;168:357–63.
- [60] Karamitopoulou E, Perentes E, Diamantis I, Maraziotis T. Ki-67 immunoreactivity in human central nervous system tumours: a study with MIB 1 monoclonal antibody on archival material. *Acta Neuropathol* 1994;87:47–54.