


REVIEW ARTICLE

Complications and treatment errors in implant positioning in the aesthetic zone: Diagnosis and possible solutions

Stephen T. Chen¹ | Daniel Buser^{2,3} | Anton Sculean⁴  | Urs C. Belser⁵

¹Melbourne Dental School, University of Melbourne, Parkville, Victoria, Australia

²School of Dental Medicine, University of Bern, Bern, Switzerland

³Center for Implantology Buser + Frei, Bern, Switzerland

⁴Department of Periodontology, School of Dental Medicine, University of Bern, Bern, Switzerland

⁵School of Dental Medicine, University of Geneva, Geneva, Switzerland

Correspondence

Stephen T. Chen, Melbourne Dental School, University of Melbourne, Parkville, Victoria, Australia.

Email: schen@periomelbourne.com.au

1 | INTRODUCTION

Dental implants today provide reliable and predictable treatment modalities for replacing missing teeth. The last 2 decades have seen a rapid expansion of implant therapy in general dental practice, with an increased focus on single tooth implants in the aesthetic zone and partially edentulous patients.¹ In a recent systematic review, 18 studies reporting on 10-year survival of titanium implants with micro-roughened surfaces were identified. A total of 1123 patients received 2688 implants. After 10 years, the summary estimate for the 10-year survival rate was 96.4% (95% CI: 95%-98%) with the associated prediction interval ranging from 92% to 99%.² This predictability has led to confidence in dental implant therapy as a viable treatment modality and its increased utilization in dentistry over the last 2 decades. In data from the USA, the prevalence of dental implants in the population increased from 0.7% in 1999 to 2000 to 5.7% in 2015 to 2016. When adjusted for covariates, there was an average 14% increase in the prevalence of dental implants each year, with a 13-fold increase in implant prevalence in the 65- to 70-year-old age cohort compared with the 18- to 34-year-old cohort. On current trends, the projected increase in prevalence of dental implants in 2026 would be 17%, with less conservative projections suggesting the prevalence could reach 23%.³ There are no doubts that these projections would be similar in many countries around the world.

With this increase in the number of patients receiving implants, there will be an inevitable rise in complications. Implant complications are related to four factors: the patient, the biomaterials used, the treatment approach, and the clinicians involved (Figure 1).⁴ The

clinician has responsibility for (i) evaluating the patient and assessing their risk profile, (ii) selecting the appropriate biomaterials to be used, (iii) selecting the most appropriate treatment approach to provide predictable outcomes with a low risk of complications, (iv) undertaking the procedural aspects of the treatment, and (v) monitoring and maintaining peri-implant health and managing complications if they arise. It is clear that the clinician bears significant responsibility for outcomes, including complications. It follows, therefore, that human factors resulting in errors of judgment represent the primary cause of complications in implant therapy.⁵ In other words, the clinician is the main cause of implant complications and the biggest risk factor for the patient.

A common clinician-related error is incorrect implant positioning, which can lead to functional and aesthetic compromise. The concept of three-dimensional implant placement to ensure that implants are placed in the correct position according to the prosthodontics needs was already established over 2 decades ago.^{6,7} Despite this well described concept, errors in implant positioning remain a common occurrence today.⁸ Malpositioned implants can result in significant aesthetic complications with loss of peri-implant soft tissue volume and recession of the peri-implant mucosa and papillae,⁹ and may also complicate successful prosthodontic rehabilitation.¹⁰

2 | IMPLANT POSITIONING ERRORS

At the Third ITI Consensus Conference in 2003 in Gstaad, Switzerland, the concept of "comfort" and "danger" zones for

This is an open access article under the terms of the [Creative Commons Attribution](https://creativecommons.org/licenses/by/4.0/) License, which permits use, distribution and reproduction in any medium, provided the original work is properly cited.

© 2023 The Authors. Periodontology 2000 published by John Wiley & Sons Ltd.

positioning of dental implants in the aesthetic zone was established.¹¹ Implants placed in the danger zone were regarded as being malpositioned and increased the risk for aesthetic complications. The comfort and danger zones may be defined in three dimensions: mesiodistal, corono-apical, and orofacial (Figure 2). The following will describe the etiology and outcomes of implant positioning errors in these three dimensions. This will be followed by a subsection on possible treatment strategies.

2.1 | Mesiodistal malposition

When an implant is placed too close to an adjacent tooth, there is a risk of a reduced height of the tooth-implant papilla because of resorption of the proximal bone at the adjacent tooth. This phenomenon was originally described for implants designed with an external hexagon abutment connection.¹² The micro gap at the implant-abutment junction results in localized bone remodeling that forms a crater- or saucer-like defect within the bone 1.0-1.5 mm lateral¹³ and 1.5-2.0 mm apical to the implant-abutment junction.¹⁴ This crater forms circumferentially around the implant (Figure 3A). If

the facial bone wall is thin, the crater does not form in this region; rather, the bone is resorbed on the facial aspect (Figure 3B). If the implant is placed greater than 1.5 mm from the adjacent teeth, the crater forms without loss of the proximal bone at the adjacent teeth (Figure 3C). If, however, the implant is placed less than 1.5 mm from the adjacent teeth, the bone remodeling causes loss of height of the proximal bone at the adjacent tooth. Because the proximal bone supports the papilla, it therefore follows that loss of proximal bone height at the adjacent teeth will result in reduction in the height of the tooth-implant papilla. The situation is often further compromised by recession of the gingiva and exposure of the root surface on the adjacent natural tooth (Figure 4A,B). This concept was corroborated in a study that found that the apical position of the proximal bone crest correlated with reduced height of the tooth-implant papilla.¹⁵ More recently, implants with an internal conical connection have been designed to minimize crestal bone remodeling.¹⁶ These implants retain marginal bone by creating a “platform switch”, in which the micro gap at the junction of the implant to the abutment is shifted internally away from the outer shoulder of the implant. Although it has been claimed that these implants can be placed closer than 1.5 mm to the adjacent

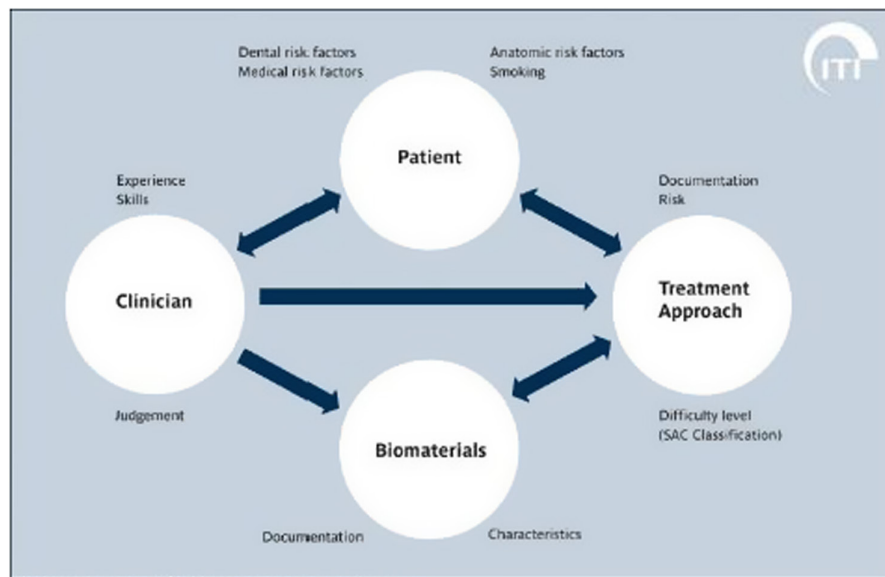


FIGURE 1 The four factors related to implant complications: the patient, the biomaterials used, the treatment approach, and the clinician. (Image from ITI Treatment Guide Vol. 3, *Implant Placement in Post-Extraction Sites*, 1st Edition, 2008 [p. 18, Figure 1] and *The SAC Classification in Implant Dentistry*, 1st Edition, 2022 [p. 10, Figure 2] used with permission from the International Team for Implantology and Quintessenz Verlags-GmbH). SAC, Straightforward, Advanced, Complex

© 2008 International Team for Implantology

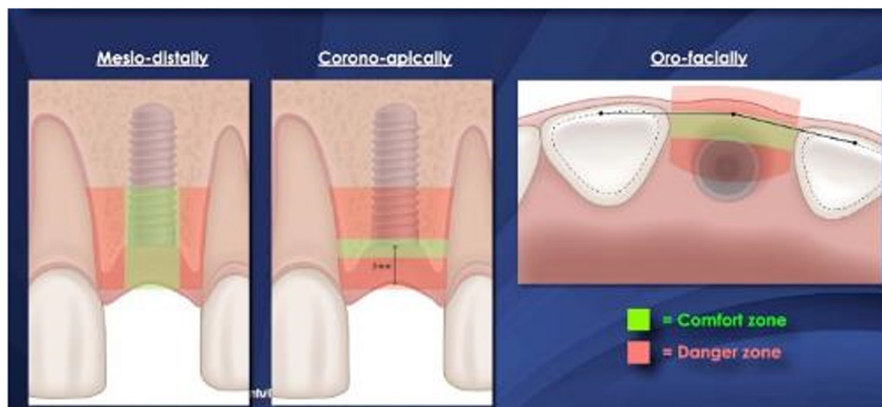


FIGURE 2 The concept of comfort and danger zones for positioning of implants in three dimensions: mesiodistally, corono-apically, and orofacially. Implants that are placed within the danger zones are more likely to be associated with compromised outcomes

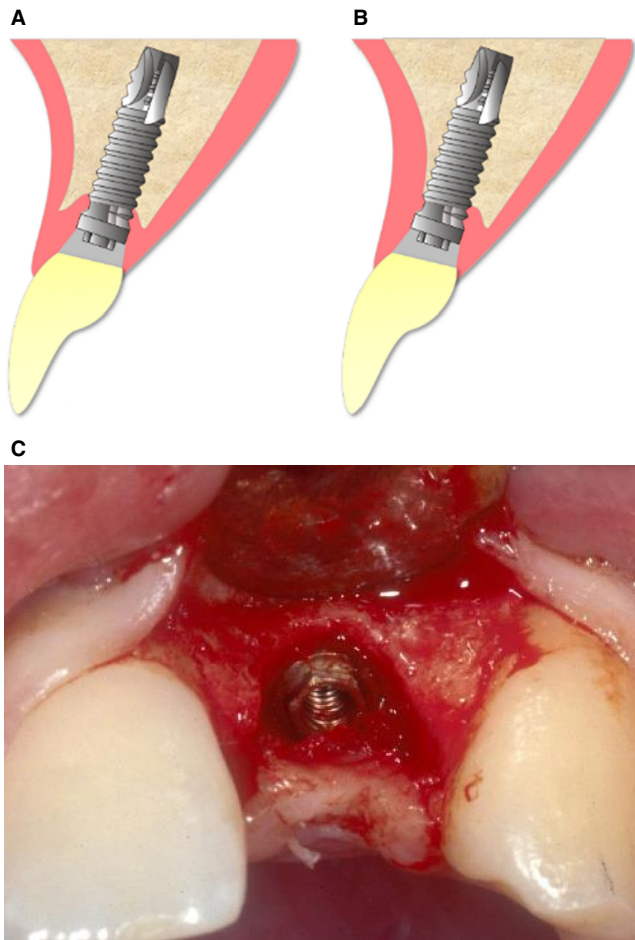


FIGURE 3 The formation of a crater- or saucer-like defect around implants with an external hexagon connection is depicted in these diagrams. A, If the facial wall is thick, a crater forms on the facial aspect. B, If the facial bone is thin, the bone resorbs to the first thread, leaving the facial soft tissue unsupported. C, A bone crater or saucer has formed around the neck of this implant with an external hexagon abutment connection. The crater extends 1.5 mm laterally from the implant to the proximal bone walls mesially and distally. As the distance from the implant to the adjacent teeth was > 1.5 mm, the proximal bone on the adjacent teeth have been preserved. Where the bone wall was thin on the facial aspect, a shallow crater has formed with loss of facial bone height

teeth with only minimal proximal bone loss,¹⁷ the proximity can be difficult to manage prosthodontically and reduces the space for the tooth-implant papilla to develop properly.

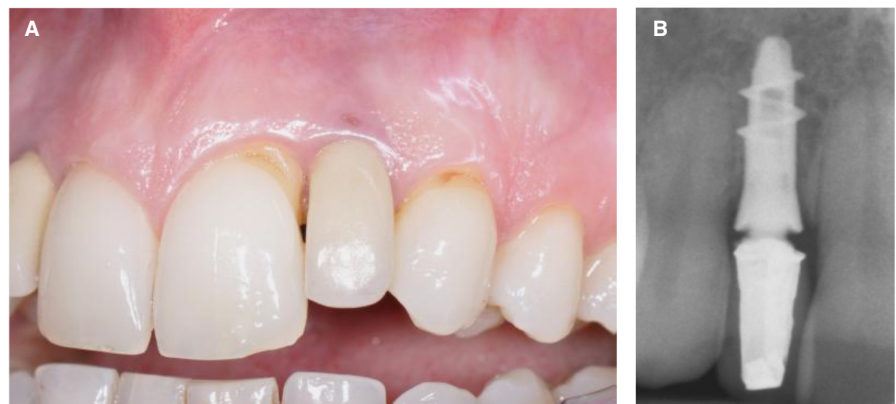Proximity to adjacent teeth may arise if the osteotomy is not prepared correctly in the mesiodistal center of the gap. This may be a result of an unrecognized positional error at the time of surgery, or sometimes because of a correction made at the time of surgery to avoid local anatomic structures, such as a prominent nasopalatine canal (Figure 5). Oversized implants for the space can result in the same type of complication.

Because of the cratering effect described previously, it has previously been recommended that a minimum 3 mm distance between the shoulder of adjacent implants be maintained to minimize proximal bone loss and to provide adequate support to the interimplant soft tissues.¹³ These recommendations were based on implants designed with external hexagon abutment connections. Even with sufficient separation between implants, however, maintaining interimplant soft tissue height can be challenging. The papilla can still be deficient, even in the presence of adequate interimplant bone. An average soft tissue height of 3.5 mm over the crestal bone between two implants may be insufficient to completely fill the interdental space^{18,19} (Figure 6A,B).

In contrast to implants with external hexagon abutment connections, many contemporary implants are designed with an internal conical abutment connection. These designs have been shown to minimize crestal bone loss and formation of circumferential bone craters at the implant shoulder.¹⁶ Several preclinical and clinical studies have demonstrated that these implants may be placed 2 mm apart without a detrimental effect on the interimplant bone peak.^{20,21} However, this degree of proximity may reduce the space available for the interimplant papilla to properly form, thereby adversely affecting the aesthetic result (Figure 7A,B). Therefore, the recommendation to maintain a minimum 3 mm of space between two adjacent implants in the aesthetic zone remains valid.

The aesthetic outcomes with two adjacent implants placed close together may also compromise the emergence profile and outline of the mucosal margin (Figure 8).

FIGURE 4 A, The papilla between the maxillary left central incisor and the lateral incisor implant has reduced in height. In addition, there has been recession of the gingiva on the distal and disto-facial aspect of the central incisor. B, The radiograph shows the proximity of the implant to the maxillary left central incisor. The peak of bone on the distal aspect of the tooth has receded



2.2 | Coronoapical malposition

In a coronoapical dimension, positioning errors may result in an implant shoulder being placed too shallow or too deep in relation to the comfort zone. For an implant crown to look natural, it needs to emerge from the shoulder of the implant through the transmucosal

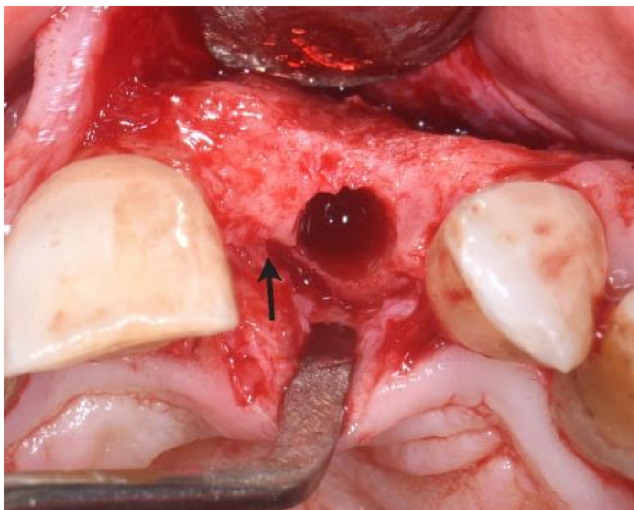


FIGURE 5 The position of the nasopalatine canal (black arrow) necessitated the osteotomy being placed slightly distally in the mesiodistal midline of the ridge. At this position, 2 mm of bone was maintained between the osteotomy and the adjacent lateral incisor

soft tissue cuff with a proper emergence contour. In the aesthetic zone, implants are generally placed slightly palatally so that the axis of the implant aligns with the cingulum of the restoration to facilitate screw retention of the prosthesis. From this slightly palatal position of the implant, sufficient vertical and horizontal distance are needed to create the proper emergence contour. The recommended vertical distance from implant shoulder to the midfacial mucosal margin is 3–4 mm. If an implant is placed with dimensions less than this, there is a risk that the abutment or even the implant shoulder may become visible (Figure 9A,B). There may also be a need for a ridge lap design in the prosthesis to provide sufficient tooth volume in the cervical region (Figure 10A–C).

A deeply placed implant is a common complication with immediate implants. This is usually associated with attempts to achieve primary stability by “driving” the implant deeper into the osteotomy. Deeply placed implants increase the complexity of restoration, and may have long-term implications for adequate plaque control. If the extraction socket has a thin or damaged facial bone wall, then the subsequent bone remodeling may lead to soft tissue recession.

2.3 | Orofacial and axial malposition

Errors in the orofacial position of an implant can lead to the implant being placed too far palatally, or too far facially. Implants can also

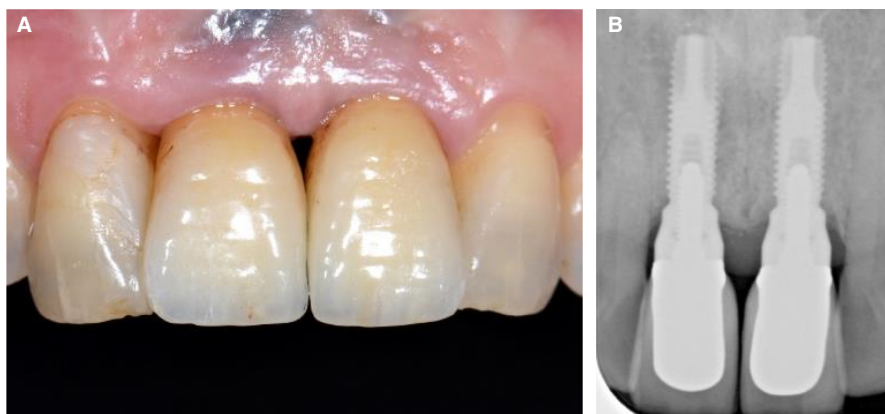


FIGURE 6 A, The papilla between the two implants in the maxillary right and left central incisor sites has flattened because of remodeling of the bone between the two implants. B, The corresponding periapical radiograph shows the flattening of the bone between the two implants. There is approximately 3.5 mm of soft tissue thickness over the interimplant peak of bone

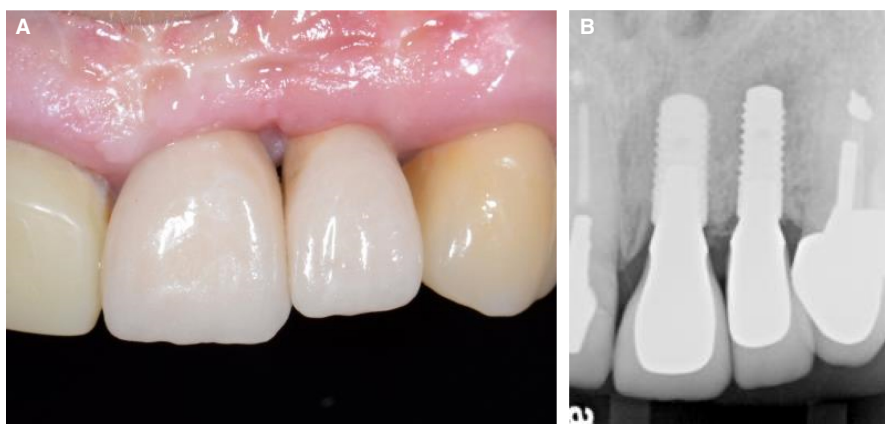


FIGURE 7 A, The interimplant papilla has failed to form because of the proximity of the two implants in the maxillary left central and lateral incisor sites. B, The corresponding radiograph shows that the two implants with an internal conical abutment connection design have been placed about 2 mm apart at the shoulder. Despite the peak of bone present between the two implants, the interimplant papilla failed to form a proper morphology

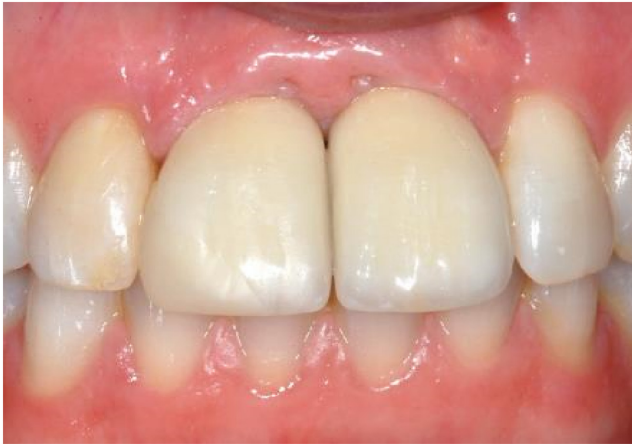

FIGURE 8 Two implants replacing maxillary central incisors have been placed too close together. As a consequence, the emergence profile of the individual crowns appears unnatural. The zenith of the mucosal margins are mesial rather than distal to the midline of each crown because of the malposition of the implants

be axially inclined too far to the facial or palatal side (Figure 11). Orofacial and axial malposition may often occur together.

An implant may be placed too far palatally because of preexisting bone loss. This is a relatively uncommon complication. In the presence of lack of tissue volume of the facial aspect, a palatal implant malposition can lead to significantly adverse aesthetic outcomes (Figure 12A-C). If, however, the palatal malposition occurs with adequate facial contour of the ridge, it may be difficult to obtain a proper emergence profile in the final crown because of the thickness of the facial soft tissues. For this reason, ridge lap designs are often used to compensate for the palatal positioning.

Facial malposition of an implant is by far the most common implant positioning error (Figure 13A,B). The implant may be either positioned or axially inclined too far facially. Often, positional and axial errors occur together (Figure 14A,B).

Another cause for a facial malposition is the insertion of an oversized implant, as was often recommended in the late 1990s. The large diameter (≥ 6 mm) results in a facial malposition (Figure 15A,B). Implants that are facially malpositioned are strongly associated with mucosal recession. Two studies calculated the odds ratios of mucosal recession at facially positioned implants compared with correctly placed implants as 14.7 and 17.2, respectively.^{8,22} Facial malposition is often encountered with immediate implant placement.^{23,24} The osteotomy is usually prepared in the apico-palatal region of the socket of an upper anterior tooth. When the implant is inserted, the dense cortical bone of the palatal socket wall can cause the implant to “move” slightly towards the facial side. The axis of the implant may also divert more towards the facial side. It has been shown that a small deviation of about 1 mm to the facial side of the socket is sufficient to increase the risk of soft tissue recession.²⁵ Axial malposition to the facial side is often seen in sites with developmentally missing teeth. Lack of development of the alveolar process routinely results in a significant facial concavity in the midfacial region of the alveolar

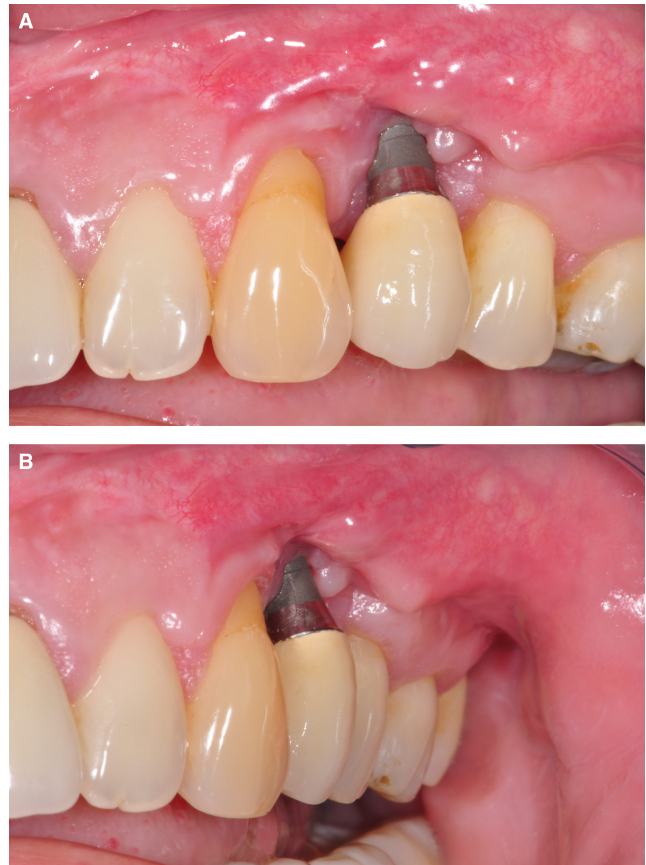

FIGURE 9 A and B, The implant in the maxillary first premolar site has been placed with the shoulder too far coronally. In addition, the implant has been placed with a slight facial malposition. The result is recession of the peri-implant mucosa and an aesthetic disaster

process. To place the implant within bone, a clinician may inadvertently angle the implant to the facial side.

2.4 | Inappropriate use of multiple adjacent implants

Multiple adjacent implants in extended edentulous spaces can also lead to positional errors and aesthetic complications. This complication arises when the clinician has either prescribed too many implants for the available space, or has adopted the treatment philosophy to place one implant for every missing tooth. When multiple adjacent teeth in the anterior maxilla are extracted, the alveolar ridge resorbs from the facial side, resulting in a flattening of the ridge. The mesiodistal dimension of the flattened ridge is less than the original mesiodistal dimension prior to tooth extraction (Figure 16). If multiple adjacent implants are placed, there is a risk that the implants may be placed too close together (Figure 17A). To avoid implant proximity, the implants may instead be facially positioned and/or axially inclined to the facial side (Figure 17B). In either scenario, the result is usually an unaesthetic soft tissue outcome.

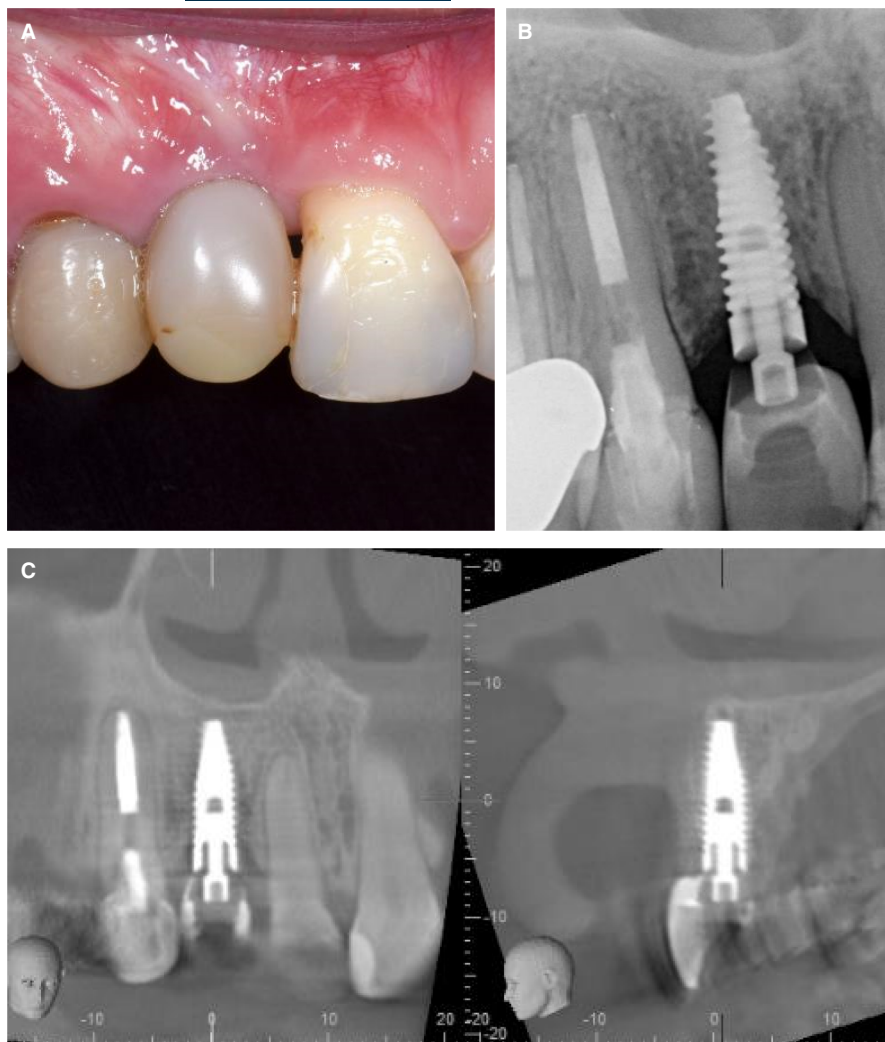


FIGURE 10 A, The implant in the maxillary right lateral incisor site has been restored with a provisional crown. The prosthesis has a ridge lap on the facial aspect. B, A periapical radiograph of the implant suggests that the implant has been placed with the shoulder positioned too far coronally. C, CBCT analysis confirmed that the shoulder of the implant has not been placed deeply enough. The implant is also in a palatal malposition. The consequence is that the prosthesis requires a ridge lap on the facial aspect. CBCT, cone beam computed tomography

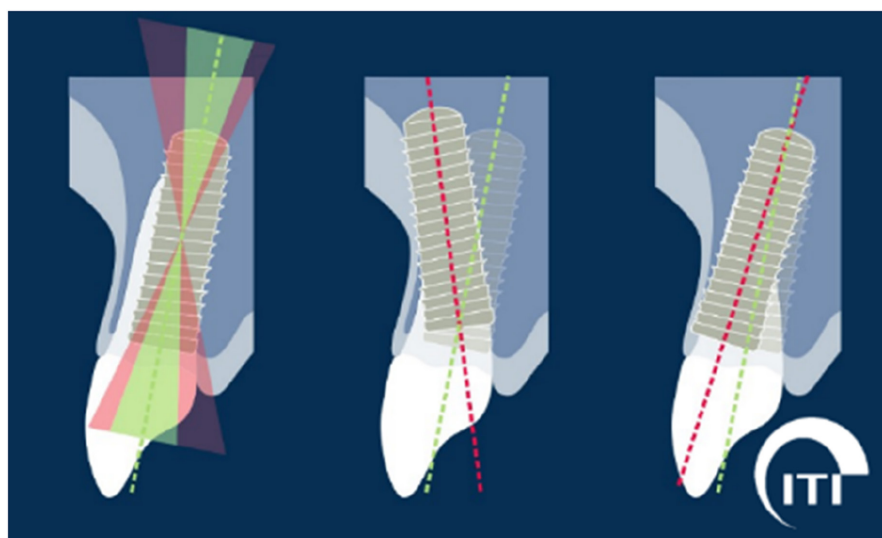


FIGURE 11 Diagrammatic representation of facial and axial malposition of implants that result in the implant shoulder being positioned in the facial and palatal danger zones, respectively. (Image from ITI Treatment Guide Vol. 10, *Implant Therapy in the Esthetic Zone - Current Treatment Modalities and Materials for Single-tooth Replacements*, 1st Edition, 2017 [p. 357, Figure 4B] used with permission from the International Team for Implantology and Quintessenz Verlags-GmbH)

3 | DIAGNOSIS AND SOLUTIONS

The treatment solutions to manage adverse outcomes through positioning errors require an understanding of the underlying

conditions and of those factors that may have led to the error being committed in the first place. Before discussing treatment solutions, prevention of such errors should be foremost in the minds of clinicians.

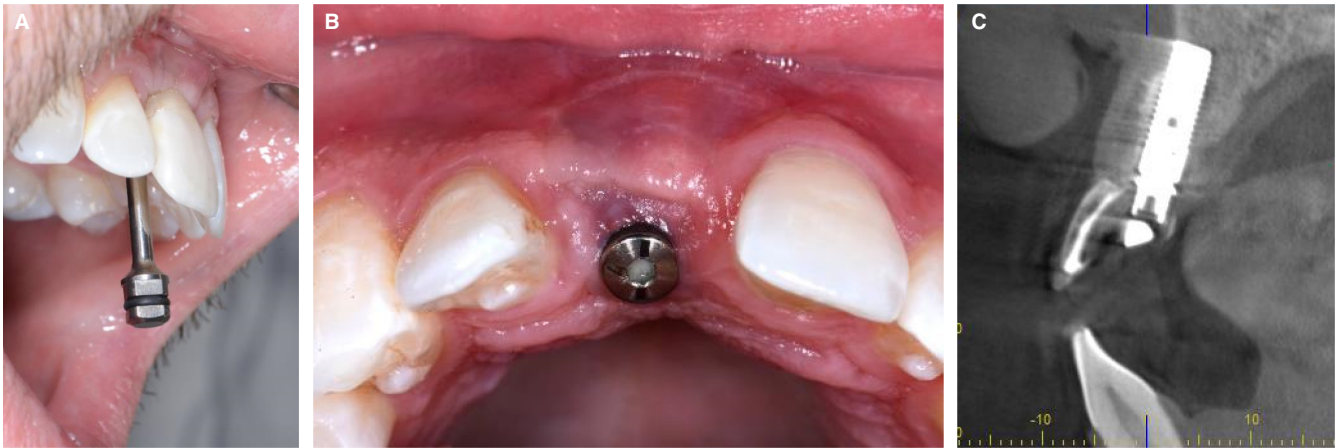

FIGURE 12 A, This implant in the upper right maxillary central incisor site has been placed in a palatal malposition. B, Following removal of the provisional crown, the palatal malposition can be observed clinically. There is also lack of tissue volume on the facial aspect. C, The CBCT scan confirmed the palatal malposition of the implant in relation to the axis of the provisional crown. Axially, the implant has also been tilted too far to the palatal side. CBCT, cone beam computed tomography

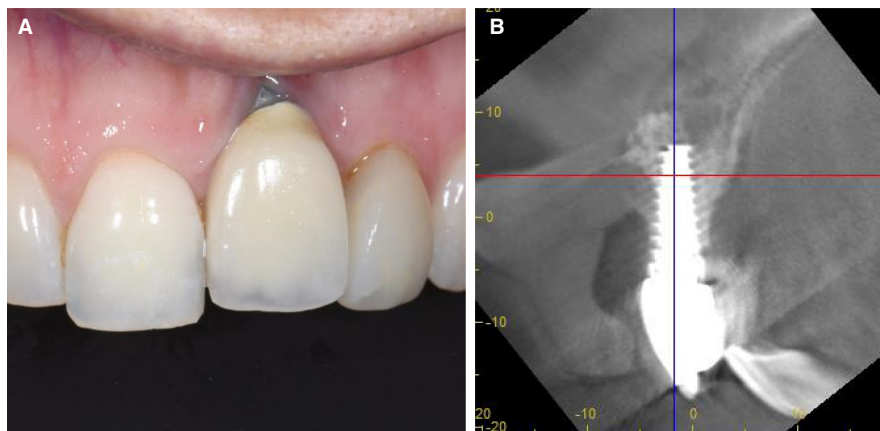


FIGURE 13 A, The implant in the maxillary left central incisor site has been placed in a facial malposition. This has resulted in recession of the facial mucosa. The implant was placed about 10 years previously, and vertical growth changes have accentuated the incisal edge and mucosal margin discrepancy. B, The corresponding CBCT scan confirms the facial malposition of the implant. The sagittal view has been rotated so that the blue vertical line coincides with the central long axis of the implant. With this orientation, it can be observed that the incisal edge of the prosthesis is palatal to the axis of the implant. CBCT, cone beam computed tomography

3.1 | Prevention of positioning errors by proper diagnosis and planning

The primary objective of implant treatment should be to provide the patient with a predictable long-term outcome with the least risk for complications during the healing period and during implant function. Because positioning errors can result in significant aesthetic complications in the anterior maxilla, the clinician should aim to eliminate the risk of this type of implant malposition by first undertaking a proper examination and diagnosis to understand the underlying situation with the alveolar bone and soft tissues, and then setting out an appropriate treatment plan that minimizes risk. An aesthetic risk assessment is therefore strongly recommended to determine the risk of adverse aesthetic outcomes with a given case.²⁶ With respect to the risk of positioning errors, the following

categories within the aesthetic risk assessment should be closely examined:

1. Width of the edentulous space. The dimension of the implant selected should be consistent with the mesiodistal width of the edentulous space. As discussed previously, the shoulder of an oversized implant may become too close to the adjacent tooth and risk the proper development of a tooth-implant papilla. Clinicians should aim to maintain a minimum 1.5 to 2 mm of distance between the shoulder of the implant and adjacent teeth.
2. Gingival phenotype. Thin gingival phenotypes are associated with a greater risk of recession of the facial mucosa margin. Thin gingival phenotypes tend to have longer papillae than thick gingival phenotypes, and are more prone to posttreatment reduction

in the height of the tooth-implant papillae, which can be compounded if an implant is placed too close to the adjacent tooth.

3. Bone anatomy at the alveolar crest. Bone volume deficiencies at the alveolar crest may lead to positioning errors. If there is a significant orofacial or horizontal deficiency on the facial aspect, the implant may be positioned with a shoulder too far to the palatal side. In the case of a vertical bone deficiency at the crest, the implant shoulder may be positioned deeper than the recommended 3-4 mm from the anticipated midfacial mucosal margin. If the

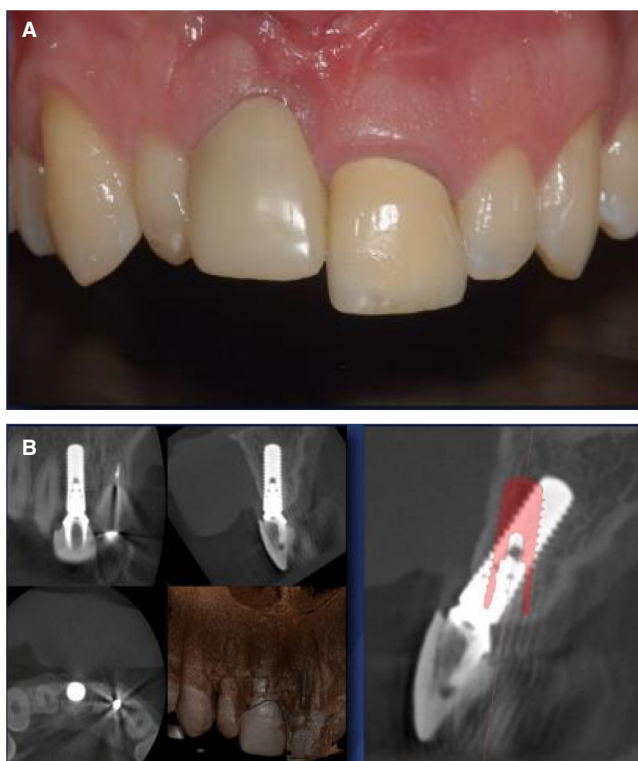


FIGURE 14 A, In this case, the implant in the maxillary right central incisor site is both positioned and inclined too far facially. B, In the sagittal view, an outline of an implant (red image) in the correct position has been overlaid on the CBCT scan of the implant. This highlights the combined facial position and facial inclination of the implant. CBCT, cone beam computed tomography

alveolar ridge has a deep concavity on the facial aspect, there is a risk that the implant may be inclined too far to the facial aspect as the clinician attempts to keep the implant within the bony envelope. Today, this potential complication can be avoided with high-quality three-dimensional radiographic imaging. With the advent of cone beam computed tomography, which is readily available to clinicians, the potential for the underlying bone anatomy to create an implant malposition can be assessed as part of the treatment planning process.

If the conditions for optimal implant positioning are not met, then the clinician should consider steps to mitigate the risk of adverse outcomes. With reduced mesiodistal width, narrow diameter implants may be a solution, provided the minimum distance between implant and adjacent teeth is observed. When the mesiodistal width is too small, alternative prosthodontic options should be considered (eg, a resin-bonded fixed partial denture).

Besides the correct three-dimensional positioning of the implant, a successful bone augmentation of the facial bone wall of sufficient thickness and height is necessary in most cases to provide good bony support for aesthetically pleasing peri-implant soft tissues. Implant placement can be differentiated into postextraction and healed sites. In postextraction sites, the thickness of the facial wall of the extraction socket is an important selection criterion for the most appropriate treatment option,²⁷ because preclinical and clinical studies have clearly shown various degrees of vertical bone loss, mainly on the facial aspect within a few weeks postextraction because of bundle bone resorption.²⁸⁻³¹ At risk are extraction sites with a thin or no facial bone wall and these sites are prone to mucosal recessions in the short term and midterm³² if the facial bone wall is not successfully augmented with a simultaneous bone augmentation procedure using guided bone regeneration. In such a case, this implant is at risk for the development of a biologic complication such as peri-implant mucositis or peri-implantitis, because it will have an exposed micro-rough implant surface in the transcristal/peri-implant sulcus area. A recent systematic review reported 5.43 higher odds for the future development of peri-implantitis at implants with early bone loss of 0.5 mm or more within the first year of function. Furthermore, the probability of peri-implantitis

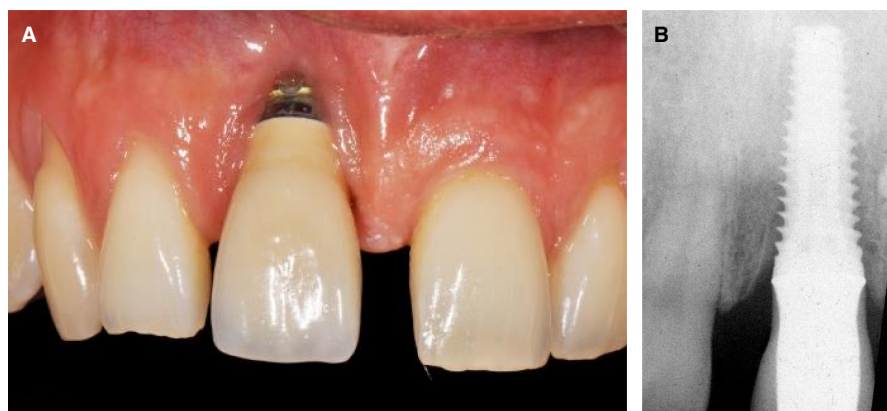

FIGURE 15 A, An implant with a shoulder diameter of 6 mm has been placed in the maxillary right central incisor site. The oversized implant has resulted in a facial malposition of the implant, and subsequent recession of the midfacial mucosa. B, The corresponding periapical radiograph of the implant

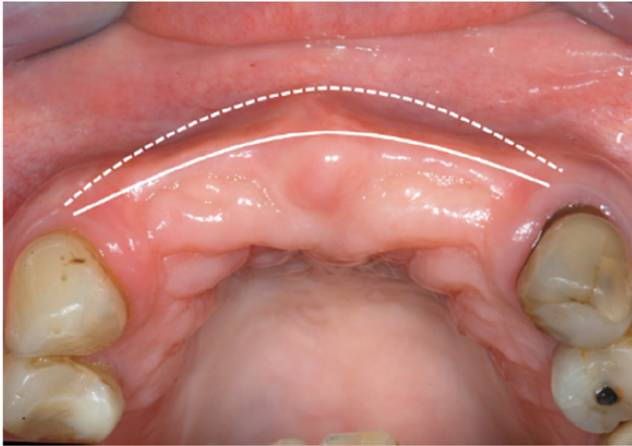


FIGURE 16 When multiple adjacent teeth in the anterior maxilla are extracted, the alveolar ridge resorbs from the facial side, resulting in a flattening of the ridge. The mesiodistal dimension of the flattened ridge (continuous line) is less than the original mesiodistal dimension prior to tooth extraction (dotted line)

developing over a 10-year observation period was 52% when early bone loss of ≥ 0.5 mm was combined with the risk factors of cigarette smoking and a history of periodontitis.³³ In the anterior maxilla, > 90% of patients present with a thin or no facial wall, as shown in several radiographic studies using cone beam computed tomography,^{30,34,35} and they all require a bone augmentation procedure (Buser et al 2021)³⁶. In sites with a thick facial wall (> 1 mm), immediate implant placement is favored by our group.²⁷ Therefore, flapless computer-assisted implant placement and internal grafting with a low-substitution bone filler are clearly preferred today, and offer the patient attractive and predictable outcomes with the least surgical morbidity.^{37,38}

In healed sites, there is frequently a buccal flattening of the alveolar ridge on the buccal aspect. If an implant cannot be placed into the correct three-dimensional position because of a bone deficiency, then the feasibility of bone augmentation procedures should be evaluated using a simultaneous or staged approach. As a general consideration, simultaneous bone augmentation is feasible if the implant can be placed in the correct three-dimensional position and the resultant peri-implant bone defect has at least two intact bone walls.³⁶ If the peri-implant bone defect has less than two intact bone walls, commonly observed at implants placed into deficient healed sites, a staged approach with a bone augmentation first is recommended. The site would be reconstructed with an autogenous block graft as a first step, followed by implant placement 4-6 months later following consolidation of the graft.³⁹ Another surgical technique is the sausage technique with a mixed composite graft and membrane fixation with pins.⁴⁰

Today, implant positioning errors can be avoided by utilizing digital software planning and three-dimensional printed surgical templates to ensure accurate positioning of implants. During the planning stage, deficiencies in bone and soft tissue can readily be identified. This provides the clinician with the opportunity to

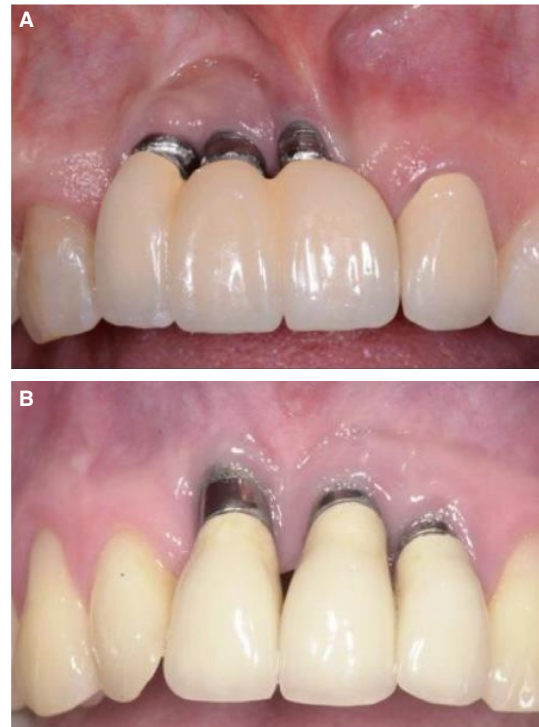

FIGURE 17 A, Because of insufficient mesiodistal space, three implants have been placed that are too close together. B, In this case, the three adjacent implants have been correctly separated. To increase the space required to accommodate the implants, they have been facially positioned and/or axially inclined to the facial aspect

consider options to manage these deficiencies before proceeding with surgery. This also facilitates discussion with the patient in case of a risk of adverse aesthetic outcomes. If a compromise is likely to eventuate, then consent from the patient prior to proceeding is of paramount importance. Nonimplant treatment options to replace teeth should also be offered in case the patient is unable to accept the aesthetic compromise.

3.2 | Treatment options for mesiodistal and coronapical malposition

As a general observation, it is not possible to correct a deficient or missing tooth-implant papilla because of a mesiodistal malposition. In most cases, it is also not feasible to remove the implant, as this may risk attachment loss or damage to the adjacent tooth. The unfortunate situation is that the compromise of a mesiodistal implant positioning error may need to be accepted. The prosthodontic option of incorporating soft tissue-colored ceramic into the prosthesis to replicate the missing soft tissue could be considered.

In relation to an implant being placed with the shoulder too shallow, a ridge lap prosthesis may be the only option if the implant is to be retained. If the coronal malposition is not too extreme, soft tissue grafting can sometimes be used to increase soft tissue height and

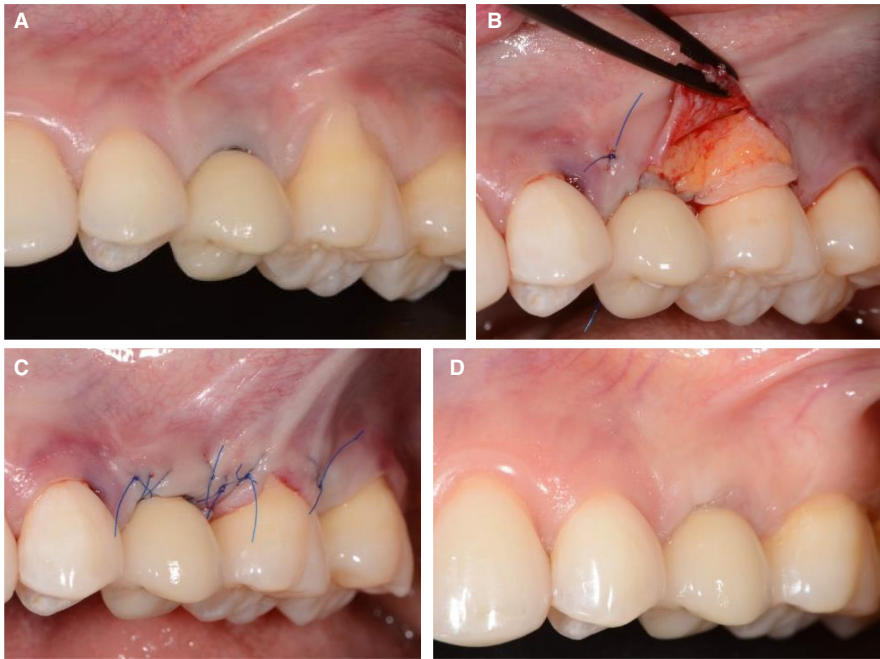


FIGURE 18 A, Shallow recession of the facial mucosa at implant 25 and a deep and large gingival recession on the mesiobuccal aspect of tooth 26. Note the lack of inflammation of the tissues. B, Treatment performed using a combination of coronally advanced tunnel and envelope in conjunction with a subepithelial palatal connective tissue graft to manage the recession defects on both the implant 25 and the adjacent tooth 26. C, Wound closure with sling sutures. D, Clinical image at 1 year postoperatively illustrating complete recession coverage at both the implant 25 and tooth 26. Please observe the absence of a gray titanium “shine through” of the facial mucosa at the 25 implant

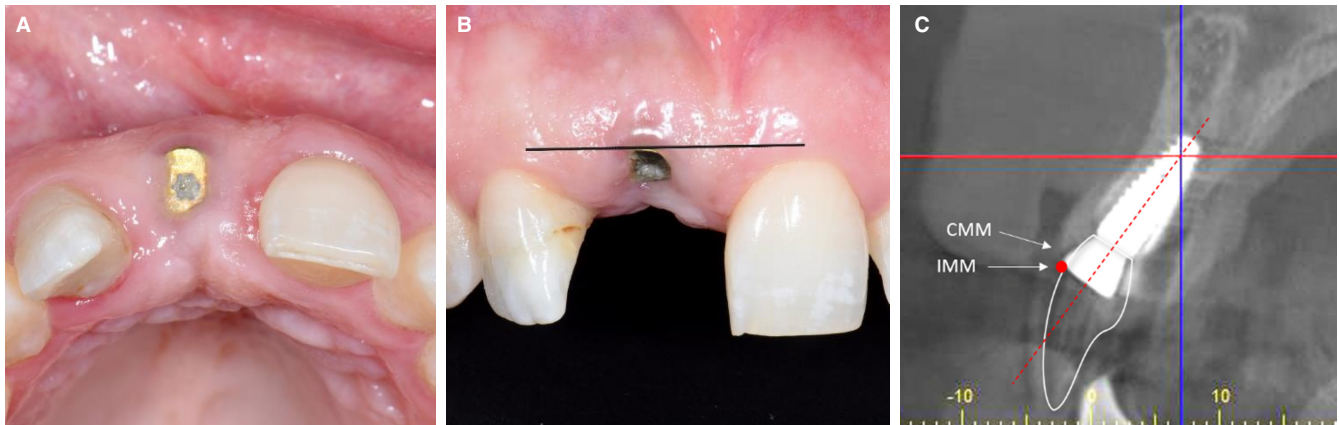

FIGURE 19 A, The implant in the maxillary right central incisor has been placed in a facial malposition. The facial aspect of the healing abutment is at the limit of the curvature of the arch at the level of the gingival margin. B, From the facial aspect, the mucosal margin at the implant is approximately 1.5 mm apical to that of the contralateral central incisor. C, The corresponding sagittal view of the CBCT scan clearly demonstrates the facial and axial malposition of the implant. The central axis of the implant in (red dotted line) shows the implant emerging facial to the incisal edge of the anticipated restoration (white outline of the crown). The red dot marks the IMM located 1.5 mm coronal to the CMM. The clinician then has to determine whether a crown, abutment, and minimum 1 mm soft tissue thickness can be accommodated at the level of the red dot without extending facially to it. In this case, it was determined that the facial and axial malposition was too severe, and the decision was therefore made to remove and replace the implant. CBCT, cone beam computed tomography; CMM, current mucosal margin; IMM, ideal midfacial mucosal margin

volume to hide the metal margin and mask the color of the underlying metal components (Figure 18A-D). The alternative is to remove the implant and replace it with one that is in the correct coronal position.

For implants placed too deep, the compromise could be accepted, or the implant removed and replaced. However, implant removal and replacement are only feasible if there is sufficient alveolar ridge height. It does not make sense to remove and replace the implant if there is preexisting loss of alveolar ridge height. Vertical bone augmentation in the maxillary anterior region is challenging and unpredictable.

3.3 | Treatment options for orofacial and axial malposition

If an orofacial and/or axial malposition results in recession of the midfacial mucosa, soft tissue correction utilizing connective tissue grafts may be considered. However, connective tissue grafts to manage recession defects on implants can be unpredictable.⁴¹⁻⁴³ The predictability is dependent upon the degree of malposition.⁹ The main limiting factor is the natural contour of the dental arch at the level of the gingival margin of the adjacent teeth.⁴² If the implant and prosthesis extend facially to this contour, it becomes more difficult

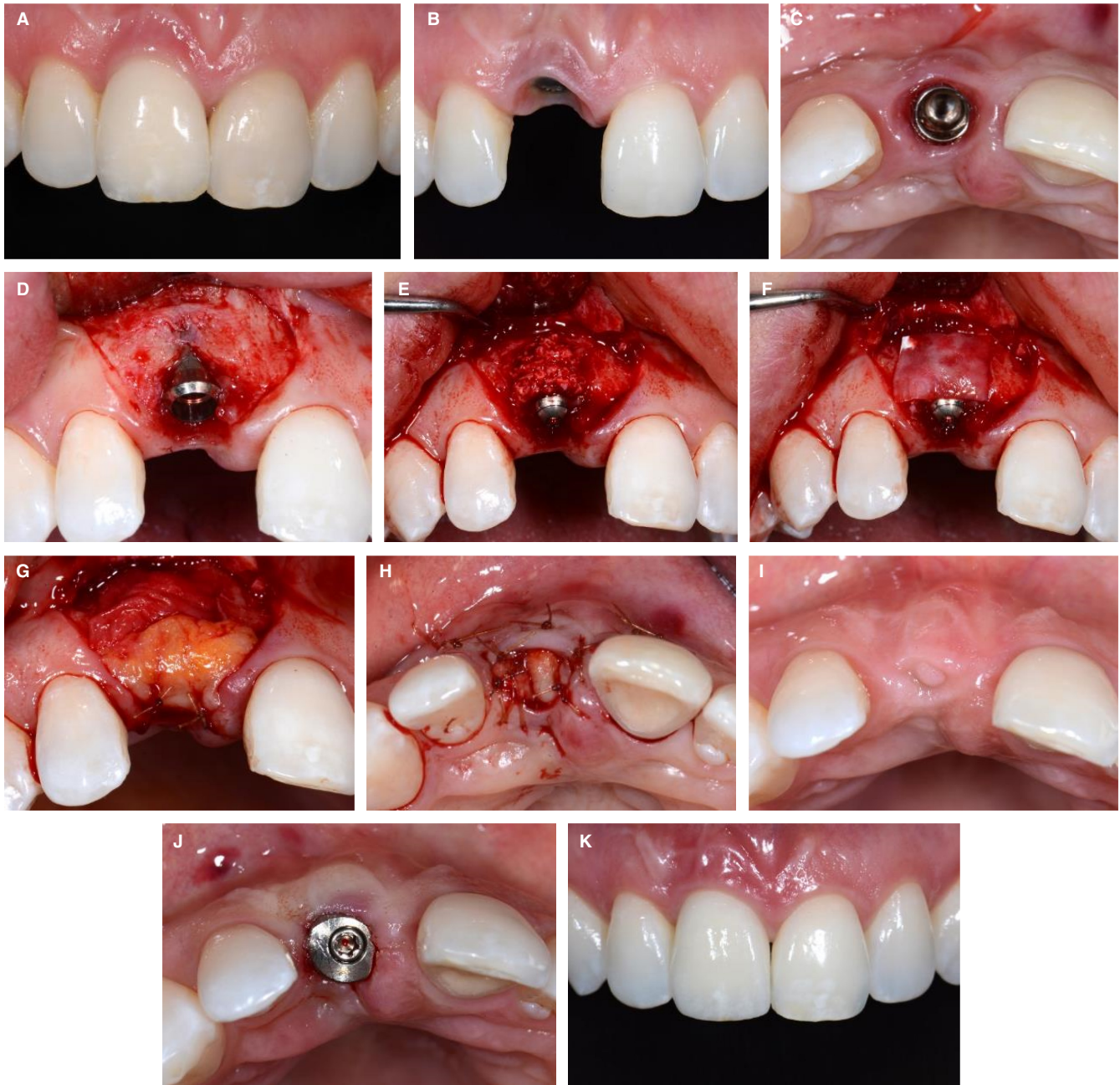


FIGURE 20 A, The implant replacing the right maxillary central incisor was placed as an immediate implant 8 years previously. Over time, there was a gradual recession of the midfacial mucosal margin, compounded by ongoing dentofacial growth. B, Following removal of the crown, the relatively thin mucosa on the facial aspect was evident. C, An occlusal view of the implant confirmed that it was positioned within the natural contour of the ridge. Soft tissue volume was lacking on the facial aspect. D, Following flap reflection, a dehiscence of the facial bone was observed in the shoulder of the tissue level implant. E, deproteinized bovine bone mineral was grafted over the defect to improve contour of the ridge. F, The graft was covered with a resorbable barrier membrane. G, A connective tissue graft harvested from the palate was then placed over the implant and the coronal facial aspect of the ridge. H, The facial flap was closed leaving the connective tissue graft over the implant exposed. I, After 4 months of healing, the soft tissues had healed with complete epithelialization of the connective tissue graft at the crest of the ridge. J, A transmucosal healing abutment was then connected to the implant. K, A new implant crown was then constructed. This image was taken 4 years after completion of the treatment

to achieve a predictable outcome with soft tissue grafting. The treatment is often complex, frequently requiring removal of the implant crown, bone augmentation if bone is deficient facially, and modification of the implant restoration emergence profile.⁴⁴

A careful analysis is therefore required to determine this. As a general rule, the implant crown cannot extend facial to the natural curve line of the arch at the level of the midfacial mucosal margin of the adjacent teeth. In the region of the affected implant, this is

an imaginary line that connects the profile of the arch of the adjacent teeth⁴² and may be clinically visualized from the occlusal aspect, or on axial views of cone beam computed tomography scans. The position of the implant/abutment/crown can sometimes be

estimated in the parasagittal plane. For the soft tissue graft to be successful, there needs to be sufficient space within the curvature of the arch to accommodate the crown, abutment, and at least 1 mm thickness of the mucosa. This is illustrated in Figure 19. This

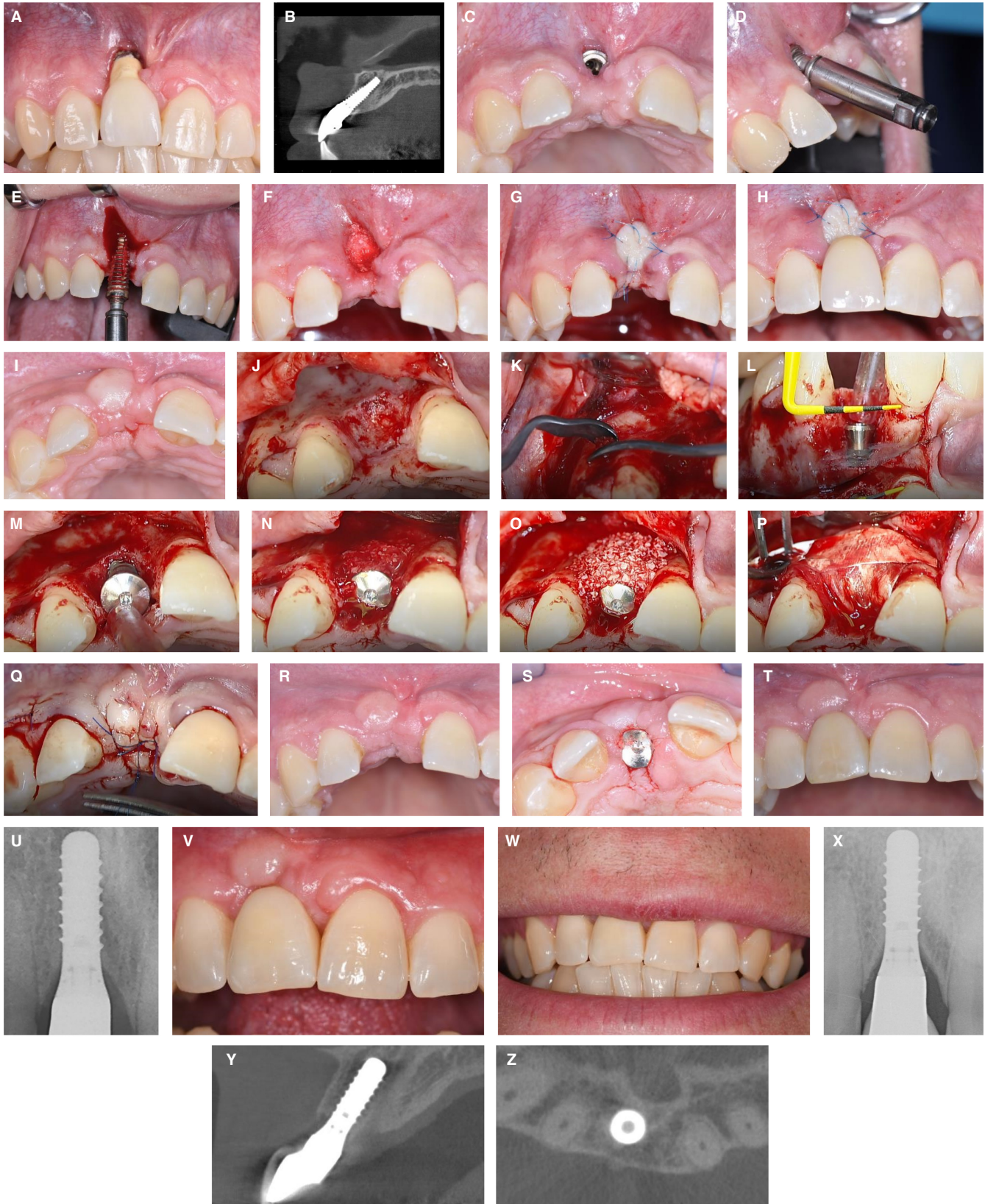

FIGURE 21 A, There has been severe recession of the facial mucosa at this maxillary right central incisor implant. The recession has resulted from facial and axial malposition of the implant. Note the absence of keratinized mucosa. B, The CBCT scan confirms the facial and axial malposition of the implant. In addition, there is no facial bone wall. C, The implant crown was removed, revealing the shoulder of the implant. From this occlusal view, it can clearly be seen that the shoulder of the implant is in a facial malposition. D, An implant removal device using reverse torque (BTI Implant Removal Kit, BTI Biotechnology Institute, Vitoria, Spain) was used to remove the implant. In this image, an extender connected to a counterclockwise threaded extractor has been inserted into the top of the implant. The axial malposition is clearly demonstrated. E, The implant was removed following application of counterclockwise torque. F, The residual defect in the bone was grafted with DBBM (Bio-Oss, Geistlich Pharma AG, Wolhusen, Switzerland). G, A free gingival graft harvested from the palate was used to protect the graft and to restore keratinized mucosa. H, A removable partial denture provided the patient with an interim replacement of the right maxillary central incisor. I, The clinical situation 2 months after implant removal. Note the increased volume of keratinized mucosa on the facial aspect. J, Following elevation of a triangular, full thickness flap, the bone defect in the alveolar crest is visible. The bone defect is located on the facial aspect, but also the palatal bone wall is reduced in height by approximately 2 mm. K, The first step following flap elevation is the local harvesting of autologous bone chips from the cortical bone surface in the vicinity with a sharp bone scraper. The chips are stored in a sterile dish with a 1:1 mixture of blood and sodium chloride (0.9%). L, Following implant bed preparation, a tissue level implant was selected and inserted (12 mm regular neck RN 4.1 Straumann SLActive implants, Straumann Group, Basel, Switzerland) with the micro-rough implant surface about 1 mm subcrestally in relation to the palatal bone wall. The facial view in the mirror shows the implant shoulder about 3 mm apically to the CEJ of the left central incisor. M, The occlusal view, following insertion of a 1.5 mm healing cap, shows the extended two-wall defect. The goal of grafting is a so-called contour augmentation with a two-layer composite graft using the GBR technique. N, The first layer is made of autologous bone chips to cover the exposed implant surface and to fill the entire bone defect. The bone chips are applied to the rim of the healing cap. O, The second layer is a thick layer of DBBM particulate (Bio-Oss). Before application, the DBBM particles have been activated in BCM. BCM is a solution of blood and sterile saline, into which the bone chips have released growth factors, in particular $TG\beta-1$. P, The graft is then protected by a double layer of a resorbable collagen membrane (Bio-Gide, Geistlich Pharma AG, Wolhusen, Switzerland). Q, The surgery was completed with a tension-free, primary closure of the flap using mattress and single sutures. For that, a release of the periosteum is always necessary to avoid tension in the flap closure. R, This is the clinical situation 8 weeks following implant surgery. The wound healing was uneventful without wound dehiscence for the duration of the healing period. S, At 8 weeks, a reopening procedure is conducted with a mucosal punch excision. The short healing cap is replaced by a 4.5 mm healing cap. Note the facial contour of the ridge that has been significantly augmented in comparison with the original clinical situation. T, This is the final crown at the 1-year follow-up examination. The aesthetic outcome is satisfactory when considering the initial status with the severe mucosal recession. U, The corresponding periapical radiograph of a well-integrated tissue level implant. The fidelity of the implant crown is excellent. V, At the 5-year follow-up, the clinical status shows good mucosal stability. However, soft tissue scars are visible, resulting from the mucosal graft performed when the implant was removed. W, The smile line exhibits no exposure of the midfacial mucosa. Therefore, the patient is reluctant to correct the observed scar lines. X, The peri-apical radiograph at the 5-year examination shows a well-integrated implant and the typical bony saucers at the implant neck with a smooth, machined surface. Y, The corresponding CBCT scan confirms a fully intact facial bone wall, which was regenerated with the GBR technique. The thickness of the facial wall measures approximately 2 mm. Z, The horizontal CBCT cut confirms the bone regeneration at the facial bone defect, which was present at the time of implant placement. BCM, bone conditioned medium; CBCT, cone beam computed tomography; CEJ, cemento-enamel junction; DBBM, deproteinized bovine bone mineral; GBR, guided bone regeneration; $TG\beta-1$, transforming growth factor beta 1

patient was referred to manage recession of the mucosa that was observed following connection of a healing abutment and prior to construction of the definitive crown. From an occlusal view, it could be seen that the facial edge of the healing abutment already extended facial to the curvature of the dental arch at the level of the gingival margins of adjacent teeth (Figure 19A). A frontal view demonstrated that the mucosal margin had already receded approximately 1.5 mm apical to that of the gingival margin of the contralateral central incisor (Figure 19B). The corresponding cone beam computed tomography scan illustrates that, at the level of the ideal midfacial mucosal margin position, there would be insufficient orofacial space to accommodate the crown, abutment, and 1 mm of soft tissue thickness (Figure 19C). The outcome of a connective tissue graft to correct the recession would therefore be unpredictable.

If the conditions described above are met, then connective tissue grafts may be a predictable means for correcting the soft tissue recession. Soft tissue grafting may be combined with bone augmentation when alveolar ridge deficiencies are identified (Figure 20A-K).

In cases when the facial and/or axial malposition is too severe, several options may be considered, including accepting the aesthetic compromise, incorporating pink ceramic at the cervical region of the crown, and removal/replacement of the implant in the correct three-dimensional position. Removal and replacement of the implant often requires adjunctive hard and soft tissue augmentation (Figure 21A-Z).

3.4 | Treatment of positional errors with adjacent implants

The options for treating these types of errors are limited. It may be possible to remove one implant if one or other implants are in the correct position. In most cases, correction of the malposition can only be achieved by the removal of all implants, reconstruction of the ridge, and replacement of the implants. This often involves multiple and complex procedures over an extended period of time. If the implants can be maintained with good peri-implant health,

prosthodontic options to mask the malposition may be considered. In cases of vertical and/or horizontal bone deficiencies, the utilization of pink ceramic to replace the missing hard and soft tissues may be considered. A removable prosthesis is sometimes the only option.

4 | CONCLUSIONS

Complications because of positioning errors of dental implants in the anterior maxilla can result in significant adverse aesthetic outcomes. In almost every case, the complication has occurred because of an error in judgment by the clinician. It is the clinician's responsibility to evaluate patient and site-related factors, and to determine if implant therapy is a suitable option. The excuse that there were preexisting factors such as a narrow gap or bone deficiencies that led to the malposition cannot be accepted in modern implant therapy today. Positioning errors can be eliminated with the use of cone beam computed tomography and digital technology to assist with planning and subsequent production of three-dimensional printed surgical templates. If errors do occur, the adverse aesthetic outcomes are difficult and sometimes impossible to correct. Connective tissue grafting to reverse recession defects is only feasible in defined situations. The option to remove and replace the implant may be the only recourse, provided the removal process does not further compromise the site. With the projected increase in the number of clinicians providing implant therapy and the rise in the number of patients treated, an increase in complications seems inevitable. The profession has a responsibility to mitigate this risk by emphasizing the need for proper implant education and training. Clinicians embarking upon a career in implant dentistry should seek appropriate mentors to support their learning.

ACKNOWLEDGMENT

Open access publishing facilitated by The University of Melbourne, as part of the Wiley - The University of Melbourne agreement via the Council of Australian University Librarians.

CONFLICT OF INTEREST

The authors report no conflict of interest.

DATA AVAILABILITY STATEMENT

Data sharing is not applicable to this article as no datasets were generated or analyzed during the current study.

ORCID

Anton Sculean  <https://orcid.org/0000-0003-2836-5477>

REFERENCES

- Buser D, Sennerby L, De Bruyn H. Modern implant dentistry based on osseointegration: 50 years of progress, current trends and open questions. *Periodontol 2000*. 2017;73:7-21.
- Howe MS, Keys W, Richards D. Long-term (10-year) dental implant survival: A systematic review and sensitivity meta-analysis. *J Dent*. 2019;84:9-21.
- Elani HW, Starr JR, Da Silva JD, Gallucci GO. Trends in dental implant use in the U.S., 1999-2016, and projections to 2026. *J Dent Res*. 2018;97:1424-1430.
- Buser D, Chen S. Factors influencing the treatment outcomes of implants in post-extraction sites. In: Buser D, Wismeijer D, Belser U, eds. *ITI Treatment Guide Volume 3: Implant placement in postextraction sites - treatment options*. Quintessence Publishing; 2008:18-28.
- Renouard F, Amalberti R, Renouard E. Are "human factors" the primary cause of complications in the field of implant dentistry? *Int J Oral Maxillofac Implants*. 2017;32:e55-e61.
- Belser UC, Bernard JP, Buser D. Implant-supported restorations in the anterior region: prosthetic considerations. *Pract Periodontics Aesthet Dent*. 1996;8:875-883. quiz 884.
- Garber DA, Belser UC. Restoration-driven implant placement with restoration-generated site development. *Compend Contin Educ Dent*. 1995;16:796 798-802, 804.
- Romandini M, Pedrinaci I, Lima C, Soldini MC, Araoz A, Sanz M. Prevalence and risk/protective indicators of buccal soft tissue dehiscence around dental implants. *J Clin Periodontol*. 2021;48:455-463.
- Chen ST, Buser D. Esthetic complications due to implant malpositions: etiology, prevention, and treatment. In: Froum SJ, ed. *Dental implant complications: etiology, prevention, and treatment*. Wiley-Blackwell; 2010:134-155.
- Cavallaro J Jr, Greenstein G. Prosthodontics complications related to non-optimal dental implant placement. In: Froum SJ, ed. *Dental implant complications Etiology, prevention, and treatment*. John Wiley & Sons; 2010:156-171.
- Buser D, Martin W, Belser UC. Optimizing esthetics for implant restorations in the anterior maxilla: anatomic and surgical considerations. *Int J Oral Maxillofac Implants*. 2004;19(Suppl):43-61.
- Esposito M, Ekstubbé A, Grondahl K. Radiological evaluation of marginal bone loss at tooth surfaces facing single Branemark implants. *Clin Oral Implants Res*. 1993;4:151-157.
- Tarnow DP, Cho SC, Wallace SS. The effect of inter-implant distance on the height of inter-implant bone crest. *J Periodontol*. 2000;71:546-549.
- Jemt T, Albrektsson T. Do long-term followed-up Branemark implants commonly show evidence of pathological bone breakdown? A review based on recently published data. *Periodontology 2000*. 2008;47:133-142.
- Schropp L, Isidor F. Papilla dimension and soft tissue level after early vs. delayed placement of single-tooth implants: 10-year results from a randomized controlled clinical trial. *Clin Oral Implants Res*. 2015;26:278-286.
- Heitz-Mayfield LJ, Darby I, Heitz F, Chen S. Preservation of crestal bone by implant design. A comparative study in minipigs. *Clin Oral Implants Res*. 2013;24:243-249.
- Vela X, Mendez V, Rodriguez X, Segala M, Tarnow DP. Crestal bone changes on platform-switched implants and adjacent teeth when the tooth-implant distance is less than 1.5 mm. *Int J Periodontics Restorative Dent*. 2012;32:149-155.
- Tarnow D, Elian N, Fletcher P, et al. Vertical distance from the crest of bone to the height of the interproximal papilla between adjacent implants. *J Periodontol*. 2003;74:1785-1788.
- Kan JY, Rungcharassaeng K, Umezu K, Kois JC. Dimensions of peri-implant mucosa: an evaluation of maxillary anterior single implants in humans. *J Periodontol*. 2003;74:557-562.
- Elian N, Bloom M, Dard M, Cho SC, Trushkowsky RD, Tarnow D. Effect of interimplant distance (2 and 3 mm) on the height of inter-implant bone crest: a histomorphometric evaluation. *J Periodontol*. 2011;82:1749-1756.
- Nevins M, Nevins M, Gobbato L, Lee HJ, Wang CW, Kim DM. Maintaining interimplant crestal bone height via a combined platform-switched, Laser-Lok implant/abutment system: a

- proof-of-principle canine study. *Int J Periodontics Restorative Dent.* 2013;33:261-267.
22. Cosyn J, Sabzevar MM, De Bruyn H. Predictors of inter-proximal and midfacial recession following single implant treatment in the anterior maxilla: a multivariate analysis. *J Clin Periodontol.* 2012;39:895-903.
 23. Evans CJD, Chen ST. Esthetic outcomes of immediate implant placements. *Clin Oral Implants Res.* 2008;19:73-80.
 24. Cosyn J, Eghbali A, Hermans A, Vervaeke S, De Bruyn H, Cleymaet R. A 5-year prospective study on single immediate implants in the aesthetic zone. *J Clin Periodontol.* 2016;43:702-709.
 25. Chen ST, Darby IB, Reynolds EC. A prospective clinical study of non-submerged immediate implants: clinical outcomes and esthetic results. *Clin Oral Implants Res.* 2007;18:552-562.
 26. Martin W, Chappuis V, Morton D, Buser R. Preoperative risk assessment and treatment planning for optimal esthetic outcomes. In: Chappuis V, Martin W, eds. *ITI Treatment Guide, Volume 10: Implant therapy in the esthetic zone.* Quintessence Publishing; 2017:23-56.
 27. Buser D, Chappuis V, Belser UC, Chen S. Implant placement post extraction in esthetic single tooth sites: when immediate, when early, when late? *Periodontol 2000.* 2017;73:84-102.
 28. Araujo MG, Lindhe J. Dimensional ridge alterations following tooth extraction. An experimental study in the dog. *J Clin Periodontol.* 2005;32:212-218.
 29. Chen ST, Darby I. The relationship between facial bone wall defects and dimensional alterations of the ridge following flapless tooth extraction in the anterior maxilla. *Clin Oral Implants Res.* 2017;28:931-937.
 30. Vera C, De Kok IJ, Chen W, Reside G, Tyndall D, Cooper LF. Evaluation of post-implant buccal bone resorption using cone beam computed tomography: a clinical pilot study. *Int J Oral Maxillofac Implants.* 2012;27:1249-1257.
 31. Chappuis V, Engel O, Reyes M, Shahim K, Nolte LP, Buser D. Ridge alterations post-extraction in the esthetic zone: a 3D analysis with CBCT. *J Dent Res.* 2013;92:1955-2015.
 32. Cosyn J, Cleymaet R, De Bruyn H. Predictors of alveolar process remodeling following ridge preservation in high-risk patients. *Clin Implant Dent Relat Res.* 2016;18:226-233.
 33. Windael S, Collaert B, De Buyser S, De Bruyn H, Vervaeke S. Early peri-implant bone loss as a predictor for peri-implantitis: A 10-year prospective cohort study. *Clin Implant Dent Relat Res.* 2021;23:298-308.
 34. Januario AL, Duarte WR, Barriviera M, Mesti JC, Araujo MG, Lindhe J. Dimension of the facial bone wall in the anterior maxilla: a cone-beam computed tomography study. *Clin Oral Implants Res.* 2011;22:1168-1171.
 35. Braut V, Bornstein MM, Belser U, Buser D. Thickness of the anterior maxillary facial bone wall—a retrospective radiographic study using cone beam computed tomography. *Int J Periodontics Restorative Dent.* 2011;31:125-131.
 36. Buser D, Monje A, Urban I. Anatomical and surgical factors influencing the outcome of GBR procedures. In: Buser D, ed. *30 years of guided bone regeneration.* Quintessence Publishing Co, Inc; 2021:93-122.
 37. Morton D, Chen ST, Martin WC, Levine RA, Buser D. Consensus statements and recommended clinical procedures regarding optimizing esthetic outcomes in implant dentistry. *Int J Oral Maxillofac Implants.* 2014;29(Suppl):216-220.
 38. Morton D, Gallucci G, Lin WS, et al. Group 2 ITI Consensus Report: Prosthodontics and implant dentistry. *Clin Oral Implants Res.* 2018;29(Suppl 16):215-223.
 39. von Arx T, Buser D. Horizontal ridge augmentation using autogenous block grafts and the guided bone regeneration technique with collagen membranes: a clinical study with 42 patients. *Clin Oral Implants Res.* 2006;17:359-366.
 40. Urban I. Chapter 11. Horizontal ridge augmentation: the sausage technique. *Vertical and horizontal ridge augmentation: new perspectives.* Quintessence Publishing Co.; 2017:117-146.
 41. Burkhardt R, Joss A, Lang NP. Soft tissue dehiscence coverage around endosseous implants: a prospective cohort study. *Clin Oral Implants Res.* 2008;19:451-457.
 42. Zucchelli G, Tavelli L, Stefanini M, et al. Classification of facial peri-implant soft tissue dehiscence/deficiencies at single implant sites in the esthetic zone. *J Periodontol.* 2019;90:1116-1124.
 43. Rocuzzo M, Dalmasso P, Pittoni D, Rocuzzo A. Treatment of buccal soft tissue dehiscence around single implant: 5-year results from a prospective study. *Clin Oral Investig.* 2019;23:1977-1983.
 44. Tarnow DP, Chu SJ. When to save or remove implants in the smile zone: a clinical report of maxillary lateral incisor implants in malposition. *J Esthet Restor Dent.* 2021;33:194-201.

How to cite this article: Chen ST, Buser D, Sculean A, Belser UC. Complications and treatment errors in implant positioning in the aesthetic zone: Diagnosis and possible solutions. *Periodontol 2000.* 2023;00:1-15. doi: [10.1111/prd.12474](https://doi.org/10.1111/prd.12474)