

## PUBLISHED VERSION

Junji Chen, Ziwei Zeng, Liang Huang, Shuangling Luo, Jianghui Dong, Fiona H Zhou, Kun Zhou, Liping Wang, Liang Kang

### Photothermal therapy technology of metastatic colorectal cancer

American Journal of Translational Research, 2020; 12(7):3089-3115

Copyright © 2020 e-Century Publishing Corporation. Once the paper is published, the copyright will be released by the publisher under the “Creative Commons Attribution Noncommercial License”, enabling the unrestricted non-commercial use, distribution, and reproduction of the published article in any medium, provided that the original work is properly cited. If the manuscript contains a figure or table reproduced from a book or another journal article, the authors should obtain permission from the copyright holder before submitting the manuscript, and be fully responsible for any legal and/or financial consequences if such permissions are not obtained.

Published version [https://e-century.us/web/journal\\_toc.php?journal=ajtr&volume=12&number=7](https://e-century.us/web/journal_toc.php?journal=ajtr&volume=12&number=7)

#### PERMISSIONS

<http://creativecommons.org/licenses/by-nc/4.0/>



### Attribution-NonCommercial 4.0 International (CC BY-NC 4.0)

This is a human-readable summary of (and not a substitute for) the [license](#). [Disclaimer](#).

#### You are free to:

- Share** — copy and redistribute the material in any medium or format
- Adapt** — remix, transform, and build upon the material

The licensor cannot revoke these freedoms as long as you follow the license terms.

#### Under the following terms:



**Attribution** — You must give [appropriate credit](#), provide a link to the license, and [indicate if changes were made](#). You may do so in any reasonable manner, but not in any way that suggests the licensor endorses you or your use.



**NonCommercial** — You may not use the material for [commercial purposes](#).

**No additional restrictions** — You may not apply legal terms or [technological measures](#) that legally restrict others from doing anything the license permits.

4 April 2022

<http://hdl.handle.net/2440/134747>

## Review Article

# Photothermal therapy technology of metastatic colorectal cancer

Junji Chen<sup>1,2</sup>, Ziwei Zeng<sup>1,2</sup>, Liang Huang<sup>1,2</sup>, Shuangling Luo<sup>1,2</sup>, Jianghui Dong<sup>3</sup>, Fiona H Zhou<sup>4</sup>, Kun Zhou<sup>3</sup>, Liping Wang<sup>3</sup>, Liang Kang<sup>1,2</sup>

<sup>1</sup>Department of Colorectal Surgery, Guangdong Provincial Key Laboratory of Colorectal and Pelvic Floor Diseases, The Sixth Affiliated Hospital of Sun Yat-Sen University, Guangzhou 510655, Guangdong, China; <sup>2</sup>Guangdong Institute of Gastroenterology, The Sixth Affiliated Hospital of Sun Yat-Sen University, Guangzhou 510655, Guangdong, China; <sup>3</sup>UniSA Clinical and Health Sciences, and UniSA Cancer Research Institute, University of South Australia, Adelaide, SA 5001, Australia; <sup>4</sup>School of Medicine, University of Adelaide, Adelaide, SA 5000, Australia

Received February 3, 2020; Accepted April 17, 2020; Epub July 15, 2020; Published July 30, 2020

**Abstract:** Colorectal cancer (CRC) is one of the most common malignancies. The current treatments of metastatic colorectal cancer (mCRC) are ineffective and the bottleneck problem. It is of significance to explore effective new therapeutic strategies to eradicate mCRC. Photothermal therapy (PTT) is an emerging technology for tumor therapy, with the potential in the treatment of mCRC. In this review, the current treatment approaches to mCRC including surgery, radiotherapy, chemotherapy interventional therapy, biotherapy, and photothermal therapy are reviewed. In addition, we will focus on the various kinds of nanomaterials used in PTT for the treatment of CRC both in vitro and in vivo models. In conclusion, we will summarize the combined application of PTT with other theranostic methods, and propose future research directions of PTT in the treatment of CRC.

**Keywords:** Mucinous adenocarcinoma, colorectal carcinoma, photothermal therapy, colorectal cancer

### Introduction

The morbidity and mortality rate of colorectal cancer (CRC) ranked third in males and second in females, is high [1]. As the age of the average population increased, accompanied by environmental factors such as poor diet, smoking, low physical activity, and obesity, the incidence in CRC has increased rapidly since the 1950s [2, 3]. In recent years, with the development of medicine and the application of tumor screening, the rate of CRC in the elderly has gradually reduced. On the other hand, the incidence of CRC in the younger population under 50 years of age has increased significantly [4]. This is because people generally would not screen if there was not a family history, leading to an advanced and less treatable form of CRC [5].

The treatment of patients with mCRC is one of the bottleneck problems. Distant metastases of CRC often occur first in the liver, the lung, and the peritoneum, followed by rarer distant metastases in the brain, the bone, and the ret-

roperitoneal lymph nodes [6]. The liver is the most common site of CRC metastases, because about 30% of mCRC patients have liver metastases and 50% of patients with liver metastases also have other metastases during the disease [7]. Lung metastasis is the second most common form of colorectal cancer metastases, occurring in about 11% of CRC patients [8, 9]. Lung metastasis from rectal cancer is more common than from colon cancer, because rectal cancer could spread directly to the systemic circulation via the internal iliac veins without passing through the portal vein [10]. Peritoneal metastasis occurs in about 4-13% of CRC patients [11, 12], which was once considered a form of systemic distant metastases and a terminal state with poor prognosis [13]. At present, the treatment pattern of early and progressive CRC is a comprehensive treatment consisting of surgery, radiotherapy, and chemotherapy. This comprehensive treatment resulted in a significant increase in 5-year survival rate of 71% in the early stage and 41% in the progressive stage [6]. However, the 5-year sur-

vival rate of patients with advanced colorectal cancer, namely metastatic CRC (mCRC), even after surgery, radiotherapy, chemotherapy, and other treatments is only 14% [6]. Therefore, exploring effective new treatment strategies is considerable for the treatment of mCRC.

This article reviews the current status of treatment of mCRC, including surgery, radiotherapy, chemotherapy, interventional therapy, biotherapy, and photothermal therapy. In addition, various photothermal conversion materials for CRC treatment using cellular and animal models, and the combination of PTT with other therapeutic methods are evaluated.

### Canonical treatment of mCRC

Currently, the main treatment methods of mCRC include: surgery [14-16]; radiotherapy [17, 18]; chemotherapy [19-22]; biotherapy [23-31] and interventional therapy [32]. Depending on the severity of the disease, mCRC can be divided into two categories, oligometastatic CRC (localized mCRC) and extensive mCRC. Oligometastatic CRC is characterized by a disease state with less than 2 metastatic sites and 5 metastatic tumors. However, when the metastatic sites and numbers are over 2 and 5, respectively, mCRC is more severe and referred to as extensive mCRC. The goal for treating oligometastatic CRC is to achieve complete resection and tumor-free status by surgery or radiotherapy, while the goal for treating extensive mCRC is to achieve disease control through chemotherapy and biotherapy, as well as symptom relief. **Table 1** compares the indications, complications, and outcomes of the current mCRC treatment methods.

#### *Surgical treatment*

Surgical treatment of mCRC refers to the simultaneous removal of primary and metastatic lesions. Primary resection mainly includes radical resection (R0 resection, no residual tumor cells under the microscope after resection) and palliative resection. The main methods include partial hepatectomy, partial pneumonectomy, and cytoreductive surgery combined with hyperthermic intraperitoneal chemotherapy (CRS-HIPEC) and retroperitoneal lymphadenectomy.

The liver is the most common metastatic site of CRC, so liver metastasis is the most critical in the treatment of mCRC. For OMD with Colorectal liver metastasis (CLM), the surgical method is primary resection and partial hepatectomy. For OMD CRC patients with liver metastasis, the 5-year survival rate of these patients after local resection was about 30%, which increased up to 50% when combined local resection with postoperative adjuvant chemotherapy (**Table 1**) [14, 33]. The disadvantage of partial hepatectomy is its limited application, for only 20% of patients with liver metastases could be removed surgically [33]. Reasons for inoperable treatment include unresectable extrahepatic disease, the cancerous liver involved is more than 70%, liver failure, and intolerance to surgery [14]. Researches show that 70% of CRC patients undergone partial hepatectomy experience tumor recurrence within 3 years [32, 34].

Surgical treatment for patients with lung metastasis involves partial pneumonectomy. The indications for surgical treatment include feasible complete resection, control of the primary tumor, and surgery tolerance [35]. The 5-year survival rate of patients after partial pneumonectomy is 25%-35% [48, 49]. This application is limited, since lung metastases are rarely isolated. Single lung metastasis account for only 1.7-7.2% of all mCRC patients with lung metastases [50]. It is expected that patients with mCRC who have undergone partial pneumonectomy would have received partial hepatectomy as well [51]. In addition, the recurrence rate after partial pneumonectomy is high with 80% of patients relapsing within 2 years [50, 52].

Peritoneal metastasis is the second most common site of CRC metastasis, which usually cannot be completely removed surgically [15]. However, the metastatic foci of CRC peritoneal metastasis do not usually occur in a single site of the peritoneum, but spread to the adjacent peritoneum to form a diffuse distribution [13], so local resection cannot completely remove the peritoneal metastasis. Currently, the clinical treatment for peritoneal mCRC is cytoreductive surgery (CRS) combined with hyperthermic intraperitoneal chemotherapy (HIPEC) [53], namely CRS-HIPEC. CRS involves in the resection of all visible lesions, followed by HIPEC, through which chemotherapy drugs at

## Photothermal therapy for metastatic CRC

**Table 1.** Treatment of mCRC

Category	Program	Indications	Complications	Efficacy	Ref.
Surgical treatment (Primary resection +)	Partial hepatectomy	Except for unresectable extrahepatic disease, tumor involvement over 70% of liver, liver failure and intolerance to surgery	Liver failure, postoperative bleeding, heart failure, systemic sepsis	The 5-year survival rate in patients with surgery combined with chemotherapy is 50%	[14, 33, 34]
	Partial pneumonectomy	Feasible complete resection, control of the primary tumor	Respiratory secretion retention, atelectasis, bronchopleural fistula	The 5-year survival rate is 25% to 35%	[8, 35, 36]
	CRS+HIPEC	Well/moderately differentiation without extraperitoneal metastasis	Anastomotic fistula, bleeding, wound infection, neutropenia	The 5-year survival rate is 31%	[15, 37]
Radiotherapy	Traditional radiotherapy	A palliative treatment for extensive mCRC	Radiation damage	Local symptom remission	[17, 18]
	SBRT	Oligometastatic CRC	Radiation hepatitis/pneumonia/enteritis	Improvement of local control rate	[17, 18]
Chemotherapy	FOLFIRI	A palliative/conversion/adjuvant therapy for mCRC	Febrile neutropenia, nausea, vomiting	The median OS is 16.2 months	[19, 38]
	FOLFOX	A palliative/conversion/adjuvant therapy for mCRC	Neutropenia, low platelet count, peripheral neuropathy	The median OS is 19.5 months	[20, 34]
	CapeOX	A palliative/conversion/adjuvant therapy for mCRC	Diarrhea, hand-foot syndrome, peripheral neuropathy	The median OS is 16.3 months	[21, 39]
	FOLFOXIRI	A palliative/conversion/adjuvant therapy for mCRC	Neutropenia, diarrhea, nausea, vomiting, peripheral neurotoxicity	The median OS is 19.6 months	[22, 40]
Interventional therapy	Radiofrequency ablation, cryoablation or microwave ablation	A palliative/conversion/adjuvant therapy for mCRC	Local recurrence, low fever, abdominal pain, muscle pain, nausea, vomiting, liver damage	Improvement of progression-free survival	[41, 42]
	Chemical/radiotherapy pharmaceuticals embolization or topical use of chemotherapy pharmaceuticals	Extensive mCRC insensitive to canonical chemotherapeutics	Local recurrence, nausea, vomiting, diarrhea, liver function damage	Improvement of progression-free survival	[43]
Biotherapy	EGFR targeting monoclonal antibody	K-ras wild-type patients combined with chemotherapy	Rashes, allergic reactions, and hypomagnesemia	Improvement of progression-free survival	[44-46]
	VEGF targeting monoclonal antibody	Combination with chemotherapy	Hypertension, proteinuria, thromboembolism	Improvement of progression-free survival	[25, 46]
	Immunity inhibitors	dMMR/MSI-H patients	Lipase concentration and amylase concentration increased	Improvement of progression-free survival	[29-31]

## Photothermal therapy for metastatic CRC

42-43°C are intraperitoneally injected during or straight after the operation [13]. CRS-HIPEC has been shown to effectively remove residual lesions in the abdominal cavity and prolong the survival time of patients with peritoneal metastasis through the combination of thermal effect and chemotherapeutics [15]. Since chemotherapeutic drugs need to be distributed uniformly throughout the abdominal cavity to kill the metastases instead of therapeutic targeting just one region, this will inevitably lead to damage of the normal surrounding tissue [54]. CRS-HIPEC has a couple of disadvantages: 1) CRS is complicated with long operation time of up to 8-10 h, making the process difficult to be tolerated by patients; and 2) The incidence of post-operative complications is very high, with the main complication rate of 12%-52%. The common complications are intestinal obstruction, abscess, hematologic toxicity, fistula, and septicemia [55].

Isolated retroperitoneal lymph node metastases usually recur after radical resection of CRC, accounting for about 1% of all CRC patients. After retroperitoneal lymphadenectomy, the median survival time is 31 months, with an overall five-year survival rate of 15%, compared with the median survival time of 3 months in the unresected patients [56]. However, the retroperitoneal lymphadenectomy is only limited to some cases. It is not appropriate when the metastases invade major blood vessels (such as superior mesenteric artery, abdominal axis, and aorta) and organs (such as the pancreas, bile ducts, and duodenum) or in patients intolerant to surgery.

### *Radiotherapy*

The radiotherapy for the treatment of mCRC includes traditional radiotherapy and stereotactic body radiotherapy (SBRT). Traditional radiotherapy has a limited effect in extracranial malignant tumors due to natural body movement and low radiation tolerance by the normal surrounding tissue. Consequently, traditional radiotherapy is only used for local symptom relief as a palliative treatment. SBRT, on the other hand, can be used for the local treatment of patients with oligometastatic CRC to achieve a tumor-free status [17]. SBRT along with the use of low-fraction radiation can deliver high-dose radiation to the target area, while normal

tissues receive only low doses of radiation. In addition, the high dose radiation from SBRT provides additional anti-tumor effects, including direct cytotoxicity and microvascular damage in the target tumor tissue [18].

SBRT can be used for inoperable patients with oligometastatic CRC. In 2014, it was reported, the 2-year local control rate after SBRT against liver metastases is about 80%, and the 2-year survival rate was 32%-83%. The 2-year local control rate after SBRT against lung metastases was about 80% and the 2-year overall survival rate was 33%-86%. As for retroperitoneal lymph node metastases, the overall 3-year survival rate of patients with SBRT treatment was reported at 71% [18]. SBRT was reported to cause some complications including radioactive hepatitis, pneumonia, and enteritis. Currently, the efficacy study of SBRT to treat mCRC is limited to a small sample size. The optimum dose, indication, and validity of SBRT are still to be defined.

### *Chemotherapy*

Chemotherapy can be applied as extensive mCRC palliative care, as well as conversion therapy for potentially resectable mCRC and adjuvant therapy for resectable mCRC. First-line chemotherapy can increase the median overall survival of patients with extensive mCRC to 12-20 months [19-22]. To date, the main CRC chemotherapy regimens include: FOLFIRI (calcium folinate, fluorouracil and irinotecan) [19]; FOLFOX (calcium folinate, fluorouracil and oxaliplatin) [20]; CapeOX (capecitabine and oxaliplatin) [21]; FOLFOXIRI (calcium folinate, fluorouracil, irinotecan and oxaliplatin) [22].

Chemotherapy is also used as a conversion therapy for unresectable mCRC and an adjuvant therapy for resectable mCRC. Conversion therapy can be used to improve disease status of unresectable metastases, and transform them into resectable lesions [57, 58]. A report showed that 10% to 30% of patients with unresectable liver metastases became resectable after chemotherapy [59]. As for resectable mCRC, preoperative neoadjuvant chemotherapy is used to help determine the tumor response to chemotherapy. Thus, it also determines the optimal postoperative chemotherapy regimen. Preoperative neoadjuvant chemotherapy was also able to aid in identifying the patients not

suitable for surgery due to the particular invasiveness of the tumor [60]. In addition, it has been shown that adjuvant chemotherapy after surgery for resectable mCRC improves the prognosis, where the 5-year RFS and OS rates (27% and 67%, respectively) of the patients receiving adjuvant chemotherapy are higher compared to those of the patients not receiving adjuvant chemotherapy after surgery (14% and 46%, respectively) [61].

Due to the poor selectivity of chemotherapeutic drugs used, treatments often come with serious systemic side effects. In patients, FOLFIRI has been shown to often cause mucous membrane inflammation, nausea, vomiting, and hair loss, while FOLFOX often causes neutropenia and neurosensory toxicity [62]. In addition, chemotherapy is not effective to treat all mCRC after surgery. Previous studies showed the use of chemotherapy after removal of peritoneal metastases did not result in obvious improvement in prognosis, and its overall survival rate was significantly lower than that of other organ metastases [63, 64]. The main reason was that the concentration of intravenous chemotherapy drugs can be diluted significantly after penetrating through the peritoneal-plasma barrier, which meant the effective drug concentration in the peritoneal cavity cannot be achieved [65].

### *Interventional therapy*

Interventional therapy of mCRC mainly includes ablation of energy devices (radiofrequency ablation, cryoablation, microwave ablation), embolization of interventional (chemotherapy or radiotherapy drugs), and local application of chemical drugs [43, 66]. The treatment of hepatic metastasis of CRC remains the most common and important point in mCRC therapy, and surgery is the preferred treatment. A 10-year (1992-2002) clinical study enrolled 418 patients with CLM, assigned different treatment to them, and found that the total recurrence rate of ablation alone group was significantly higher than that of surgery combined with ablation group and surgery alone group for colorectal cancer with liver metastasis (84% vs 64% vs 52%) [67]. After follow-up for 4 years, the overall survival rate was 22% in the ablation alone group, 36% in the surgical combined ablation group, and 65% in the surgery alone group. The overall survival rate in the 5-year

follow-up group was still 58% [67]. However, there are still a large number of patients with CLM who cannot remove the lesion completely. Therefore, the use of interventional therapy (such as ablation, interventional embolization, and local injection of chemicals) is of great significance for eliminating tumor lesions and improving PFS and OS in CLM patients. A phase II clinical trial (EORTC 40004) enrolled 119 patients with mCRC that cannot be resected completely, through comparing the efficacy of radiofrequency ablation + systemic chemotherapy and systemic chemotherapy, concluded that radiofrequency ablation combined with chemotherapy than simple chemotherapy significantly improves the OS and PFS. To radiofrequency ablation combined with systemic chemotherapy, the 3-year survival rate was 27.6%, the median progression-free survival was 16.8 months, and to systemic chemotherapy group, the 3-year survival rate was 10.6%, the median survival was 9.9 months [68]. In the latest guidelines of the European cancer society (ESMO), the significance of ablative therapy in the treatment of oligometastatic mCRC is again emphasized. The treatment of oligometastatic mCRC needs to be determined based on multidisciplinary discussions. Treatment options include R0 surgical resection, radiofrequency ablation, and interventional embolization [32].

### *Biotherapy*

In recent years, the application of biotherapy in the treatment of cancer is a growing interest in cancer research. The main biotherapeutic agents used against mCRC include targeting drugs for CRC biomarkers and immunosuppressants for immune checkpoints [29-31]. However, biotherapy alone improves patients' survival time limitedly, therefore, it's usually used in combination with chemotherapy [69, 70]. Along with chemotherapy, biotherapy was often used as palliative therapy for extensive mCRC and conversion therapy or adjuvant therapy in resectable mCRC [60, 71].

Targeting biotherapy drugs used for mCRC treatment include monoclonal antibody for epidermal growth factor receptor (EGFR) and vascular endothelial growth factor (VEGF) [23-28]. EGFR targeting drugs include cetuximab (EGFR monoclonal antibody) and paracetamol. The overall survival time of patients with K-ras wild-type mCRC treated with cetuximab was 9.5

## Photothermal therapy for metastatic CRC

months, which almost doubled compared to 4.8 months for patients with supportive care alone [28]. In addition, cetuximab in combination with chemotherapy regimens such as FOLFOX and FOLFIRI reduced the risk of progression in K-ras wild type mCRC patients [44, 45]. Unfortunately, cetuximab can only use for wild-type K-ras patients, since it was shown to not be beneficial in treating K-ras mutant patients [28, 44].

VEGF targeted monoclonal antibody includes bevacizumab. Several studies have shown that the combination of bevacizumab and chemotherapy regimens prolongs the survival of patients with mCRC [23-25]. However, a study in 2015 found that the VEGF monoclonal antibody combined with the current first-line chemotherapy regimen of FOLFIRI and FOLFOX did not increase progression-free survival and the overall survival in patients with mCRC [23]. Thus, the efficacy of such therapies is still controversial.

The prevailing immunity inhibitors of programmed cell death protein-1 (PD-1) and Cytotoxic T lymphocyte-associated protein-4 (CTLA-4) are effective in the treatment of mismatch repair deficient/microsatellite instability-high (dMMR/MSI-H) CRC [29, 30]. Patients with mCRC of dMMR/MSI-H are usually not sensitive to chemotherapy, but they will experience a long-term control of the disease after receiving a combination of naloxone (a PD-1 inhibitor) and chemotherapy [31]. Compared with PD-1 inhibitor monotherapy alone, the combination of naltrexone and ipilimumab (a CTLA-4 inhibitor) improves the efficacy in mCRC of dMMR/MSI-H patients with higher progression-free survival and overall survival [30]. However, the application of immunity inhibitors has its limitations. First, the incidence of dMMR/MSI-H in the CRC terminal stage was low (about 3%-5%) [72], while whether or not to take immunity inhibitors depends on the type of tumor. Second, the efficacy of PD-1 inhibitors in patients with mismatch repair proficient/microsatellite instability-low (pMMR/MSI-L) or normal mismatch repair proficient/microsatellite stability (pMMR/MSS) was poor [29]. In addition, the combination therapy of PD-1 inhibitor and CTLA-4 inhibitor was beneficial only in a small number of pMMR/MSI-L patients [30].

In summary, there are some limitations in the traditional surgical treatment of mCRC, such as

surgical trauma, side effects, and drug resistance. Surgical treatment is only limited to patients with resectable metastasis [15, 33, 35]. This method also leads to a higher rate of postoperative recurrence or complication [52, 54, 73]. SBRT, on the other hand, can be used for inoperable patients with oligometastatic CRC. However, indications for radiotherapy are limited, and the optimal dose and efficacy remain unknown [17, 18]. Although chemotherapy showed some effectiveness in improving the disease status of mCRC and converting an unresectable tumor into an operative lesion, its disadvantages and limitations include poor selectivity, poor efficacy, and more systemic adverse reactions [19-22, 62]. Biotherapy, a relatively new concept, is often used in combination with chemotherapy and is only limited in treating a specific set of mCRC cohort [28, 44, 69, 70]. There are levels of trauma and often major side effects associated with the current mCRC treatments available. Therefore, it is desirable to exploit new therapeutic strategies with low trauma and fewer side effects in the treatment of mCRC.

### *Photothermal therapy (PTT) for CRC*

Photothermal therapy is a new technology of tumor therapy with great potential. The procedure for PTT is concentrating photothermal nano-materials on the tumor tissue by targeting technology, and then illuminating the tumor tissue with a light source. In this way, the light energy from the irradiation with strong tissue penetration is rapidly converted into heat energy utilizing photothermal nanomaterials, and thus killing the tumor cells [74]. Compared to the traditional treatment methods, PTT has significant advantages including higher specificity, lower invasive injury, and less normal tissue damage [75].

### *Photothermal nanomaterials for PTT*

Photothermal nanomaterials are nano-materials with the ability of photothermal conversion, usually using near-infrared radiation (NIR) as the light energy source [74, 76]. Tissue components such as hemoglobin and water have the highest transmittance for NIR, allowing it to penetrate through 10 cm of subcutaneous tissue, 4 cm of skull/brain tissue, or 4 cm of muscle tissue [77, 78]. Under the irradiation of NIR, only the part of the photothermal nanomaterial can produce enough heat to specifically kill the

cancer cells, without damaging the surrounding tissues [79]. The types of photothermal nanomaterials currently under development for the use in CRC PTT include noble metal nanomaterials, carbon-based nanomaterials, metal compounds nanomaterials and organic nanomaterials [80]. **Table 2** summarizes the application, outcomes, and clinical application prospects of various PTT materials with *in vitro* and *in vivo* models.

The noble metal nanomaterials of photothermal nanomaterials for photothermal therapy include gold nanoparticles [81-84], gold nanorods [85-87], gold nanoshells [88, 89], and silver-based or platinum-based nanomaterials [90, 91]. The surface plasmon resonance (SPR) of noble metal nanomaterials is the basis of their photothermal conversion ability [92]. The absorption wavelength and photothermal conversion efficiency of these nanomaterials depend on the SPR effects, adjusted by the size, shape and structure of these nanomaterials [93].

The absorption peak of spherical gold nanoparticles is located within the visible light range. In 2017, Hosseinzadeh et al. demonstrated the use of a gold nanoparticle targeting MUC1 aptamer, with the maximum absorption wavelength of 630 nm which is within visible wavelength range *in vitro* [81]. Although they demonstrated its ability in decreasing the activity and migration of colorectal cancer cells by photothermal effect, the pure gold spherical nanoparticles alone were unsuitable for *in vivo* work due to the absorption peak of visible radiation. Therefore, the gold nanoparticles need to be hybridized to other materials, which will adjust their absorption peak to the near-infrared region making it suitable for PTT [94]. This is demonstrated in a paper showing tail vein injection of a gold-iron oxide hybrid nanoparticle targeting the CRC single-chain antibody A33scFv into the CRC subcutaneous tumor-bearing mice slowed down the growth rate of tumor volume and caused necrosis of tumor tissue after irradiation with NIR (**Figure 1A**) [83]. In addition, the material can be used as a contrast agent for T2-weighted imaging in magnetic resonance (MR) imaging, which can clearly show antigen-expressing tumor cells *in vivo* [83].

The absorption peak of gold nanorods is suitable to be adjusted to the NIR region by adjusting the aspect ratio [95]. Similarly, the method

for adjusting the gold nanoshells is adjusting the size and the thickness [96]. In recent years, there are several studies indicating the potential of nanorod as a tool for PTT against CRC. This is demonstrated in a paper by Parchur et al., where they synthesized gold nanorods coated with Gd<sub>2</sub>O<sub>3</sub>: Ln (Au@Gd<sub>2</sub>O<sub>3</sub>: Ln) [84]. Their results showed that the nanorod injected through the portal vein into CRC liver metastatic cancer-bearing rats (**Figure 1B**) were able to cause tumor tissue necrosis by NIR irradiation, with minimal damage to the normal surrounding liver tissue. Another group showed a PEGylated gold nanorod intravenously injected and activated by NIR irradiation increased the average survival time of the CRC subcutaneous tumor-bearing mice significantly (**Figure 1D**) [86]. As a result, 4/9 of the mice had complete tumor ablation. In addition, a number of *in vitro* experiments also support the anti-tumor effect of the nanorod. Methylene blue loaded gold nanorods with SiO<sub>2</sub> shell (**Figure 1C**) was shown to decrease the activity of CRC cells to 11% after NIR irradiation [85], while FITC and cisplatin loaded chitosan-gold nanorods hybrid nanosphere was also effective in decreasing CRC cell viability [87]. Gold nanoshells have a characteristic of the ability to carry functionalized molecules, thus making it multifunctional. This is shown in the paper describing the simultaneous use of a gold nanoshell carrying superparamagnetic iron oxide nanoparticles in PTT and MR imaging [88]. Moreover, gold half-shell nanoparticles loaded with a chemotherapeutic drug doxorubicin (DOX) could produce both chemotherapy and PTT effects in CRC subcutaneous tumor-bearing mice [89]. Low photostability is the common disadvantage of gold materials. Low photostability can cause structural deformation, and structure deformation is one of the disadvantages in the use of gold materials [97]. This makes the viability and the therapeutic effects of gold materials difficult to control for treatments that require long irradiation time. Further study is required in creating a stable nanomaterial.

Platinum-based and silver-based nanomaterials are also considered for photothermal therapy. PVIII fusion protein modified gold-silver hybrid nanorods (PHNRS, **Figure 1E**) were used in PTT to target against CRC cells. As a result, the cell viability of cancer cells was reduced to 30%, while the control group was above 80% [91]. In addition, FePt-gold hybrid nanoparticles were put into the CRC subcutaneous tumor



## Photothermal therapy for metastatic CRC

**Table 2.** Photothermotherapy for CRC (continued from previous table)

Category	Material	Model	Wavelength and intensity	Application	Outcome	Summarize	Ref.
Noble metal nanomaterials	SN38 conjugated hyaluronic acid gold nanoparticles	HT-29 and SW-480 cells	630 nm; 30 mW 6 min	Combined chemo-PTT	Decreased cell viability and cell migration	excited with visible light; PTT in vitro; Lack of in vivo application value	[81]
	Anti-MG1 conjugated hybrid magnetic gold nanoparticles	CC-531 cells CRC liver metastasis-bearing rats	808 nm; 0.56 W/cm <sup>2</sup> 3 min	PTT, MR imaging	Increased tumor necrosis rate	excited with NIR; PTT; low photostability	[82]
	Immune-targeted gold-iron oxide hybrid nanoparticles	SW-1222 cells subcutaneous tumor-bearing mice	808 nm; 3-5 W/cm <sup>2</sup> 20 min*7 times	PTT, MR imaging	Slowing down of tumor growth, tumor tissue necrosis	excited with NIR; PTT; low photostability	[83]
	Gd2O <sub>3</sub> : Ln coated gold nanorods	CC-531 cells CRC liver metastasis-bearing rats	808 nm; 0.5/0.55 W/cm <sup>2</sup> 3 min	PTT, CT imaging	Large necrotic region in the center of the tumor	excited with NIR; interventional imaging guided chemo-PTT; low photostability	[84]
	Methylene blue loaded gold nanorods with SiO <sub>2</sub> shell	CT-26 cells	780 nm; 1 W/cm <sup>2</sup> 50 min	Combined PTT-PDT	Cell activity dropped to 11%	excited with NIR; PTT; low photostability	[85]
	PEGylated gold nanorods	CT-26 cells subcutaneous tumor-bearing mice	808 nm; 3.5 W/cm <sup>2</sup>	PTT	Increased OS, 4/9 of mice completed ablation	excited with NIR; molecular targeting and magnetic targeting guided chemo-PTT; low photostability	[86]
	FITC/cisplatin loaded chitosan-gold nanorods	LoVo cells	808 nm; 1/2/3 W/cm <sup>2</sup>	chemo-PTT, fluorescence imaging	Decreased cell viability	excited with NIR; chemo-PTT; low photostability	[87]
	MUC-1 aptamer targeted gold coated superparamagnetic iron oxide nanoparticles	HT-29 cells	820 nm; 0.7 W/cm <sup>2</sup> 2 min	PTT, MR imaging	Decreased cell viability	excited with NIR; PTT; low photostability	[88]
	DOX-loaded gold half-shell nanoparticles with anti-DR4 antibody	DLD-1 cells subcutaneous tumor-bearing mice	808 nm; 82 W/cm <sup>2</sup> 10 min	Combined chemo-photothermal therapy	Slowing down of tumor growth, tumor tissue necrosis	excited with NIR; molecular targeting guided chemo-PTT; reduce MDR; low photostability	[89]
	FePt-gold nanoparticles hybrid anisotropic nanostructures	HT-29 cells subcutaneous tumor-bearing mice	808 nm; 0.6 W/cm <sup>2</sup>	PTT, MR/PAI imaging	Completed ablation	excited with NIR; MRI and PAI guided chemo-PTT; cytotoxicity	[90]
Assembled phage fusion proteins modified gold-silver hybrid nanorods	SW-620 cells	808 nm; 4 W/cm <sup>2</sup> 10 min	PTT, fluorescence imaging	Decreased cell viability	excited with NIR; PTT; photostability	[91]	
Carbon-based nanomaterials	Irinotecan loaded hyaluronic acid/polyaspartamide-based double-network nanogels	HCT-116 cells	810 nm; 3×10 <sup>-3</sup> W/mm <sup>3</sup>	chemo-PTT	Decreased cell viability	excited with NIR; chemo-PTT; low photothermal conversion efficiency; cumulative toxicity	[103]
	SN38 conjugated cyclodextrins coated graphene oxide	HT-29 cells	808 nm; 2 W/cm <sup>3</sup>	chemo-PTT	Decreased cell viability	excited with NIR; chemo-PTT; low photothermal conversion efficiency; cumulative toxicity	[104]
	Cetuximab/DOX modified magnetic graphene oxide	CT-26 cells subcutaneous tumor-bearing mice	808 nm; 2.5 W/cm <sup>2</sup>	chemo-PTT, MRI guidance	Completed ablation	excited with NIR; chemo-PTT; dual targeting; low photothermal conversion efficiency; cumulative toxicity	[105]

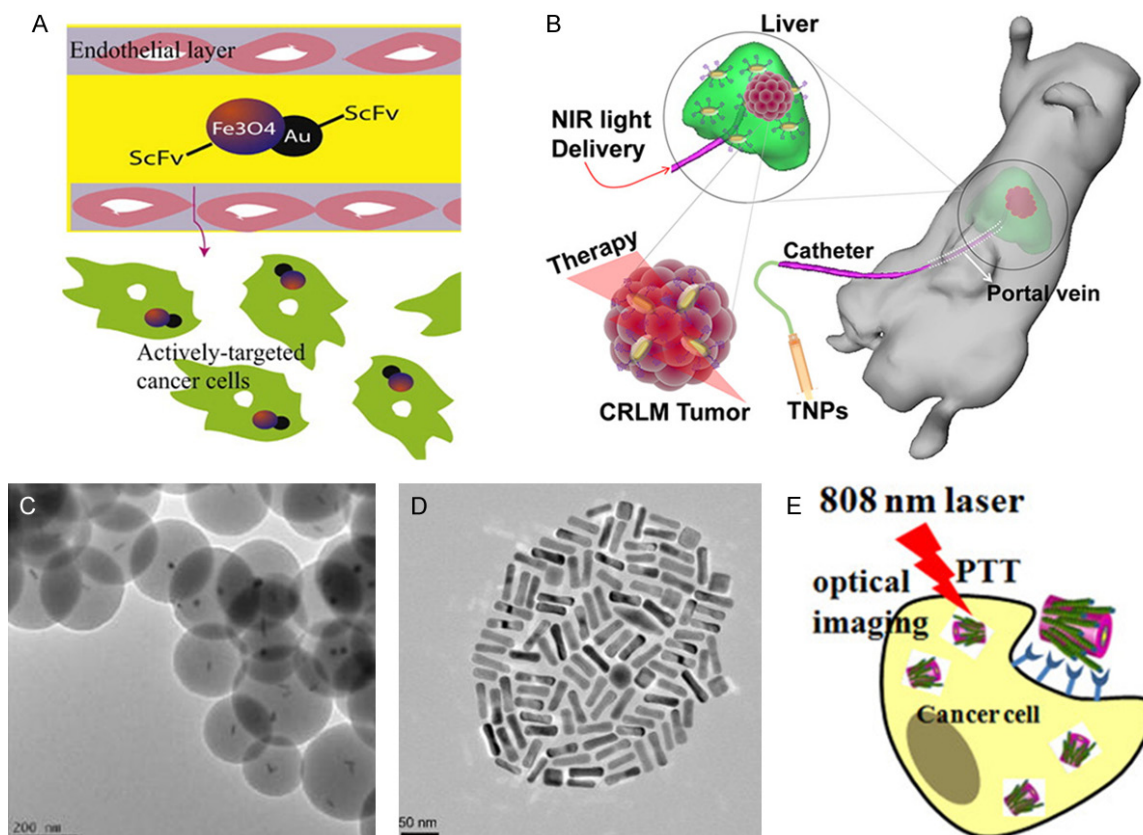
## Photothermal therapy for metastatic CRC

	Folic acid-functionalized multi-walled carbon nanotubes	RKO and HCT-116 cells	1,064 nm; 30 J/cm <sup>2</sup>	PTT	Decreased cell viability	excited with NIR; chemo-PTT; enhanced tumor affinity; low photothermal conversion efficiency; cumulative toxicity	[106]
	Multiwalled carbon nanotubes	RKO and HCT-116 cells	1064 nm; 3 W/cm <sup>2</sup> 10 s	chemo-PTT	Decreased cell viability	excited with NIR; chemo-PTT; enhanced photothermal conversion efficiency; cumulative toxicity	[107]
	POSS-PCU nanocomposite polymer	HT-29 cells	808 nm; 1/0.5 W/cm <sup>2</sup> 10 min	PTT	Decreased cell viability	excited with NIR; chemo-PTT; enhanced biocompatibility and photothermal conversion efficiency	[108]
Metal compounds nanomaterials	copper sulfate nanocomposite materials	Caco-2 cells	808 nm; 1/2/5 W/cm <sup>2</sup>	PTT	Decreased cell viability	excited with NIR; PTT; low photothermal conversion efficiency; cumulative toxicity; inexpensive	[115]
	PEGylated copper nanowires	CT-26 cells subcutaneous tumor-bearing mice	808 nm; 1.5 W/cm <sup>2</sup> 6 min	chemo-PTT	Slowing down of tumor growth, tumor tissue necrosis	excited with NIR; PTT; low photothermal conversion efficiency; cumulative toxicity; inexpensive	[116]
	Amphiphilic polymer coated copper selenide nanocrystals	HCT-116 cells	800 nm; 33 W/cm <sup>2</sup> 5 min	PTT	Necrocytosis	excited with NIR; PTT; inexpensive; moderate photothermal conversion efficiency; cumulative toxicity	[117]
Organic nanomaterial	EGFR targeted micelles loaded with IR-780	HCT-116 and SW-620 cells subcutaneous tumor-bearing mice	780 nm 1.8 W/cm <sup>2</sup>	chemo-PTT	Completed ablation of HCT-116 tumor	excited with NIR; chemo-PTT; biocompatibility and biodegradation; multimodal images; photobleaching	[118]
	IR780 encapsulated nanostructured lipid	CT-26 cells subcutaneous tumor-bearing mice	808 nm; 2 W/cm <sup>2</sup>	PTT	Slowing down of tumor growth, tumor necrosis	excited with NIR; chemo-PTT; biocompatibility and biodegradation; Oral administration; photobleaching	[119]
	Indocyanine green and DOX loaded hyaluronic acid	HCT-116 cells subcutaneous/in situ tumor-bearing mice	808 nm; 1 W/cm <sup>2</sup>	chemo-PTT	inhibition of subcutaneous tumor and in situ tumor	excited with NIR; chemo-PTT; better biocompatibility and biodegradation; controllable drug release; photobleaching	[120]
	Radionuclide rhenium labeled micelles containing Dye IR-780	HCT-116 cells subcutaneous tumor-bearing mice	808 nm; 1.8 W/cm <sup>2</sup>	PTT, SPECT imaging	Slowing down of tumor growth, tumor tissue necrosis	excited with NIR; chemo-PTT; biocompatibility and biodegradation; tissue damage	[121]
	SN38 and dye IR780 loaded nanomicelles	HCT-116 cells subcutaneous tumor-bearing mice	808 nm; 1 W/cm <sup>2</sup>	chemo-PTT	Slowing down of tumor growth, tumor tissue necrosis	excited with NIR; chemo-PTT; biocompatibility and biodegradation; reticuloendothelial system avoidance	[122]
	ADS-780 decorated apoferritin nanoparticles	HT-29 cells subcutaneous tumor-bearing mice	808 nm; 1.2 W/cm <sup>2</sup>	chemo-PTT fluorescence imaging	Slowing down of tumor growth, tumor tissue necrosis	excited with NIR; chemo-PTT; biocompatibility and biodegradation; dual-release mechanisms	[123]
	Platinum-chelated bilirubin nanoparticles	HT-29 cells subcutaneous tumor-bearing mice	808 nm; 1 W/cm <sup>2</sup>	PTT, PAI imaging	Slowing down of tumor growth, tumor tissue necrosis	excited with NIR; chemo-PTT; biocompatibility and biodegradation; PAI; EPR	[135]
	SN-38-encapsulated porphyrin micelles	HT-29 cells subcutaneous tumor-bearing mice	690 nm; 45/90 J/cm <sup>2</sup>	chemo-PTT-PDT	Slowing down of tumor growth, tumor tissue necrosis	excited with NIR; chemo-PTT-PDT; biocompatibility and biodegradation; multimodal images	[124]

## Photothermal therapy for metastatic CRC

Organic nanomaterial	Diketopyrrolopyrrole-triphenylamine organic Nanoparticles	HCT-116 cells subcutaneous tumor-bearing mice	660 nm; 1 W/cm <sup>2</sup>	PTT and PDT, PAI imaging	Completed ablation	excited with NIR; imaging combined with chemo-PTT; better biocompatibility and biodegradation; EPR; PTT-PDT	[125]
	Fe <sup>3+</sup> /vinylpyrrolidone coordination polymer nanoparticles	SW-620 cells subcutaneous tumor-bearing mice	808 nm; 1.3 W/cm <sup>2</sup> 6 min	PTT, MR imaging	Completed ablation	excited with NIR; MRI guided PTT; biocompatibility and biodegradation; tumour-imaging sensitivity; facilitated renal clearance	[127]
	Polydioxanone nanofibers	CT-26 cells	808 nm; 2 W/cm <sup>2</sup> 3 min	chemo-PTT	Decreased cell viability	excited with NIR; chemo-PTT; biocompatibility and biodegradation; multimodal images	[126]
	Polyaniline-coated upconversion nanoparticles	U87MG cells subcutaneous tumor-bearing mice	808 nm; 0.5 W/cm <sup>2</sup>	PTT, fluorescence imaging	Completed ablation	excited with NIR; chemo-PTT; better biocompatibility and biodegradation; multimodal images	[128]
	Polyoxyethylene chain coated polyaniline nanoparticles	HCT-116 cells subcutaneous tumor-bearing mice	808 nm; 0.5 W/cm <sup>2</sup>	PTT	Completed ablation	excited with NIR; chemo-PTT; biocompatibility and biodegradation; photobleaching	[129]
	Conjugated polymer PCP-DTBS <sub>e</sub> nanoparticles	CT-26 cells	450/800 nm; 1.91/3.82 W/cm <sup>2</sup>	PTT	Decreased cell viability	excited with NIR; chemo-PTT; biocompatibility and biodegradation; multimodal images; photobleaching	[130]
Low band gap donor-acceptor conjugated polymer nanoparticles	RKO and HCT-116 cells	808 nm; 600 mW/cm <sup>2</sup>	PTT	Decreased cell viability	excited with NIR; chemo-PTT; biocompatibility and biodegradation; photobleaching; high photothermal efficiency	[131]	

## Photothermal therapy for metastatic CRC



**Figure 1.** Noble metal nanomaterials. A. Gold-iron oxide hybrid nanoparticles [83]; B. Portal vein injection of Au@Gd<sub>2</sub>O<sub>3</sub>:Ln [84]; C. Methylene blue loaded gold nanorods with SiO<sub>2</sub> shell [85]; D. PEGylated gold nanorods [86]; E. schematic diagram showing PHNRS for PTT against CRC SW-620 cells [91].

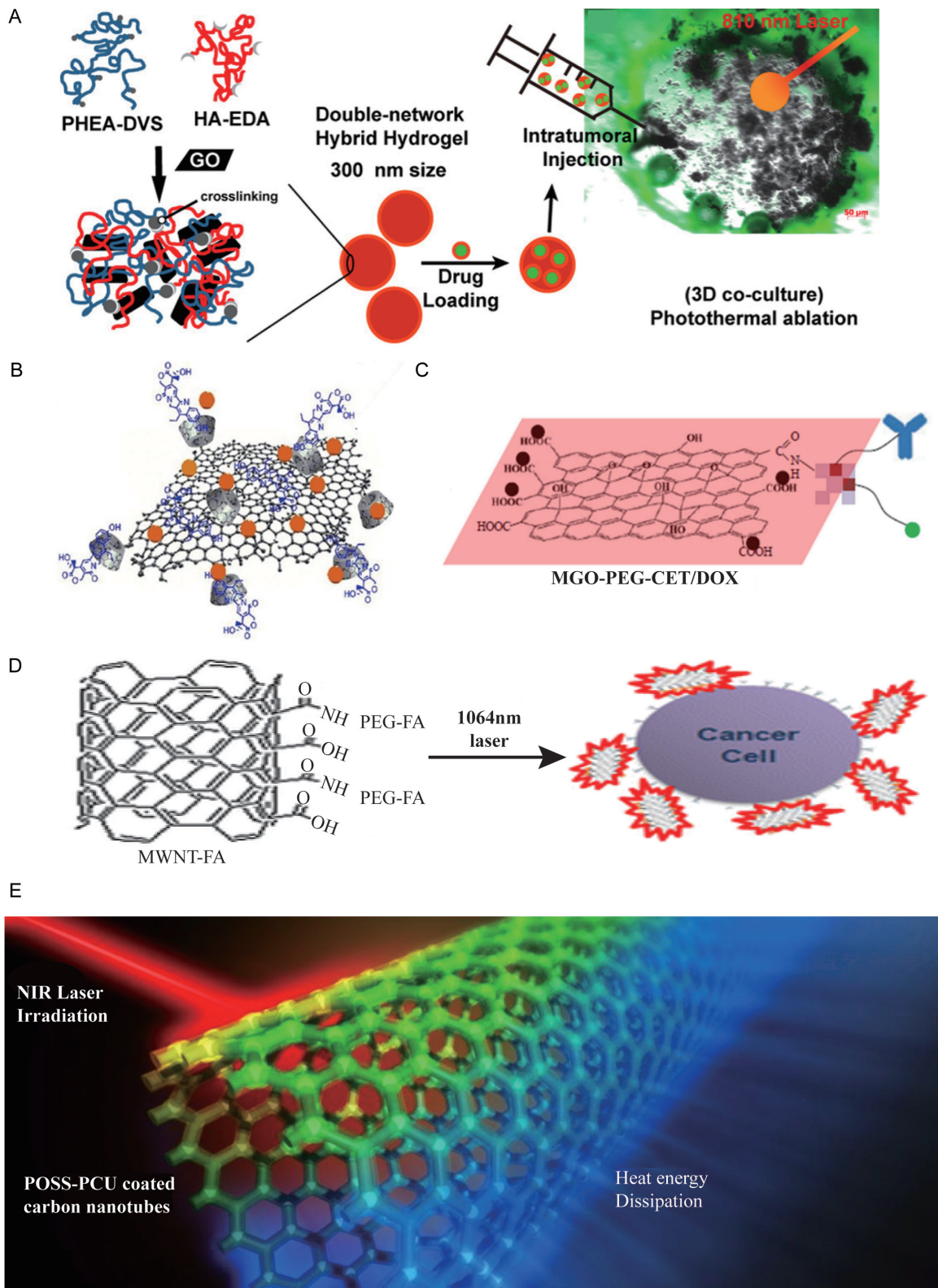
mouse model by intra-tumor injection, causing complete tumor ablation after NIR irradiation [90]. Besides their photothermal conversion properties, platinum nanomaterials have natural anticancer properties including their ability in causing DNA strand breaks and their antioxidant behavior [98, 99], which could be enhanced by appropriate surface modification [100]. The anticancer characteristic of silver nanoparticles is the release of Ag<sup>+</sup> that results in the formation of reactive oxygen species, and further mitochondrial toxicity and DNA damage [100, 101]. Therefore, the cytotoxicity produced by local high concentrations of platinum-based and silver-based nanoparticles form a synergistic effect with photothermal therapy. Unfortunately, both platinum-based and silver-based nanomaterials have disadvantages in causing cytotoxicity to normal cells as well. For platinum-based nanomaterials, the reason is that their ability to cause DNA strand breaks in cells is non-selective, while for silver-based nanomaterials the reason is that they can also be easily oxidized by O<sub>2</sub> or H<sub>2</sub>S in vivo

to produce cytotoxic Ag<sup>+</sup> in surrounding tissue or in blood circulation [102].

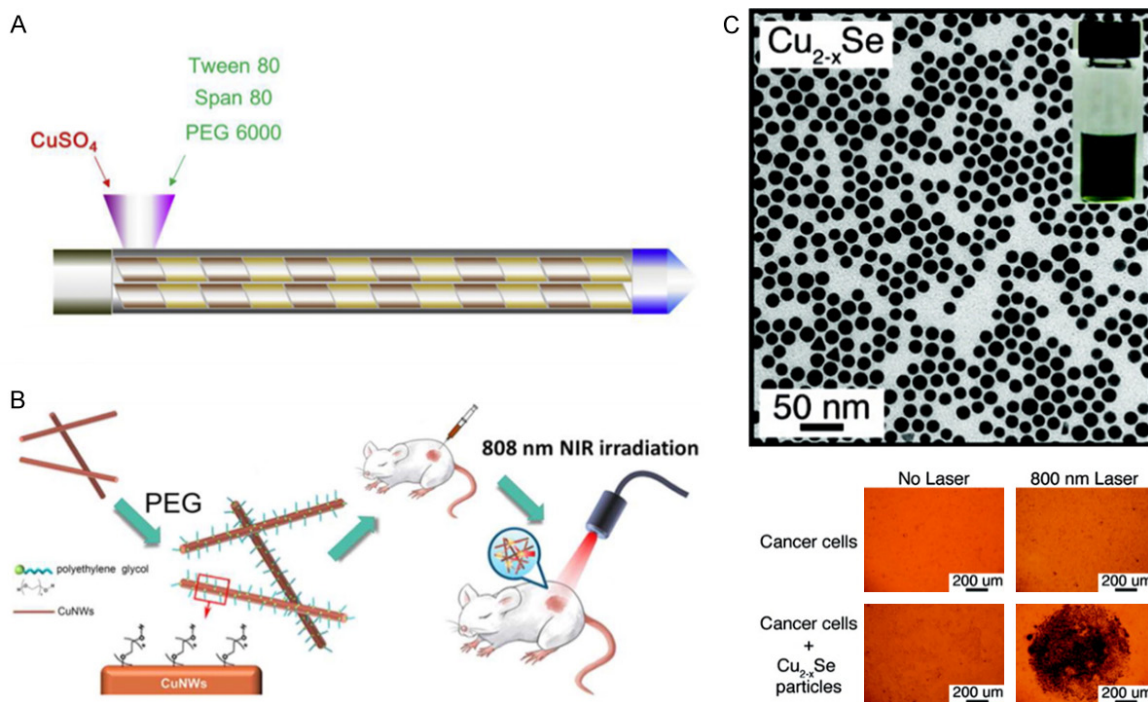
Carbon-based nanomaterials also have NIR absorption capacity. The types which currently under development for photothermal therapy include graphene [103-105] and carbon nanotubes [106-108]. Graphene is made up of a flat sheet of carbon atoms, while carbon nanotube is a three-dimensional structure made of graphene [109, 110].

Carbon-based nanomaterials have electrochemical properties and non-covalent bond binding properties, thus allowing them to use in combination with functionalized molecules which also have covalent or noncovalent binding and different surface chemical properties. Some of these include magnetic materials [105] and chemotherapeutic drugs [111]. A number of publications have demonstrated due to the large aromatic surface areas of the graphene oxide nanogels, they can be loaded with chemotherapeutic drugs including irinote-

Photothermal therapy for metastatic CRC



**Figure 2.** Carbon-based nanomaterials. A. Irinotecan loaded graphene oxide nanogels [103]. B. SN38 loaded graphene oxide nanogels [104]. C. Cetuximab and Fe<sub>3</sub>O<sub>4</sub> Magnetic nanoparticles loaded graphene oxide nanogels [105]. D. Multiwalled carbon nanotubes bound with folic acid [106]. E. POSS-PCU nanocomposite polymer [108].



**Figure 3.** Metal compounds nanomaterials. A.  $\text{CuSO}_4$  NCs [115]. B. PEGylated CuNWs [116]. C.  $\text{Cu}_{2-x}\text{Se}$  nanocrystals [117].

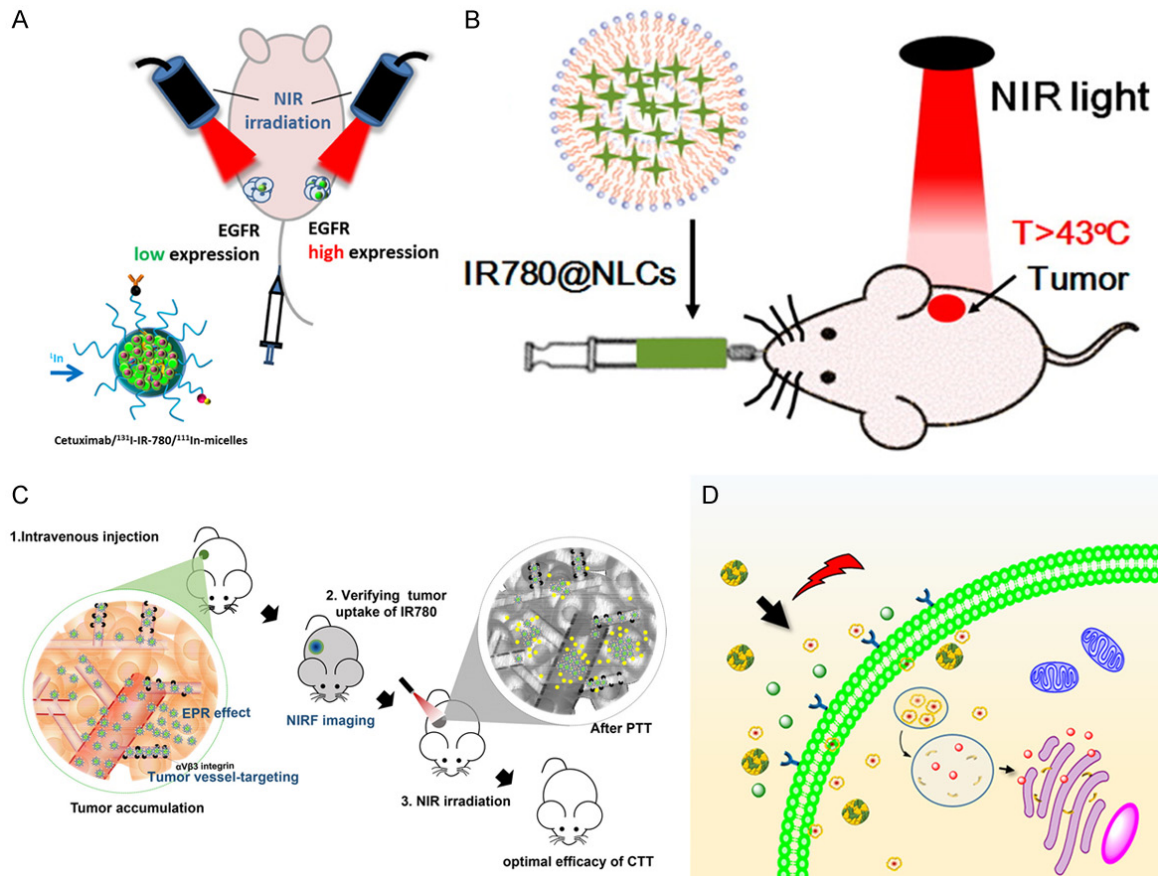
can (**Figure 2A**) [103], SN38 (an active metabolite of irinotecan, **Figure 2B**) [104], cetuximab and  $\text{Fe}_3\text{O}_4$  magnetic nanoparticles (**Figure 2C**) [105]. In addition, another paper showed that the multiwalled carbon nanotubes bound with folic acid **Figure 2D**) can enhance the affinity for CRC cells by 400-500%, and decrease the activity of CRC cells by 50-60% after NIR irradiation [106]. Moreover, Tan et al., synthesized poly (carbonate-urea) urethane functionalized multiwalled carbon nanotubes (POSS-PCU, **Figure 2E**) that can thermally ablate cancer cells under NIR irradiation [108]. However, the main disadvantages of carbon-based nanomaterials are first their low photothermal conversion efficiency, which means a higher irradiation wavelength or intensity is necessary compared with other materials. This may result in more normal tissue damage [112]. Second, they can easily deposit into organs such as liver, kidney, and skin, causing granuloma formation and further leading to the development of cysts and organ damage [113, 114].

Currently, the studies of metal compound nanomaterials used in CRC photothermal therapy are few, and the materials targeting CRC in vivo need to be developed. Metal compound nanomaterials mainly include copper compounds

[115-117]. The advantages of metal compound nanomaterials are their low cost and low cytotoxicity [116]. A recent study reported that copper sulfate nanocomposite materials ( $\text{CuSO}_4$  NCs, **Figure 3A**) decreased the viability of CRC cells after NIR irradiation [115]. In addition, polyethylene glycol coated copper nanowires (PEGylated CuNWs, **Figure 3B**) was shown to induce tumor cell necrosis and inhibit tumor growth in CRC subcutaneous tumor-bearing mice through intratumor injection and NIR irradiation [116]. Furthermore, Hessel et al. [117] synthesized copper selenide nanocrystals ( $\text{Cu}_{2-x}\text{Se}$  nanocrystals, **Figure 3C**) that necrotized CRC cells under NIR irradiation. The disadvantage of metal compound nanomaterials is similar to carbon-based nanomaterials in that they also have low photothermal conversion efficiency. Ultimately, these materials require high power NIR or adjustment in their size and shape to improve the photothermal conversion ability [75].

Organic nanomaterials currently under development include NIR dye-based nanomicelles [118-124], porphyrin liposome nanomaterials [89], small organic nanomaterials [125]; and organic polymer nanomaterials [126-131].

## Photothermal therapy for metastatic CRC



**Figure 4.** Organic nanomaterials. A. EGFR-targeted micelles containing NIR dye [118]. B. IR780@NLCs [119]. C. SN38 and dye IR780 loaded nanomicelles [122]. D. Dye ADS-780 decorated apoferritin nanoparticles [123].

Organic nanomaterials have better biocompatibility and biodegradation compared with inorganic nanomaterials [132]. This is demonstrated by research showing the use of nanomaterials containing NIR dyes such as indocyanine green and heptamethine cyanine which can be excreted through the urine [133]. Nanomaterials carrying liposome and protein have been shown to be degraded in the body [134, 135]. It was shown that an EGFR-targeted micelle containing NIR dye IR-780 (**Figure 4A**) can successfully accumulate in CRC tumor tissue through tail vein injection of subcutaneous tumor-bearing mice and subsequently reduce the size of the tumor after irradiation [118]. In another report, they demonstrated that a nanostructured lipid carrier containing NIR dye (IR780@NLCs, **Figure 4B**) was stable in simulated gastric and intestinal conditions and targeted tumor in subcutaneous tumor-bearing mice through oral absorption [119]. In addition, some polymer materials, such as Fe<sup>3+</sup>/vinylpyrrolidone coordination poly-

mer nanoparticles [127], polyaniline-coated upconversion nanoparticles [128], and polyoxyethylene chain coated polyaniline nanoparticles [129], have been shown to completely ablate the tumor in a CRC subcutaneous tumor-bearing mouse model after NIR irradiation.

For combined applications, some organic nanomaterials have been designed to bind to functional molecules, such as anticancer drugs and contrast agents. Many functional molecules binding nanomaterials for colorectal cancer were reported, including SN38 and dye IR780 loaded nanomicelles (**Figure 4C**) [122], SN-38-encapsulated nano porphyrin micelles (SN-NPM) [122], DOX and indocyanine green loaded hyaluronic acid [120], dye ADS-780 decorated apoferritin nanoparticles (**Figure 4D**) [123], Platinum-chelated bilirubin nanoparticles [136], and radionuclide rhenium labeled micelles containing Dye IR-780 [121]. After tail vein injection and NIR irradiation of these materials in CRC subcutaneous tumor-bearing mice they were all

shown to be effective in slowing down the growth rate of tumor volume and in causing tumor tissue necrosis. The disadvantage of organic photothermic agents is their susceptibility to photobleaching [118]. Their absorption capacity decreases rapidly as functions of time, which makes them insufficient for long irradiation treatment [135].

### *Combined application of photothermal therapy*

Imaging-guided photothermal therapy is an effective method to detect the biological distribution of photothermal nanomaterials and evaluate the performance of PTT in tumor ablation. In this way, visualization of the tumor metastasis provides an effective reference factor for irradiation range before treatment, and therapeutic effect after treatment as well. These include fluorescence imaging [87, 91, 123, 128], MR imaging [82-84, 88, 90, 127], and photoacoustic imaging [90, 125, 136].

Attaching fluorescent probes to nanomaterials is to detect/track fluorescence imaging-guided photothermal therapy. Synthesized cisplatin was loaded into chitosan/gold nanorod hybrid nanosphere conjugated to a fluorescence probe, fluorescein isothiocyanate (FITC) by a covalent linkage [87]. By using the microscopic scattering dark-field imaging of localized surface plasmon resonance and fluorescence images of FITC, the hybrid nanosphere could be used as a bimodal contrast agent for real-time optical imaging. At the same time, the combined effect from the PTT and chemotherapy can accelerate the death of cancer cells, allowing an all-in-one system of cell imaging, drug delivery, and photothermal therapy.

Photothermal conversion materials connected with superparamagnetic materials are suitable for MR imaging and PTT. Azhdazadeh et al. [88] synthesized gold-plated superparamagnetic iron oxide nanoparticles with the MUC-1 aptamer as a targeting agent (Au@SPIONs). Au@SPIONs significantly attenuated the MR signal strength of CRC cells HT-29 treated compared with control cells.

Nanomaterials carrying radionuclides are applicable for positron emission tomography (PET) or single-photon emission computed tomography (SPECT) [137, 138]. Peng et al. [121] synthesized NIR dye IR-780 loaded multifunctional

micelles labeled with the radionuclide rhenium-188 for photothermal treatment and SPECT imaging in CRC subcutaneous tumor-bearing mice. The radiation of the subcutaneous tumor increased in SPECT/CT image after injection of the micelles 24 h later, achieving a better tumor and non-tumor contrast (**Figure 5A**).

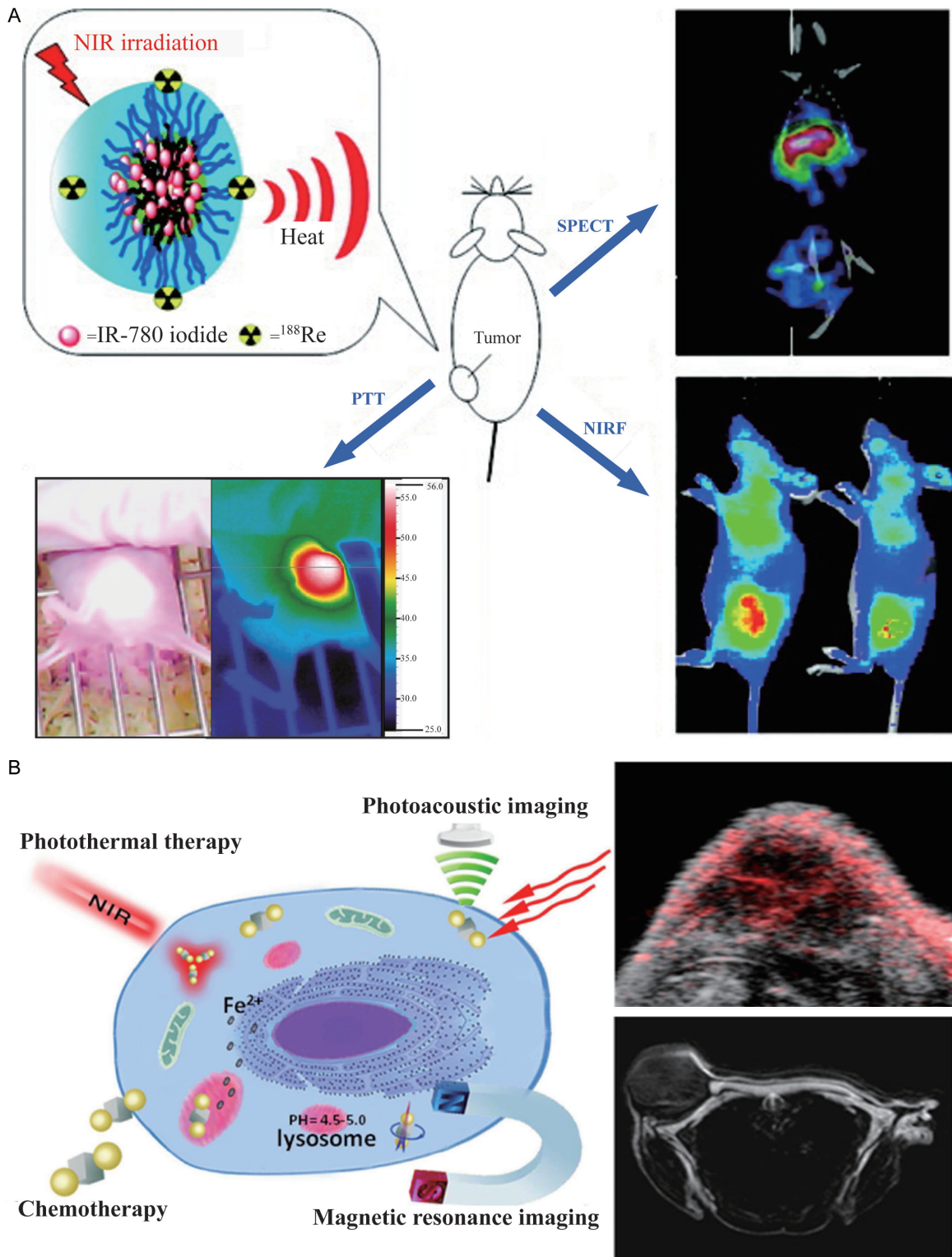
Photothermal therapy can be guided by photoacoustic imaging (PAI). Tissue produces sound waves under irradiation because of local heating and small expansion, and the signal of the photoacoustic effect is proportional to light absorption [139]. An interesting report by Zhang et al. [90] synthesized hybrid anisotropic nanoparticles (HANs) composed of iron platinum alloy nanoparticles and gold nanoparticles. The irradiation absorption ability of the gold nanoparticles was applicable as a contrast agent for PAI and as a photothermal conversion material. Also, the iron platinum alloy nanoparticles have super paramagnetism which is applicable as an MRI contrast agent [140]. Therefore, HANs can be used to act as a PAI and an MRI contrast agent, as well as a PTT photothermal conversion material, to utilize different imaging modes and overcome the disadvantages of different imaging modes. The photoacoustic signal and MR signal could be clearly detected in the tumor site 1 h after injecting HANs in tumor-bearing mice (**Figure 5B**).

Traditional chemotherapeutic drugs often cause systemic adverse reactions due to their poor selectivity [62]. However, combined chemo-photothermal therapy is more than just a simple combination. Here are the advantages: 1) The photothermal conversion materials are suitable as carriers of chemotherapeutic drugs, improving the selectivity of the chemotherapeutic drugs and prolonging their circulation time in the blood [141]. 2) The thermal effect produced by photothermal therapy can enhance the local chemotherapy effect [142] or allow a temperature-sensitive drug delivery system [143]. Therefore, combined chemo-PTT will allow fewer drugs to be used to achieve the same effect and thus minimize the side effects.

Recently, a publication reported a FITC/cisplatin loaded chitosan/gold nanorod hybrid nanosphere for combined chemo-PTT (**Figure 6A**) [87]. The idea is that the hybrid nanospheres can provide space for loading of the specific anticancer drugs, and cisplatin. Traditional can-



## Photothermal therapy for metastatic CRC

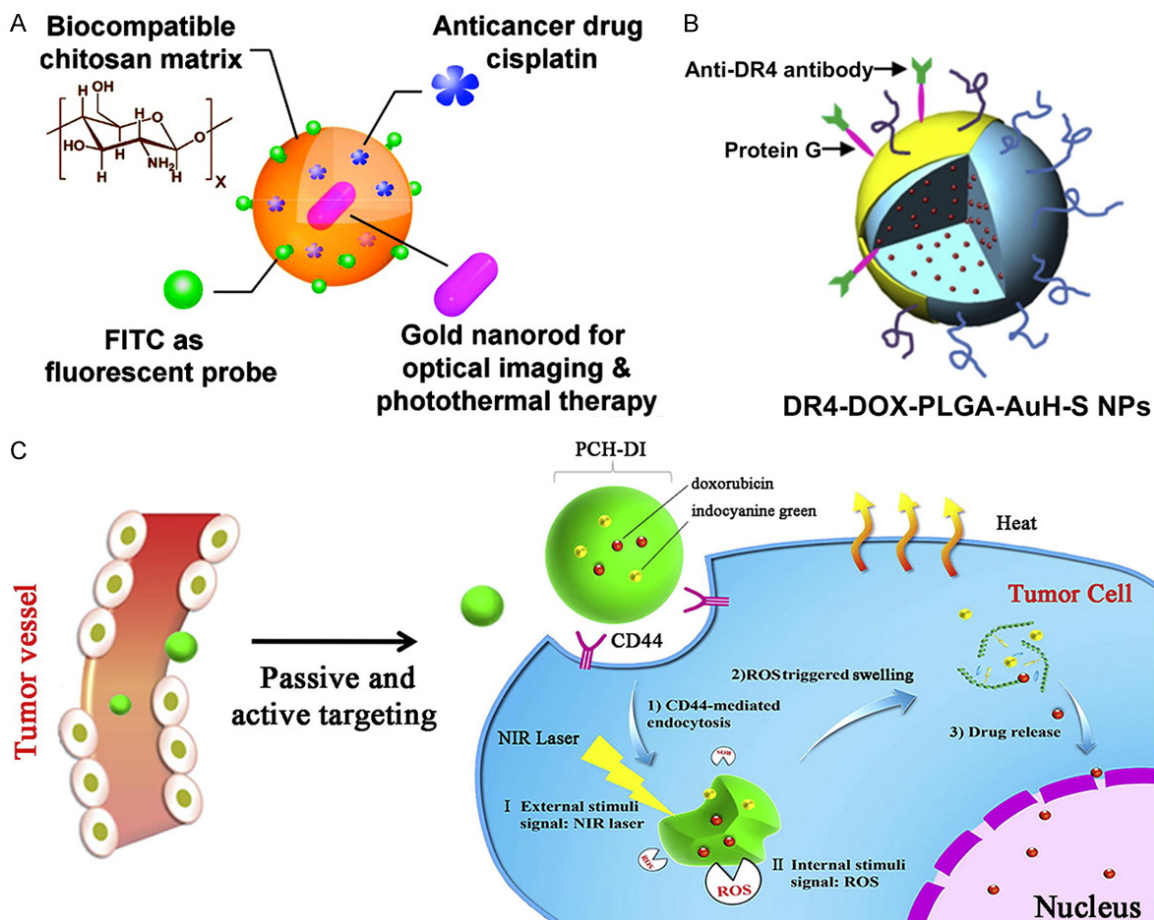


**Figure 5.** Image-guided photothermal therapy. A. NIR dye IR-780 loaded multifunctional micelles labeled with the radionuclide rhenium-188 [121]. B. hybrid anisotropic nanoparticles composed of iron platinum alloy nanoparticles and gold nanoparticles [90].

cer chemotherapy is often limited by multidrug resistance (MDR), because the multidrug resis-

tance membrane transporters can transport multiple drugs out of cells and prevent intracel-

## Photothermal therapy for metastatic CRC



**Figure 6.** Combined chemo-photothermal therapy. A. FITC/cisplatin loaded chitosan/gold nanorod hybrid nanoparticles [87]; B. DOX loaded gold half-shell nanoparticles [89]. C. PCH-DI [120].

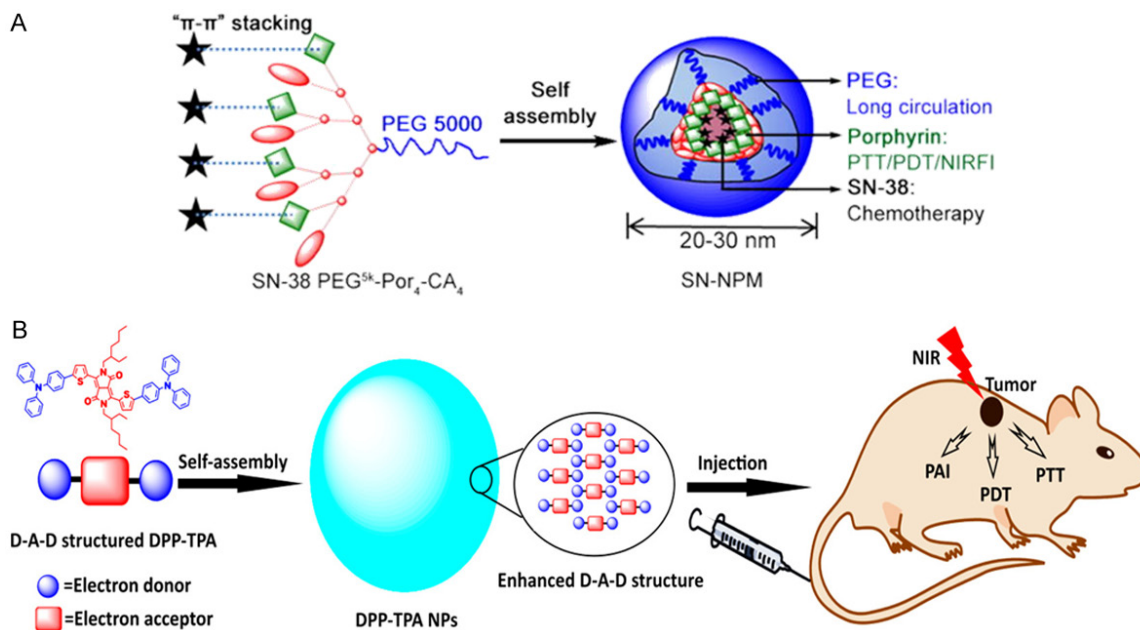
ular drug accumulation [144]. However, this nanosphere technology including DOX loaded gold half-shell nanoparticles (Figure 6B) is capable of overcoming MDR by transferring heat to cancer cells effectively [89]. As a result, the nanoparticles combined with the chemotherapy drugs decreased the growth rate of tumors in a CRC subcutaneous tumor-bearing mouse model with a significantly lower DOX dose compared to conventional chemotherapy at a higher dose. Another group showed treatment of hyaluronic acid nanoparticles loaded with DOX and indocyanine green (PCH-DI, Figure 6C) [120] can result in 82.9% subcutaneous tumor inhibition. PCH-DI treatment in the in-situ induction model resulted in a significantly lower number and volume of tumors compared to those in the chemotherapy alone group, PTT alone group, or untreated group.

Photosensitizers used in photodynamic therapy (PDT) transport energy to oxygen molecule to produce cytotoxic singlet oxygen and subse-

quently induces cells to produce cytokines which can destroy tumor cell membranes and microvessels [145, 146]. Since both PDT and PTT require light irradiation, combining both photothermal-photodynamic therapies will form a highly effective cancer irradiation treatment. However, the disadvantages of PDT therapy are that the wavelength of radiation required for photosensitizer is usually less than 700 nm which is below the NIR range, and that the synthesis of water-soluble photosensitizers is difficult due to the hydrophobic structure of photosensitizers [147]. Therefore, photothermal materials are required to serve as carriers of the photosensitizers for targeted transport to the tumor regions and to address their limitations in wavelength of light irradiation and water solubility.

Recently, Seo et al. [85] used gold nanorods (GNR) combined with methylene blue (MB) as the photothermal material. Methylene blue is a water-soluble phenothiazine photosensitizer

## Photothermal therapy for metastatic CRC



**Figure 7.** Combined photothermal-photodynamic therapy. A. SN-NPM capable of triple therapy of photothermal therapy, photodynamic therapy and chemotherapy [124]. B. DPP-TPA applicable for PAI-guided combined photothermal-photodynamic therapy [125].

with a high quantum yield of singlet oxygen [148]. MB-GNR resulted in prolonged NIR irradiation time, thus reactive oxygen species increased significantly compared to the group with MB without the GNR photothermal material. Consequently, MB-GNR showed the dual effects of photodynamic and photothermal treatment with a significantly better anticancer effect compared to pure gold nanorod or pure methylene blue alone.

Besides, Yang et al. [124] synthesized SN-38-encapsulated nanoporphyrin micelles (SN-NPM) which were capable of combining photothermal therapy, photodynamic therapy, and chemotherapy into one (**Figure 7A**). SN-38 is an important and highly effective chemotherapeutic drug for various cancers including colorectal cancer [149]. Water-soluble nano porphyrin micelles can be activated to generate heat and reactive oxygen at the tumor sites under NIR irradiation. Yang et al. [124] showed the tumor volume grew significantly slower after SN-NPM combined therapy in tumor-bearing mice compared to each of the three single therapies.

Furthermore, Cai et al. [125] synthesized dike-topyrrolopyrrole-triphenylamine organic nanoparticles (DPP-TPA) applicable for PAI combined with PTT and PDT (**Figure 7B**). The use of DPP-

TPA showed a passive targeted effect at the tumor sites through the enhanced permeability and retention effects after they were injected into subcutaneous tumor-bearing mice [150]. In the study, the photoacoustic signal intensity reached its maximum value in the tumor site 2 hours after injection, suggesting the best waiting time for tumor localization and photothermal-photodynamic therapy. Ultimately, the tumor achieved completed ablation after the treatment.

### Conclusions and perspective

In summary, the traditional treatments of mCRC, including surgery, chemotherapy, radiotherapy, and biotherapy, have inevitable limitations. Photothermal therapy provides a new strategy for the treatment of mCRC. Current researches of PTT are centered on material construction and verification on animal models, focusing on three main themes: low cytotoxicity, high photothermal conversion efficiency, and high biocompatibility.

The major challenges now remain to solve the application of photothermal therapy in clinical medicine. The first is the issue of biological safety. The photothermal nanomaterials in current researches do not cause acute toxicity in

the short term, but lack of long-term toxicity evaluation criteria and research reports. The second is clinical technology issues. Current researches are limited to the treatment of cell level and animal tumor models. The corresponding medical equipment and method for clinical photothermal therapy thus are needed to investigate due to the limited range of effects of light irradiation.

Therefore, future studies need to focus on three aspects. Firstly, the evaluation standard of the biosafety of photothermal nanomaterials should be defined. In which the mechanism and rate of removal of photothermal nanomaterials, such as through their own metabolic degradation, photodegradation, or through urine excretion, need to be explored. Moreover, researchers should explore the short-term and long-term toxic and side effects caused by material deposition in vivo and define the evaluation indicators. Finally, the development of new nanomaterials or optimization of existing nanomaterials should be devoted to. The existing nanomaterials are, more or less, defective. It's of great significance to improve the photostability of gold nanomaterials or improve the photothermal conversion efficiency of graphene nanomaterials. In another way, we could develop new nanomaterials that are photostable and efficient in photothermal conversion. What's more, the clinical application of photothermal therapy should be studied. As to mCRC, it's critical to explore the application of photothermal therapy for mCRC, such as external irradiation, natural intracavitary irradiation, or intraperitoneal irradiation. There is potential for photothermal therapy to become an ideal choice in accurate positioning and precise treatment of metastatic colorectal cancer with the development of interdisciplinary research.

### Acknowledgements

This work was supported by the Fundamental Research Funds for the Central Universities (16ykjc25), Sun Yat-Sen University Clinical Research 5010 Program (2016005), Australian National Health and Medical Research Council (NHMRC) Grant (1158402) and National Natural Science Foundation of China (NSFC) (81671928).

### Disclosure of conflict of interest

None.

**Address correspondence to:** Dr. Liping Wang, UniSA Clinical and Health Sciences, and UniSA Cancer Research Institute, University of South Australia, Adelaide, SA 5001, Australia. Tel: 618-8302-2715; Fax: 618-8302-1087; E-mail: liping.wang@mymail.unisa.edu.au; Dr. Liang Kang, Department of Colorectal Surgery, Guangdong Institute of Gastroenterology, and Guangdong Provincial Key Laboratory of Colorectal and Pelvic Floor Diseases, The Sixth Affiliated Hospital of Sun Yat-sen University, Guangzhou 510655, Guangdong, China. Tel: +86-2038455369; Fax: +862038254221; E-mail: kangl@mail.sysu.edu.cn

### References

- [1] Bray F, Ferlay J, Soerjomataram I, Siegel RL, Torre LA and Jemal A. Global cancer statistics 2018: GLOBOCAN estimates of incidence and mortality worldwide for 36 cancers in 185 countries. *CA Cancer J Clin* 2018; 68: 394-424.
- [2] Siegel RL, Fedewa SA, Anderson WF, Miller KD, Ma J, Rosenberg PS and Jemal A. Colorectal cancer incidence patterns in the united states, 1974-2013. *J Natl Cancer Inst* 2017; 109.
- [3] Kuipers EJ, Grady WM, Lieberman D, Seufferlein T, Sung JJ, Boelens PG, van de Velde CJ and Watanabe T. Colorectal cancer. *Nat Rev Dis Primers* 2015; 1: 15065.
- [4] Austin H, Henley SJ, King J, Richardson LC and Ehemann C. Changes in colorectal cancer incidence rates in young and older adults in the United States: what does it tell us about screening. *Cancer Causes Control* 2014; 25: 191-201.
- [5] Moore KJ, Sussman DA and Koru-Sengul T. Age-specific risk factors for advanced stage colorectal cancer, 1981-2013. *Prev Chronic Dis* 2018; 15: E106.
- [6] Siegel RL, Miller KD, Fedewa SA, Ahnen DJ, Meester RGS, Barzi A and Jemal A. Colorectal cancer statistics, 2017. *CA Cancer J Clin* 2017; 67: 177-193.
- [7] Lemmens VE, Klaver YL, Verwaal VJ, Rutten HJ, Coebergh JW and de Hingh IH. Predictors and survival of synchronous peritoneal carcinomatosis of colorectal origin: a population-based study. *Int J Cancer* 2011; 128: 2717-2725.
- [8] Vatandoust S, Price TJ and Karapetis CS. Colorectal cancer: metastases to a single organ. *World J Gastroenterol* 2015; 21: 11767-11776.
- [9] Mitry E, Guiu B, Coscinea S, Jooste V, Faivre J and Bouvier AM. Epidemiology, management and prognosis of colorectal cancer with lung metastases: a 30-year population-based study. *Gut* 2010; 59: 1383-1388.

## Photothermal therapy for metastatic CRC

- [10] Sakorafas GH, Zouros E and Peros G. Applied vascular anatomy of the colon and rectum: clinical implications for the surgical oncologist. *Surg Oncol* 2006; 15: 243-255.
- [11] Hughes ES and Cuthbertson AM. Recurrence after curative excision of carcinoma of the large bowel. *JAMA* 1962; 182: 1303-1306.
- [12] Segelman J, Granath F, Holm T, Machado M, Mahteme H and Martling A. Incidence, prevalence and risk factors for peritoneal carcinomatosis from colorectal cancer. *Br J Surg* 2012; 99: 699-705.
- [13] Aoyagi T, Terracina KP, Raza A and Takabe K. Current treatment options for colon cancer peritoneal carcinomatosis. *World J Gastroenterol* 2014; 20: 12493-12500.
- [14] Simmonds PC, Primrose JN, Colquitt JL, Garden OJ, Poston GJ and Rees M. Surgical resection of hepatic metastases from colorectal cancer: a systematic review of published studies. *Br J Cancer* 2006; 94: 982-999.
- [15] Vassos N and Piso P. Metastatic colorectal cancer to the peritoneum: current treatment options. *Curr Treat Options Oncol* 2018; 19: 49.
- [16] Pfannschmidt J, Dienemann H and Hoffmann H. Surgical resection of pulmonary metastases from colorectal cancer: a systematic review of published series. *Ann Thorac Surg* 2007; 84: 324-338.
- [17] Kobiela J, Spychalski P, Marvaso G, Ciardo D, Dell'Acqua V, Kraja F, Błażyńska-Spychalska A, Łachiński AJ, Surgo A, Glynn-Jones R and Jerezek-Fossa BA. Ablative stereotactic radiotherapy for oligometastatic colorectal cancer: systematic review. *Crit Rev Oncol Hematol* 2018; 129: 91-101.
- [18] Takeda A, Sanuki N and Kunieda E. Role of stereotactic body radiotherapy for oligometastasis from colorectal cancer. *World J Gastroenterol* 2014; 20: 4220-4229.
- [19] de Gramont A, Figer A, Seymour M, Homerin M, Hmissi A, Cassidy J, Boni C, Cortes-Funes H, Cervantes A, Freyer G, Papamichael D, Le Bail N, Louvet C, Hendler D, de Braud F, Wilson C, Morvan F and Bonetti A. Leucovorin and fluorouracil with or without oxaliplatin as first-line treatment in advanced colorectal cancer. *J Clin Oncol* 2000; 18: 2938-2947.
- [20] Goldberg RM, Sargent DJ, Morton RF, Fuchs CS, Ramanathan RK, Williamson SK, Findlay BP, Pitot HC and Alberts SR. A randomized controlled trial of fluorouracil plus leucovorin, irinotecan, and oxaliplatin combinations in patients with previously untreated metastatic colorectal cancer. *J Clin Oncol* 2004; 22: 23-30.
- [21] Cassidy J, Clarke S, Díaz-Rubio E, Scheithauer W, Figer A, Wong R, Koski S, Lichinitser M, Yang TS, Rivera F, Couture F, Sirzén F and Saltz L. Randomized phase III study of capecitabine plus oxaliplatin compared with fluorouracil/folinic acid plus oxaliplatin as first-line therapy for metastatic colorectal cancer. *J Clin Oncol* 2008; 26: 2006-2012.
- [22] Falcone A, Ricci S, Brunetti I, Pfanner E, Allegri G, Barbara C, Crinò L, Benedetti G, Evangelista W, Fanchini L, Cortesi E, Picone V, Vitello S, Chiara S, Granetto C, Porcile G, Fioretto L, Orlandini C, Andreuccetti M and Masi G. Phase III trial of infusional fluorouracil, leucovorin, oxaliplatin, and irinotecan (FOLFOXIRI) compared with infusional fluorouracil, leucovorin, and irinotecan (FOLFIRI) as first-line treatment for metastatic colorectal cancer: the Gruppo Oncologico Nord Ovest. *J Clin Oncol* 2007; 25: 1670-1676.
- [23] Passardi A, Nanni O, Tassinari D, Turci D, Cavanna L, Fontana A, Ruscelli S, Mucciari C, Lorusso V, Ragazzini A, Frassinetti GL and Amadori D. Effectiveness of bevacizumab added to standard chemotherapy in metastatic colorectal cancer: final results for first-line treatment from the ITACa randomized clinical trial. *Ann Oncol* 2015; 26: 1201-1207.
- [24] Hurwitz H, Fehrenbacher L, Novotny W, Cartwright T, Hainsworth J, Heim W, Berlin J, Baron A, Griffing S, Holmgren E, Ferrara N, Fyfe G, Rogers B, Ross R and Kabbinavar F. Bevacizumab plus irinotecan, fluorouracil, and leucovorin for metastatic colorectal cancer. *N Engl J Med* 2004; 350: 2335-2342.
- [25] Saltz LB, Clarke S, Díaz-Rubio E, Scheithauer W, Figer A, Wong R, Koski S, Lichinitser M, Yang TS, Rivera F, Couture F, Sirzén F and Cassidy J. Bevacizumab in combination with oxaliplatin-based chemotherapy as first-line therapy in metastatic colorectal cancer: a randomized phase III study. *J Clin Oncol* 2008; 26: 2013-2019.
- [26] Stintzing S, Modest DP, Rossius L, Lerch MM, von Weikersthal LF, Decker T, Kiani A, Vehling-Kaiser U, Al-Batran SE, Heintges T, Lerchenmüller C, Kahl C, Seipelt G, Kullmann F, Stauch M, Scheithauer W, Held S, Giessen-Jung C, Moehler M, Jagenburg A, Kirchner T, Jung A and Heinemann V. FOLFIRI plus cetuximab versus FOLFIRI plus bevacizumab for metastatic colorectal cancer (FIRE-3): a post-hoc analysis of tumour dynamics in the final RAS wild-type subgroup of this randomised open-label phase 3 trial. *Lancet Oncol* 2016; 17: 1426-1434.
- [27] Heinemann V, von Weikersthal LF, Decker T, Kiani A, Vehling-Kaiser U, Al-Batran SE, Heintges T, Lerchenmüller C, Kahl C, Seipelt G, Kullmann F, Stauch M, Scheithauer W, Hielscher J, Scholz M, Müller S, Link H, Niederle N, Rost A, Höffkes HG, Moehler M, Lindig RU, Modest DP, Rossius L, Kirchner T, Jung A and Stintzing S.

## Photothermal therapy for metastatic CRC

- FOLFIRI plus cetuximab versus FOLFIRI plus bevacizumab as first-line treatment for patients with metastatic colorectal cancer (FIRE-3): a randomised, open-label, phase 3 trial. *Lancet Oncol* 2014; 15: 1065-1075.
- [28] Karapetis CS, Khambata-Ford S, Jonker DJ, O'Callaghan CJ, Tu D, Tebbutt NC, Simes RJ, Chalchal H, Shapiro JD, Robitaille S, Price TJ, Shepherd L, Au HJ, Langer C, Moore MJ and Zalcborg JR. K-ras mutations and benefit from cetuximab in advanced colorectal cancer. *N Engl J Med* 2008; 359: 1757-1765.
- [29] Le DT, Uram JN, Wang H, Bartlett BR, Kemberling H, Eyring AD, Skora AD, Luber BS, Azad NS, Laheru D, Biedrzycki B, Donehower RC, Zaheer A, Fisher GA, Crocenzi TS, Lee JJ, Duffy SM, Goldberg RM, de la Chapelle A, Koshiji M, Bhaijee F, Huebner T, Hruban RH, Wood LD, Cuka N, Pardoll DM, Papadopoulos N, Kinzler KW, Zhou S, Cornish TC, Taube JM, Anders RA, Eschleman JR, Vogelstein B and Diaz LA. PD-1 blockade in tumors with mismatch-repair deficiency. *N Engl J Med* 2015; 372: 2509-2520.
- [30] Overman MJ, Lonardi S, Wong KYM, Lenz HJ, Gelsomino F, Aglietta M, Morse MA, Van Cutsem E, McDermott R, Hill A, Sawyer MB, Hendlisz A, Neyns B, Svrcek M, Moss RA, Ledezine JM, Cao ZA, Kamble S, Kopetz S and Andre T. Durable clinical benefit with nivolumab plus ipilimumab in DNA mismatch repair-deficient/microsatellite instability-High metastatic colorectal cancer. *J Clin Oncol* 2018; 36: 773-779.
- [31] Overman MJ, McDermott R, Leach JL, Lonardi S, Lenz HJ, Morse MA, Desai J, Hill A, Axelson M, Moss RA, Goldberg MV, Cao ZA, Ledezine JM, Maglente GA, Kopetz S and André T. Nivolumab in patients with metastatic DNA mismatch repair-deficient or microsatellite instability-high colorectal cancer (CheckMate 142): an open-label, multicentre, phase 2 study. *Lancet Oncol* 2017; 18: 1182-1191.
- [32] Van Cutsem E, Cervantes A, Adam R, Sobrero A, Van Krieken JH, Aderka D, Aranda Aguilar E, Bardelli A, Benson A, Bodoky G, Ciardiello F, D'Hoore A, Diaz-Rubio E, Douillard JY, Ducreux M, Falcone A, Grothey A, Gruenberger T, Haustermans K, Heinemann V, Hoff P, Köhne CH, Labianca R, Laurent-Puig P, Ma B, Maughan T, Muro K, Normanno N, Österlund P, Oyen WJ, Papamichael D, Pentheroudakis G, Pfeiffer P, Price TJ, Punt C, Ricke J, Roth A, Salazar R, Scheithauer W, Schmoll HJ, Tabernero J, Taieb J, Tejpar S, Wasan H, Yoshino T, Zaanan A and Arnold D. ESMO consensus guidelines for the management of patients with metastatic colorectal cancer. *Ann Oncol* 2016; 27: 1386-1422.
- [33] Poston GJ, Adam R, Alberts S, Curley S, Figueras J, Haller D, Kunstlinger F, Mentha G, Nordlinger B, Patt Y, Primrose J, Roh M, Rougier P, Ruers T, Schmoll HJ, Valls C, Vauthey NJ, Cornelis M and Kahan JP. OncoSurge: a strategy for improving resectability with curative intent in metastatic colorectal cancer. *J Clin Oncol* 2005; 23: 7125-7134.
- [34] Nordlinger B, Sorbye H, Glimelius B, Poston GJ, Schlag PM, Rougier P, Bechstein WO, Primrose JN, Walpole ET, Finch-Jones M, Jaeck D, Mirza D, Parks RW, Mauer M, Tanis E, Van Cutsem E, Scheithauer W and Gruenberger T. Perioperative FOLFOX4 chemotherapy and surgery versus surgery alone for resectable liver metastases from colorectal cancer (EORTC 40983): long-term results of a randomised, controlled, phase 3 trial. *Lancet Oncol* 2013; 14: 1208-1215.
- [35] Warwick R and Page R. Resection of pulmonary metastases from colorectal carcinoma. *Eur J Surg Oncol* 2007; 33 Suppl 2: S59-63.
- [36] McAfee MK, Allen MS, Trastek VF, Ilstrup DM, Deschamps C and Pairolero PC. Colorectal lung metastases: results of surgical excision. *Ann Thorac Surg* 1992; 53: 780-786.
- [37] Kuijpers AM, Mirck B, Aalbers AG, Nienhuijs SW, de Hingh IH, Wiezer MJ, van Ramshorst B, van Ginkel RJ, Havenga K, Bremers AJ, de Wilt JH, Te VE and Verwaal VJ. Cytoreduction and HIPEC in the Netherlands: nationwide long-term outcome following the Dutch protocol. *Ann Surg Oncol* 2013; 20: 4224-4230.
- [38] Ychou M, Hohenberger W, Thezenas S, Navarro M, Maurel J, Bokemeyer C, Shacham-Shmueli E, Rivera F, Kwok-Keung Choi C and Santoro A. A randomized phase III study comparing adjuvant 5-fluorouracil/foinic acid with FOLFIRI in patients following complete resection of liver metastases from colorectal cancer. *Ann Oncol* 2009; 20: 1964-1970.
- [39] Coskun U, Buyukberber S, Yaman E, Uner A, Er O, Ozkan M, Dikilitas M, Oguz M, Yildiz R, B DY, Kaya AO and Benekli M. Xelox (capecitabine plus oxaliplatin) as neoadjuvant chemotherapy of unresectable liver metastases in colorectal cancer patients. *Neoplasma* 2008; 55: 65-70.
- [40] Masi G, Cupini S, Marcucci L, Cerri E, Loupakis F, Allegrini G, Brunetti IM, Pfanner E, Viti M, Goletti O, Filipponi F and Falcone A. Treatment with 5-fluorouracil/foinic acid, oxaliplatin, and irinotecan enables surgical resection of metastases in patients with initially unresectable metastatic colorectal cancer. *Ann Surg Oncol* 2006; 13: 58-65.
- [41] Inoue Y, Miki C, Hiro J, Ojima E, Yamakado K, Takeda K and Kusunoki M. Improved survival using multi-modality therapy in patients with lung metastases from colorectal cancer: a pre-

## Photothermal therapy for metastatic CRC

- liminary study. *Oncol Rep* 2005; 14: 1571-1576.
- [42] Petre EN, Jia X, Thornton RH, Sofocleous CT, Alago W, Kemeny NE and Solomon SB. Treatment of pulmonary colorectal metastases by radiofrequency ablation. *Clin Colorectal Cancer* 2013; 12: 37-44.
- [43] Nishiofuku H, Tanaka T, Matsuoka M, Otsuji T, Anai H, Sueyoshi S, Inaba Y, Koyama F, Sho M, Nakajima Y and Kichikawa K. Transcatheter arterial chemoembolization using cisplatin powder mixed with degradable starch microspheres for colorectal liver metastases after FOLFOX failure: results of a phase I/II study. *J Vasc Interv Radiol* 2013; 24: 56-65.
- [44] Van Cutsem E, Köhne CH, Hitre E, Zaluski J, Chang Chien CR, Makhson A, D'Haens G, Pintér T, Lim R, Bodoky G, Roh JK, Folprecht G, Ruff P, Stroh C, Tejpar S, Schlichting M, Nippgen J and Rougier P. Cetuximab and chemotherapy as initial treatment for metastatic colorectal cancer. *N Engl J Med* 2009; 360: 1408-1417.
- [45] Bokemeyer C, Bondarenko I, Makhson A, Hartmann JT, Aparicio J, de Braud F, Donea S, Ludwig H, Schuch G, Stroh C, Loos AH, Zube A and Koralewski P. Fluorouracil, leucovorin, and oxaliplatin with and without cetuximab in the first-line treatment of metastatic colorectal cancer. *J Clin Oncol* 2009; 27: 663-671.
- [46] Berger MD and Lenz HJ. The safety of monoclonal antibodies for treatment of colorectal cancer. *Expert Opin Drug Saf* 2016; 15: 799-808.
- [47] Sheth KR and Clary BM. Management of hepatic metastases from colorectal cancer. *Clin Colon Rectal Surg* 2005; 18: 215-223.
- [48] Abdalla EK, Vauthey JN, Ellis LM, Ellis V, Pollock R, Broglio KR, Hess K and Curley SA. Recurrence and outcomes following hepatic resection, radiofrequency ablation, and combined resection/ablation for colorectal liver metastases. *Ann Surg* 2004; 239: 818-825; discussion 825-817.
- [49] Van Cutsem E, Cervantes A, Nordlinger B and Arnold D. Metastatic colorectal cancer: ESMO clinical practice guidelines for diagnosis, treatment and follow-up. *Ann Oncol* 2014; 25 Suppl 3: iii1-9.
- [50] Tan KK, Lopes Gde L and Sim R. How uncommon are isolated lung metastases in colorectal cancer? A review from database of 754 patients over 4 years. *J Gastrointest Surg* 2009; 13: 642-648.
- [51] Embún R, Fiorentino F, Treasure T and Rivas JJ, Molins L; Grupo Español de Cirugía Metástasis Pulmonares de Carcinoma Colo-Rectal (GECMP-CCR) de la Sociedad Española de Neumología y Cirugía Torácica (SEPAR). (See appendix for membership of GECMP-CCR-SE. Pulmonary metastasectomy in colorectal cancer: a prospective study of demography and clinical characteristics of 543 patients in the Spanish colorectal metastasectomy registry (GECMP-CCR). *BMJ Open* 2013; 3.
- [52] Tampellini M, Ottone A, Bellini E, Alabiso I, Barattelli C, Bitossi R, Brizzi MP, Ferrero A, Sperti E, Leone F, Miraglia S, Forti L, Bertona E, Ardisone F, Berruti A, Alabiso O, Aglietta M and Scagliotti GV. The role of lung metastasis resection in improving outcome of colorectal cancer patients: results from a large retrospective study. *Oncologist* 2012; 17: 1430-1438.
- [53] Verwaal VJ, van Ruth S, de Bree E, van Slooten GW, van Tinteren H, Boot H and Zoetmulder FAN. Randomized trial of cytoreduction and hyperthermic intraperitoneal chemotherapy versus systemic chemotherapy and palliative surgery in patients with peritoneal carcinomatosis of colorectal cancer. *J Clin Oncol* 2003; 21: 3737-3743.
- [54] Halkia E, Kopanakis N, Nikolaou G and Spiliotis J. Cytoreductive surgery and HIPEC for peritoneal carcinomatosis. A review on morbidity and mortality. *J BUON* 2015; 20 Suppl 1: S80.
- [55] Chua TC, Yan TD, Saxena A and Morris DL. Should the treatment of peritoneal carcinomatosis by cytoreductive surgery and hyperthermic intraperitoneal chemotherapy still be regarded as a highly morbid procedure?: a systematic review of morbidity and mortality. *Ann Surg* 2009; 249: 900-907.
- [56] Shibata D, Paty PB, Guillem JG, Wong WD and Cohen AM. Surgical management of isolated retroperitoneal recurrences of colorectal carcinoma. *Dis Colon Rectum* 2002; 45: 795-801.
- [57] Ismaili N. Treatment of colorectal liver metastases. *World J Surg Oncol* 2011; 9: 154.
- [58] Skof E, Rebersek M, Hlebanja Z and Ocvirk J. Capecitabine plus Irinotecan (XELIRI regimen) compared to 5-FU/LV plus Irinotecan (FOLFIRI regimen) as neoadjuvant treatment for patients with unresectable liver-only metastases of metastatic colorectal cancer: a randomised prospective phase II trial. *BMC Cancer* 2009; 9: 120.
- [59] Nordlinger B, Van Cutsem E, Rougier P, Köhne CH, Ychou M, Sobrero A, Adam R, Arvidsson D, Carrato A, Georgoulas V, Giuliante F, Glimelius B, Golling M, Gruenberger T, Tabernero J, Wasan H and Poston G; European Colorectal Metastases Treatment Group. Does chemotherapy prior to liver resection increase the potential for cure in patients with metastatic colorectal cancer? A report from the European Colorectal Metastases Treatment Group. *Eur J Cancer* 2007; 43: 2037-2045.
- [60] Gruenberger B, Tamandl D, Schueller J, Scheithauer W, Zielinski C, Herbst F and Gruenberger T. Bevacizumab, capecitabine, and

- oxaliplatin as neoadjuvant therapy for patients with potentially curable metastatic colorectal cancer. *J Clin Oncol* 2008; 26: 1830-1835.
- [61] Nozawa H, Takiyama H, Hasegawa K, Kawai K, Hata K, Tanaka T, Nishikawa T, Sasaki K, Kaneko M, Muroto K, Emoto S, Sonoda H and Nakajima J. Adjuvant chemotherapy improves prognosis of resectable stage IV colorectal cancer: a comparative study using inverse probability of treatment weighting. *Ther Adv Med Oncol* 2019; 11: 1758835919838960.
- [62] Tournigand C, André T, Achille E, Lledo G, Flesh M, Mery-Mignard D, Quinaux E, Couteau C, Buyse M, Ganem G, Landi B, Colin P, Louvet C and de Gramont A. FOLFIRI followed by FOLF-*OX6* or the reverse sequence in advanced colorectal cancer: a randomized GERCOR study. *J Clin Oncol* 2004; 22: 229-237.
- [63] Franko J, Shi Q, Meyers JP, Maughan TS, Adams RA, Seymour MT, Saltz L, Punt CJA, Koopman M, Tournigand C, Tebbutt NC, Diaz-Rubio E, Souglakos J, Falcone A, Chibaudel B, Heinemann V, Moen J, De Gramont A, Sargent DJ and Grothey A; Analysis and Research in Cancers of the Digestive System (ARCAD) Group. Prognosis of patients with peritoneal metastatic colorectal cancer given systemic therapy: an analysis of individual patient data from prospective randomised trials from the Analysis and Research in Cancers of the Digestive System (ARCAD) database. *Lancet Oncol* 2016; 17: 1709-1719.
- [64] März L and Piso P. Treatment of peritoneal metastases from colorectal cancer. *Gastroenterol Rep (Oxf)* 2015; 3: 298-302.
- [65] Sugarbaker PH, Mora JT, Carmignani P, Stuart OA and Yoo D. Update on chemotherapeutic agents utilized for perioperative intraperitoneal chemotherapy. *Oncologist* 2005; 10: 112-122.
- [66] Liu Q, Jia Y, Tian J, Wang Z, Ye H, Yang J and Sun F. Comparative study of different interventional therapies for primary liver cancer. *World J Gastroenterol* 1997; 3: 231-233.
- [67] Abdalla EK, Vauthey JN, Ellis LM, Ellis V, Pollock R, Broglio KR, Hess K and Curley SA. Recurrence and outcomes following hepatic resection, radiofrequency ablation, and combined resection/ablation for colorectal liver metastases. *Ann Surg* 2004; 239: 818-825; discussion 825-817.
- [68] Ruers T, Punt C, Van Coevorden F, Pierie JP, Borel-Rinkes I, Ledermann JA, Poston G, Bechstein W, Lentz MA, Mauer M, Van Cutsem E, Lutz MP and Nordlinger B; EORTC Gastro-Intestinal Tract Cancer Group, Arbeitsgruppe Lebermetastasen und-tumoren in der Chirur-gischen Arbeitsgemeinschaft Onkologie (ALM-CAO) and the National Cancer Research Insti-tute Colorectal Clinical Study Group (NCRI CCSG). Radiofrequency ablation combined with systemic treatment versus systemic treat-ment alone in patients with non-resectable colorectal liver metastases: a randomized EORTC Intergroup phase II study (EORTC 40004). *Ann Oncol* 2012; 23: 2619-2626.
- [69] Aparicio T, Ghiringhelli F, Boige V, Le Malicot K, Taieb J, Bouché O, Phelip JM, François E, Borel C, Faroux R, Dahan L, Jacquot S, Genet D, Khemissa F, Suc E, Desseigne F, Texereau P, Lepage C and Bennouna J. Bevacizumab main-tenance versus no maintenance during che-motherapy-free intervals in metastatic colorec-tal cancer: a randomized phase III trial (PRODIGE 9). *J Clin Oncol* 2018; 36: 674-681.
- [70] Cunningham D, Humblet Y, Siena S, Khayat D, Bleiberg H, Santoro A, Bets D, Mueser M, Har-strick A, Verslype C, Chau I and Van Cutsem E. Cetuximab monotherapy and cetuximab plus irinotecan in irinotecan-refractory metastatic colorectal cancer. *N Engl J Med* 2004; 351: 337-345.
- [71] Folprecht G, Gruenberger T, Bechstein WO, Raab HR, Lordick F, Hartmann JT, Lang H, Frill-ing A, Stoehlmacher J, Weitz J, Konopke R, Stroszczyński C, Liersch T, Ockert D, Herrmann T, Goekkurt E, Parisi F and Köhne CH. Tumour response and secondary resectability of colorectal liver metastases following neoadju-vant chemotherapy with cetuximab: the CELIM randomised phase 2 trial. *Lancet Oncol* 2010; 11: 38-47.
- [72] Franke AJ, Skelton WP, Starr JS, Parekh H, Lee JJ, Overman MJ, Allegra C and George TJ. Im-munotherapy for colorectal cancer: a review of current and novel therapeutic approaches. *J Natl Cancer Inst* 2019; 111: 1131-1141.
- [73] Creasy JM, Sadot E, Koerkamp BG, Chou JF, Gonen M, Kemeny NE, Balachandran VP, King-ham TP, DeMatteo RP, Allen PJ, Blumgart LH, Jarnagin WR and D'Angelica MI. Actual 10-year survival after hepatic resection of colorectal liver metastases: what factors preclude cure? *Surgery* 2018; 163: 1238-1244.
- [74] Jaque D, Martínez Maestro L, Del Rosal B, Ha-ro-Gonzalez P, Benayas A, Plaza JL, Martín Ro-dríguez E and García Solé J. Nanoparticles for photothermal therapies. *Nanoscale* 2014; 6: 9494-9530.
- [75] Chen J, Ning C, Zhou Z, Yu P, Zhu Y, Tan G and Mao C. Nanomaterials as photothermal thera-peutic agents. *Prog Mater Sci* 2019; 99: 1-26.
- [76] Weissleder R. A clearer vision for in vivo imag-ing. *Nat Biotechnol* 2001; 19: 316-317.
- [77] Melancon MP, Lu W and Li C. Gold-based mag-neto/optical nanostructures: challenges for in vivo applications in cancer diagnostics and therapy. *MRS Bulletin* 2009; 34: 415-421.



## Photothermal therapy for metastatic CRC

- [78] Ntziachristos V, Yodh AG, Schnall M and Chance B. Concurrent MRI and diffuse optical tomography of breast after indocyanine green enhancement. *Proc Natl Acad Sci U S A* 2000; 97: 2767-2772.
- [79] Day ES, Morton JG and West JL. Nanoparticles for thermal cancer therapy. *J Biomech Eng* 2009; 131: 074001.
- [80] Vankayala R and Hwang KC. Near-infrared-light-activatable nanomaterial-mediated phototheranostic nanomedicines: an emerging paradigm for cancer treatment. *Adv Mater* 2018; 30: e1706320.
- [81] Hosseinzadeh H, Atyabi F, Varnamkhasti BS, Hosseinzadeh R, Ostad SN, Ghahremani MH and Dinarvand R. SN38 conjugated hyaluronic acid gold nanoparticles as a novel system against metastatic colon cancer cells. *Int J Pharm* 2017; 526: 339-352.
- [82] White SB, Kim DH, Guo Y, Li W, Yang Y, Chen J, Gogineni VR and Larson AC. Biofunctionalized hybrid magnetic gold nanoparticles as catalysts for photothermal ablation of colorectal liver metastases. *Radiology* 2017; 285: 809-819.
- [83] Kirui DK, Khalidov I, Wang Y and Batt CA. Targeted near-IR hybrid magnetic nanoparticles for in vivo cancer therapy and imaging. *Nanomedicine* 2013; 9: 702-711.
- [84] Parchur AK, Sharma G, Jagtap JM, Gogineni VR, LaViolette PS, Flister MJ, White SB and Joshi A. Vascular interventional radiology-guided photothermal therapy of colorectal cancer liver metastasis with theranostic gold nanorods. *ACS Nano* 2018; 12: 6597-6611.
- [85] Seo SH, Kim BM, Joe A, Han HW, Chen X, Cheng Z and Jang ES. NIR-light-induced surface-enhanced Raman scattering for detection and photothermal/photodynamic therapy of cancer cells using methylene blue-embedded gold nanorod@SiO<sub>2</sub> nanocomposites. *Biomaterials* 2014; 35: 3309-3318.
- [86] Goodrich GP, Bao L, Gill-Sharp K, Sang KL, Wang J and Payne JD. Photothermal therapy in a murine colon cancer model using near-infrared absorbing gold nanorods. *J Biomed Opt* 2010; 15: 018001.
- [87] Guo R, Zhang L, Qian H, Li R, Jiang X and Liu B. Multifunctional nanocarriers for cell imaging, drug delivery, and near-IR photothermal therapy. *Langmuir* 2010; 26: 5428-5434.
- [88] Azhdarzadeh M, Atyabi F, Saei AA, Varnamkhasti BS, Omidi Y, Fateh M, Ghavami M, Shanehsazzadeh S and Dinarvand R. Theranostic MUC-1 aptamer targeted gold coated superparamagnetic iron oxide nanoparticles for magnetic resonance imaging and photothermal therapy of colon cancer. *Colloids Surf B Biointerfaces* 2016; 143: 224-232.
- [89] Lee SM, Kim HJ, Kim SY, Kwon MK, Kim S, Cho A, Yun M, Shin JS and Yoo KH. Drug-loaded gold plasmonic nanoparticles for treatment of multidrug resistance in cancer. *Biomaterials* 2014; 35: 2272-2282.
- [90] Zhang R, Cheng K, Antaris AL, Ma X, Yang M, Ramakrishnan S, Liu G, Lu A, Dai H, Tian M and Cheng Z. Hybrid anisotropic nanostructures for dual-modal cancer imaging and image-guided chemo-thermo therapies. *Biomaterials* 2016; 103: 265-277.
- [91] Wang F, Liu P, Sun L, Li C, Petrenko VA and Liu A. Bio-mimetic nanostructure self-assembled from Au@Ag heterogeneous nanorods and phage fusion proteins for targeted tumor optical detection and photothermal therapy. *Sci Rep* 2014; 4: 6808.
- [92] Hirsch LR, Stafford RJ, Bankson JA, Sershen SR, Rivera B, Price RE, Hazle JD, Halas NJ and West JL. Nanoshell-mediated near-infrared thermal therapy of tumors under magnetic resonance guidance. *Proc Natl Acad Sci U S A* 2003; 100: 13549-13554.
- [93] Zharov VP, Galitovskaya EN, Johnson C and Kelly T. Synergistic enhancement of selective nanophotothermolysis with gold nanoclusters: potential for cancer therapy. *Lasers Surg Med* 2005; 37: 219-226.
- [94] Kim J, Park J, Kim H, Singha K and Kim WJ. Transfection and intracellular trafficking properties of carbon dot-gold nanoparticle molecular assembly conjugated with PEI-pDNA. *Biomaterials* 2013; 34: 7168-7180.
- [95] Xiaohua H, El-Sayed IH, Wei Q and El-Sayed MA. Cancer cell imaging and photothermal therapy in the near-infrared region by using gold nanorods. *J Am Chem Soc* 2006; 128: 2115-2120.
- [96] Hu M, Chen J, Li ZY, Au L, Hartland GV, Li X, Marquez M and Xia Y. Gold nanostructures: engineering their plasmonic properties for biomedical applications. *Chem Soc Rev* 2006; 35: 1084-1094.
- [97] Wang D, Xu Z, Yu H, Chen X, Feng B, Cui Z, Lin B, Yin Q, Zhang Z, Chen C, Wang J, Zhang W and Li Y. Treatment of metastatic breast cancer by combination of chemotherapy and photothermal ablation using doxorubicin-loaded DNA wrapped gold nanorods. *Biomaterials* 2014; 35: 8374-8384.
- [98] Porcel E, Liehn S, Remita H, Usami N, Kobayashi K, Furusawa Y, Le Sech C and Lacombe S. Platinum nanoparticles: a promising material for future cancer therapy? *Nanotechnology* 2010; 21: 85103.
- [99] Watanabe A, Kajita M, Kim J, Kanayama A, Takahashi K, Mashino T and Miyamoto Y. In vitro free radical scavenging activity of platinum

- nanoparticles. *Nanotechnology* 2009; 20: 455105.
- [100] AshaRani PV, Low Kah Mun G, Hande MP and Valiyaveetil S. Cytotoxicity and genotoxicity of silver nanoparticles in human cells. *ACS Nano* 2009; 3: 279-290.
- [101] Ott M, Gogvadze V, Orrenius S and Zhivotovsky B. Mitochondria, oxidative stress and cell death. *Apoptosis* 2007; 12: 913-922.
- [102] Manivannan K, Cheng CC, Anbazhagan R, Tsai HC and Chen JK. Fabrication of silver seeds and nanoparticle on core-shell Ag@SiO<sub>2</sub> nanohybrids for combined photothermal therapy and bioimaging. *J Colloid Interface Sci* 2019; 537: 604-614.
- [103] Fiorica C, Mauro N, Pitarresi G, Scialabba C, Palumbo FS and Giammona G. Double-network-structured graphene oxide-containing nanogels as photothermal agents for the treatment of colorectal cancer. *Biomacromolecules* 2017; 18: 1010-1018.
- [104] Einafshar E, Asl AH, Nia AH, Mohammadi M, Malekzadeh A and Ramezani M. New cyclodextrin-based nanocarriers for drug delivery and phototherapy using an irinotecan metabolite. *Carbohydr Polym* 2018; 194: 103-110.
- [105] Lu YJ, Lin PY, Huang PH, Kuo CY, Shalumon KT, Chen MY and Chen JP. Magnetic graphene oxide for dual targeted delivery of doxorubicin and photothermal therapy. *Nanomaterials (Basel)* 2018; 8.
- [106] Graham EG and Macneill CM. Quantifying folic acid-functionalized multi-walled carbon nanotubes bound to colorectal cancer cells for improved photothermal ablation. *Journal of Nanoparticle Research* 2013; 15: 1649.
- [107] Levi-Polyachenko NH, Merkel EJ, Jones BT, Carroll DL and Stewart JT. Rapid photothermal intracellular drug delivery using multiwalled carbon nanotubes. *Mol Pharm* 2009; 6: 1092-1099.
- [108] Tan A, Madani SY, Rajadas J, Pastorin G and Seifalian AM. Synergistic photothermal ablative effects of functionalizing carbon nanotubes with a POSS-PCU nanocomposite polymer. *J Nanobiotechnology* 2012; 10: 34.
- [109] Balandin AA, Ghosh S, Bao W, Calizo I, Teweldbrhan D, Miao F and Lau CN. Superior thermal conductivity of single-layer graphene. *Nano Lett* 2008; 8: 902-907.
- [110] Moon HK, Lee SH and Choi HC. In vivo near-infrared mediated tumor destruction by photothermal effect of carbon nanotubes. *ACS Nano* 2009; 3: 3707-3713.
- [111] Arsawang U, Saengsawang O, Rungrotmongkol T, Sornmee P, Wittayanarakul K, Remsungnen T and Hannongbua S. How do carbon nanotubes serve as carriers for gemcitabine transport in a drug delivery system? *J Mol Graph Model* 2011; 29: 591-596.
- [112] Bai J, Liu Y and Jiang X. Multifunctional PEG-GO/CuS nanocomposites for near-infrared chemo-photothermal therapy. *Biomaterials* 2014; 35: 5805-5813.
- [113] Liu X, Tao H, Yang K, Zhang S, Lee ST and Liu Z. Optimization of surface chemistry on single-walled carbon nanotubes for in vivo photothermal ablation of tumors. *Biomaterials* 2011; 32: 144-151.
- [114] Jastrzębska AM, Kurtycz P and Olszyna AR. Recent advances in graphene family materials toxicity investigations. *J Nanopart Res* 2012; 14: 1320.
- [115] Koo JS, Lee SY, Nam S, Azad MOK, Kim M, Kim K, Chae BJ, Kang WS and Cho HJ. Preparation of cupric sulfate-based self-emulsifiable nanocomposites and their application to the photothermal therapy of colon adenocarcinoma. *Biochem Biophys Res Commun* 2018; 503: 2471-2477.
- [116] Li KC, Chu HC, Lin Y, Tuan HY and Hu YC. PEGylated copper nanowires as a novel photothermal therapy agent. *ACS Appl Mater Interfaces* 2016; 8: 12082-12090.
- [117] Hessel CM, Pattani VP, Rasch M, Panthani MG, Koo B, Tunnell JW and Korgel BA. Copper selenide nanocrystals for photothermal therapy. *Nano Letters* 2011; 11: 2560-2566.
- [118] Shih YH, Luo TY, Chiang PF, Yao CJ, Lin WJ, Peng CL and Shieh MJ. EGFR-targeted micelles containing near-infrared dye for enhanced photothermal therapy in colorectal cancer. *J Control Release* 2017; 258: 196-207.
- [119] Chen G, Wang K, Zhou Y, Ding L, Ullah A, Hu Q, Sun M and Oupicky D. Oral nanostructured lipid carriers loaded with near-infrared dye for image-guided photothermal therapy. *ACS Appl Mater Interfaces* 2016; 8: 25087-25095.
- [120] Chen Y, Li H, Deng Y, Sun H, Ke X and Ci T. Near-infrared light triggered drug delivery system for higher efficacy of combined chemophotothermal treatment. *Acta Biomaterialia* 2017; 51: 374-392.
- [121] Peng CL, Shih YH, Lee PC, Hsieh TM, Luo TY and Shieh MJ. Multimodal image-guided photothermal therapy mediated by <sup>188</sup>Re-labeled micelles containing a cyanine-type photosensitizer. *ACS Nano* 2011; 5: 5594-5607.
- [122] Tsai MH, Peng CL, Yang SJ and Shieh MJ. Photothermal, targeting, theranostic near-infrared nanoagent with SN38 against colorectal cancer for chemothermal therapy. *Mol Pharm* 2017; 14: 2766-2780.
- [123] Lin CY and Shieh MJ. Near-infrared fluorescent dye-decorated nanocages to form grenade-like nanoparticles with dual control release for photothermal theranostics and chemotherapy. *Bioconjug Chem* 2018; 29: 1384-1398.
- [124] Yang X, Xue X, Luo Y, Lin TY, Zhang H, Lac D, Xiao K, He Y, Jia B, Lam KS and Li Y. Sub-100

## Photothermal therapy for metastatic CRC

- nm, long tumor retention SN-38-loaded photonic micelles for tri-modal cancer therapy. *J Control Release* 2017; 261: 297-306.
- [125] Cai Y, Liang P, Tang Q, Yang X, Si W, Huang W, Zhang Q and Dong X. Diketopyrrolopyrrole-triphenylamine organic nanoparticles as multi-functional reagents for photoacoustic imaging-guided photodynamic/photothermal synergistic tumor therapy. *ACS Nano* 2017; 11: 1054-1063.
- [126] Obiweluozor FO, Emechebe GA, Tiwari AP, Kim JY, Park CH and Kim CS. Short duration cancer treatment: inspired by a fast bio-resorbable smart nano-fiber device containing NIR lethal polydopamine nanospheres for effective chemo-photothermal cancer therapy. *Int J Nanomedicine* 2018; 13: 6375-6390.
- [127] Liu F, He X, Chen H, Zhang J, Zhang H and Wang Z. Gram-scale synthesis of coordination polymer nanodots with renal clearance properties for cancer theranostic applications. *Nat Commun* 2015; 6: 8003.
- [128] Xing Y, Li L, Ai X and Fu L. Polyaniline-coated upconversion nanoparticles with upconverting luminescent and photothermal conversion properties for photothermal cancer therapy. *Int J Nanomedicine* 2016; 11: 4327-4338.
- [129] Zhou J, Lu Z, Zhu X, Wang X, Liao Y, Ma Z and Li F. NIR photothermal therapy using polyaniline nanoparticles. *Biomaterials* 2013; 34: 9584-9592.
- [130] Kelkar SS, McCabe-Lankford E, Albright R, Harrington P and Levi-Polyachenko NH. Dual wavelength stimulation of polymeric nanoparticles for photothermal therapy. *Lasers Surg Med* 2016; 48: 893-902.
- [131] MacNeill CM, Coffin RC, Carroll DL and Levi-Polyachenko NH. Low band gap donor-acceptor conjugated polymer nanoparticles and their NIR-mediated thermal ablation of cancer cells. *Macromol Biosci* 2013; 13: 28-34.
- [132] Jung HS, Verwilst P, Sharma A, Shin J, Sessler JL and Kim JS. Organic molecule-based photothermal agents: an expanding photothermal therapy universe. *Chem Soc Rev* 2018; 47: 2280-2297.
- [133] Li N, Li T, Hu C, Lei X, Zuo Y and Han H. Targeted near-infrared fluorescent turn-on nanoprobe for activatable imaging and effective phototherapy of cancer cells. *ACS Appl Mater Interfaces* 2016; 8: 15013-15023.
- [134] Lovell JF, Jin CS, Huynh E, Jin H, Kim C, Rubinstein JL, Chan WC, Cao W, Wang LV and Zheng G. Porphyrinsomes nanovesicles generated by porphyrin bilayers for use as multimodal biophotonic contrast agents. *Nat Mater* 2011; 10: 324-332.
- [135] Jiang Q, Luo Z, Men Y, Yang P, Peng H, Guo R, Tian Y, Pang Z and Yang W. Red blood cell membrane-camouflaged melanin nanoparticles for enhanced photothermal therapy. *Biomaterials* 2017; 143: 29-45.
- [136] Lee DY, Kim JY, Lee Y, Lee S, Miao W, Kim HS, Min JJ and Jon S. Black pigment gallstone inspired platinum-chelated bilirubin nanoparticles for combined photoacoustic imaging and photothermal therapy of cancers. *Angew Chem Int Ed Engl* 2017; 56: 13684-13688.
- [137] Pressly ED, Rossin R, Hagooly A, Fukukawa K, Messmore BW, Welch MJ, Wooley KL, Lamm MS, Hule RA, Pochan DJ and Hawker CJ. Structural effects on the biodistribution and positron emission tomography (PET) imaging of well-defined (64)Cu-labeled nanoparticles comprised of amphiphilic block graft copolymers. *Biomacromolecules* 2007; 8: 3126-3134.
- [138] Hoang B, Lee H, Reilly RM and Allen C. Noninvasive monitoring of the fate of 111In-labeled block copolymer micelles by high resolution and high sensitivity microSPECT/CT imaging. *Mol Pharm* 2009; 6: 581-592.
- [139] Yang X, Stein EW, Ashkenazi S and Wang LV. Nanoparticles for photoacoustic imaging. *Wiley Interdiscip Rev Nanomed Nanobiotechnol* 2009; 1: 360-368.
- [140] Chou SW, Shau YH, Wu PC, Yang YS, Shieh DB and Chen CC. In vitro and in vivo studies of FePt nanoparticles for dual modal CT/MRI molecular imaging. *J Am Chem Soc* 2010; 132: 13270-13278.
- [141] Wang L, Shi J, Jia X, Liu R, Wang H, Wang Z, Li L, Zhang J, Zhang C and Zhang Z. NIR-/pH-Responsive drug delivery of functionalized single-walled carbon nanotubes for potential application in cancer chemo-photothermal therapy. *Pharm Res* 2013; 30: 2757-2771.
- [142] Kirui DK, Koay EJ, Guo XJ, Cristini V, Shen HF and Ferrari M. Tumor vascular permeabilization using localized mild hyperthermia to improve macromolecule transport. *Nanomedicine* 2014; 10: 1487-1496.
- [143] Zandberg WF, Bakhtiari AB, Erno Z, Hsiao D, Gates BD, Claydon T and Branda NR. Photothermal release of small molecules from gold nanoparticles in live cells. *Nanomedicine* 2012; 8: 908-915.
- [144] Giacomini KM, Huang SM, Tweedie DJ, Benet LZ, Brouwer KL, Chu X, Dahlin A, Evers R, Fischer V, Hillgren KM, Hoffmaster KA, Ishikawa T, Keppler D, Kim RB, Lee CA, Niemi M, Polli JW, Sugiyama Y, Swaan PW, Ware JA, Wright SH, Yee SW, Zamek-Gliszczynski MJ and Zhang L. Membrane transporters in drug development. *Nat Rev Drug Discov* 2010; 9: 215-236.
- [145] Bechet D, Couleaud P, Frochot C, Viriot ML, Guillemin F and Barberi-Heyob M. Nanoparti-

## Photothermal therapy for metastatic CRC

- cles as vehicles for delivery of photodynamic therapy agents. *Trends Biotechnol* 2008; 26: 612-621.
- [146] Li WT. Nanotechnology-based strategies to enhance the efficacy of photodynamic therapy for cancers. *Curr Drug Metab* 2009; 10: 851-860.
- [147] DeRosa M. Photosensitized singlet oxygen and its applications. *Coord Chem Rev* 2002; 233-234: 351-371.
- [148] Tardivo JP, Del Giglio A, de Oliveira CS, Gabrielli DS, Junqueira HC, Tada DB, Severino D, de Fátima Turchiello R and Baptista MS. Methylene blue in photodynamic therapy: from basic mechanisms to clinical applications. *Photodiagnosis Photodyn Ther* 2005; 2: 175-191.
- [149] Muroto K, Tsuno NH, Kawai K, Sasaki K, Honjo K, Kaneko M, Hiyoshi M, Tada N, Nirei T, Sunami E, Takahashi K and Kitayama J. SN-38 overcomes chemoresistance of colorectal cancer cells induced by hypoxia, through HIF1 $\alpha$ . *Anticancer Res* 2012; 32: 865-872.
- [150] Peng HS and Chiu DT. Soft fluorescent nanomaterials for biological and biomedical imaging. *Chem Soc Rev* 2015; 44: 4699-4722.