

University of Groningen

IgA-epidermolysis bullosa acquisita associated with lyme borreliosis

Smits, Daniela R.Petermann; Shadid, Nadia H.; Goossens, Valère J.; Diercks, Gilles F.H.; Steijlen, Peter M.; Tervaert, Jan Willem Cohen

Published in:
Immunome Research

DOI:
[10.4172/1745-7580.1000066](https://doi.org/10.4172/1745-7580.1000066)

IMPORTANT NOTE: You are advised to consult the publisher's version (publisher's PDF) if you wish to cite from it. Please check the document version below.

Document Version
Publisher's PDF, also known as Version of record

Publication date:
2013

[Link to publication in University of Groningen/UMCG research database](#)

Citation for published version (APA):

Smits, D. R. P., Shadid, N. H., Goossens, V. J., Diercks, G. F. H., Steijlen, P. M., & Tervaert, J. W. C. (2013). IgA-epidermolysis bullosa acquisita associated with lyme borreliosis: A case report. *Immunome Research*, 9(1), [1000066]. <https://doi.org/10.4172/1745-7580.1000066>

Copyright

Other than for strictly personal use, it is not permitted to download or to forward/distribute the text or part of it without the consent of the author(s) and/or copyright holder(s), unless the work is under an open content license (like Creative Commons).

The publication may also be distributed here under the terms of Article 25fa of the Dutch Copyright Act, indicated by the "Taverne" license. More information can be found on the University of Groningen website: <https://www.rug.nl/library/open-access/self-archiving-pure/taverne-amendment>.

Take-down policy

If you believe that this document breaches copyright please contact us providing details, and we will remove access to the work immediately and investigate your claim.

Downloaded from the University of Groningen/UMCG research database (Pure): <http://www.rug.nl/research/portal>. For technical reasons the number of authors shown on this cover page is limited to 10 maximum.

IgA-Epidermolysis Bullosa Acquisita Associated with Lyme Borreliosis: A Case Report

Daniela R Petermann Smits¹, Nadia H Shadid², Valère J Goossens³, Gilles FH Diercks⁴, Peter M Steijlen² and Jan Willem Cohen Tervaert^{1*}

¹Department of Internal Medicine, Division of Clinical and Experimental Immunology, Maastricht University Medical Center, PO Box 5800, 6202 AZ Maastricht, The Netherlands

²Department of Dermatology, Maastricht University Medical Center, PO Box 5800, 6202 AZ Maastricht, The Netherlands, GROW Research Institute for Oncology and Developmental Biology, Maastricht University, Maastricht, The Netherlands

³Department of Medical Microbiology, Maastricht University Medical Center, 6202 AZ Maastricht, The Netherlands

⁴Center for Blistering Diseases, Department of Dermatology, University Hospital Groningen, PO Box 30.001, 9700 RB Groningen, The Netherlands

Introduction

We report a woman who developed IgA-epidermolysis bullosa acquisita (IgA-EBA) after a *Borrelia burgdorferi* infection. IgA-EBA is an autoimmune bullous disease with exclusive IgA deposition along the epidermal basement membrane zone. Cases with an association with drugs, rheumatoid arthritis, Hodgkin's disease and/or hypertension [1] have been described but an association with Lyme borreliosis has never been reported.

Case Report

In 2007, a 39-year old Caucasian woman developed an erythematous lesion above her left breast, which evolved into an erythematous, concentric spreading and raised five-centimetre ring, leaving a vesicle filled with clear liquid in the centre. Despite living in an endemic region for ticks and having dealt with the removal of ticks in the past, she had not noticed a tick bite at the site where the lesion developed. During the six months that followed, several vesicular lesions on the left breast and shoulder developed. In 2008, lesions spread to the whole body, except for the face, the palms and the soles. In November 2008, a biopsy of the skin was suggestive for urticarial vasculitis. Treatment with clobetasol propionate cream 0,05% and levocetirizine dihydrochloride was started but was not effective.

We saw the patient in October 2009. Serology for *Borrelia burgdorferi* was strongly positive and these results were confirmed by a positive IgG and IgM blot. She was treated with doxycycline 100 mg twice daily for four weeks with no improvement. Treatment with hydroxychloroquine was started without a beneficial effect. Because of progression of the lesions in the facial area (Figure 1) dapsone 100 mg was started. A biopsy showed a subepidermal blister with a

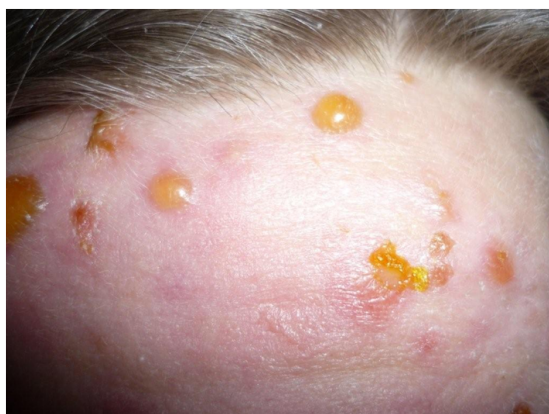

Figure 1: IgA-epidermolysis bullosa acquisita. Development of vesicles and bullae on the previously eruption-free facial area, after treatment with hydroxychloroquine.

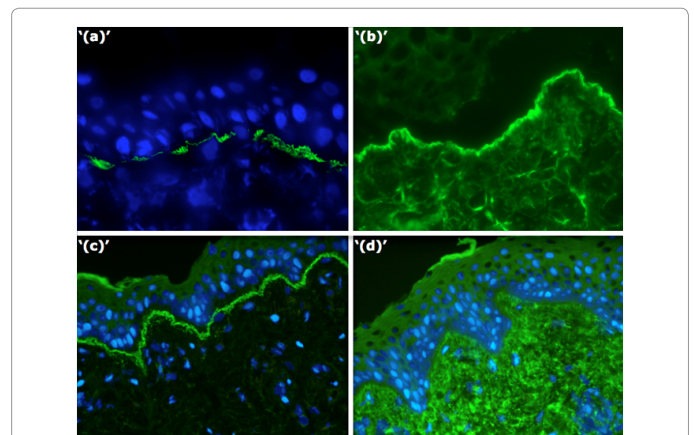


Figure 2: IgA-epidermolysis bullosa acquisita. Immunofluorescence analysis. (a) Deposition of linear IgA in a u-serrated pattern along the epidermal basement membrane in patient skin. (b) Binding of patient serum IgA autoantibodies to the dermal side of salt-split skin. (c) Patient serum IgA antibodies bind to laminin-332 knockout skin. (d) Patient serum IgA antibodies do not bind to type VII collagen knockout skin.

predominance of neutrophils. Immunofluorescence revealed a linear IgA deposition along the epidermal basement membrane, in a u-serrated pattern [2] (Figure 2). Indirect immunofluorescence on salt-split skin showed binding of IgA to the dermal side of the split. The combination of a linear u-serrated deposition pattern in patient skin and a dermal binding of antibodies on salt-split skin suggest epidermolysis bullosa [3]. Furthermore, knockout skin substrates [4], lacking laminin-332 showed binding of patient's IgA along the basement membrane, whereas her IgA did not bind to the type VII collagen knockout skin.

A diagnosis of IgA-EBA was made. Daily prednisone 25 mg was started and dapsone 100 mg was continued. During follow up

***Corresponding author:** Jan Willem Cohen Tervaert, Department of Internal Medicine, Division of Clinical and Experimental Immunology, Maastricht University Medical Center, PO Box 5800, 6202 AZ Maastricht, The Netherlands, E-mail: jw.cohentervaert@maastrichtuniversity.nl

Received September 11, 2013; **Accepted** September 30, 2013; **Published** October 15, 2013

Citation: Petermann Smits DR, Shadid NH, Goossens VJ, Diercks GFH, Steijlen PM, et al. (2013) IgA-Epidermolysis Bullosa Acquisita Associated with Lyme Borreliosis: A Case Report. Immunome Res 9: 066. doi: [10.4172/1745-7580.1000066](http://dx.doi.org/10.4172/1745-7580.1000066)

Copyright: © 2013 Petermann Smits DR, et al. This is an open-access article distributed under the terms of the Creative Commons Attribution License, which permits unrestricted use, distribution, and reproduction in any medium, provided the original author and source are credited.

prednisone could not be decreased below 10 mg daily because of recurrence of the dermal lesions.

Discussion

Lyme borreliosis is an inflammatory disease transmitted by three different tick species of the spirochete *Borrelia burgdorferi* [5]. Despite the fact that *B. burgdorferi* is very susceptible to antibiotics, some patients develop chronic persistent disease after treatment.

We postulate that in our patient chronic Lyme borreliosis may have caused an autoimmune activation, resulting in the development of IgA-EBA. The development of autoimmunity could be mediated directly or indirectly by intracellular persistence of *B. burgdorferi* [6]. Alternatively, there might be a homology between type VII collagen and *Borrelia* proteins, leading to molecular mimicry [5]. Further studies are needed to evaluate the possibility of *Borrelia burgdorferi* being a causative agent for IgA-EBA.

References

1. Vodegel RM, de Jong MCJM, Pas HH, Jonkman MF (2002) IgA-mediated epidermolysis bullosa acquisita: Two cases and review of the literature. *J Am Acad Dermatol* 47:919-25.
2. Buijsrogge JJA, Diercks GFH, Pas HH, Jonkman MF (2011) The many faces of epidermolysis bullosa acquisita after serration pattern analysis by direct immunofluorescence microscopy. *Br J Dermatol* 165: 92-8.
3. Vodegel RM, Jonkman MF, Pas HH, de Jong MC (2004) U-serrated immunodeposition pattern differentiates type VII collagen targeting bullous diseases from other subepidermal bullous autoimmune diseases. *Br J Dermatol* 151:112-8.
4. Vodegel RM, de Jong MC, Pas HH, Yancey KB, Jonkman MF (2003) Anti-epiligrin cicatricial pemphigoid and epidermolysis bullosa acquisita: differentiation by use of indirect immunofluorescence microscopy. *J Am Acad Dermatol* 48: 542-7.
5. Singh SK, Girschick HJ (2004) Lyme borreliosis: from infection to autoimmunity. *Clin Microbiol Infect* 10: 598-614.
6. Girschick HJ, Morbach H, Tappe D (2009) Treatment of Lyme borreliosis. *Arthritis Res Ther* 11: 258.

Citation: Petermann Smits DR, Shadid NH, Goossens VJ, Diercks GFH, Steijlen PM, et al. (2013) IgA-Epidermolysis Bullosa Acquisita Associated with Lyme Borreliosis: A Case Report. *Immunome Res* 9: 066. doi: [10.4172/1745-7580.1000066](https://doi.org/10.4172/1745-7580.1000066)

Submit your next manuscript and get advantages of OMICS Group submissions


Unique features:

- User friendly/feasible website-translation of your paper to 50 world's leading languages
- Audio Version of published paper
- Digital articles to share and explore

Special features:

- 250 Open Access Journals
- 20,000 editorial team
- 21 days rapid review process
- Quality and quick editorial, review and publication processing
- Indexing at PubMed (partial), Scopus, EBSCO, Index Copernicus and Google Scholar etc
- Sharing Option: Social Networking Enabled
- Authors, Reviewers and Editors rewarded with online Scientific Credits
- Better discount for your subsequent articles

Submit your manuscript at: <http://www.omicsonline.org/submission>



Reproduced with permission of the copyright owner. Further reproduction prohibited without permission.