

## MINI-FOCUS ISSUE: HEART FAILURE

ADVANCED

## CASE REPORT: CLINICAL CASE

# A Unique Case of Systemic Lupus Erythematosus Myocarditis Complicated by Plasmapheresis-Responsive Cardiogenic Shock



Carson Smith, MD,<sup>a</sup> Maya Guglin, MD, PhD,<sup>b</sup> Rachel E. Dougherty, MD,<sup>c</sup> Roopa A. Rao, MBBS<sup>d</sup>

## ABSTRACT

A 25-year-old woman with systemic lupus erythematosus complicated by biventricular failure with a history of multiple admissions presented with cardiogenic shock unresponsive to steroids, intravenous immunoglobulin, cyclophosphamide, and required extra-corporeal membrane oxygenation. Left ventricular function eventually recovered after plasmapheresis. (**Level of Difficulty: Advanced.**) (J Am Coll Cardiol Case Rep 2020;2:2376-80) © 2020 The Authors. Published by Elsevier on behalf of the American College of Cardiology Foundation. This is an open access article under the CC BY-NC-ND license (<http://creativecommons.org/licenses/by-nc-nd/4.0/>).

A 25-year-old female with a medical history of systemic lupus erythematosus (SLE) initially presented at age 17 with serositis, arthritis, and malar rash. She had elevated antinuclear antibody, anti-RO, anti-La, anti-Smith, anti-ribonucleoprotein, and double-stranded DNA (dsDNA) antibodies and was started on prednisone, mycophenolate, and hydroxychloroquine therapy. Lymph

node and renal biopsy results (**Figures 1 and 2**) showed lupus lymphadenitis and lupus nephritis, respectively.

Her first episode of cardiogenic shock occurred when she was 20 years of age and required an intra-aortic balloon pump with dobutamine support. She was treated with methylprednisolone and cyclophosphamide and showed improvement in the left ventricular ejection fraction (LVEF) to 40% immediately after the completion of treatment. Follow up was inconsistent. Two years later, she delivered a healthy baby at 33 weeks and her LVEF was around 55% on prednisone and hydroxychloroquine maintenance therapy.

Six months after the birth of her child, she experienced her second episode of cardiogenic shock, with a cardiac index of 1.7 l/m<sup>2</sup>/min and LVEF of 20%. She was initially started on inotropes and solumedrol, but her condition declined with further deterioration of

## LEARNING OBJECTIVES

- To present a unique case of SLE myocarditis complicated by cardiogenic shock.
- To demonstrate efficacy of aggressive therapies including plasmapheresis with IVIG with normalization of EF over 3 separate SLE flares.

From the <sup>a</sup>Department of Internal Medicine, Indiana University School of Medicine, Indianapolis, Indiana, USA; <sup>b</sup>Division of Cardiology, Krannert Institute of Cardiology at Indiana University School of Medicine, Indianapolis, Indiana, USA; <sup>c</sup>Department of Pathology, Indiana University School of Medicine, Indianapolis, Indiana, USA; and the <sup>d</sup>Division of Cardiology, Krannert Institute of Cardiology at Indiana University School of Medicine, Indianapolis, Indiana, USA.

The authors attest they are in compliance with human studies committees and animal welfare regulations of the authors' institutions and Food and Drug Administration guidelines, including patient consent where appropriate. For more information, visit the [Author Center](#).

Manuscript received July 2, 2020; revised manuscript received September 14, 2020, accepted September 22, 2020.

LVEF to 5% to 10%. She was started on plasmapheresis with immediate improvement in her overall clinical condition and hemodynamic stability. Her LVEF improved to 20% at the end of hospitalization. Follow-up was inconsistent due to noncompliance.

Ten months later, she once again presented with cardiogenic shock with LVEF 10% to 15% and cardiac index of 1.3 l/m<sup>2</sup>/min (Video 1A). Laboratory values showed low complement levels and elevated dsDNA antibody titers. Endomyocardial biopsy and cardiac magnetic resonance (CMR) images were nondiagnostic (Figures 3 and 4).

### MEDICAL HISTORY

SLE was complicated by lupus myocarditis, serositis, and renal membranous glomerulopathy; and hypertension, asthma, and fibromyalgia.

### DIFFERENTIAL DIAGNOSIS

Diagnosis included lupus myocarditis, versus other immune-mediated myocarditis, viral myocarditis, and familial cardiomyopathy.

### INVESTIGATIONS

Both C3 complement 23 mg/dl (normal: 65 to 180 mg/dl) and C4 complement 3 mg/dl (normal: 13 to 52 mg/dl) levels were low. Anti-dsDNA antibody titer levels were elevated to 72 IU/ml (0 to 9.9 IU/ml). ANA was positive

at a 1:2,560 dilution. Cardiac markers were not elevated. Erythrocyte sedimentation rate was within normal limits. Endomyocardial biopsy and CMR images were nondiagnostic (Figures 3 and 4).

### MANAGEMENT

The patient was critically ill with fulminant lupus myocarditis on presentation and was taken to the catheterization laboratory initially with the intention of placing an Impella (Abiomed, Danvers, Massachusetts) for mechanical cardiac support. However, the patient went into pulseless electrical activity arrest during Impella placement, requiring venoarterial extracorporeal membrane oxygenation (VA-ECMO) support. Cardiac transplantation was considered; however, due to the patient's history of noncompliance and poor social support, evaluation of transplantation was not pursued. Initial efforts to wean her from ECMO were unsuccessful despite aggressive immunomodulation with methylprednisolone, intravenous immunoglobulin (IVIG), and cyclophosphamide. Hence treatment was escalated to plasmapheresis. However, after she completed 5 cycles of plasmapheresis, her EF almost normalized, allowing successful ECMO decannulation (Video 1B). Approximately 10 days later, she again decompensated, with decline in LVEF to 10% (Video 1C). This time, plasmapheresis was started immediately, and after 2 sessions of plasmapheresis, her EF improved to 44%. She successfully completed a total of 5 cycles of plasmapheresis with sustained improvement in EF without further decompensation. All LVEF measurements during decompensations are shown in Figure 5.

### DISCUSSION

SLE is an autoimmune disorder classically presenting with skin, joint, and kidney injury. Cardiac involvement has been documented, ranging from 10% to 57% from clinical series autopsy reports of steroid-naïve patients (1,2). The prevalence of myocarditis decreased from 6% to 7% clinically and on autopsy after the introduction of steroids (2). Lupus myocarditis uncommonly presents with heart failure as the dominant clinical feature, especially with fulminant cardiogenic shock requiring mechanical circulatory support. This paper reports a therapeutically challenging case in which a patient required full circulatory support with VA-ECMO.

This case is unusual, if not unique. The following features make it stand out: 1) the patient's heart

### ABBREVIATIONS AND ACRONYMS

ECMO = extra-corporeal membrane oxygenation

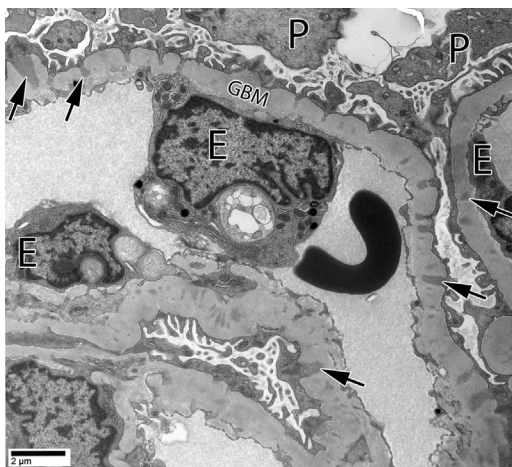
IVIG = intravenous immunoglobulin

LVEF = left ventricular ejection fraction

SLE = systemic lupus erythematosus

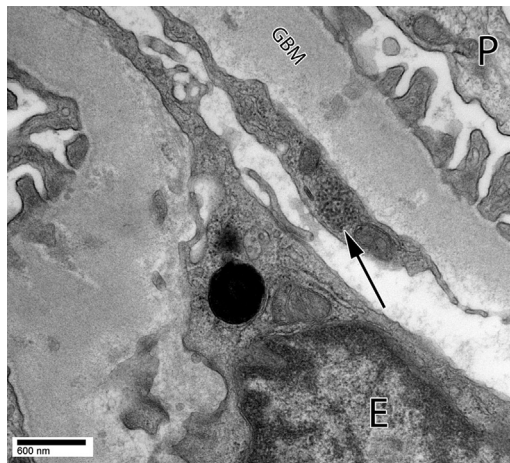
VA-ECMO = venoarterial extracorporeal membrane oxygenation

**FIGURE 1** Electron Microscopy of Renal Biopsy Demonstrating Electron-Dense Deposits Along the Glomerular Basement Membrane in Both the Subepithelial and Intramembranous Locations



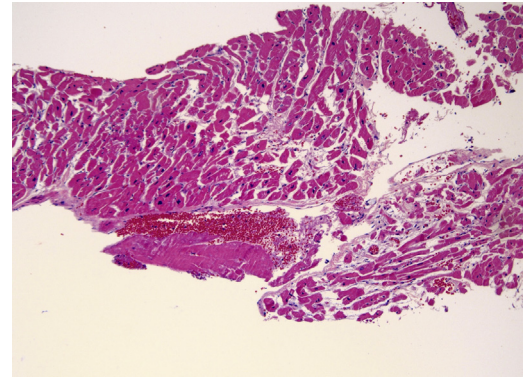
Electron dense deposits (arrows) are detected ultrastructurally along glomerular basement membranes (GBM) in subepithelial and intramembranous locations. E = glomerular endothelial cell; P = podocyte.

**FIGURE 2** A Tubuloreticular Inclusion Was Found in a Glomerular Endothelial Cell



A tubuloreticular inclusion (arrow) was found in a glomerular endothelial cell. Abbreviations as in Figure 1.

**FIGURE 3** Endomyocardial Biopsy Shows Moderate to Marked Myocyte Hypertrophy Without Inflammatory Infiltrates or Myocyte Necrosis (10× magnification)



No endothelial swelling, viral inclusions, or toxoplasma inclusions were identified. The direct immunofluorescence for IgG, IgA, IgM, C3, and C1q was negative. Indirect immunofluorescence for C4d was also negative. Immunohistochemical staining for CD4 and CD68 was not performed due to lack of visible lymphocytic or histiocytic inflammation.

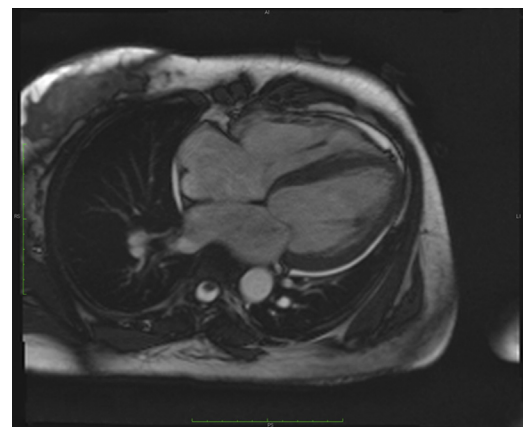failure was the dominant presentation, with minimal involvement of other systems; 2) recurrent cardiogenic shock required VA-ECMO support; 3) Relapses of severe systolic dysfunction occurred, with multiple episodes of partial or full recovery between; and 4) she was resistant to high-dose steroids, IVIG, and cyclophosphamide therapy but responded impressively to plasmapheresis.

This patient had 2 separate endomyocardial biopsies: neither of which revealed the classic inflammatory infiltrate in association with myocyte degeneration (3). In the most contemporary published series of endomyocardial biopsies of serology-proven lupus patients with decreased LVEF, none of the relevant samples had features characteristic for lupus myocarditis. Findings included interstitial fibrosis, myocyte hypertrophy, and mild lymphocytic and macrophage infiltration without clear evidence of myocarditis (3). Therefore, there is growing evidence that CMR imaging with late gadolinium enhancement may be a better diagnostic modality for lupus myocarditis (4).

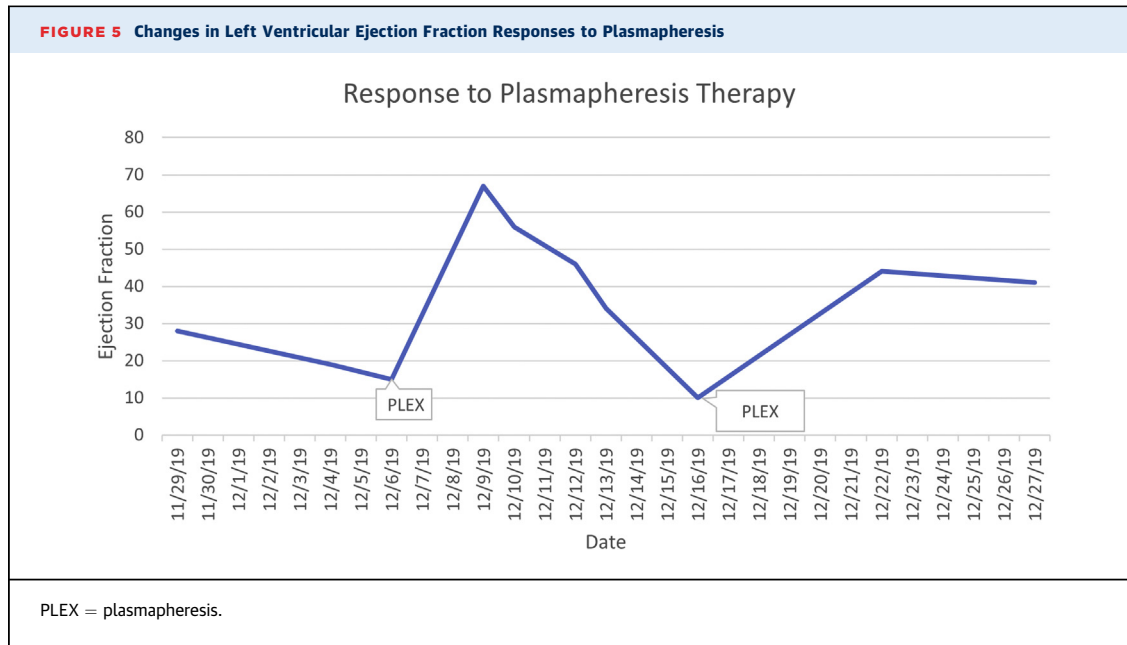
Most published case reports of cardiogenic shock attributed to lupus myocarditis have positive outcomes, whereas case series have generally resulted in worse outcomes (5-8). This may suggest selection bias and underdiagnosis; thus, not reflecting a true extent of the disease. Additionally, the role of cardiac transplantation in systemic disorders such as SLE

remains controversial; limited cases in the medical literature have reported favorable outcomes and could be considered in resistant cases such as the one presented here (9).

**FIGURE 4** Cardiac CMR Images Show Biventricular Dilation With Severely Decreased Biventricular Systolic Function (Left Ventricular Ejection Fraction = 23%; Right Ventricular Ejection Fraction = 21%)



There was no late gadolinium enhancement to suggest myocardial scarring or fibrosis, infiltration, or inflammation. Findings are most consistent with nonischemic dilated cardiomyopathy.



### FOLLOW-UP

The patient was followed in clinic as an outpatient and was maintained on oral steroids, and she completed the Euro-Lupus regimen of cyclophosphamide and received 2 doses of rituximab as an outpatient. After discharge, the patient’s anti-dsDNA and complement were monitored every 2 to 3 months, and anti-dsDNA remained mildly elevated, while the complement level has normalized. At 6 months’ follow-up, her EF remained at 53% (Video 1D) without recurrent hospitalization since her last admission requiring VA-ECMO.

### CONCLUSIONS

The success with this patient illustrates the fact that the management of lupus myocarditis complicated by cardiogenic shock should include aggressive

treatment plasmapheresis if there is no immediate improvement with immunosuppression. In this patient, there was recovery of cardiac function only after plasmapheresis. Finally, the role of cardiac transplantation in patients with connective tissue disease remains contested in the medical literature; however, it could be a consideration for patients with recurrent cardiogenic shock.

### AUTHOR DISCLOSURES

All authors have reported that they have no relationships relevant to the contents of this paper to disclose.

**ADDRESS FOR CORRESPONDENCE:** Dr. Roopa Rao, Division of Cardiology, Krannert Institute of Cardiology at Indiana University School of Medicine, 1801, N Senate Blvd, MPC II, Suite 2000, Indianapolis, Indiana 46202, USA. E-mail: rrao@iuhealth.org.

### REFERENCES

1. Appenzeller S, Pineau CA, Clarke AE. Acute lupus myocarditis: clinical features and outcome. *Lupus* 2011;20:981-8.
2. Wijetunga M, Rockson S. Myocarditis in systemic lupus erythematosus. *Am J Med* 2002;113:419-23.
3. Gartshteyn Y, Tamargo M, Fleischer S, et al. Endomyocardial biopsies in the diagnosis of myocardial involvement in systemic lupus erythematosus. *Lupus* 2020;29:199-204.
4. Mavrogeni S, Koutsogeorgopoulou L, Markousis-Mavrogenis G, et al. Cardiovascular magnetic resonance detects silent heart disease missed by echocardiography in systemic lupus erythematosus. *Lupus* 2018;27:564-71.
5. Du Toit R, Herbst PG, van Rensburg A, du Plessis LM, Reuter H, Doubell AF. Clinical features and outcome of lupus myocarditis in the Western Cape, South Africa. *Lupus* 2017;26:38-47.
6. Tanwani J, Tselios K, Gladman DD, Su J, Urowitz MB. Lupus myocarditis: a single center experience and a comparative analysis of

observational cohort studies. *Lupus* 2018;27:1296-302.

7. Zawadowski GM, Klarich KW, Moder KG, Edwards WD, Cooper LT Jr. A contemporary case series of lupus myocarditis. *Lupus* 2012;21:1378-84.


8. Zhang L, Zhu YL, Li MT, et al. Lupus myocarditis: a case-control study from China. *Chin Med J (Engl)* 2015;128:2588-94.

9. Tariq S, Garg A, Gass A, Aronow WS. Myocarditis due to systemic lupus erythematosus associated with cardiogenic shock. *Arch Med Sci* 2018;14:460-2.

---

**KEY WORDS** autoimmune, cardiomyopathy, systolic heart failure

---

 **APPENDIX** For supplemental videos, please see the online version of this paper.