

Original Research Article

Total hip arthroplasty in ankylosing spondylitis in a tertiary care hospital: a prospective cohort study

Pervez Ahsan*, Israt Jahan, Abul Khair

Department of Orthopedic Surgery, Ibn Sina Medical College Hospital, Dhaka, Bangladesh

Received: 23 December 2022

Revised: 27 January 2023

Accepted: 30 January 2023

***Correspondence:**

Dr. Pervez Ahsan,

E-mail: pervezahsan60@yahoo.com

Copyright: © the author(s), publisher and licensee Medip Academy. This is an open-access article distributed under the terms of the Creative Commons Attribution Non-Commercial License, which permits unrestricted non-commercial use, distribution, and reproduction in any medium, provided the original work is properly cited.

ABSTRACT

Background: Ankylosing spondylitis is a chronic inflammatory-type arthritis that forms part of the group of spondyloarthritides. It primarily affects the spine and pelvis but peripheral arthritis and enthesitis are also common features. Onset of AS often occurs at a relatively young age and that is accepted as a greater risk of hip involvement. THA in AS patients is a challenging procedure owing to multiple factors. The aim of this study was to evaluate the clinical, radiological & functional outcomes of total hip arthroplasty among patients with Ankylosing Spondylitis.

Methods: This was a prospective cohort study and was conducted in the Department of Orthopaedic Surgery of Ibn Sina Medical College Hospital, Dhaka, Bangladesh during the period from June, 2021 to May, 2022. In this study we included fifty patients with ankylosing spondylitis who underwent total hip arthroplasty.

Result: In our study we found the highest prevalence (36%) was present in aged between 31-40 years old. The mean±SD of age among patients was (37±12). We found the mean±SD of Harris hip score was 44.2±12.3 & 87.2±17.4 during preoperative & postoperative phase respectively.

Conclusions: In our study, we found that total hip arthroplasty is a safe and effective treatment of advanced hip involvement in patients with AS. It results in significant improvements in objective outcome measures such as HHS, patient mobility & reduced the difficulty level of patients in their day-to-day activities.

Keywords: Ankylosing spondylitis, Radiologic, Functional outcome, THA

INTRODUCTION

Ankylosing spondylitis (AS) is a chronic inflammatory-type arthritis that forms part of the group of spondyloarthritides. It primarily affects the spine and pelvis but peripheral arthritis and enthesitis are also common features. Approximately 0.1% to 1.8% of people are affected.¹ Severe disability and functional impairment can result rapidly due to a combination of axial spine and hip involvement.¹ Ankylosing spondylitis (AS) is a prototype of seronegative spondyloarthropathies and characterized by progressive erosion of affected joints as a result of inflammation.² Onset of AS often occurs at a relatively

young age and that is accepted as a greater risk of hip involvement. In addition to hip involvement, spine stiffness and intra-thoracic problems can cause severe disability in AS patients.³ The incidence of hip involvement in AS is between 30-50% of patients and 47-90% of patients having such involvement have it bilaterally.⁴⁻⁶ The incidence of both hip joints involvement in AS are involved in nearly 90% of patients who have hip disease. Hip joint involvement in AS results in severe disabling changes in function, posture, and gait.⁷ Disease-modifying anti-rheumatic drugs (DMARDs) such as anti-tumour necrosis factor (TNF) agents and sulfasalazine and methotrexate can slow the progression of the disease but

they have a limited role in treating advanced established arthritis of the joints and hip problems.⁸⁻¹⁰ Standard treatment option for advanced hip disease is total hip arthroplasty (THA).

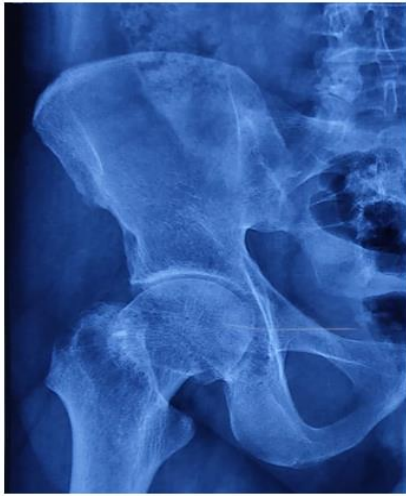

Figure 1: Stage II.

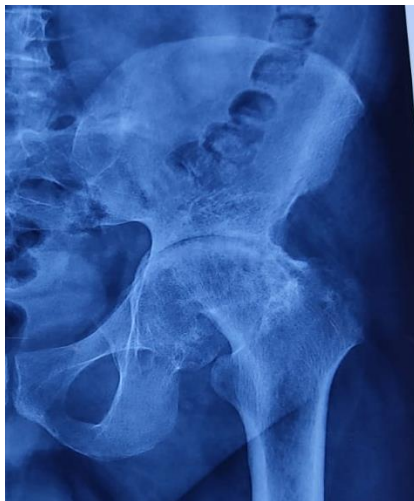

Figure 2: Stage III

Indications of THA are refractory pain, disability and radiologic evidence of damage in hips, regardless of age.^{4,5} When painful degenerative changes occur in the hip, (THA) has been shown to alleviate pain and improve function in AS patients.¹¹ Total hip arthroplasty in AS patients is a challenging procedure owing to multiple factors. The approach and exposure of the hip can be difficult due to the presence of an ankylosed joint. There is a risk of implant malposition due to sagittal plane malrotation of the pelvis. Bone quality is affected by disuse osteopenia, resulting in an increased risk of fracture and there is a subsequent risk of re-ankylosis of the joint after arthroplasty.^{12,13} The success of total hip replacement is the outcome of the surgery that enables to relieve the pain associated with the hip joint pathology with maintaining the mobility and stability of the hip joint for

many years. The main indication for total hip replacement is excruciating pain and restriction of day-to-day activities.¹⁴ Early complications associated with total hip arthroplasty include fracture, nerve injury, dislocation, deep vein thrombosis and pulmonary embolism. Late complications include infection, heterotrophic ossification and loosening.¹⁵ Periprosthetic fractures is also a difficult problem which is associated with total hip arthroplasty, factors contributing for periprosthetic fractures are mostly the choice of implant and patient selection.¹⁶ Total hip arthroplasty relieves pain and functional disability experienced by patients in moderate and severe hip arthritis resulting in improving the quality of life of the patient.¹⁷ Many designs are studied and continuous efforts are made to minimise the complications and improve the outcomes of total hip arthroplasty. Several reports on series with variable follow-up periods have been published that have focused on the management of AS with total hip arthroplasty (THA).¹⁸⁻²⁰ Reported mean implant survival at 8.5 years follow-up was 85.9% and all patients were satisfied with using cementless THA. Also cemented THA in AS is provided satisfactory clinical and radiologic outcome, with a 71% survival rate at 27 years follow-up.^{5,13} In this study we aimed to evaluate and analyze the clinical, radiological and functional outcomes of THA in patients with AS at our institution.

Objectives

The objective of the study was to evaluate the clinical, radiological and functional outcomes of total hip arthroplasty among patients with ankylosing spondylitis.

METHODS

This was a prospective cohort study and was conducted in the department of orthopedic surgery of Ibn Sina Medical College Hospital, Dhaka, Bangladesh during the period from June 2021 to May 2022. In this study we included fifty patients with ankylosing spondylitis who underwent total hip arthroplasty (THA). These are the following criteria to be eligible for the enrolment as our study participants: Patients who were aged above 18 years; Patients who had significant disabling hip pain and moderate to severe functional limitation of activities of daily living due to AS; Patients who had one or more of the following radiological signs namely loss of sphericity of the femoral head, collapse of the weight bearing area of the femoral head, flattening of the femoral head, joint space narrowing, acetabular changes and osteoarthritic changes; Patients with minimum 4 times follow up were included and Patients with severe systemic diseases contraindicating surgical procedure; Patients with previous surgical history; Patients with revision total hip arthroplasties; Patients with any acute illness (e.g., renal or pancreatic diseases, ischemic heart disease etc.) were excluded from our study.

In this study charts were analyzed for clinical and radiologic features preoperatively and at last follow-up.

The radiographic study involved the review of anteroposterior (AP) both hips X-ray taken pre-operatively, immediate postoperative period and at last follow-up. Preoperative X-ray assessments were included Dorr's classification, acetabular protrusion and bone ankylosis.²¹ Acetabular protrusion was defined as femoral head in that the medial aspect of the femoral cortex is medial to the ilioischial line.²² Brooker classification of heterotopic ossification (HO), Gruen and Charnley classifications of implant loosening were assessed at last follow-up X-ray.²³⁻²⁵ In addition to the chart and radiographic review, patients were called back to return for additional long-term follow up. Those able to return had additional radiographs, functional outcome assessment with Harris hip score (HHS).²⁶

Radiological hip involvement

Both of these procedures produce modifications that can be viewed on traditional radiographs with the aid of two regular features: concentric osteoproliferation with osteophytes round the femoral neck and erosions of the acetabulum. These are two typical features that have been considered in the conventional radiograph. The most broadly used and best-validated index to consider the severity and evolution of hip involvement is the bath ankylosing spondylitis radiology index. The hips are graded on a scale of 0-4; 0= no change; 1=suspicious: focal joint space narrowing; 2= mild: circumferential joint space narrowing >2 mm; 3=moderate: circumferential joint space narrowing 2 mm or bone-on-bone apposition of <2 cm; 4= severe: bone deformity or bone-on-bone apposition of 2 cm). This score shows a reasonable sensitivity to change and therefore can be used in clinical trials and observational studies. Statistical analysis was performed using IBM Statistical Package for Social Sciences version 23 (SPSS version 23.0) for windows 10. Categorical data were compared using chi-square test, and continuous data using two-sample Student's t-test. A p value of 0.05 was considered significant.

RESULTS

In this study (Figure 3) showed the age distribution among study subjects where we found that majority (36%) of the patients were aged between 18-30 years old; 32% and 26% were aged 31-45 and 46-60 years old respectively. The least prevalence 10% was found among >60 years old. Here, figure 2 shows the gender description of our study people. Majority of our patients were male (66%) and female (34%). In (Table 1) we showed the demographics and clinical characteristics of our study people.

The highest prevalence (36%) was present in aged between 31-40 years old. The mean±SD of age among patients was (37±12). We found HLA B27 positive among 35 (70%) patients in our study. The mean±SD of height was (163.5±7.9); weight was (67.06±8.92) and BMI was (22.50±2.8) among our study participants respectively. We found the mean±SD of follow up (7.36±2.00) in times of

patients. The prevalence of chief complains among our patients is shown in (Table 2).

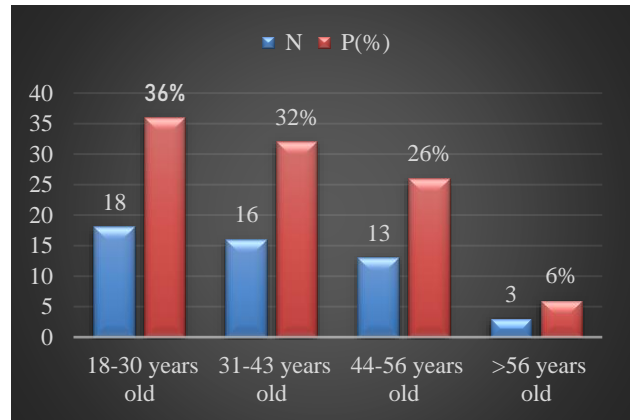


Figure 3: Age distribution among our study subjects.

Table 1: Demographics and clinical characteristics of study participants.

Demographics and clinical characteristics	N	%	P value
Age (years)			
Mean±SD	37±12		0.311
Clinical characteristics			
HLA B27	35	70	0.015
Height (cm) (Mean±SD)	163.5±7.9		0.016
Weight (cm) (Mean±SD)	67.06± 8.92		0.155
BMI (kg/m ²) (Mean±SD)	22.50±2.8		0.966
Follow-up times (Mean±SD)	7.36± 2.00		0.095

Table 2: The prevalence of chief complains among our study participants.

Chief complains	N	%	P value
Pain in both hip joint for years (1-8)	23	46	0.001
Left sided hip pain	11	22	0.001
Right sided hip pain	16	32	0.001
Mild pain	8	16	0.001
Moderate pain	32	64	0.001
Severe pain	10	20	0.001
Burning sensation	31	62	0.001
Joint pain	16	32	0.001
Pain during walking	19	38	0.001
Inability to walk normally	28	56	0.001
Unable to walk (bed ridden)	38	76	0.001

The highest prevalence (76%) was found among study patients who were unable to walk. Pain in both hip joint for years (1-8) was found in 23 (46%); left sided hip pain was found in 11(22%); right sided hip pain was found in 16 (32%) patients respectively. The prevalence of mild pain, moderate pain & severe pain was 16%, 64% and 20% respectively. Burning sensation & joint pain was present among 31 (62%) and 16 (32%) patients respectively. Total

19 (38%) patients felt pain during walking and 28 (56%) patients showed inability to walk normally.

In (Table 3) we showed the comparison of outcome after THA between preoperative and postoperative phase among study people based on their day-to-day activities. Before THA we found the prevalence of patients who needed cane & crutches all the time was 8% and 16%

respectively and were unable to walk was 76%. After THA the prevalence of patients who didn't need any support was 76%, who needed cane for long walk was 14% and needed crutches was 10% respectively. We found patients with slight, moderate and severe limping was 6%, 16% and 78% respectively before THA. After THA we found patients with no limping was 92% and slight limping was 8%.

Table 3: Comparison of outcome after THA between preoperative and postoperative phase of our study participants based on their day-to-day activities.

Outcome variables	Score	Preoperative		Postoperative		P value
		N	%	N	%	
Types of support						
None	11	0	0	38	76	0.015
Cane for long walk	7	0	0	7	14	
Cane all the time	5	4	8	0	0	
Crutches or Walker	0	8	16	5	10	
Unable to walk	0	38	76	0	0	
Limping						
None	11	0	0	46	92	0.012
Slight	8	3	6	4	8	
Moderate	5	8	16	0	0	
Severe	0	39	78	0	0	
Walking distance						
Unlimited	11	0	0	42	84	0.015
5-6 blocks (25-30 minutes)	8	16	32	8	16	
1-4 blocks (5-20 minutes)	5	34	68	0	0	
Climbing stairs						
Normally	4	0	0	38	76	0.013
Need a banister or crutches	2	11	22	12	24	
Severe trouble climbing stairs	1	39	78	0	0	
Ability to wear socks & tie shoes						
Can put on socks and tie a shoe easily	4	0	0	39	78	0.015
Can put on socks and tie a shoe with difficulty	2	18	36	11	22	
Cannot put on socks and shoes	0	32	64	0	0	
Sitting						
Comfortable in any chair	5	0	0	42	84	0.012
Can sit comfortably for 0.5 hour on high chair	3	21	42	8	16	
Cannot sit for 0.5 hour	0	29	58	0	0	

Table 4: Functional improvement after THA among our study people.

Functional outcome	Pre-operative	Post-operative	P value
Harris hip score	44.2±12.3	87.2±17.4	0.01

During preoperative phase we found the prevalence of patients who could walk for 25-30 min was 32% and 5-20 min was 68% respectively. After follow-up we found patients who could walk with unlimited distance was 84% and could walk for 25-30 min was 16% respectively. In preoperative phase we found patients with severe trouble in climbing stairs was 78% and during follow up we found patients with no trouble in climbing stairs was 76% and

needed a banister was 24% respectively. Before THA there were patients who couldn't put on socks and shoes was 64% while after THA there were patients who could put them easily was 78%. The patients who could put socks and shoes with difficulty was 36% and 22% during preoperative and postoperative respectively. Before THA the prevalence of patients who couldn't sit for half an hour was 58% while after THA who could sit comfortably in any chair was 84%. The patients who could sit comfortably for 0.5 hour on high chair was 42% and 16% during preoperative and postoperative respectively. In (Table 4) we showed the functional improvement after THA among our study people. We found the mean±SD of Harris hip score (HHS) was 44.2±12.3 and 87.2±17.4 during preoperative & postoperative phase respectively.

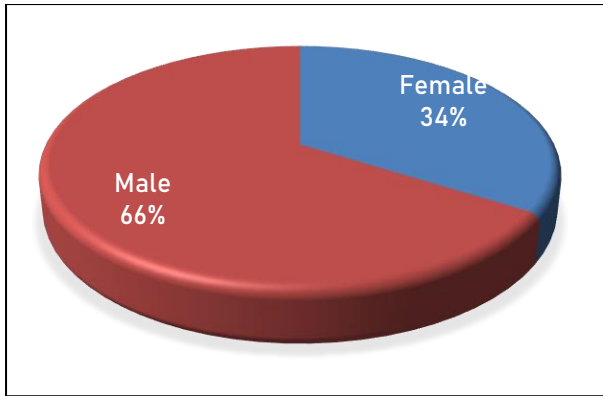


Figure 4: Gender description of the study people.

DISCUSSION

In this study we found the majority (36%) of the patients were aged between 18-30 years old; followed by 32% and 26% were aged between 31-45 and 46-60 years old respectively. The least prevalence 10% was found among >60 years old (Figure 3). In other study; Joshi et al found the age distribution of patients when AS was diagnosed was as follows: 38 patients (70 hips) were <20 years old, 45 patients (80 hips) were between 21 and 40 years old, and 12 patients (16 hips) were ≥ 41 years old.²⁷ In our study we found the majority of our patients were male (66%) and female (34%) (Figure 4). In other study Saglam et al found that there were 61 patients among of them 50 patients were male and 11 patients were female.²⁸ In our study we found the highest prevalence (36%) was present in aged between 31-40 years old. The mean \pm SD of age among patients was (37 \pm 12). We found HLA B27 positive among 35(70%) patients in our study. The mean \pm SD of height was (163.5 \pm 7.9); weight was (67.06 \pm 8.92) and BMI was (22.50 \pm 2.8) among our study participants respectively. We found the mean \pm SD of follow up (7.36 \pm 2.00) in times among patients (Table 1). In other study Saglam et al found the average patient age at surgery was 41.3 \pm 10.2 years old.²⁸ In this study we found the highest prevalence (76%) among study patients who were unable to walk. Pain in both hip joint for years (1-8) was found in 23 (26%); left sided hip pain was found in 11 (22%); right sided hip pain was found in 8 (16%) patients respectively. The prevalence of mild pain, moderate pain and severe pain was 22%, 64% and 36% respectively. Burning sensation and joint pain was present among 31 (62%) and 16 (32%) patients respectively.¹⁹ (38%) patients felt pain during walking and 28 (56%) patients showed inability to walk normally (Table 2). In our study we found the prevalence of patients who needed cane & crutches all the time was 8% and 16% respectively and were unable to walk was 76% before THA while after THA the prevalence of patients who didn't need any support was 76%, who needed cane for long walk was 14% and needed crutches was 10% respectively. During preoperative phase we found the prevalence of patients who could walk for 25-30 min was 32% and 5-20 min was 68% respectively. After follow-up we found patients who could walk with

unlimited distance was 84% and could walk for 25-30 min was 16% respectively. In this study we found the decreased prevalence of patients who were unable to walk, severe pain and had difficulty to do daily activities after THA compared to preoperative phase (Table 3). In our study we found the mean \pm SD of Harris hip score (HHS) was 44.2 \pm 12.3 & 87.2 \pm 17.4 during preoperative and postoperative phase respectively which has been improved after THA (Table 4). In other study (Saglam et al.) found the average pre-operative HHS was 46.6 \pm 16.3, and it improved to 80.7 \pm 18.7 at last follow-up ($p < 0.01$).²⁸

Limitations

Our study was a single center study that conducted in the department of orthopaedic surgery of Ibn Sina medical college hospital. We observed the clinical, radiological & functional outcomes of total hip arthroplasty among patients with AS and evaluated those patients with 12 months follow-up and have not known other possible interference that may happen in the long term with these patients.

CONCLUSION

In our study, we analyzed the clinical, radiological & functional outcomes of total hip arthroplasty among patients with AS and found that total hip arthroplasty is a safe and effective treatment of patients with advanced hip involvement. It results in significant improvements in objective outcome measures such as Harris Hip Score, patient mobility & reduced the difficulty level of patients in their day-to-day activities.

Funding: No funding sources

Conflict of interest: None declared

Ethical approval: The study was approved by the Institutional Ethics Committee

REFERENCES

1. He C, He X, Tong W. The effect of total hip replacement on employment in patients with ankylosing spondylitis. *Clin Rheumatol.* 2016;35:2975-81.
2. Vander CB, Munoz-Gomariz E, Font P. Hip involvement in ankylosing spondylitis: epidemiology and risk factors associated with hip replacement surgery. *Rheumatol.* 2010;49:73e81.
3. Cooksey R, Brophy S, Husain MJ, Irvine E, Davies H, Siebert S. The information needs of people living with ankylosing spondylitis: a questionnaire survey. *BMC Musculoskelet Disord.* 2012;13:243.
4. Guan M, Wang J, Zhao L, Xiao J, Li Z, Shi Z. Management of hip involvement in ankylosing spondylitis. *Clin Rheumatol.* 2013;32:1115-20.
5. Joshi A, Ilchmann T, Markovic L. Socket wear in bilateral simultaneous total hip arthroplasty. *J Arthroplast.* 2001;16:117-20.

6. Ulucay C, Ozler T, Güven M, Akman B, Kocadal AO, Altintas, F. Etiology of coxarthrosis in patients with total hip replacement. *Acta Orthop Traumatol Turc.* 2013;47:330-33.
7. Braun J, van der Horst-Bruinsma IE, Huang F, et al. Clinical efficacy and safety of etanercept versus sulfasalazine in patients with ankylosing spondylitis: a randomized, double-blind trial. *Arthritis Rheum.* 2011;63:1543-51.
8. Moll JMH. *Ankylosing spondylitis.* London: Churchill Livingstone; 1980.
9. Hou LQ, Jiang GX, Chen YF. The comparative safety of TNF inhibitors in ankylosing spondylitis: a meta-analysis update of 14 randomized controlled trials. *Clin Rev Allergy Immunol.* 2018;54:234-43.
10. Braun J, van der Horst-Bruinsma IE, Huang F. Clinical efficacy and safety of etanercept versus sulfasalazine in patients with ankylosing spondylitis: a randomized, double-blind trial. *Arthritis Rheum.* 2011;63:1543-51.
11. Shanahan WR, Jr, Kaprove RE, Major PA, Hunter T, Baragar FD. Assessment of longterm benefit of total hip replacement in patients with ankylosing spondylitis. *J Rheumatol.* 1982;9:101-4.
12. Brinker MR, Rosenberg AG, Kull L, Cox DD. Primary noncemented total hip arthroplasty in patients with ankylosing spondylitis: clinical and radiographic results at an average follow-up period of 6 years. *J Arthroplasty* 1996;11:802-12.
13. Bhan S, Eachempati KK, Malhotra R. Primary cementless total hip arthroplasty for bony ankylosis in patients with ankylosing spondylitis. *J Arthroplasty.* 2008;23:859-66.
14. Charnley, John. Arthroplasty of the hip: a new operation. *Lancet.* 1961; 277:1129-32.
15. Azansky, Mark GI. Complications revisited the debit side of total hip replacement. *Clin Orthopaed Related Res.* 1973;95:96-103.
16. Ragab AA, Kraay MJ, Goldberg VM. Clinical and radiographic outcomes of total hip arthroplasty with insertion of an anatomically designed femoral component without cement for the treatment of primary osteoarthritis. *J Bone Joint Surg.* 1999;81(2):210-8.
17. Wiklund I, Romanus B. A comparison of quality of life before and after arthroplasty in patients who had arthrosis of the hip joint. *J Bone Joint Surg Am.* 1991;73(5):765-9.
18. Walker L, Sledge C. Total hip arthroplasty in ankylosing spondylitis. *Clin Orthop.* 1991;262:198.
19. Welch R, Charnley J. Low-friction arthroplasty of the hip in rheumatoid arthritis and ankylosing spondylitis. *Clin Orthop.* 1970;72:22.
20. Williams E, Taylor A, Arden G, Edwards D. Arthroplasty of the hip in ankylosing spondylitis. *J Bone Joint Surg Br.* 1977;59:393.
21. Dorr LD, Faugere MC, Mackel AM, Gruen TA, Bognar B, Malluche HH. Structural and cellular assessment of bone quality of proximal femur. *Bone.* 1993;14:231-42.
22. Van De Velde S, Fillman R, Yandow S. The aetiology of protrusio acetabuli. Literature review from 1824 to 2006. *Acta Orthop Belg.* 2006;72:524-9.
23. Brooker AF, Bowerman JW, Robinson RA, Riley LH. Ectopic ossification following total hip replacement. Incidence and a method of classification. *J Bone Jt Surg Am.* 1973;55:1629-32.
24. Gruen TA, McNeice GM, Amstutz HC. Modes of failure of cemented stem-type femoral components: a radiographic analysis of loosening. *Clin Orthop Relat Res.* 1979;141:17-27.
25. Charnley J. Proceedings: the histology of loosening between acrylic cement and bone. *J Bone Jt Surg Br.* 1975;57:245.
26. Harris WH. Traumatic arthritis of the hip after dislocation and acetabular fractures: treatment by mold arthroplasty. An end-result study using a new method of result evaluation. *J Bone Jt Surg Am.* 1969;51:737-55.
27. Joshi A B, Markovic L, Hardinge K, Murphy JCM. Total hip arthroplasty in ankylosing spondylitis: An analysis of 181 hips. *J Arthroplas.* 2002;17(4):427-33.
28. Saglam Y, Ozturk I, Cakmak MF, Ozdemir M, Yazicioglu O. Total hip arthroplasty in patients with ankylosing spondylitis: Midterm radiologic and functional results. *Acta Orthop Traumatol Turc.* 2016;50(4):443-7.

Cite this article as: Ahsan P, Jahan I, Khair A. Total hip arthroplasty in ankylosing spondylitis in a tertiary care hospital: a prospective cohort study. *Int J Res Orthop* 2023;9:xxx-xx.