



Duodenal Perforation due to Inferior Vena Cava Filter in a Multi-morbid Young Patient: First Clinical Case Report in Latvia

Sintija Strautmane^{1*}, Roberts Rumba², Zanda Priede¹, Andrejs Millers¹, Kaspars Kisis², Andrejs Brikuns³, Dainis Krievins²

¹Department of Neurology, Pauls Stradins Clinical University Hospital, Pilsonu iela 13, Riga, LV-1002, Latvia; ²Department of Vascular Surgery, Pauls Stradins Clinical University Hospital, Pilsonu iela 13, Riga, LV-1002, Latvia; ³Department of Surgery, Pauls Stradins Clinical University Hospital, Pilsonu iela 13, Riga, LV-1002, Latvia

ABSTRACT

Introduction: The inferior vena cava filter is known to be a safe and effective method for preventing fatal pulmonary artery thromboembolism. We report a case report of inferior vena cava filter perforation on duodenum in a multimorbid young patient undergoing full midline laparotomy and cavotomy.

Case presentation: A 37-year-old male was admitted to a tertiary university hospital following recurrent episodes of epistaxis. In 2008, the patient developed traumatic subarachnoid haemorrhage with a following decompressive trepanation and bilateral pulmonary artery thromboembolism. An inferior vena cava filter was implanted. In 2021, due to suspected duodenal perforation, an urgent fibrogastroscopy was performed, revealing duodenal perforation caused by the inferior vena cava filter and aortic pseudoaneurysm. Vena cava filter evacuation was indicated; to date, no such operation has been performed in Latvia. The early postoperative period occurred without any complications. The patient was discharged 15 days after the surgical treatment in good overall health.

Results: This was a clinical case report about a 37-year-old multimorbid patient with positive anamnesis of traumatic subarachnoid haemorrhage following decompressive trepanation and bilateral pulmonary artery thromboembolism and inferior vena cava filter implantation due to absolute contraindications to anticoagulant therapy.

Conclusion: Inferior vena cava filters are generally safe but can cause clinically significant complications. The case of 37-year-old multimorbid patient with the main complaints of pain around the left ear and recurrent nose bleeds was discussed. On fibrogastroscopy, duodenal perforation caused by the inferior vena cava filter and aortic pseudoaneurysm were seen. Full midline laparotomy and cavotomy was performed. The patient was discharged in good overall health. Detailed assessment of the radiological findings, fibrogastroscopic studies and the novel treatment of a complicated disease occurring for the first time in Latvia proved successful for both patient recovery and outcome.

Keywords: Cavotomy; Laparotomy; Multimorbidity; Inferior vena cava filter; Duodenal perforation

INTRODUCTION

The inferior vena cava filter is reported to be a safe and effective method for preventing fatal pulmonary artery thromboembolism

by mechanically preventing blood clots from reaching the pulmonary circulation [1,2,3,4]. According to the Escardio 2019 guidelines on pulmonary artery thromboembolism and other articles in the literature, potential indications for inferior vena

Correspondence to: Sintija Strautmane, Department of Neurology, Riga Stradins University, Dzirciema iela 16, Riga, Latvia; E-mail: sintijasstrautmane@gmail.com

Received: 02-Aug-2022, Manuscript No. JVMS-22-17646; **Editor assigned:** 08-Aug-2022, Pre QC No. JVMS-22-17646 (PQ); **Reviewed:** 29-Aug-2022, QC No. JVMS-22-17646; **Revised:** 05-Sep-2022, Manuscript No. JVMS-22-17646 (R); **Published:** 12-Sep-2022, DOI: 10.35248/2329-6925.22.S9.472.

Citation: Strautmane S, Rumba R, Priede Z, Millers A, Krievins D, Kisis K, et al (2022) Duodenal Perforation due to Inferior Vena Cava Filter in a Multi-morbid Young Patient: First Clinical Case Report in Latvia. J Vasc Surg. S9:472.

Copyright: © 2022 Strautmane S, et al. This is an open access article distributed under the terms of the Creative Commons Attribution License, which permits unrestricted use, distribution, and reproduction in any medium, provided the original author and source are credited.

cava filter include venous thromboembolism and absolute contraindications to anticoagulant therapy, major bleeding, recurrent pulmonary embolism despite adequate anticoagulation and primary prophylaxis with a high risk of venous thromboembolism [2,3,5]. According to the literature, inferior vena cava filters are safe but can cause clinically significant complications, especially during extended periods of implantation; therefore, it is recommended to remove the filter as early as possible [4]. Filter migration may occur as a late symptomatic or asymptomatic complication [4]. Vena cava filter perforation is common, but an inferior vena cava filter duodenal perforation is rare [4,5], with aortic pseudoaneurysm being noted to be exceptionally rare [6]; in some cases, it could be life-threatening [5]. According to the literature, it is possible to perform both open procedures and use endovascular approaches, with the latter showing the advantage of reduced morbidity [7]. We report a case report of inferior vena cava filter perforation on the duodenum in a multi morbid young patient undergoing full midline laparotomy and cavotomy. The patient has given written informed consent to publish this case.

CASE PRESENTATION

A 37-year-old male was admitted to Pauls Stradins Clinical University Hospital following recurrent episodes of epistaxis. The patient was consulted by an otorhinolaryngologist; Merocel nasal tampons were inserted in the nose bilaterally. It was reported that the patient had been admitted to a regional hospital earlier in the year due to pain in their spinal cord. A left-side hidradenitis incision was performed in the regional hospital with subsequent antibacterial therapy using ceftriaxone, metronidazole and piperacillin/tazobactam. Computed tomography of the lumbar-sacral region was performed, excluding spondylodiscitis. The patient was recommended ambulatory magnetic resonance imaging on the same region, where L4-L5 spondylodiscitis with a strikingly wide bilateral psoas muscle infiltration and a left-side wide epidural abscess from L3-L4 to S1 was noted with dural sac compression. The patient denied any substance abuse and was then consulted by a neurosurgeon. An operative approach was considered, but the patient's inflammatory markers rose, so further conservative therapy was recommended. The main complaints included pain around the left ear and recurrent epistaxis; therefore, computed tomography of the brain and pyramids was performed, where content in the external acoustic meatus was visualized with no data of mastoiditis. During hospitalization, recurrent episodes of epistaxis were noted in the patient; thermo coagulation and hemostatic tampons were placed. The patient developed normochromic normocytic anemia, so recurrent blood transfusion with packed red blood cells was performed. In 2008, the patient had developed traumatic subarachnoid haemorrhage with a following decompressive trepanation and bilateral pulmonary artery thromboembolism. Due to massive bleeding from the subarachnoid hemorrhage (spontaneous intracranial blood vessel pathologies were excluded), perioral anticoagulant

therapy was contraindicated and an inferior vena cava filter was implanted; no pulmonary artery thromboembolism and no deep vein thrombosis was noted afterwards. The patient admitted that there had been no inferior vena cava filter control visits since 2008. During this intra hospital stay, the patient was consulted by a vascular surgeon and urgent fibro gastroscopy was recommended. A duodenal perforation caused by the inferior vena cava filter and aortic pseudo aneurysm were seen. The only complaints included pain around the left ear and difficulty breathing due to recurrent epistaxis.

A multidisciplinary team meeting consisting of neurologists, neurosurgeons, abdominal surgeons, and vascular surgeons was undertaken and it was decided that removal of the inferior vena cava filter was indicated. To date, however, no such operation had been performed in Latvia. The patient underwent full midline laparotomy under general anesthesia. Mobilization from the right ascending colon to the caecum was performed, providing adequate visualization of the duodenum. The duodenum was then mobilized using the Kocher manoeuvre. Two metallic struts of the inferior vena cava filter were seen in the duodenum. Evacuation of the metallic struts was performed, which created two duodenal defects; one of these defects was around 1 cm in diameter and produced a yellowish discharge. The duodenal damage was repaired using a GIA stapler, DST Series 6 mm/4.8 mm. Subsequently, the inferior vena cava was mobilized from the kidney level to the aortic bifurcation. A strikingly massive infiltration in the posterior duodenal wall was noted, so the vena cava was controlled with a vessel loop just distal from the kidney veins. The proximal end of the inferior vena cava filter was palpable distally under kidney veins. In addition, 5000 units of heparin were given intravenously. The cava was clamped proximally and distally from the filter struts. Thereafter, a cavotomy incision of around 6 cm in length was made in the anterior wall where the struts were located. The proximal end of the filter was separated from the posterior wall of the vena cava and the filter was removed. An aortic bleed was noticed adjacent to the vena cava, where one of the struts had pierced the aortic wall and created an aortic pseudo aneurysm with a diameter of 34 mm (Figure 1). This bleed was controlled using separate 5-0 Prolene sutures. Then, a 5-0 Prolene running suture was used to close the cavotomy incision. Drainage was inserted close to this area. The early postoperative period was without complications and the patient was gradually activated. Another multidisciplinary meeting was performed, where all agreed to treat the spondylodiscitis conservatively and follow-up with ambulatory magnetic resonance imaging with secondary treatment planning afterwards. The aortic pseudo aneurysm was re-evaluated 3 months after the primary surgery by CT angiography, which did not show any increase in diameter; thus, given the patient's age and history, the pseudo aneurysm was managed conservatively at this point (Figure 2). Recurrent consultation by an otorhinolaryngologist was performed. The patient was discharged 15 days after the surgical treatment in good overall health.

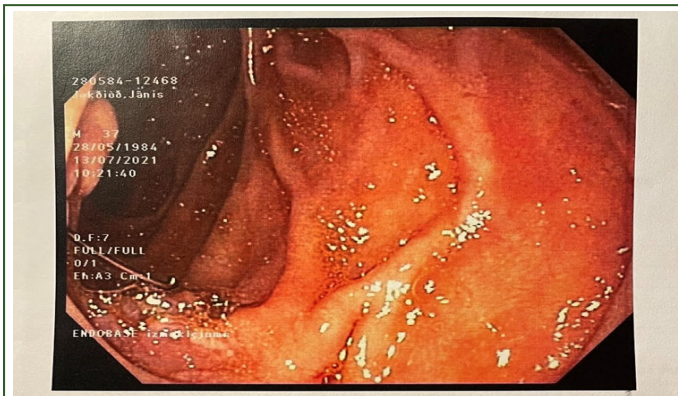


Figure 1: Upper gastrointestinal endoscopy revealing metallic strings perforating the duodenum into the lumen.

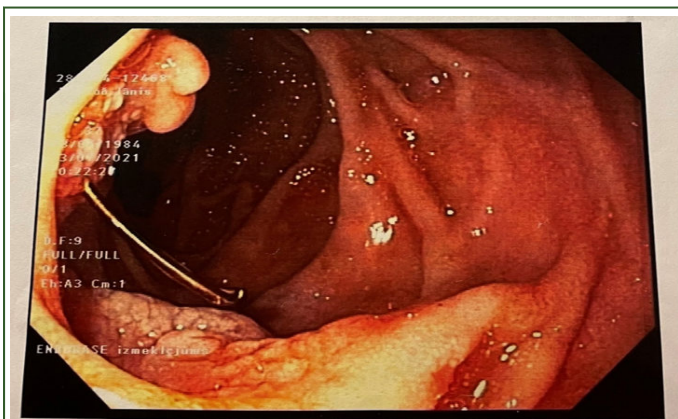

Figure 2: Upper gastrointestinal endoscopy revealing metallic strings perforating the duodenum into the lumen.

RESULTS

This was a clinical case report about a 37-year-old multimorbid patient with positive anamnesis of traumatic subarachnoid haemorrhage following decompressive trepanation and bilateral pulmonary artery thromboembolism and inferior vena cava filter implantation due to absolute contraindications to anticoagulant therapy. His main complaints included recurrent episodes of epistaxis and pain in their spinal cord. Magnetic resonance imaging findings included L4-L5 spondylodiscitis with a strikingly wide bilateral psoas muscle infiltration and a left-side wide epidural abscess from L3-L4 to S1 was noted with dural sac compression. Further conservative therapy was recommended. During this intrahospital stay, the patient was consulted by a vascular surgeon and urgent fibrogastroscopy was recommended, revealing duodenal perforation caused by the inferior vena cava filter and aortic pseudoaneurysm. Patient underwent a full midline laparotomy and cavotomy. Eventually, patient was discharged from the hospital 15 days after the surgical treatment in a good overall health condition, proving it is possible to lead a successful, high-quality life after being diagnosed with a spondylodiscitis simultaneously with a duodenal perforation due to inferior vena cava filter implantation.

DISCUSSION

According to the literature, vena cava filters are reported to be a safe and effective method for preventing fatal pulmonary artery thromboembolism in patients with absolute contraindications to anticoagulant therapy. Nevertheless, the routine use of this filter is not recommended due to the complications that may occur after its implantation, especially during extended periods of implantation. Vena cava filter migration is a common complication, while duodenal perforation and aortic pseudoaneurysm are noted to be exceptionally rare. According to the literature, it is possible to perform both open procedures and use endovascular approaches, with the latter showing the advantage of reduced morbidity. In this case report, a 37-year-old patient with spondylodiscitis simultaneously with duodenal perforation due to inferior vena cava filter undergoing full midline laparotomy and cavotomy was demonstrated resulting in a successful patient recovery and outcome. Further research on vena cava filter implantation indications, contraindications, their monitoring and occurrence of complications is warranted to prevent life-threatening events resulting in the best outcome for the patient.

CONCLUSION

Vena cava filters can be placed in patients with venous thromboembolism and absolute contraindications to anticoagulant therapy. Although the use of these filters is generally reported to be safe, the routine use of these filters is not recommended as many complications have been reported after implantation of the inferior vena cava filter. The case of a 37-year-old multi morbid patient with the main complaints of pain around left ear and difficulty breathing due to recurrent nose bleeds without coagulopathies was presented. On fibro gastroscopy, a duodenal perforation by an inferior vena cava filter placed after traumatic subarachnoid hemorrhage in 2008 was visualized. Full midline laparotomy and cavotomy was performed. The early postoperative period occurred without any complications. The patient was discharged 15 days after the surgical treatment in good overall health. Detailed assessment of the radiological findings, fibro gastroscopy studies and novel treatment of a complicated disease for the first time in Latvia proved successful in both patient recovery and outcome.

REFERENCES

1. Bae MJ, Chung SW, Lee CW, Kim S, Song S. Duodenal perforation caused by an inferior vena cava filter. *Korean J Thoracic Cardiovasc Surg.* 2012;45(1):69.
2. Konstantinides SV, Meyer G, Becattini C, Bueno H, Geersing GJ, Harjola VP, et al. ESC Guidelines for the diagnosis and management of acute pulmonary embolism developed in collaboration with the European Respiratory Society (ERS) The Task Force for the diagnosis and management of acute pulmonary embolism of the European Society of Cardiology (ESC). *Eur Heart J.* 2020;41(4):543–603.
3. Harvey JJ, Hopkins J, McCafferty IJ, Jones RG. Inferior vena cava filters: What radiologists need to know. *Clin Radiol.* 2013;68(7):721–732.
4. Jha KK, Thakur LK, Jha S. Duodenal perforation by an inferior vena cava filter. *Case Reports.* 2017.

5. Baptista AP, Sincos IR, Labropoulos N, Donegá BC, Klepacz A, Aun R. Symptomatic duodenal perforation by inferior vena cava filter. *Phlebology*. 2018;33(8):523–533.
6. Grewal S, Chamarthy MR, Kalva SP. Complications of inferior vena cava filters. *Cardiovasc Diagn Ther*. 2016;6(6):632–641.
7. Krutman M, Yazbek G, Nishinari K, Pignataro BS, Bomfim GAZ, Cavalcante RN, et al. An alternative approach to treatment of inferior vena cava filter perforation. *J Vasc Brasileiro*. 2020;19.