

Atypical Presentation of Multiple Evanescent White Dot Syndrome with Optic Atrophy, Macular Thinning, and Arcuate Scotoma

Optik Atrofi, Maküler İncelme ve Arkuat Skotom Gibi Atipik Klinik Bulgular Gösteren Çoklu Geçici Beyaz Nokta Sendromu Olgusu

Murat OKUTUCU^a, Mehmet Gökhan ASLAN^a, Erkan DUMAN^b, Hüseyin FINDIK^a

^aDepartment of Ophthalmology, Recep Tayyip Erdoğan University Faculty of Medicine, Rize, TURKEY

^bDepartment of Ophthalmology, Ordu University Faculty of Medicine, Ordu, TURKEY

ABSTRACT A 57-year-old man presented with a sudden loss of vision, central scotoma, and photopsia in the left eye. Grayish-white spots localized in the deep retina around the macula and optic disc were observed in the left eye on funduscopic examination. We observed a hyperfluorescence in a wreath-like pattern with late staining in retinal lesions during the early stage of fundus fluorescein angiography. Disruption was observed in an ellipsoid zone in optical coherence tomography. Multiple evanescent white dot syndrome was diagnosed based on findings and followed up without medication. The visual acuity of the left eye improved from 1/20 to 6/10 after a 7-week follow-up. Dilated fundus examination showed optic atrophy, and visual field examination revealed an arcuate scotoma.

Keywords: White dot syndromes; optical coherence tomography; fluorescein angiography; optic atrophy; scotoma

ÖZET Elli yedi yaşında erkek hasta, sol gözde ani görme kaybı, santal skotom ve fotopsi şikâyetleri ile kliniğimize başvurdu. Funduskopik muayenesinde, sol gözde makula ve optik disk etrafında, retinanın derin katlarında lokalize olmuş grimsi beyaz lezyonlar gözlemlendi. Fundus floresan anjiyografi erken dönemi boyunca retinal lezyonlarda gözlenen çelenk benzeri hiperfloresans, geç boyanma ile devam etti. Optik koherens tomografide, fotoreseptör iç ve dış segment tabakasında harabiyet görüldü. Mevcut bulgular eşliğinde hastaya, çoklu geçici beyaz nokta sendromu teşhisi kondu ve ilaçsız takip edildi. Yedi haftalık takip sonrası hastanın görme keskinliği 1/20'den 6/10'a yükseldi. Dilate fundus muayenesinde, optik atrofi ve görme alanında arkuat skotom oluştuğu gözlemlendi.

Anahtar Kelimeler: Beyaz nokta sendromları; optik koherens tomografi; floresan anjiyografi; optik atrofi; skotom

Multiple evanescent white dot syndrome (MEWDS) was first described by Jampol et al. in 1984, and manifests as a different clinical entity with subjective, clinical, demographic, fluorescein angiographic, and electrophysiological characteristics.¹ The main symptom is acute unilateral visual loss. Almost all patients present with photopsia (floaters or flashes of light). Usually, patients state that they have had a pro-

dromal flu-like episode before the development of symptoms.^{1,2}

Ocular discomfort and headache accompanying visual symptoms are rarely observed.^{3,4} In this study, we report a case of MEWDS with atypical clinical characteristics such as a delay in the arterial phase alongside early and late arteriovenous phases of fundus fluorescein angiography (FFA), atrophy of the

Correspondence: Murat OKUTUCU

Department of Ophthalmology, Recep Tayyip Erdoğan University Faculty of Medicine, Rize, TURKEY/TÜRKİYE

E-mail: muratokutucu83@gmail.com



Peer review under responsibility of Türkiye Klinikleri Journal of Ophthalmology.

Received: 27 Sep 2020

Received in revised form: 01 Mar 2021

Accepted: 03 Mar 2021

Available online: 05 Mar 2021

2146-9008 / Copyright © 2021 by Türkiye Klinikleri. This is an open access article under the CC BY-NC-ND license (<http://creativecommons.org/licenses/by-nc-nd/4.0/>).

optic disc, macular thinning, and arcuate scotoma in the visual field.

CASE REPORT

Written informed consent was obtained from the patient for publication of his case details and images obtained through medical imaging techniques. The

patient is a 57-year-old man presenting with an acute visual loss, photopsia, and central scotoma in the left eye starting a day ago. Ophthalmoscopic examination revealed a best-corrected visual acuity of 10/10 in the right eye and counting fingers at 2 meters in the left eye in the Snellen chart. Intraocular pressure and anterior segment examination results were within nor-

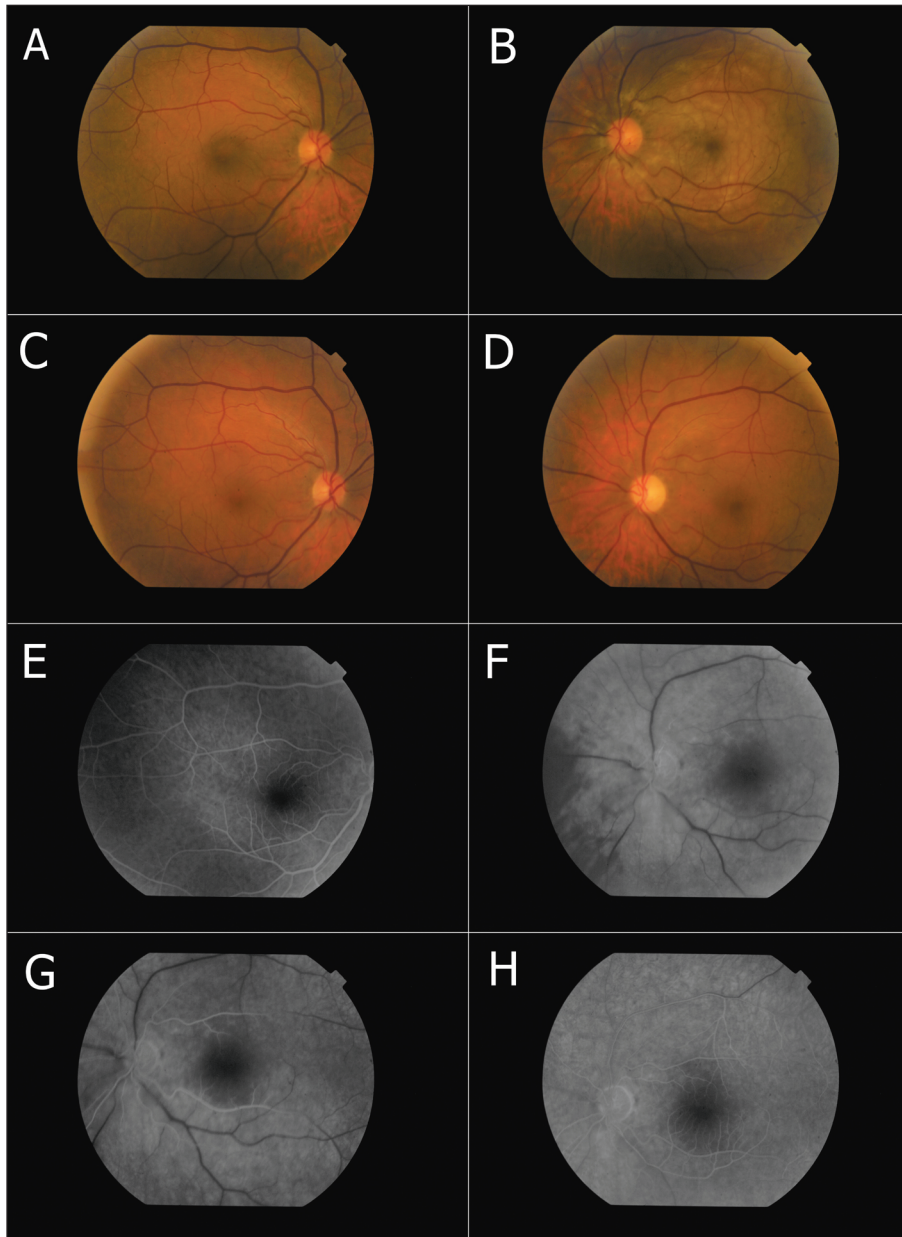


FIGURE 1: Color fundus image findings; (A) the right eye was normal; (B) irregularly bordered grayish-white lesions in size of 100-300 μm localized in the deep retina around the macula and the optic disc in the left eye. On color fundus image performed at 7-week follow-up showed that; (C) the right eye was normal; (D) the lesions in the left eye were resolved without any trace and optic atrophy developed. Fundus fluorescein angiography showed; (E) the right eye was normal, and a hyperfluorescence in a wreath-like pattern during the early stage of fundus fluorescein angiography; (F) at 1.08 and (G) 1.43 minutes and a delay in the arterial phase and early and late arteriovenous phases of fundus fluorescein angiography; (H) a delay in the late arteriovenous phase of fundus fluorescein angiography at 3.47 minute and late staining in the lesions especially around the optic disc in the left eye.

mal limits. Dilated fundus examination revealed that the right eye was normal and there were multiple irregularly bordered opaque grayish-white spots localized in the deep retina around the macula and optic disc in the left eye (Figure 1A, B). The color fundus photograph and FFA of the right eye were unremarkable (Figure 1C, E).

Hyperfluorescence in a wreath-like pattern with late staining in retinal lesions during the early stage of FFA, and a delay in the arterial phase and early/late arteriovenous phases of FFA was observed (Figure 1F-H). On optical coherence tomography (OCT), we observed a disruption at the junction of photoreceptor inner and outer segments (ellipsoid zone) and a mild

macular thickening (Figure 2B). A hyperreflective appearance was observed in the inner retinal layers due to edema caused by retinal ischemia. The central macular thickness (CMT) was 240 µm and 246 µm in the right and left eyes, respectively. From retinal nerve fiber layer (RNFL) analysis, the average thickness in the right eye was 80 µm, while that of the left eye was 113 µm, implying a mild optic disc edema (Figure 2E). The OCT examination of the right eye was unremarkable during the disease (Figure 2A, C).

MEWDS was diagnosed based on existing findings and followed up without medication. The visual acuity of the patient improved to 1/10 at the 2-week follow-up, 5/10 at the 4-week follow-up, and 6/10 at

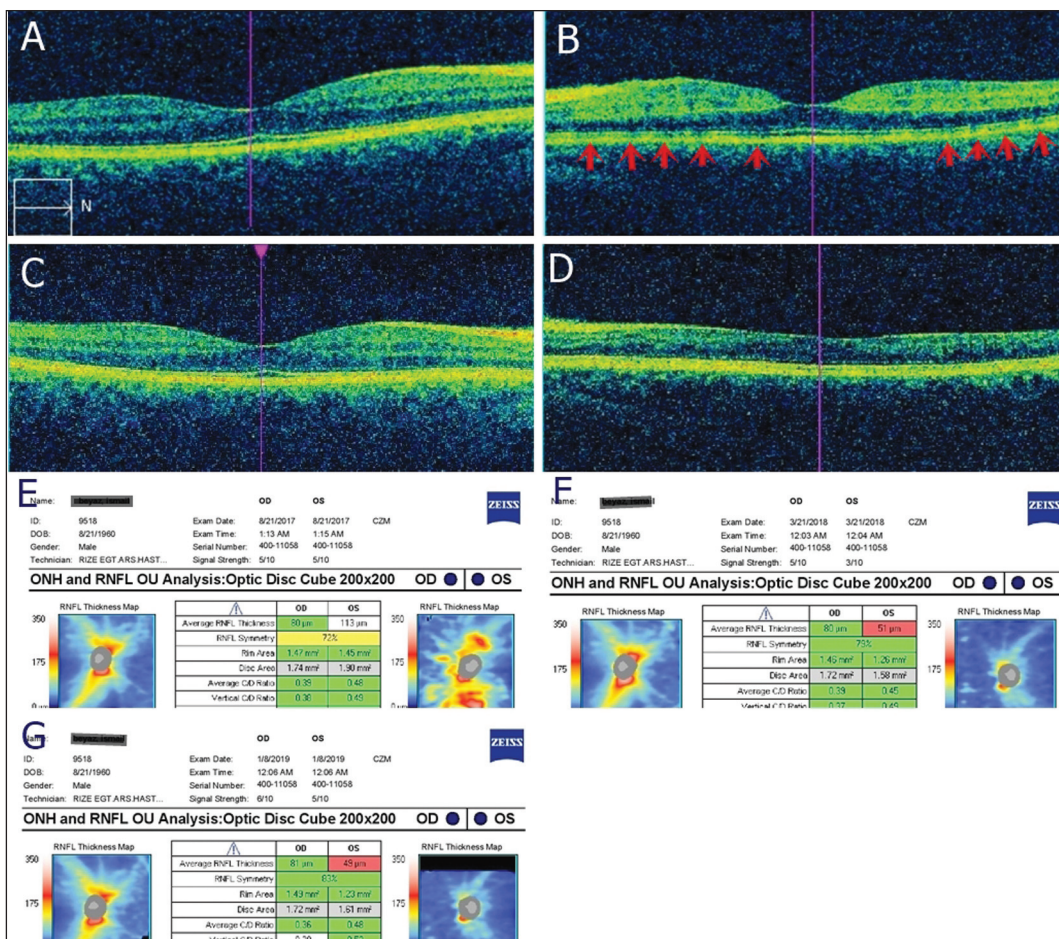


FIGURE 2: Findings of optical coherence tomography; (A) the right macula was normal; (B) there was a mild thickening and a disruption at the junction of photoreceptor inner and outer segments in the left macula (red arrow). Optical coherence tomography performed at a 17-month follow-up showed; (C) the right macula was normal; (D) disruption at the junction of photoreceptor inner and outer segments in the left macula was recovered but a generalized thinning developed in the left macula; (E) in retinal nerve fiber layer analysis, at the beginning of the disease, while the right average thickness was 80 µm, the left average thickness of 113 µm was implying a mild optic disc edema; (F) in retinal nerve fiber layer analysis performed at 7-month follow-up showed that the right average thickness was 80 µm and the left average thickness of 51 µm was implying the development of optic atrophy; (G) in retinal nerve fiber layer analysis performed at a 17-month follow-up showed that the right average thickness was 81 µm and the left average thickness of 49 µm was implying the development of optic atrophy.

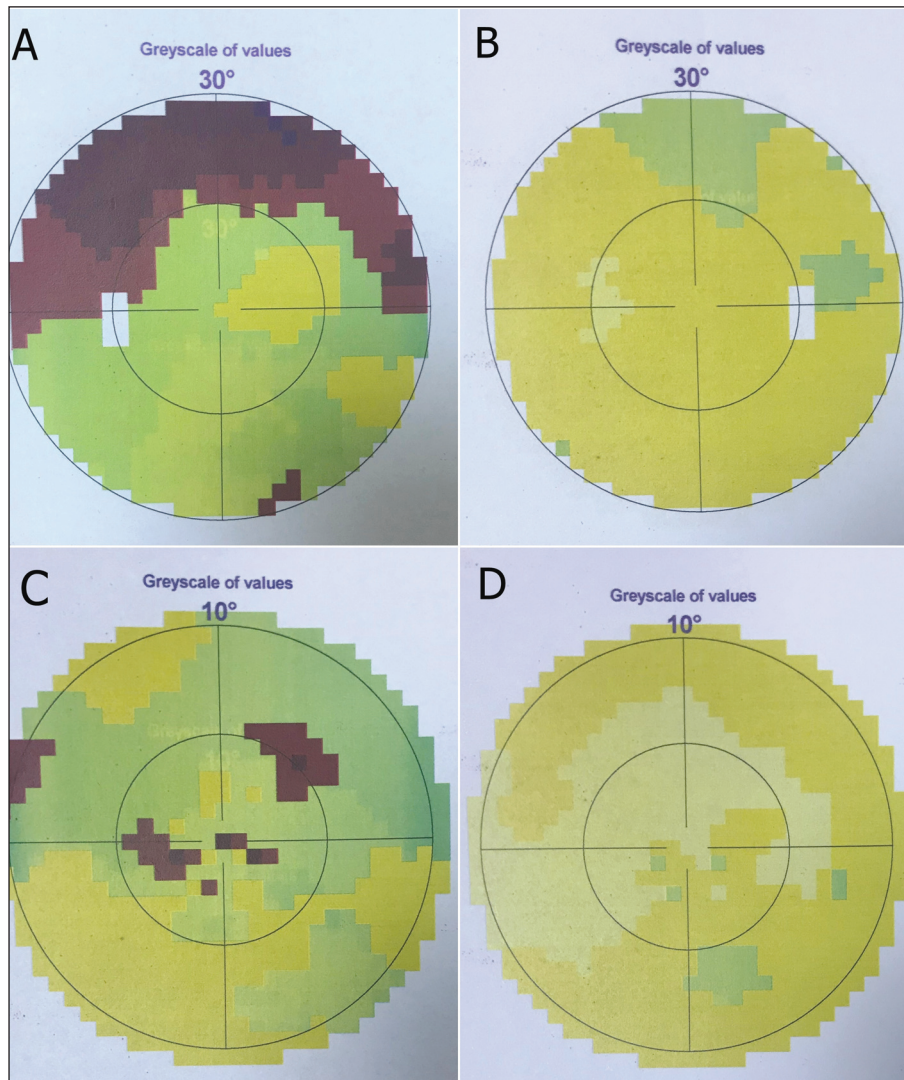


FIGURE 3: Findings at 17-month follow-up; (A) an arcuate scotoma developed in 30/2 visual field of the left eye; (B) the right eye was normal; (C) a central, paracentral, and temporal scotoma developed in 10-2 visual field (D) the right eye was normal.

the 7-week follow-up. On color fundus images performed at a 7-week follow-up, lesions resolved without any trace but optic atrophy developed (Figure 1D). At the 7-month and 17-month follow-up, the visual acuity was still 6/10, and macular thinning and optic atrophy were observed on OCT (Figure 2D, F, G). CMT was 241 μm and 207 μm in the right and left eyes, respectively. On RNFL analysis, the right average thickness and left average thickness were 81 μm and 49 μm , respectively (Figure 2G). An arcuate scotoma developed in a 30/2 visual field, and a central, paracentral, and temporal scotoma developed in the 10/2 visual field (Figure 3A, C) while the right eye right eye was normal (Figure 3B, D).

DISCUSSION

In this study, we report a case of MEWDS presenting with atypical clinical characteristics such as a delay in the arterial phase, early and late arteriovenous phases of FFA, atrophy in the optic disc, macular thinning, and arcuate scotoma in the visual field. Until now, a delay in the phases of FFA in the active period and arcuate scotoma, atrophy in the optic disc, and macular thinning after the recovery period were not reported during MEWDS. MEWDS usually presents with an acute unilateral visual loss. The visual acuity of the patient ranged from 10/10 to 1/20. Visual loss may be accompanied by central scotoma

and photopsia in MEWDS.⁵ Our patient presented with complaint of acute unilateral visual loss. He complained of central scotoma and photopsia at the time of presentation.

The typical fundus examination finding is the existence of multiple nummular grayish-white lesions with a size of 100-300 µm beginning from outside the macula and extending to the mid-peripheral retina.⁵ Also in the fundus examination of our case, there were the same typical lesions, but they were irregularly bordered and not nummular. FFA shows a hyperfluorescence in a wreath-like pattern with late staining in areas corresponding to the white spots.² Similarly, in the FFA in our case, a hyperfluorescence in a wreath-like pattern with late staining in areas corresponding to the white spots was observed. In the study performed by Nguyen et al., the authors demonstrated that there was a disruption at the IS/OS junction in all eyes affected by MEWDS.⁶ We also observed a disruption at the IS/OS junction in the evaluation of our patient after performing OCT.

In the study performed by Gross et al. with five MEWDS patients, the authors reported that this disease was a chorioretinopathy according to data obtained from the retinal and choroidal images.⁷ As it is in many posterior segment inflammatory disorders, the degree of retinal and choroidal involvement in MEWDS shows great variance among patients.⁷ The common feature among all of these variants is the pathology of the peripapillary circulation caused by the disease. The peripapillary circulation is largely nourished by the ciliary arteries that communicate with the retinal circulation.⁷ The condition accounts for the characteristic enlargement of the blind spot observed in this disorder.⁷ We attributed the development of a delay in the phases of FFA, atrophy in the optic disc, macular thinning, and arcuate scotoma in the visual field to the disruption in circulation caused by intense inflammation in the peripapillary and macular areas. Our patient presented with the most severe expression of the MEWDS spectrum with a more severe disease course.

The following differential diagnoses should be considered: punctate inner choroidopathy, acute posterior multifocal placoid pigment epitheliopathy, serpiginous choroidopathy, birdshot chorioretinopathy,

acute zonal occult outer retinopathy, and multifocal choroiditis with panuveitis. The majority of these syndromes are bilateral and the presence of retinal lesions, disruption of the IS/OS junction, and hyperfluorescence in a wreath-like pattern with late staining in retinal lesions during the early stage of FFA (characteristic features of MEWDS), made our diagnosis much easier.

Although all signs and symptoms were resolved completely during the natural course of the disease, cases of chorioretinal scar, peripapillary atrophy, and choroidal neovascular membrane have also been reported.⁵ To the best of our knowledge, there is no case presentation in the literature reporting a delay in the phases of FFA in the active period, and development of atrophy in the optic disc, a generalized macular thinning, and an arcuate scotoma after the recovery period during MEWDS. Only Dodwell et al. reported that an arcuate scotoma developed in a case of MEWDS during the active period of the disease, but this condition resolved completely later.⁸

Therefore, our case contributes significantly to the literature on these atypical clinical features.

Source of Finance

During this study, no financial or spiritual support was received neither from any pharmaceutical company that has a direct connection with the research subject, nor from a company that provides or produces medical instruments and materials which may negatively affect the evaluation process of this study.

Conflict of Interest

No conflicts of interest between the authors and / or family members of the scientific and medical committee members or members of the potential conflicts of interest, counseling, expertise, working conditions, share holding and similar situations in any firm.

Authorship Contributions

Idea/Concept: Murat Okutucu; **Design:** Murat Okutucu; **Control/Supervision:** Murat Okutucu, Hüseyin Fındık; **Data Collection and/or Processing:** Murat Okutucu, Mehmet Gökhan Aslan; **Analysis and/or Interpretation:** Murat Okutucu, Mehmet Gökhan Aslan, Erkan Duman; **Literature Review:** Murat Okutucu, Erkan Duman; **Writing the Article:** Murat Okutucu, Mehmet Gökhan Aslan, Erkan Duman; **Critical Review:** Murat Okutucu, Hüseyin Fındık; **Materials:** Murat Okutucu, Hüseyin Fındık.

REFERENCES

1. Jampol LM, Sieving PA, Pugh D, Fishman GA, Gilbert H. Multiple evanescent white dot syndrome. I. Clinical findings. *Arch Ophthalmol.* 1984;102(5):671-4. [[Crossref](#)] [[PubMed](#)]
2. Slusher MM, Weaver RG. Multiple evanescent white dot syndrome. *Retina.* 1988;8(2):132-5. [[Crossref](#)] [[PubMed](#)]
3. Meyer RJ, Jampol LM. Recurrences and bilaterality in the multiple evanescent white-dot syndrome. *Am J Ophthalmol.* 1986;101(3):388-9. [[Crossref](#)] [[PubMed](#)]
4. Kimmel AS, Folk JC, Thompson HS, Strnad LS. The multiple evanescent white-dot syndrome with acute blind spot enlargement. *Am J Ophthalmol.* 1989;107(4):425-6. [[Crossref](#)] [[PubMed](#)]
5. Lombardo J. Multiple evanescent white dot syndrome and acute zonal occult outer retinopathies. *Optom Vis Sci.* 2003;80(10):673-80. [[Crossref](#)] [[PubMed](#)]
6. Nguyen MH, Witkin AJ, Reichel E, Ko TH, Fujimoto JG, Schuman JS, et al. Microstructural abnormalities in MEWDS demonstrated by ultrahigh resolution optical coherence tomography. *Retina.* 2007;27(4):414-8. [[Crossref](#)] [[PubMed](#)] [[PMC](#)]
7. Gross NE, Yannuzzi LA, Freund KB, Spaide RF, Amato GP, Sigal R. Multiple evanescent white dot syndrome. *Arch Ophthalmol.* 2006;124(4):493-500. [[Crossref](#)] [[PubMed](#)]
8. Dodwell DG, Jampol LM, Rosenberg M, Berman A, Zaret CR. Optic nerve involvement associated with the multiple evanescent white-dot syndrome. *Ophthalmology.* 1990;97(7):862-8. [[Crossref](#)] [[PubMed](#)]