



Socket preservation with high-density polytetrafluoroethylene barrier membrane during open healing

Gregor–Georg Zafiropoulos ¹, Branko Trajkovski ^{1*}

¹ Faculty of Dentistry, Kuwait University, 13110 Safat, Kuwait; ggzafi@gmx.de (G.-G.Z.)

* Correspondence: Branko Trajkovski, biobranko@gmail.com

Abstract: Bone volume loss appears after tooth extraction and socket preservation is the most applied procedure to prevent an alveolar resorption. The aim of this study was to retrospectively analyse three socket preservation cases with high-density polytetrafluoroethylene barrier membrane (permamem®) for open healing with and without the use of additional dental regeneration biomaterials. Here no bacterial plaque was present and the soft tissue completely re-epithelialized, which allowed new bone formation and implant treatment. The current findings indicate that the use of this membrane, leads to successful socket treatment during open healing.

Keywords: socket preservation; PTFE membrane; open healing



Published: 25.04.2022

DOI: <https://doi.org/10.56939/DBR221013z>

Introduction

Alveolar bone loss after tooth extraction can be an issue during dental implant placement and may result in compromised aesthetics [1]. The alveoli may have about 40% height and 60% width bone volume loss within 6 months after tooth extraction [2], [3]. Such bone resorption leads to buccal soft tissue recession and altered interdental gingival structure [4].

Socket preservation with various dental regeneration biomaterials, is the most commonly applied procedure to control the bone volume loss following tooth extractions [5]. The use of non-resorbable polytetrafluoroethylene (PTFE) barrier membranes for guided tissue regeneration, alone or in combination with particulate grafting materials, is one of such many treatment options [4]. They can be classified expanded and dense PTFE membranes, as the dense PTFE barrier has been demonstrated to provide excellent results for open healing situations in combination with xenograft particles [6]. The main difference between the expanded and dense PTFE membranes is the pore size, as the larger pore size in the extended PTFE (5-30µm) enable better stretching if compared to the dense PTFE membranes (0.2µm) [4]. While the bigger pore size allows nutrient diffusion, the expanded PTFE membranes have higher risk of infections if left exposed, which is why the dense PTFE membranes are preferred for open healing. However, not much data exists on socket preservation with a high-density PTFE (hdPTFE) membrane (permamem®, botiss biomaterials GmbH, Germany) alone and during open healing. It is a ultra-thin (~0.08 mm) thin membrane with blue color, which makes it easier to detect and remove at later stage [6].

The aim of this work was to retrospectively analyze three socket preservation cases with hdPTFE for open healing with and without the use of additional dental regeneration biomaterials.

Materials and Methods

Case 1

A 60-year-old nonsmoker male patient was presented in the private dental office of the author. Patient's main complaint was a continuous pain in the right maxilla. Tooth #16 has been endodontically treated 9 years ago and received apicectomy 1 year before initial examination (Figure 1a). Tooth #16 was diagnosed with mobility II to III and pain on palpation of the buccal site, suppuration and pocket dept >10 mm in the buccal site.

An intrasulcular incision extending to the adjacent teeth was made, a full thickness flap with vertical releasing incisions was elevated and the tooth #16 was extracted. The whole buccal wall of the socket #16 was destroyed due to previous surgeries and the chronic endo-perio inflammation (Figure 1b, 1c). Then the socket was curetted carefully and irrigated with sterile saline solution. The socket preservation was performed by using a non-resorbable high-density polytetrafluoroethylene barrier membrane (permamem® 15x20 mm, botiss biomaterials GmbH, Germany) alone and without additional use of any soft- or hard-tissue grafts. It is a pure PTFE, ultra-thin (~0.08 mm) membrane impervious to bacteria due to the highly dense, textured and non-porous structure [6], [7]. No further steps were taken to secure the membrane in place. The flap was repositioned and sutured in place with interrupted sutures as the membrane was left partially exposed during the healing period.

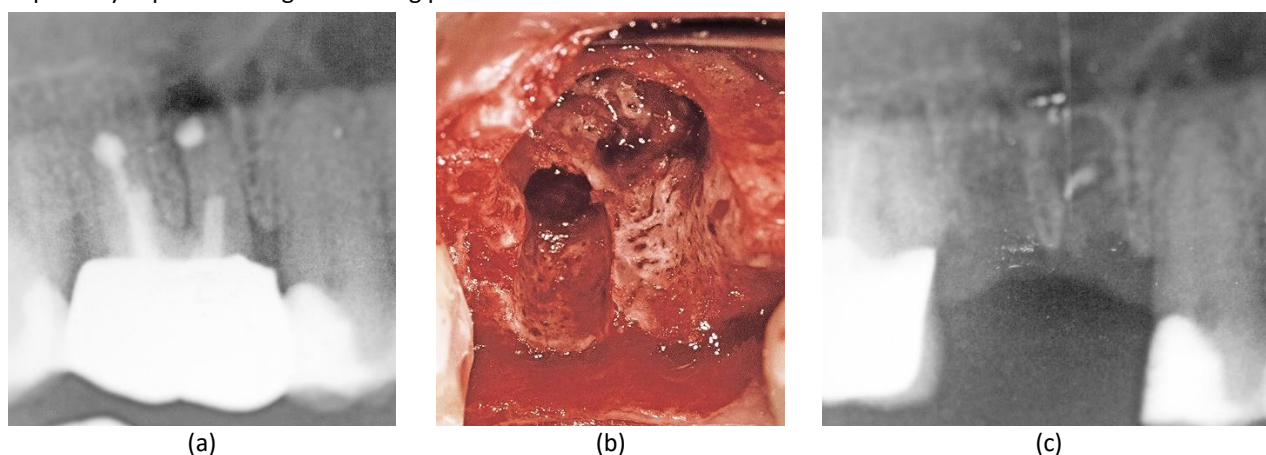


Figure 1. Extraction of tooth #16: (a) Initial situation; (b) full thickness flap; (c) destroyed buccal wall.

Case 2

A 58-year-old nonsmoker female patient was referred for periodontal and implant treatment. The diagnosis of an advanced chronic periodontitis was made (Figure 2a). The maxillary teeth and the teeth #33-36 were treated with scaling/root planning and periodontal surgery. First the teeth #43-47 were extracted (Figure 2b). Then a socket preservation was performed by two membranes permamem® 15x20 mm (Figure 2c). They were used to cover the extraction sockets and without additional use of grafting material by leaving them partially exposed after suturing (Figure 2d).

Post-operative care

The patient was prescribed analgesics and a systemic antibiotic (Clyndamycin 600 mg) twice a day for 6 days. She was instructed to start the medication one day before surgery. The patient rinsed twice daily with chlorhexidine digluconate solution 0.1% starting one day before surgery and until one week after membrane removal. Sutures were left for 10 days, and the membranes were removed at the end of the 4th week after surgery.

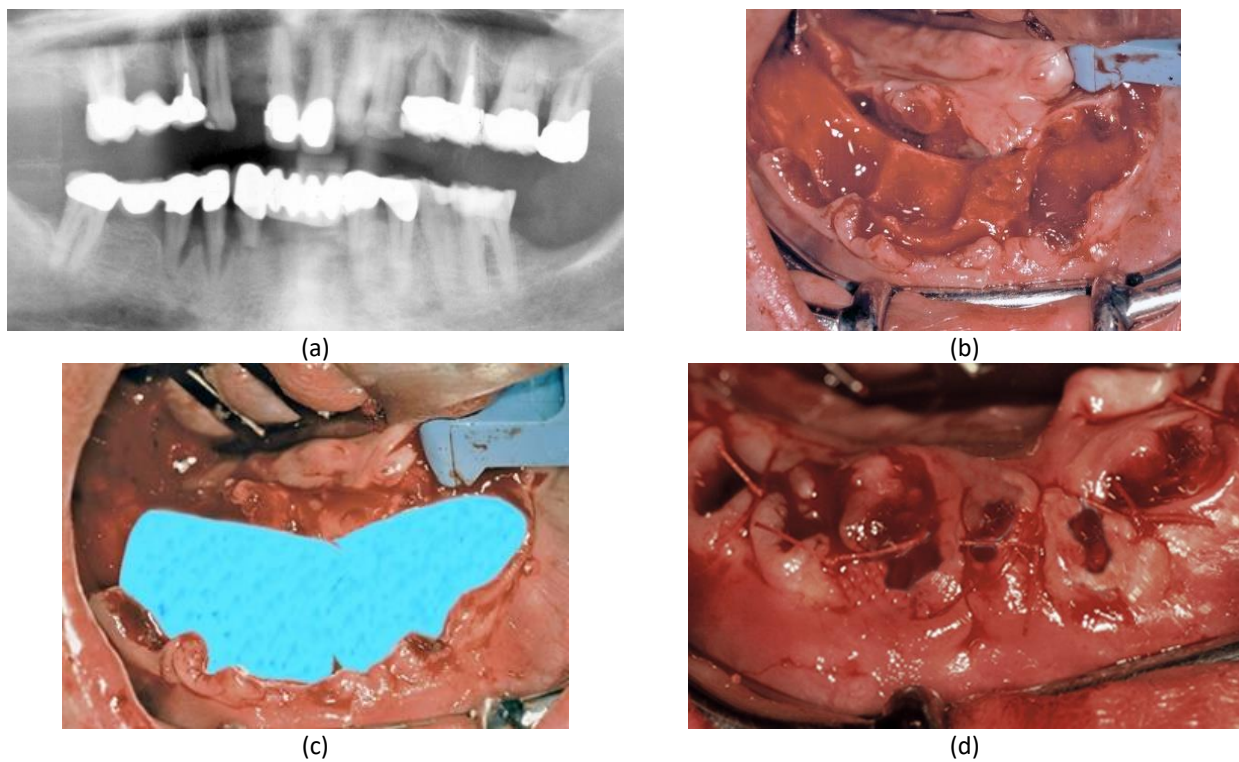


Figure 2. Open healing socket preservation with membrane only: (a) Initial situation; (b) Extraction of teeth #43-47; (c) Socket preservation with permamem®; (d) Partially exposed membranes after suturing.

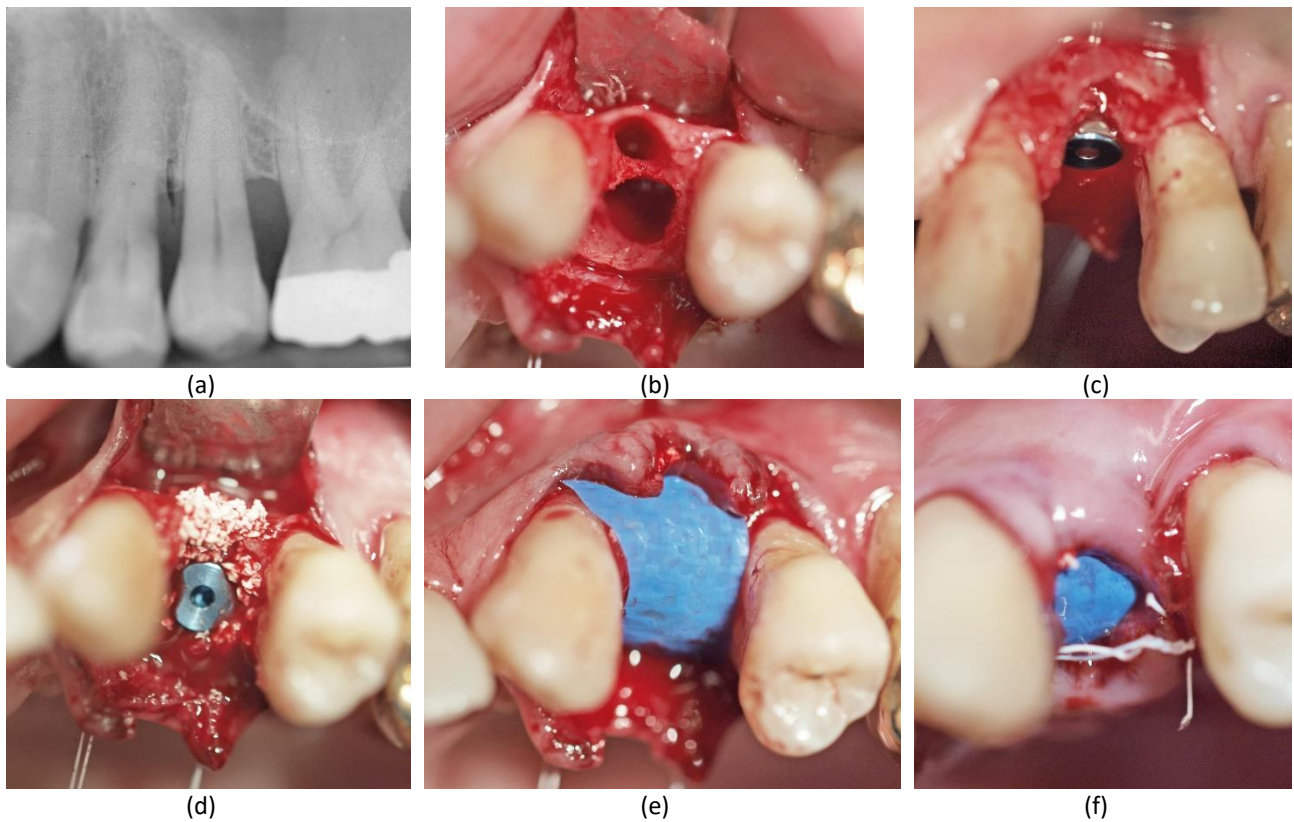


Figure 3. Open healing socket preservation with membrane and xenograft (a) Initial situation; (b) Extraction of tooth #24; (c) Immediate implant placement; (d) Augmentation with cerabone®; (e) Area coverage with permamem®; (f) Partially exposed membrane after suturing.

Case 3

A 55-year-old nonsmoker male was presented for treatment. The patient had a history of chronic periodontitis and was treated one year before. Also, three times per year he underwent supportive periodontal care program with oral hygiene sessions. Still the main complaint was pain during mastication. Therefore, a long vertical root fracture diagnosis of tooth #24 was established (Figure 3a) and then the tooth #24 was extracted (Figure 3b). Consequently, an implant (Soft Bone, 4.5 x 11.5 mm; Dentegris GmbH, Germany) was immediately placed (Figure 3c). Then the gap between implant body and the buccal bone wall of the extraction socket was augmented using a xenograft granules (cerabone® 0,5-1 mm; botiss biomaterials, Germany) (Figure 3d). Next, the area was covered with permamem® 15x20 mm after gently creation of a mucosa flap without vertical buccal and/or palatal incisions (Figure 3e). Finally, the soft tissue was fixed in the areas of the interdental papillae and the membrane left partially exposed (Figure 3f).

Results

Case 1

Four weeks later no bacterial plaque formation was present (Figure 4a). Then after membrane retrieval at the end of the 4th week, a non-epithelialized soft tissue was found in the areas previously covered by the membrane (Figure 4b, 4c). This tissue completely re-epithelialized clinically within 4 weeks after membrane removal (Figure 4d). Nevertheless, a slight but clearly distinguishable difference in color versus the adjacent mucosa persisted (Figure 4e). Clinically, the whole keratinized gingiva was preserved (Figure 4e). Due to a home accident, the tooth #17 was fractured and consequently extracted.

Six months after socket preservation, roentgenological diagnosis showed a complete bone regeneration of the area (Figure 4f). After elevation of a full flap as a part of implant surgery, the bone regeneration of the area #16 and the buccal socket's wall was observed (Figure 4g, 4h). Then an implant (SLS straight 11.5 x 5.5 mm, Dentegris GmbH, Germany) was placed, which was consequently loaded after 3 months (Figure 4i).

Case 2

Six months after sockets preservation, a full flap was elevated, and the regeneration of the sockets was observed (Figure 5a). Then 3 implants (2 implants 4.1 x 10 mm, 1 implant 4.8 x 10 mm, Straumann Group, Switzerland) were placed, and were loaded after 3 months with a fixed bridge (Figure 5b, 5c).

Case 3

During the healing period of four weeks no bacterial plaque was present, and no complications were noticed (Figure 6a). After membrane removal without flap creation and local anesthesia use, a complete coverage of the treated area with soft tissue was observed (Figure 6b), which epithelialized 10 days later (Figure 6c). Four months later, the implant was uncovered and restored with a fixed metal-ceramic crown (Figures 6d, 6e).

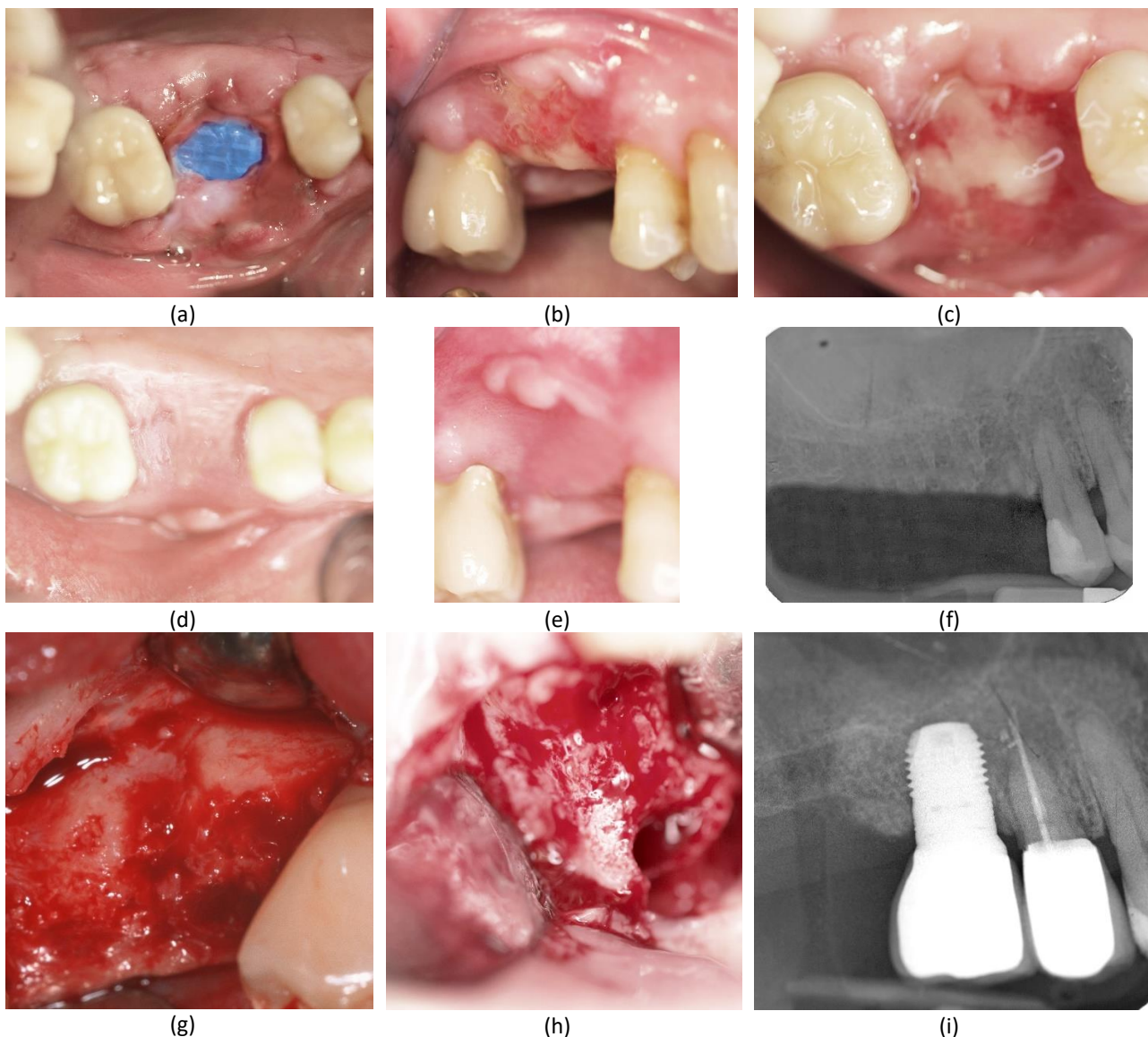


Figure 4. Follow-up and implant placement: (a) No bacterial plaque present after 4 weeks; (b) Immediately after membrane retrieval at 4 weeks post socket preservation; (c) Presence of non-epithelialized soft tissue at 4 weeks post socket preservation; (d) Completely re-epithelialized soft tissue 4 weeks after membrane removal; (e) Preserved keratinized gingiva 4 weeks after membrane removal; (f) Complete bone regeneration 6 months after socket preservation; (g) Elevation of a full flap in order to place implant; (h) Socket’s buccal wall present during implant placement at 6 months after socket preservation; (i) Implant loaded 3 months after its placement.

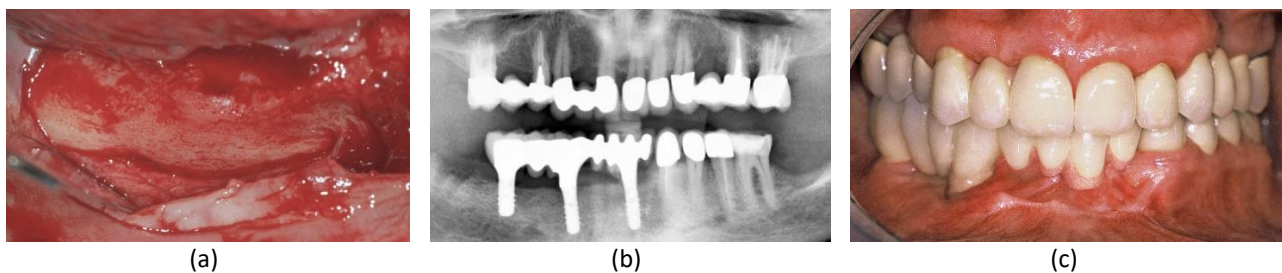


Figure 5. Follow-up and fixed bridge loading: (a) Regenerated sockets after 6 months, ready to receive implants; (b), (c) Implants loaded 3 months after their placement.

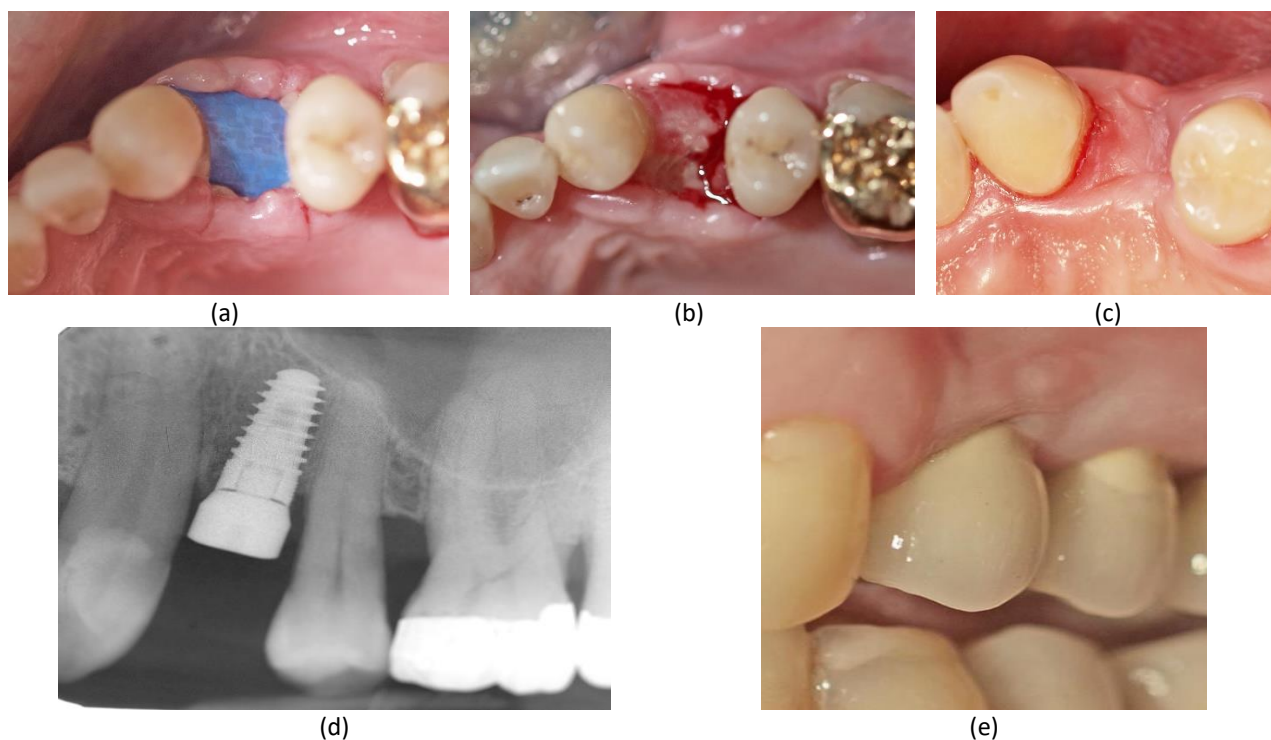


Figure 6. Follow-up and implant restoration: (a) No bacterial plaque or complications after 4 weeks; (b) Soft tissue coverage after membrane retrieval at 4 weeks post socket preservation; (c) Epithelialized soft tissue 10 days after membrane removal; (d), (e) Implant restoration 4 months after membrane removal.

Discussion

The present study demonstrated that the use of high-density polytetrafluoroethylene barrier membrane (hdPTFE) leads to successful socket treatment during open healing.

We selected permamem® as hdPTFE membrane because its exceptionally thin (~0.08 mm), impervious to bacteria due to the highly dense, textured and non-porous structure, can be used in open healing for ridge reservation (unlike the expanded PTFE membranes), with minimal or no bacterial plaque formation, which is followed by easy membrane detection and removal due to the blue color [6]. The tissue response to this membrane involves inflammatory macrophages with comparable cell numbers to the collagen membranes, which is most likely due to the PTFE purity [8]. More specifically, just like in any other foreign body reaction, it is not fully bioinert, but its biocompatibility is comparable to the collagen membranes. Also it is useful in alveolar socket preservation due to its non-bacterial permeability which enables a non-wound primary closure [9]. In addition, it proved to be effective in alveolar ridge preservation, as the regeneration was not affected by the complete exposure of permamem® [7].

Our patients received socket preservation treatment with permamem® by leaving the membrane partially exposed during the healing period (Figure 2, 3). The membranes were removed at 4 weeks after surgery and no bacterial plaque was present during removal (Figure 4, 6). Here an immature soft tissue was observed during membrane removal that completely covered the socket. However, the soft tissue completely re-epithelialized after 4 weeks in all patients and enabled new bone formation (Figure 4, 5, 6). During the two-stage implantation process without grafting material use, it was possible to install implants six months after socket preservation, that were loaded three months later (Figure 4, 5). However, the immediate implantation with xenograft augmentation enabled implant restoration at four months after the membrane removal (Figure 6).

Conclusions

Within the limitations of this study, the current findings indicate that the use of high-density polytetrafluoroethylene barrier membrane leads to successful socket treatment during open healing. No bacterial plaque was present before membrane removal and the soft tissue completely re-epithelialized in all patients, which allowed new bone formation capable for implant placement and restoration. Further study with bigger number of patients is necessary to verify the current findings.

Funding and conflict of interest statement: The author claims no conflict of interest and no funding or sponsorship was received for this work.

Board review and informed consent statement: The patients were informed about the planned procedures and informed consent was provided. The local health authorities allow such work to be published with informed consent only.

References

- [1] S. Hansson and A. Halldin, "Alveolar ridge resorption after tooth extraction: A consequence of a fundamental principle of bone physiology," *J. Dent. Biomech.*, vol. 3, no. 1, pp. 1–8, 2012, doi: 10.1177/1758736012456543.
- [2] K. Johnson, "A study of the dimensional changes occurring in the maxilla following closed face immediate denture treatment*," *Aust. Dent. J.*, vol. 14, no. 6, pp. 370–376, Dec. 1969, doi: 10.1111/j.1834-7819.1969.tb02290.x.
- [3] J. Pietrokovski and M. Massler, "Alveolar ridge resorption following tooth extraction," *J. Prosthet. Dent.*, vol. 17, no. 1, pp. 21–27, 1967, doi: 10.1016/0022-3913(67)90046-7.
- [4] N. Rathnayake, B. Trajkovski, B. Rahman, and G.-G. Zafiroopoulos, "Clinical applications and outcomes of non-resorbable polytetrafluoroethylene (PTFE) membranes: Review," *J Int Med. Dent. Res*, vol. 12, no. 4, pp. 1626–1635, 2019.
- [5] G. Troiano, K. Zhurakivska, L. Lo Muzio, L. Laino, M. Ciccì, and L. Lo Russo, "Combination of Bone Graft and Resorbable Membrane for Alveolar Ridge Preservation: a Systematic Review, Meta-analysis and Trial Sequential Analysis," *J. Periodontol.*, vol. 89, no. 1, pp. 46–57, 2018, doi: 10.1902/jop.2017.170241.
- [6] G. Zafiroopoulos, Z. P. Kačarević, S. S. B. Qasim, and B. Trajkovski, "Open-Healing Socket Preservation with a Novel Dense Polytetrafluoroethylene (dPTFE) Membrane: A Retrospective Clinical Study," *Med. 2020, Vol. 56, Page 216*, vol. 56, no. 5, p. 216, Apr. 2020, doi: 10.3390/MEDICINA56050216.
- [7] P. Papi, B. Di Murro, M. Tromba, P. C. Passarelli, A. D'addona, and G. Pompa, "The Use of a Non-Absorbable Membrane as an Occlusive Barrier for Alveolar Ridge Preservation: A One Year Follow-Up Prospective Cohort Study," *Antibiot. 2020, Vol. 9, Page 110*, vol. 9, no. 3, p. 110, Mar. 2020, doi: 10.3390/ANTIBIOTICS9030110.
- [8] T. Korzinskas *et al.*, "In vivo analysis of the biocompatibility and macrophage response of a non-resorbable PTFE membrane for guided bone regeneration," *Int. J. Mol. Sci.*, vol. 19, no. 10, p. 2952, 2018, doi: 10.3390/ijms19102952.
- [9] J. M. Heurtebise and S. Vincent-Bugnas, "Use of a new hd-PTFE membrane in alveolar socket preservation (Permamem®) – A case series," *Clin. Oral Implants Res.*, vol. 30, no. S19, pp. 451–451, Sep. 2019, doi: 10.1111/CLR.406_13509.