



LETTER TO THE EDITOR

Ultrasound-guided carotid sheath block for carotid endarterectomy surgery in a high-risky patient and literature review

Yüksek riskli hastada karotis endarterektomi cerrahisi için ultrason eşliğinde karotis kılıf bloğu ve literatür taraması

Yahya YILDIZ, Bahadır ÇİFTÇİ, Mürsel EKİNCİ, Yavuz DEMİRARAN

To the Editor,

Nowadays, there is an increasing number of the patients that underwent carotid endarterectomy (CEA) surgery.^[1–3] However, the patients usually have several comorbidities such as diabetes mellitus, coronary diseases, and hypertension.^[2,3] CEA is generally performed for patients who under the risk of ischemic cerebral stroke due to the critical obstruction of the carotid artery.^[1,2] The important point is that ischemic complications may occur during the surgery.^[4,5] Thus, the central nervous system monitoring should be performed to improve the safety.^[4] The awareness of the patient is more effective method than the monitoring methods.^[4,5] Hence, regional anesthesia techniques may be performed instead of general anesthesia for shunt placement during CEA surgery. The regional anesthesia is the favorite technique for CEA surgery since it provides the direct neurological monitoring due the awakesness of the patient.^[6,7] In addition, it provides the post-operative pain management at the same time. Ultrasound (US)-guided methods such as superficial cervical block and carotid sheath block (CSB) may be used for CEA operations.^[6,7] Herein, we aimed to share our successful US-guided CSB experience for anesthesia management during CEA surgery.

Written informed consent was obtained from the patient for this report. The patient was 72 year old man and had an ASA III class; diabetes, hyperten-

sion, and ischemic stroke. The patient underwent CEA surgery due to the obstruction of the carotid artery. The patient was taken to the operation room. He was monitored classically. 18G intravenous cannula was inserted. A dose of 2 mg midazolam and 50 mcg fentanyl IV was administrated for sedation. Nasal oxygen (2 L/min) was started continuously. While the patient was in supine position, his head was turned to the opposite site. Under aseptic conditions following the skin infiltration with 2% lidocaine 40 mg, US-guided CSB was performed. The high frequency, sterile sheath covered, and 12 MHz linear US probe were placed horizontally over the level of C5–C6 (level of the cricoid cartilage). After the visualization of the bifurcation of the carotid artery; 22G, 50 mm block needle was inserted using the in-plane technique. A dose of 2 ml normal saline was administrated on the ventral side of the carotid for correction. Then, totally 20 ml local anesthetic solution including 10 ml of 0.5% bupivacaine and 10 ml of 2% lidocaine was injected here with carefully aspiration (Fig. 1). Following 10 min performing the block, pin-prick test was performed on the surgical area. After observation no pain during the pin-prick test, the surgery was started. The operation lasted 80 mins. No additional analgesic or sedation was applied to the patient. He was comfortable and awake and he felt no pain during the surgery.

The C2–4 cervical nerves should be blocked for CEA surgery.^[6–9] Cervical plexus block and CSB may pro-

Department of Anesthesiology and Reanimation, İstanbul Medipol University Faculty of Medicine, İstanbul, Türkiye

Submitted (Başvuru) 22.02.2020 Revised (Revizyon) 02.12.2020 Accepted (Kabul) 06.07.2021 Available online (Online yayımlanma) 04.01.2023

Correspondence: Dr. Bahadır Çiftçi. İstanbul Medipol Üniversitesi Tıp Fakültesi, Anesteziyoloji ve Reanimasyon Anabilim Dalı, İstanbul, Türkiye.

Phone: +90 - 532 - 503 44 28 **e-mail:** baha_cftci@hotmail.com

© 2023 Turkish Society of Algology

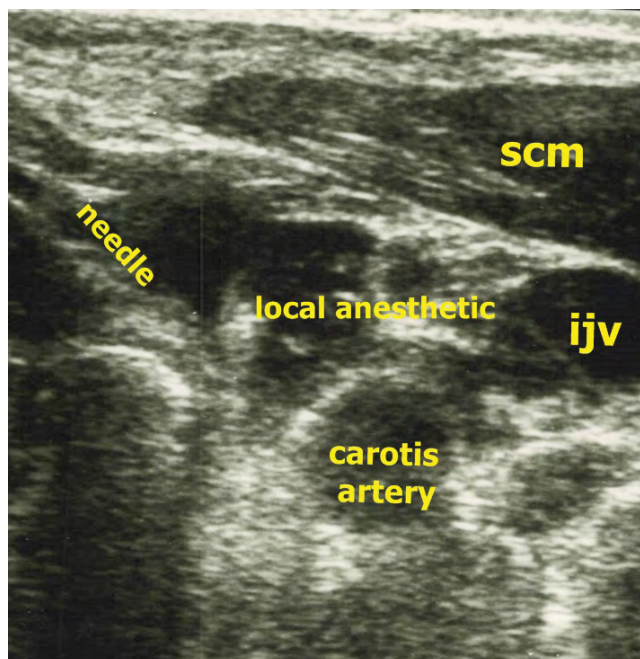


Figure 1. Sonographic anatomy, needle direction, and spread of local anesthetic around the carotid artery.

SCM: Sternocleidomastoid muscle; IJV: Internal jugular vein.

vide this blockade. Performing the block under US guidance may reduce the probably complications such as hematoma or nerve injuries. The patients underwent CEA surgery usually receives anticoagulant therapy, so there is an increased risk of vascular hematoma.^[8,9] The use of US reduces this potential risk of complication by visualization the anatomical instructions directly. Superficial or deep blocks may be performed for cervical plexus blockage.^[7] However, complications such as epidural or subarachnoid injections and vertebral artery injury may be occur during cervical plexus blockage.^[6-8] CSB may be performed safely under US guidance and it may provide effective anesthesia management.^[8] It is a sheath block because, there is no need for seeing the nerve roots or fibers. In the literature, there is only a case series about CSB. Casutt et al.^[8] performed CSB to their patients and they evaluated the injectate with computed tomography scan. They reported effective results and emphasized that the solution covers the around of the artery. We showed the spread of local anesthetic around the carotid artery during the surgery (Fig. 2). In another study, CSB was combined with superficial cervical plexus block.^[9] In that study, carotid sheath infiltration was performed by surgeons and US-guided superficial cervical plexus block was performed by anesthesiologist. Our report is the second one that CSB was performed alone for CEA surgery. Sometimes, the

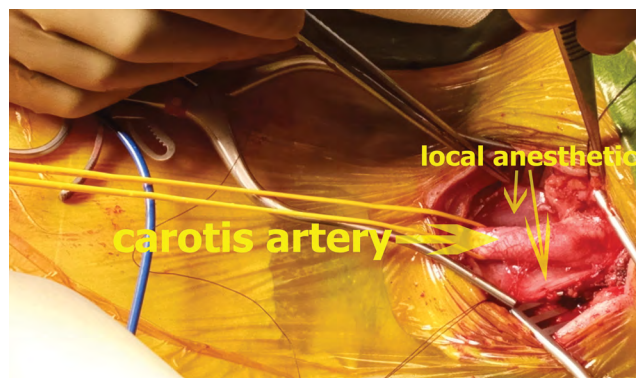


Figure 2. Spread of local anesthetic is seen surgically.

surgeons perform carotid block with blind method. We want to emphasize that this block may be safer when it is performed by an anesthesiologist under US guidance. We performed US-guided CSB in a high-risk patient and there was no complication. However, there may be some complications such as arterial punctures (to the carotid artery) resulting in hematoma, intravascular injection, local anesthetic toxicity, and intrathecal injection. It should not be forgotten that, this block may be dangerous in less skilled hands. Hence, clinicians may prefer either cervical plexus block or CSB according to their experiences. Further studies may be needed for clearly understanding the effectiveness of CSB or to compare it with the other regional methods.

We conclude that CSB may be used for both anesthesia management and post-operative pain control effectively and safely for CEA procedures.

References

1. Ricotta JJ, Aburahma A, Ascher E, Eskandari M, Faries P, Society for Vascular Surgery, et al. Updated Society for Vascular Surgery guidelines for management of extracranial carotid disease. *J Vasc Surg* 2011;54:e1–31. [\[CrossRef\]](#)
2. Alamowitch S, Eliasziw M, Algra A, Meldrum H, Barnett HJ; North American Symptomatic Carotid Endarterectomy Trial (NASCET) Group. Risk, causes, and prevention of ischaemic stroke in elderly patients with symptomatic internal-carotid-artery stenosis. *Lancet* 2001;357:1154–60.
3. Liapis CD, Bell PR, Mikhailidis D, Sivenius J, Nicolaidis A, ESVS Guidelines Collaborators, et al. ESVS guidelines. Invasive treatment for carotid stenosis: Indications, techniques. *Eur J Vasc Endovasc Surg* 2009;37(Suppl 4):1–19. [\[CrossRef\]](#)
4. Schneemilch CE, Ludwig S, Ulrich A, Halloul Z, Hachenberg T. Somatosensory evoked potentials and biochemical markers of neuronal deficits in patients undergoing carotid endarterectomy under regional anesthesia. *Zentralbl Chir [Article in German]* 2007;132:176–82.
5. Hans SS, Jareunpoon O. Prospective evaluation of elec-

- troencephalography, carotid artery stump pressure, and neurologic changes during 314 consecutive carotid endarterectomies performed in awake patients. *J Vasc Surg* 2007;45:511–5. [\[CrossRef\]](#)
6. Hakl M, Michalek P, Sevcík P, Pavlíková J, Stern M. Regional anaesthesia for carotid endarterectomy: An audit over 10 years. *Br J Anaesth* 2007;99:415–20. [\[CrossRef\]](#)
 7. Messner M, Albrecht S, Lang W, Sittl R, Dinkel M. The superficial cervical plexus block for postoperative pain therapy in carotid artery surgery. A prospective randomised controlled trial. *Eur J Vasc Endovasc Surg* 2007;33:50–4.
 8. Casutt M, Breitenmoser I, Werner L, Seelos R, Konrad C. Ultrasound-guided carotid sheath block for carotid endarterectomy: A case series of the spread of injectate. *Heart Lung Vessel* 2015;7:168–76.
 9. Mądro P, Dąbrowska A, Jarecki J, Garba P. Anaesthesia for carotid endarterectomy. Ultrasound-guided superficial/intermediate cervical plexus block combined with carotid sheath infiltration. *Anaesthesiol Intensive Ther* 2016;48:234–8. [\[CrossRef\]](#)