

This is a provisional PDF only. Copyedited and fully formatted version will be made available soon.



**ISSN:** 2449-6170

**e-ISSN:** 2449-6162

## **Methods for the assessment of microcirculation in patients with hypertension**

**Authors:** Katarzyna Lewandowska, Dorota Marzyńska, Patrycja Rzeszoś, Alicja Partyka, Franciszek Dydowicz, Mikołaj Lewandowski, Regina Pawlak-Chomicka, Andrzej Tykarski, Paweł Uruski

**DOI:** 10.5603/AH.a2023.0004

**Article type:** Review paper

**Submitted:** 2022-08-12

**Accepted:** 2022-12-18

**Published online:** 2023-01-31

This article has been peer reviewed and published immediately upon acceptance. It is an open access article, which means that it can be downloaded, printed, and distributed freely, provided the work is properly cited.

The final version may contain major or minor changes.

## **Methods for the assessment of microcirculation in hypertensive patients**

### **Short title: Microcirculation in hypertensive patients**

Katarzyna Lewandowska, Dorota Marzyńska, Patrycja Rzeszoś, Alicja Partyka, Franciszek Dydowicz, Mikołaj Lewandowski, Regina Pawlak-Chomicka, Andrzej Tykarski, Paweł Uruski

*Department of Hypertensiology, Angiology and Internal Medicine, Poznan University of Medical Sciences, Poznan, Poland*

**Address for correspondence:** Katarzyna Lewandowska, MD, Department of Hypertensiology, Angiology and Internal Medicine, Poznan University of Medical Sciences, Długa 1/2, 61–848 Poznan, Poland, tel: (+48) 512 809 952, e-mail: katarzyna.piotrowska93@gmail.com

### **Abstract**

**Background:** Skin microcirculation is considered an easily accessible vascular bed, which can potentially be representative and helpful in evaluating, understanding the mechanisms of microvascular function and detection of its dysfunction. Many studies claim that functional changes in cutaneous circulation precede the development of arterial hypertension (HT). Identifying them at an early stage can enhance patients prognosis. There are methods which can be applied for these purposes. We aimed to describe available methods of skin microcirculation assessment, in the context of HT.

**Material and methods:** The PubMed database was searched till March 2022. Research articles used in the systematic review were experimental articles, reviews and abstracts from conference materials that reported the methods of the microcirculation assessment. From 1131 records, 47 articles were included in the final review.

**Results:** This review identified that the microcirculation examined with various methods was dysfunctional in HT patients. Standard HT treatment usually helped to achieve a partial

reversal of those changes. Even though some of the methods described are non-invasive and relatively affordable, still, none of them is the standard for HT diagnosis.

**Conclusion:** Each of the methods, has its advantages and disadvantages. Photoplethysmography appears to be promising. The method is non-invasive, cheap, does not require experience, might be synchronised with mobile devices. Its possible that the simplification of the device calibration process and the development of a method allowing for the correct interpretation of the result, regardless of e.g., the patient's skin colour, could influence its wider use in the group of HT patients.

**Keywords:** arterial hypertension; microcirculation; skin; microvascular rarefaction

## **Introduction**

Arterial hypertension (HT) is one of the most common lifestyle diseases worldwide, including Poland. According to World Health Organisation, as many as 1,28 billion adults worldwide were suffering from HT in 2011 — a half were unaware of their disease. It is claimed that approximately 10 million of deaths annually are the result of improperly high blood pressure values (BP) [1]. It is estimated that the number of HT patients will exceed 1,5 billion by 2025. Therefore, it classifies HT as a major global healthcare problem [2].

According to the WOBASZ II study, more than 40% of the adult Polish population were diagnosed with HT. A constantly increasing trend of newly diagnosed HT, besides diabetes mellitus, dyslipidaemia and tobacco use, account for one of the main cardiovascular risk factors [3]. Uncontrolled HT contribute to the development of severe organ damage, including cardiac failure, myocardial infarction, brain stroke, aorta damage, or hypertensive encephalopathy. Organ complications are preceded by damage to vessels and microvasculature [4].

The main role in vascular pathology is the damage of two components that build the vascular wall: endothelial and smooth muscle cells. In HT, damage it is initially seen in small vessels, including microvasculature, the so-called resistance vessels, formed by arterioles, capillaries and venules, which diameter does not exceed a few hundred  $\mu\text{m}$  [5]. The microcirculatory vessels mediate between the arterial and venous vascular systems. They are responsible for the oxygen and nutrients supplied to the tissues and protection against major fluctuations in hydrostatic pressure, which could affect the exchange of substances in the

capillaries (5)(6). In patients with HT, the skin microcirculation is among the first to be affected [7].

BP depends on vascular resistance and cardiac output. Vascular resistance is regulated at the arteriolar level and is controlled by hormonal as well as neural factors. Both, an increase in vascular resistance and higher BP, result in more potent vasoconstriction through autoregulation. Long-term tension of vascular wall's smooth muscle cells leads to structural changes in these cells [8–10].

In hypertensive patients, a continuous decrease in diameter or even complete closure of the vessel lumen is observed due to a decrease in the ratio of the thickness of the middle membrane to the vessel lumen [10–14]. In addition, an increase in the tone of smooth muscles of the vascular wall maintained chronically in HT leads to remodeling, known as eutrophic inward remodeling [14]. In the microcirculation of patients with HT, there is observed a reduction in the density of the capillary network, by up to 10-20% in unit of volume of skin, conjunctiva and skeletal muscle. The probable cause of this phenomenon is a destruction of an already existing vascular network due to shear forces [14–16].

A second reason for this phenomenon is a disruption of angiogenesis, caused by dysfunction of the vascular endothelium [5]. The inner walls of all vessels in the human body, including microcirculatory vessels, are covered by endothelial cells [5]. The long-term increase of BP in a microcirculatory vessels (> 30 mm Hg), due to mechanical stress, damages an endothelial cells. The endothelium has numerous functions in the human body, including endocrine functions related to the secretion of substances responsible for coagulation regulation, fibrinolysis, platelet aggregation, angiogenesis, immune and inflammatory processes, up to a function related to the autoregulation of vascular tone [5]. Therefore, its dysfunction impairs angiogenesis and promotes vascular rarefaction, which may be reversible in HT by antihypertensive treatment implementation [17, 18].

Nitric oxide (NO), secreted by the endothelium, plays a major role in maintaining an appropriate vascular wall tone. It increases vessel lumen through vascular smooth muscle relaxation, thus reducing vascular resistance [5]. When arterial pressure in resistance vessels is increased due to HT, endothelial cell swelling occurs, destroying the vessel wall and exacerbating the inflammatory cascade in the endothelium [5, 10]. As a result, vascular homeostasis, maintained by vasoconstrictive (mainly endothelin) and vasodilatory (mainly NO) substances secreted by the endothelium, is disrupted. Other processes regulated by the

endothelium are also impaired resulting in increased risk of thromboembolism or elevated production of free radicals, intensifying the endothelial destruction cascade. In consequence of endothelial cell dysfunction, the stimulation of smooth muscle proliferation and an increased cellular matrix production occur [5, 10]. Those microcirculatory remodelling processes induced by shear forces and endothelial damage, associated with disruption of mainly endocrine endothelial function, lead to vasoconstriction of resistance vessels, long-term increase in systemic vascular resistance, damage of the microcirculation and as a consequence in decrease of capillary density [5, 11].

The next stage of increased vascular resistance is damage of larger vessels. This process, at the beginning, is observed as an increase in vascular stiffness, changes in the pulse wave image, and then, as a result of hemodynamic forces. Further dysfunction and damage to the wall, leading to the development of atherosclerotic plaques. The development of atherosclerosis promotes the occurrence of numerous organ complications in patients with HT [4]. The damages connected with the development of diseases and cardiovascular events influence not only the quality, but also the lifespan of the patients [19].

Early diagnosis of microcirculatory changes, as the first sign of the damage due to HT, is crucial in HT patient assessment to prevent severe organ damage. The article aims to give a systematic review of available testing methods utilized in the group of HT patients, which enables the assessment of the severity of HT complications on the level of microcirculation damage.

## **Material and methods**

### ***Inclusion criteria***

The studies included in this systematic review were: original articles, reviews and abstracts from conference materials, published till March 2022. Article searches were limited to publications in English and Polish. The articles were related to the study aim and concerned various methods for assessment of the skin microcirculation, their working principles, applications, strengths and weaknesses. We included studies involving adult patients, healthy volunteers and adult hypertensive patients, in which microcirculation was evaluated using different methods.

## ***Exclusion criteria***

We excluded from our review case studies and studies conducted on animal or in vitro models.

## ***Article search strategy***

Search location for articles was originating from PubMed database. Screening and selection of articles was conducted from March to June 2022. The search MeSH descriptors were ("Investigative Techniques"[MeSH Terms] OR "Diagnostic Techniques and Procedures"[MeSH Terms]) AND "Hypertension"[MeSH Terms] AND ("Microcirculation"[MeSH Terms] OR "Microvascular Rarefaction"[MeSH Terms]) obtaining 1131 records. Additionally, the search was broadened by 8 articles, which got included using the snowball method. We reduced a systematic search to studies carried out on humans, over 18 years old, clinic trials, reviews and conference abstracts, published in English or Polish, which identified 394 records. Duplicates were removed. Three independent reviewers then reviewed articles with relevant titles and abstracts. The fourth researcher reviewed the selection in case of disagreement. Articles with relevant titles and abstracts were subsequently reviewed in full-text. Finally, 47 articles were included in this analysis. In the presented review we listed only the methods which described the studies held on a group of patients with HT. The study selection flowchart is shown in Figure 1.

## **Results and discussion**

### ***Methods for the assessment of skin microcirculation in hypertensive patients***

Methods evaluating microcirculation in most cases are based on a temporary occlusion and/or dilatation of a vessel, which enables the assessment of blood supply and changes in blood flow in the examined tissue. Non-invasive methods are usually extended with additional components like: medications administered by the systemic route or provocation testing [20]. Among the most common tests we can distinguish:

- 1) post-occlusive reactive hyperemia (PORH) — is based on a vessel occlusion followed by its observation with an objective methods, temporarily increasing skin circulation (reactive hyperemia) after the release of the blood flow blockage. It results in endothelium-dependent vasodilatation of precapillaries, which causes the recruitment

of bigger amount of capillaries. In normal conditions, the flow through those vessels would be slower. The occlusion of a vessel is performed by using a sphygmomanometer cuff, typically on a shoulder. The vessel closure lasts at least 5 minutes. An increase in blood circulation, straight after the release of the cuff pressure, is considered correct. Among patients with HT, blood flow is impaired instantly after the release of the occlusion [21, 22].

- 2) venous occlusion test (VO) — is based on evaluating the level of hyperemia of the investigated tissue. The occlusion of venous vessels is performed using a sphygmomanometer cuff, which is then less inflated compared to the one used in PORH method. The smaller pressure allows to blocking flow only in venous vessels.
- 3) Pressure-induced vasodilatation (PIV) — is based on inducing of a temporary vasodilatation triggered by the external skin compression. The etiology of the observed hyperemia is multifactorial and is explained by a defensive mechanism for a short-term ischemia. The reaction is impaired, especially in older patients, which are the typical group for HT occurrence.
- 4) Local thermal hyperemia (LTH) — is based on a thermally triggered blood flow increase. The skin is heated with a special probe. The highest effect is achieved when the temperature reaches 42–44°C. The two-stage reaction can be observed. The first phase is a quick peak of the flow dependent on axon reflex. The second phase, plateau, is determined by a NO released by an endothelium. Vasodilatation properties of the microcirculation are diminished in the group of HT patients [23].
- 5) Ionophoresis of vasoactive agents (i.e. acetylcholine, sodium nitroprusside, L-arginine) — pharmacologic test for a vessel reactivity assessment. The dissolved substances of choice in the ionized form are placed on clear skin. These ions penetrate percutaneously, with the help of an electric current, into the vicinity of the vessels [20].

### **Laser Doppler flowmetry (LDF)**

Laser Doppler flowmetry (LDF) is a non-invasive method of microcirculation assessment using the Doppler affect. The examination includes a real time evaluation of the red blood cell flow in the approximate volume of 1 mm<sup>3</sup> tissue. The device emits a beam of laser light which undergoes changes in wavelength (Doppler shift) when it hits moving blood cells. The reflected beam returns to the detector, where the reflected light spectrum is analysed in terms of distribution of wavelengths. On this basis, the quantity and speed of red blood cells are

evaluated in a tissue as it generates the directly proportional voltage. Then it's illustrated as a flow spectrum (blood supply of the examined area in perfusion unit) in arbitrary Perfusion Units [24].

The test can be conducted on a surface of any organ, but it's usually performed on a skin. Simplicity and non-invasiveness of the method causes that it's used to assess an effectiveness of a treatment, pharmacologic and non-pharmacologic ones, on a microcirculation in case of different medical conditions including HT. Unfortunately, the method is characterized by poor spatial resolution as it captures a small area of the tissue and then reproducibility. The results assessing the circulation depending on an examined area can differ up to 100% and depend on the environmental conditions (i.e., body temperature, smoking, drinking caffeine), what additionally hinder a correct measurement performance [24].

For many years LDF was utilized for examination of a microcirculation changes in HT patients, mainly to assess a response to treatment. Cesarone et al. while evaluating the response to treatment in patients with HT found out that the blood flow in the examined area was much lower comparing to the healthy control group. Those parameters got better after nifedipine administration [25]. Nahid et al. assessed microcirculation in three different groups of patients: elderly and healthy; long-term HT and younger & healthy patients. They used PORH test to evaluate reactive hyperemia. The post-ischemic phase was registered by LDF as the increase of detected signal (maximal flow after the occlusion), and then the signal returned to the baseline. The difference between the HT and the healthy group was significant, no matter if it was compared to the healthy & young or elderly group. At the same time there were no significant differences between the healthy groups – young and elderly. The authors concluded then that an epithelial dysfunction of a microcirculation is not age dependent [26]. Sieg-Dobrescu et al. observed drop of post-ischemic circulation in the hypertensive patients without treatment [27].

### **Laser Doppler imaging (LDI)**

Laser Doppler imaging (LDI) is a method of microcirculation assessment based on LDF. LDI enables to evaluate and visualize the perfusion of a big area, much bigger than in case of LDF. Thanks to that modification it is possible to assess the change of the flows in microcirculation. Due to the necessity of scanning of a bigger area, the drawback of the method is worse time resolution.



Aellen et al. examined the microcirculation, and more precisely the density of capillaries, based on video capillaroscopy and LDI in 3 patients' groups: A: healthy individuals; B: HT patients; C: patients with HT and diabetes mellitus type 2. The authors did not distinguish any significant differences between the groups. Occurrence of diabetes mellitus type 2 among HT patients did not have influence on worsening of microcirculation function [28].

### **Laser speckle contrast imaging (LSCI)**

Laser speckle contrast imaging (LSCI) is a microcirculation and endothelial function assessment method, which is a combination of LDF and LDI, but characterized by a very good time resolution (a measurement is instant), spatial resolution (big examined area) and measurement repeatability [29, 30]. The method uses laser and a high-resolution special camera. The targeted skin area is irradiated with laser light, and then the two-dimensional image of the circulation built by different speckles is registered. The diversity and changes in intensity of speckles of the same location enables to calculate the velocity of the components. The contrasts achieved in the image are interpreted as the perfusion. The lower the contrast, the higher the perfusion is. LSCI method enables to obtain up to 100 perfusion images per second. The circulation is expressed in the same perfusion units as LDF or LDI [29–31].

Lazaridis et al. evaluated the microcirculation function using LSCI and PORH testing in the group of patients with untreated, recently diagnosed, masked HT and healthy volunteers. The HT status determined the microcirculation condition. Patients with untreated and masked HT did not differ from each other and presented with impaired microcirculation function. The authors presented LSCI as a new method, which could be useful in an evaluation of microcirculation among HT patients [32].

### **Venous occlusion plethysmography (VOP)**

Venous occlusion plethysmography (VOP) is a method that evaluates the change in volume of an extremity after venous occlusion (upper limb — forearm area, less often lower limb). The occlusion-induced changes in vascular hydrostatic pressure allow for measuring blood flow and vascular permeability in the skeletal muscles. Venous occlusion of the arm (using a sphygmomanometer cuff filled to 40 mm Hg) is interrupted at intervals of several seconds. This makes the arterial inflow unchanged, and venous blood can flow into the forearm. A linear increase in forearm volume over time is observed, which volume is measured by a

plethysmograph. The test result presented as flow in the unit ml/100ml forearm volume/minute. Similar to the hyperaemia test described above, an increase in flow is observed correctly after occlusion is inhibited [33].

The test is mainly used in a group of so-called vascular patients, to assess venous capacitance, diagnose venous thrombosis, or evaluate the process of recanalization of venous vessels. There are few studies evaluating microcirculation based on VOP in HT patients.

Junqueira et al. studied the correlation between markers of inflammation (CRP, endothelin, adiponectin, I-CAM, and V-CAM) and parameters assessing microcirculation obtained with VOP — in a group of patients with HT. They compared patients with refractory and mild-to-moderate NT and normotensive patients. The lowest percentage of the maximal blood flow was observed in the group of patients with resistant HT. The groups did not differ after the local injection of nitroglycerin. Patients with severe hypertension and uncontrolled BP levels were characterized by a significant impairment of vascular reactivity as assessed by VOP [34].

### **Photoplethysmography (PPG)**

Photoplethysmography (PPG) is a non-invasive, optic method enabling a microcirculation assessment based on a blood volume changes in a vascular bed of an examined tissue - the vessels located close to a skin surface. In PPG a slight fluctuation connected with an infrared light intensity are measured. The changes are based on the perfusion shifts of the tissue. During the examination, a probe emitting the aforementioned light is placed on the skin. The light waves are variously absorbed depending on the structures they meet on their way (including formed blood elements, skin pigments), so the absorption depends on a level of filling of a vascular bed. Then reflected waves are detected by PPG sensor — a photodetector to measure the intensity of reflected light from the tissue. The results are presented as a curve representing changes of a blood volume flowing through an examined area [35].

Zheleznykh et al. evaluated an influence of implementation of a HT therapy (perindopril + indapamide) on a microcirculation/endothelial function with PPG in the patients with HT. For this purpose, they set an occlusion index, which provided them information about the endothelial function and a reflection index, which value indicated the vessel wall remodeling. To designate those values, they measured and analysed the pulse wave registered with PPG before and after the radial artery closure. Those parameters examined by PPG got improved

after the drug administration [36] However, there are new studies revealing a correlation of waves examined with PPG and systolic BP. A combination of PPG and mobile devices sheds a new light on the methods of BP measurement. Perhaps in the near future PPG will replace the traditional BP measure method and with its help patients will can effectively identify and monitor HT [37–39].

The method is non-invasive, cheap and does not require an experience. Additionally, its possibility to synchronic with mobile devices. Nevertheless, due to the numerous factors which can influence on the achieved curve of an examined area (including skin tone, clinical factors) and a need of calibration for patients' individualization, the method is still not considered as fully reliable in a group of HT patients [39].

### **Near-infrared spectroscopy (NIRS)**

Near-infrared spectroscopy (NIRS) is a a method of the microcirculation evaluation used in case of brain blood flow, including during a perioperative management [40]. The change of haemoglobin oxygenation is evaluated. NIRS rely on constant, non-invasive optic measurement, utilizing Lambert-Beer's law. The device emits waves with a length of 700–1300 nm. Those penetrate encountered organs to the depth of 20–25 mm. The detector captures changes in the absorption of light for haemoglobin, myoglobin and AA<sub>3</sub> cytochrome in microcirculation, what enables to assess the level of tissue oxygenation. In practice there are two distinguished types of NIRS. The first one, so called nonabsorbing NIRS lets to assess different parameters including velocity of blood flow in microcirculation. The second one, absorbing NIRS, enables to determinate the level of oxygenation and nutrition of tissues [41].

There are not many studies describing the NIRS usage for microcirculation assessment among the group of HT patients. Jones et al. utilized NIRS to evaluate reactive hyperemia (PORH) of HT patients and normotensive ones. Time needed to achieve the peak after the occlusion cessation among HT patients was significantly longer comparing to the normotensive group. HT occurrence was connected with an impaired vessel's respond in skeletal muscles to occlusion. The researchers presented NIRS as a non-invasive tool, which could enable to detect changes in microcirculation in HT patients [42]. There is still a lack of studies, which evaluate a true prognostic value of the method.

### **Orthogonal polarization spectroscopy (OPS)**

Orthogonal polarization spectroscopy (OPS) is a method which utilizes polarized light of 548 nm wavelength, which represents the length of light absorbance of haemoglobin — both oxygenated and deoxygenated one. Thanks to that, haemoglobin becomes a contrast agent itself, what enables to visualize microcirculation and perfusion evaluation. Emitted light undergoes the first polarization with the help of lenses set, and then it is projected through a beam splitter onto the examined area. When it hits a tissue, it reflects, and then after passing through the second lens it undergoes polarization once again. Around 10% of light penetrates the tissue more deeply and diffuses. Doubly polarized light gets to the analyser, from where it is projected into a CCD video camera, where blood vessels of the microcirculation can be visualized. The observation of blood cells movement accompanied by computer analysis enables the assessment of the examined tissue [43, 44]. The method also provides such an option as evaluation of vessel diameter or density of capillaries.

He et al. conducted a randomized double-blinded study assessing if decreased salt intake is connected with skin capillary rarefaction. The study group consisted of white, black, and Asian individuals, all with nontreated HT. To assess the density of capillary bed they used OPS and capillaroscopy. In all of the group they implemented salt intake reduction from 9,7 to 6,5 g/day. It resulted in the increase of density of capillaries. The authors concluded that such a small intervention (reduction of salt intake) can affect a microcirculation and tissues perfusion [45]. That is why the microcirculation evaluation is important on the early stage. There are not many studies conducted on a group of HT patients. Results depends on movement artefacts and BP changes. Testing is time consuming itself, what makes that method not commonly used on that group of patients.

### **Optical coherence tomography (OCT)**

Optical coherence tomography (OCT) is a non-invasive, high resolution and sensitivity method. Light interference phenomenon is used for evaluation of microcirculation. Near-infrared light is projected to the examined area. Waves reflected from the surface are analysed, what gives an information about depth, at which the reflection took place. It enables to create a spatial map of an examined tissue. The method is mainly used by ophthalmologists is eye fundus assessment as OCT angiography (OCTA) [46].

Donati et al. used OCTA in assessment of microcirculation in HT patients in order to study a role of early diagnosis of HT. The group consisted of: 1 — patients with HT; 2 — healthy patients (control group). Results indicated significant microcirculation rarefaction in case of

the first group of patients. Additionally, they had bigger avascular zone than healthy patients. Mean foveal choroidal thickness was much thinner in the group of HT patients. Also mean retinal vascular thickness was affected in the first group of patients. For these reasons the researchers suggested that OCTA could become a relevant screening test identifying an early marker of systemic diseases [47]. Meta-analysis of 11 studies comparing selected OCTA parameters in the group of HT patients showed that eyes of HT individuals have lower superficial and deep vascular densities at the macula in comparison with healthy patients. The authors also indicated that OCTA was a useful tool in microcirculation assessment in HT patients [48]. The changes observed in eye microcirculation are consistent then with those observed in skin microcirculation of HT patients – in both cases it results in capillary rarefaction.

### **Capillaroscopy**

Capillaroscopy is a non-invasive method that evaluates the microcirculation of the skin and mucous membranes using a light microscope. The examiner mainly evaluates the capillaries of nail walls of fingers II-V of both hands. They describe the condition of the nail plate, capillary array and architecture, the number, quality, morphological type, and tension of the capillary loops. Additionally, they evaluate skin transparency and visibility [49, 50].

Microcirculation on repeated examinations changes significantly during the course of the disease, unlike in healthy subjects. Capillaroscopy is a simple and reproducible method of assessing microcirculation [50].

Mishra et al. compared patients with newly diagnosed hypertension with normotensive subjects on capillaroscopy. In the study group, mean capillary density (MCD) was significantly lower than in controls. In addition, capillary morphological changes were more common in HT patients (including meandering capillaries, non-vascular areas, dilated capillaries, or microbleeds). In patients with hypertension, retinopathy and microalbuminuria, MCD was lower, and dilated capillaries and nonvascular areas were more frequently observed. The authors suggested the usefulness of capillaroscopy in the early detection of cardiovascular complications [51].

The study by He et al. cited when describing the OPS method showed that reducing dietary salt intake significantly increased capillary density in patients of three races with hypertension

(black, white, and yellow). The capillaroscopy results were consistent with data obtained in the OPS study [45].

### ***Videocapillaroscopy***

Videocapillaroscopy is a modern variation of capillaroscopic examination uses a camera, equipped with a suitable lens, transmitting the image to a computer monitor. The principles for conducting the examination are identical to those in traditional capillaroscopy. During the examination, we evaluate functional capillary density (number of vessels with flowing red blood cells in the examined area), diameters of the loops in the nail walls, and speed of flow of red blood cells. Compared to traditional capillaroscopy, this method allows for higher magnification and image modification with special software and enables storage, transmission, printing, and later comparison of results [52, 53].

Antonios et al. in their study showed that capillary density and maximal capillary density, as assessed by videocapillaroscopy, were significantly lower in HT patients compared to healthy subjects. The researchers suggest that the anatomical lack of capillaries, rather than the lack of perfusion through these vessels, is responsible for the observed lower capillary density in this group of patients [54].

Both capillaroscopy and videocapillaroscopy of the nail walls are effective tools for observing microcirculation in HT patients. However, the difficulties associated with image interpretation due to the individual variability of the vascular loop and the effects of drugs ( $\beta$ -blockers and calcium channel blockers) on vascular morphology mean that these studies still have not found widespread use in the diagnosis of hypertension [49, 55].

### **Thermography**

Thermography is a simple, relatively sensitive, and non-invasive method of evaluating microcirculation. During the test, we assess the temperature of selected body parts. A thermogram using a thermal imaging camera captures infrared radiation emitted or reflected by the area under examination and then converts it into digital images of infrared radiation on the skin (thermograms). This graphical visualization enables the creation of a two-dimensional map of skin temperature. Thus, the study allows indirect assessment of heat flow in the skin microcirculation. The variability of the temperature measurement follows the pulsatile blood flow [56]. An abnormal temperature of a particular area indicates disease [57].

The high cost of the equipment and the evaluation of flow only in the superficial layers of the skin means that clinicians rarely use this method [57].

Microcirculation in HT patients is rarely studied using thermography. However, available studies show that both static and dynamic thermography can help assess microcirculatory changes in these patients.

Kirubha et al. evaluated the relationship between temperature (measured with a thermograph) and BP. They measured BP (systolic and diastolic) using a mercury sphygmomanometer and an automatic sphygmomanometer in a group of men and women aged 18–35. They determined two regions of the forearm where, in both men and women, an increase or decrease in BP correlated with an increase or decrease in the temperature of the area under study respectively. However, the temperature variability was more pronounced in men than in women. According to the authors, the results of their study can be used in further research to develop a device for non-contact BP measurement based on infrared thermography [58].

In the study by Thiruvengadam et al., temperature values in HT patients from the neck, forearms, or feet differed significantly from those in healthy people. In addition, the authors suggest that a thermograph may be beneficial for observing hypertension without taking traditional BP measurements. In the model study, the authors obtained the highest measurement accuracy when combining variables from dynamic thermographs, static thermographs, and pulse wave velocity (PWV) [59].

### **Transcutaneous oxygen measurements (tcpO<sub>2</sub>)**

Transcutaneous oxygen measurements (tcpO<sub>2</sub>) is a method known since the 1970s; it was first applied in intensive care units, to monitor the partial oxygen concentration in new-borns. Measurement of tcpO<sub>2</sub> determines the body's ability to deliver oxygen to tissues. In this method, we evaluate the amount of oxygen diffusing from the capillaries, through the epidermis, to the electrode. The measurement can be made in any part of the body, but the most common choice is the skin of the sole surface of the foot. A tcpO<sub>2</sub> between 50-70 mm Hg is considered a reference range [60, 61]. TcpO<sub>2</sub> is an old, well-studied, simple, reproducible, but unfortunately, time-consuming method of assessing microcirculation, which has been used for many years in the evaluation of vascular diseases (such as evaluating wound healing or the effectiveness of revascularization) [62].

Cesarone et al. used several methods to evaluate skin microcirculation in patients with HT. TcpO<sub>2</sub> was significantly lower in the group of patients with HT than without it. In addition, patients showed improvement in the measured parameters after the inclusion of the calcium channel blocker — nifedipine [25].

### **The flow mediated skin fluorescence (FMSF)**

Both reduced (NADH) and oxidised (NAD<sup>+</sup>) forms of nicotinamide adenine dinucleotide participate in many essential reactions in human cells. NADH is found in the cytoplasm, nucleus, and mitochondria. Under aerobic conditions, two electrons and a proton delivered by NADH are transferred to the mitochondrial electron transport chain to produce adenosine triphosphate (ATP) particles required in cellular energy metabolism. Generally, the NADH amount reflects mitochondrial function. However, during hypoxia and anoxia, mitochondrial oxidation of NADH to NAD<sup>+</sup> is ceased, and NADH gradually accumulates in the cells.

NADH absorbs ultraviolet light at 320–380 nm and emits fluorescent light in the 420–480 nm range. The 460-nm fluorescence measurement estimates NADH in solutions and tissues, including human skin. FMSF technique measures non-invasively the 460-nm skin fluorescence at rest, during transient ischaemia and reperfusion, giving an indirect insight into microcirculation and mitochondrial function [63].

The AngioExpert device acquires the FMSF (Angionica, Poland) emitting 340 nm UV light towards the skin and measuring the induced autofluorescent light at 460 nm corresponding to the NADH emission spectrum. The emitted 460-nm fluorescence comes from the most superficial part of the papillary dermis up to 0.5 mm of the skin depth. Shortly, for the FMSM measurement, sitting participants kept their left forearm motionless. After the resting recording, the brachial cuff on the same arm was inflated for 100 seconds during the controlled ischaemia and deflated again for reperfusion. The inflation pressure, set at 60 mm Hg above pre-test individual resting SBP<sub>9</sub>, compresses the brachial artery and induces forearm ischaemia distal to the occlusion [64].

To quantify the FMSF response, we used the following parameters:

- B<sub>mean</sub> [kFU] — mean baseline 460-nm fluorescence during rest;
- F<sub>Imax</sub> [kFU] — the maximal 460-nm fluorescence during ischaemia;
- F<sub>Rmin</sub> [kFU] — the minimal 460-nm fluorescence during reperfusion;
- I<sub>max</sub> [kFU] — the difference between F<sub>Imax</sub> and B<sub>mean</sub>;



- $R_{min}$  [kFU] — the difference between  $B_{mean}$  and  $FR_{min}$ ;
- $IR_{amp}$  [kFU] — the range of the 460-nm fluorescence change during ischaemia and reperfusion;
- $Cl_{max}$  — the rate of  $I_{max}$  to  $IR_{amp}$  showing the relative contribution of the NADH increase during ischaemia to the maximal change in NADH during ischaemia and reperfusion [65]. A diagram showing the above parameters is shown in the Figure 2.

Pawlak-Chomicka et al. examined HT patients before and after implementation of a therapy with a selected medication: amlodipine, perindopril, metoprolol or nebivolol. The treatment using amlodipine, perindopril and nebivolol did not influence the parameters describing FMSF curve pattern, but there was a significant change in case of metoprolol. During ischemia and reperfusion, there was observed the raised this fluorescence at rest, which indicated an increase in the total NADH skin content [66]. The method requires experienced personnel and appropriate equipment.

## Conclusion

Early detection of pathology in the microcirculatory area is crucial for HT patients [7]. The sooner pathology is detected, the earlier appropriate non- or pharmacological treatment can be introduced and the greater the chance of inhibiting or reversing the pathologic changes [1, 2]. Appropriate management, especially at an early stage, makes it possible to reduce cardiovascular risk, thereby reducing hospitalizations for cardiovascular incidents, which results in a reduction in the cost of care for this large group of patients, but also has an impact on improving their quality of life, mobility and independence [1, 2].

Each of the methods described in the review has its advantages and disadvantages. Doppler methods of microcirculation assessment (LDF, LDI, LSCI) are non-invasive, and the results are relatively easy to interpret, but each method has its limitations. Additionally, they all require provocation tests. VOP has a relatively complicated testing protocol. NIRS, OPS, OCT, FMSF, and thermography require special equipment. Capillaroscopy would seem to be a simple and repeatable method, but there are significant difficulties in interpreting the image of the vessels of the nail fold due to individual diversity.  $TcpO_2$  is a simple but time-consuming method. Photoplethysmography appears to be promising. The method is non-invasive, cheap, does not require experience and might be synchronises with mobile devices

[39]. It is possible that the simplification of the device calibration process and the development of a method allowing for the correct interpretation of the result, regardless of e.g., the patient's skin colour, could influence its wider use in the group of HT patients.

#### *Declarations*

The whole or part of the work was not previously presented in the article.

#### ***Conflict of interest***

None declared.

All authors certify that they have no affiliations with or involvement in any organization or entity with any financial interest or non-financial interest in the subject matter or materials discussed in this manuscript.

#### ***Funding***

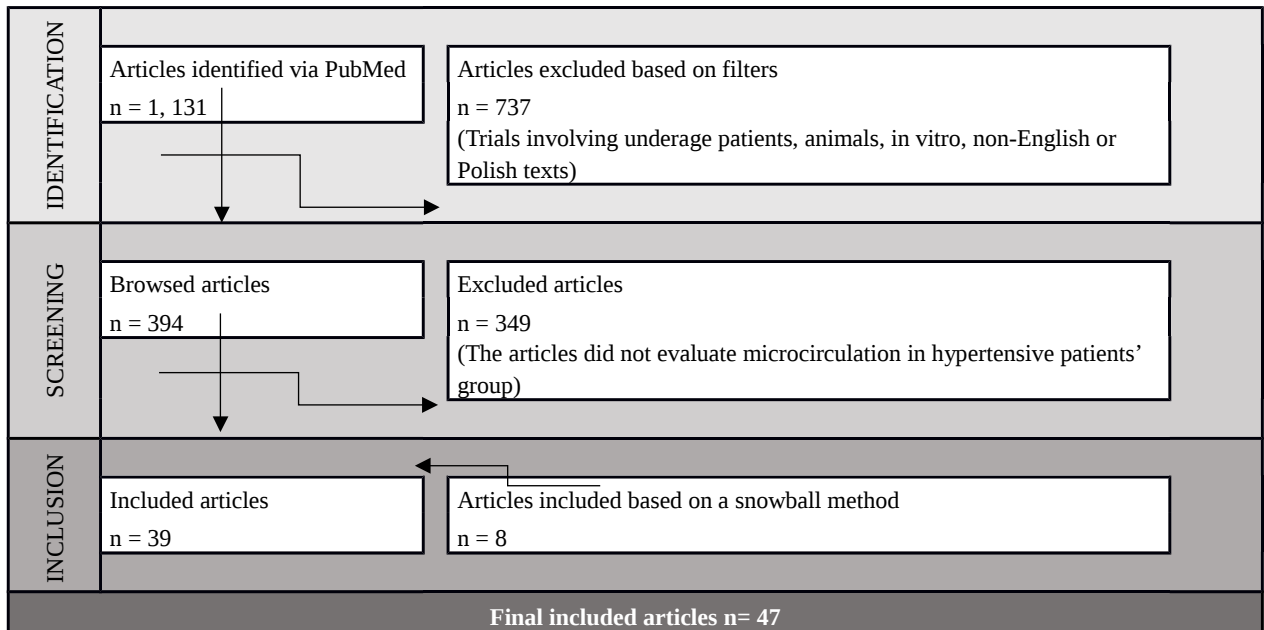
The authors did not receive support from any organization for the submitted work.

#### ***Author contributions***

All authors contributed to the study conception and design. Material preparation, data collection and analysis were performed by all authors. The first draft of the manuscript was written by Katarzyna Lewandowska, and all authors commented on previous versions of the manuscript. All authors read and approved the final manuscript.

#### ***Acknowledgments***

None.



**Figure 1.** Flow diagram of study selection.

**Figure 2.** An example of the 460 nm skin fluorescence recorded at rest, during 100-second transient ischemia and the following reperfusion in healthy patient. Based on: [66]

