

This is a provisional PDF only. Copyedited and fully formatted version will be made available soon.



ISSN: 0015-5659

e-ISSN: 1644-3284

Rare high branching pattern from the first part of the right axillary artery

Authors: Ahmad O. Odeh, Shivika O. Ahuja, Sania V. Karir, Felicia D. Lee, Young T. Lee, Zoe I. Henkes, Larry F. Yang, Dane A. Meyer, Daniel T. Daly, Yun Tan

DOI: 10.5603/FM.a2023.0003

Article type: Case report

Submitted: 2022-08-09

Accepted: 2022-10-21

Published online: 2023-01-17

This article has been peer reviewed and published immediately upon acceptance. It is an open access article, which means that it can be downloaded, printed, and distributed freely, provided the work is properly cited.

Articles in "Folia Morphologica" are listed in PubMed.

Rare high branching pattern from the first part of the right axillary artery

Ahmad O. Odeh et al., Rare high branching pattern from the first part of the right axillary artery

Ahmad O. Odeh¹, Shivika O. Ahuja¹, Sania V. Karir¹, Felicia D. Lee¹, Young T. Lee¹, Zoe I. Henkes¹, Larry F. Yang¹, Dane A. Meyer¹, Daniel T. Daly^{1,2,3}, Yun Tan^{1,2,3}

¹Saint Louis University School of Medicine, Saint Louis, MO, United States

²Center for Anatomical Science and Education, Saint Louis University School of Medicine, Saint Louis, MO, United States

³Department of Surgery, Saint Louis University School of Medicine, Saint Louis, MO, United States

Address for correspondence: Daniel T. Daly, Center for Anatomical Science and Education, Department of Surgery, Saint Louis University School of Medicine, Saint Louis, MO 63104, USA, tel: 314-977-8027, fax: 314-977-5127, e-mail: daniel.daly@health.slu.edu

ABSTRACT

A 77-year-old female cadaver was observed to have a rare branching pattern of the right axillary artery (AA). The first part of the AA typically gives off only a superior thoracic artery (STA) but was observed to give off three branches in the case: a lateral thoracic artery (LTA), a thoracoacromial trunk (TAT), and a large common trunk (CT). The LTA traveled to provide a variant STA to the 1st and 2nd intercostal spaces. The CT provided an accessory lateral thoracic artery (aLTA) and accessory thoracodorsal artery (aTDA) before bifurcating into a subscapular artery (SA) and posterior humeral circumflex artery (PHCA). As expected, the SA further divided into the circumflex scapular artery (CSA) and thoracodorsal artery (TDA). A pectoral artery and the anterior humeral circumflex artery (AHCA) originated directly from the second and third parts of the AA, respectively. Knowledge of AA branching variations is of great

clinical significance to anatomists, radiologists, and surgeons due to the high rate of injury to this artery.

Key words: artery, upper limb vasculature, axillary artery, variation

INTRODUCTION

The subclavian artery continues lateral to the first rib as the AA where it is divided into three distinct parts as it relates to the pectoralis minor muscle. The first part of the AA is proximal to the pectoralis minor and typically gives off only one branch, the STA. As the AA travels in its second part, posterior to the pectoralis minor, it normally provides two branches: the TAT and the LTA. Finally, distal to the pectoralis minor muscle, the third part of the AA typically gives three branches: the AHCA, PHCA, and SA. The SA then typically quickly bifurcates into the CSA and the TDA. As the AA passes the inferior border of teres major its name changes to brachial artery which continues in the arm.

While the muscles of the shoulder girdle can receive collateral circulation from numerous sources, the study of arterial branching remains important because these major arteries maintain close anatomical relationships with the brachial plexus. The cords of the brachial plexus are named based on their relationship to the second part of the AA; their close proximity suggests that arterial variation in this region can pose a risk for neuropathy as seen by previous anatomical and clinical case studies [1, 2]. An understanding of possible anatomical variations can help guide surgical and therapeutic procedures.

While AA variations are not uncommon, the current case discusses a rare variation in which the first part of the right AA provides a novel CT. This aberrant CT gave origin to the following branches: an aLTA, an aTDA, the SA and the PHCA (**Table 1**). The aim of this case study is to provide a detailed case presentation of this unique branching pattern of the AA while outlining possible clinical implications of this variant.

Useful abbreviations: axillary artery (AA), anterior humeral circumflex artery (AHCA), accessory thoracodorsal artery (aTDA), circumflex scapular artery (CSA), lateral thoracic artery (LTA), posterior humeral circumflex artery (PHCA), superior thoracic artery (STA), thoracoacromial trunk (TAT), thoracodorsal artery (TDA)

CASE REPORT

The body of a 77-year-old female was received by the Saint Louis University Gift Body Program of the Center for Anatomical Science and Education (CASE) with the informed consent of the donor. The death certificate listed hepatic carcinoma as the cause of death. No other pathologies were noted.

Dissection of the right axilla was completed according to instructions outlined in Grant's dissector, 16th Edition [3]. After the right axillary vein was cleaned and studied, it was removed to better study the AA branching pattern. One unique variation observed in the right AA included the absence of a traditional STA originating from the first part of the AA. Instead, from proximal to distal, the first part of the AA gave three branches: the LTA, the TAT, and a large CT. After providing these three branches, the AA continued distally, deep to the pectoralis minor and surrounded by the lateral, posterior, and medial cords of the brachial plexus. Proximally, the LTA provided the STA to the first and second intercostal spaces before continuing with the long thoracic nerve to supply the serratus anterior muscle (**Figure 1**).

The large CT branched into an aLTA to the serratus anterior muscle and a large aTDA to the latissimus dorsi muscle. These named branches were identified based on the muscles they supply but are described as accessories because they originate from an atypical source. The CT then bifurcated into the PHCA and the SA. The PHCA traveled with the axillary nerve, while the SA bifurcated into a CSA and a small TDA (**Figure 2**).

The second part of the AA provided one pectoral artery to the pectoralis minor. The third part of the AA supplied the AHCA artery before continuing as the brachial artery (**Figure 3**). Normally, the AA is closely approximated by the three cords of the brachial plexus. However, in this unique case, the AA and CT surrounded the medial cord and the medial antebrachial cutaneous nerve (**Figure 3**). The branching pattern of this variant AA is summarized in a sketch depicting the branches from each part of the AA (**Figure 4**). The left axillary artery and upper extremity venous drainage were anatomically typical.

DISCUSSION

Previously Documented AA Variations

A wide variety of AA variations have been documented in the literature, including the presence of common arterial trunks which give rise to branches that normally originate directly from the AA [4, 5]. In addition to the typical origin of the SA and PHCA from the third part of the AA, these two vessels have been observed arising from a CT from either the first or second part of the AA [6]. The current case adds another distinct finding to this description with the higher origin of a CT from the first part of the AA.

A study of 166 axillae described the branching pattern of the LTA, SA, and PHCA finding that the LTA gave rise to both the TDA and the SA in about 10% of the cases while the PHCA was observed to variably originate from either the SA or the deep brachial artery in about 20% of the cases [7]. The current case adds to the description of the possible origins of the SA and PHCA as arising from a CT from the first part of the AA. Another case study describes two branches, the TAT and SA, arising from the first part of the AA, with the SA providing the LTA before terminating as the TDA and PHCA [8]. However, the current case has three branches originating from the first part of the AA. The CT in our report provided both an aLTA and an aTDA before bifurcating into the SA and PHCA artery.

Furthermore, the current case includes an LTA that quickly provides the STA, a branching pattern which is rarely seen. The current literature regarding reported anomalous STA origins and trajectories includes one case study in which the STA originates from the first part of the AA but travels between components of the brachial plexus to reach the lateral thoracic wall [9]. A second case report includes two cadaveric dissections where the LTA originated cephalad to the STA along the first part of the AA [10].

The presence of a large CT from the first part of the AA that supplies an aLTA and an aTDA, before bifurcating into the PHCA and SA, has not been reported in the literature. Table 1 outlines descriptions of documented AA branching patterns as they compare to the current case.

Clinical Significance

It has been reported that the AA has the highest rate of arterial injury after the popliteal artery, so it is of great clinical significance for radiologists and surgeons to be aware of its possible variations [1, 7, 9, 11-17]. Carotid-axillary bypass is an alternative to carotid-

subclavian bypass due to the significant lymphatic risks that can occur in the latter procedure, but variations in the AA branching pattern can introduce new risks [18]. Furthermore, the current case reveals the PHCA artery originating from a CT rather than from the most distal portion of the AA. Both the AHCA and PHCA (as well as the deep brachial artery) are significant when repairing rotator cuff and proximal humeral injuries as the arteries anastomose around the surgical neck of the humerus [19-21].

Brachial plexus injuries account for 35% of surgical complications in the axillary region and have the most significant long-term morbidity and mortality [22]. In the present case, the medial cord of the brachial plexus and the medial antebrachial cutaneous nerve traveled between the AA and the CT. This atypical relationship of the medial cord with an arterial variation may complicate peripheral nerve blocks or, in general, increase the risk of nerve damage during any procedure within the axilla [23].

The right axillary vein was not anatomically unique in this case, but the course of the venous tributaries may be altered in such arterial variation and can complicate procedures like central venous line placements, arteriovenous fistulas, or impede venous flow and cause swelling [24]. Aside from venous procedures, AA variations such as the one presented in this case may also complicate axillary lymph node dissection, breast augmentation, reconstructive surgery and tumor resections [24].

CONCLUSIONS

While AA variations are common, it is unreported in the literature to see a CT originating from the first segment of the AA. This CT is unique as it provided accessory arteries to the serratus anterior and latissimus dorsi muscles before terminating as the PHCA and SA. The first part of the AA also atypically provided the LTA and TAT. Knowledge of unique arterial variations can impact a wide range of procedures performed by radiologists as well as orthopedic, vascular, oncology, and plastic surgeons.

Acknowledgments

The authors are very grateful for the donations of these bodies that contribute to the advancement of science and medical education. This study was supported by the Center for Anatomical Science and Education, Saint Louis University School of Medicine.

Conflict of interest: None declared

REFERENCES

1. Venieratos, D. and E.D. Lolis, [*Abnormal ramification of the axillary artery: subscapular common trunk*]. *Morphologie*, 2001. 85(270): p. 23-4.
2. Ortiz-Pomales, Y., et al., *Tortuous axillary artery aneurysm causing median nerve compression*. *Ann Vasc Surg*, 2014. 28(1): p. 122 e1-3.
3. Detton, A.J. and P.W. Tank, *Grant's dissector*. 2017.
4. Bozlar, U., et al., *CT angiography of the upper extremity arterial system: Part 1- Anatomy, technique, and use in trauma patients*. *AJR Am J Roentgenol*, 2013. 201(4): p. 745-52.
5. Berezovsky, D.R. and B. Bordoni, *Anatomy, Shoulder and Upper Limb, Forearm Arteries*, in *StatPearls*. 2021, StatPearls Publishing Copyright © 2021, StatPearls Publishing LLC.: Treasure Island (FL).
6. Hattori, Y., et al., *Anatomic variations in branching patterns of the axillary artery: a multidetector-row computed tomography angiography study*. *J Reconstr Microsurg*, 2013. 29(8): p. 531-6.
7. Olinger, A. and B. Benninger, *Branching patterns of the lateral thoracic, subscapular, and posterior circumflex humeral arteries and their relationship to the posterior cord of the brachial plexus*. *Clin Anat*, 2010. 23(4): p. 407-12.
8. Lee, J.H. and D.K. Kim, *Bilateral variations in the origin and branches of the subscapular artery*. *Clin Anat*, 2008. 21(8): p. 783-5.
9. Aastha, A. Jain, and M.S. Kumar, *An unusual variation of axillary artery: a case report*. *J Clin Diagn Res*, 2015. 9(1): p. AD05-7.
10. Yuksel, M. and E. Yuksel, *Anomalous branching order of the superior and lateral thoracic arteries*. *Clin Anat*, 1997. 10(6): p. 394-6.

11. Khaki, A.A., M.A. Shoja, and A. Khaki, *A rare case report of subscapular artery*. Ital J Anat Embryol, 2011. 116(1): p. 56-9.
12. Singh, R., *Abnormal origin of posterior circumflex humeral artery and subscapular artery: case report and review of the literature*. J Vasc Bras, 2017. 16(3): p. 248-251.
13. Bagoji, I.B., et al., *A unique branching pattern of the axillary artery: a case report*. J Clin Diagn Res, 2013. 7(12): p. 2939-40.
14. Swamy, R., et al., *Unusual branching pattern of axillary artery associated with the high origin of ulnar artery*. Ann Med Health Sci Res, 2013. 3(2): p. 265-7.
15. Shantakumar, S.R. and K.G. Mohandas Rao, *Variant branching pattern of axillary artery: a case report*. Case Rep Vasc Med, 2012. 2012: p. 976968.
16. Yang, H.J., et al., *Variations of the superficial brachial artery in Korean cadavers*. J Korean Med Sci, 2008. 23(5): p. 884-7.
17. Patnaik, V.V.G.K., G., *Singla Rajan, K., *Branching Pattern of Brachial Artery-A Morphological Study*. J Anat. Soc. India, 2002. 51(2): p. 176-186.
18. Barakat, T.I., et al., *Carotid axillary bypass in a patient with blocked subclavian stents: a case report*. J Med Case Rep, 2011. 5: p. 237.
19. Tang, A. and M. Varacallo, *Anatomy, Head and Neck, Posterior Humeral Circumflex Artery*, in *StatPearls*. 2021, StatPearls Publishing Copyright © 2021, StatPearls Publishing LLC.: Treasure Island (FL).
20. Gilbert, G.M. and R. Nelson, *Anatomy, Shoulder and Upper Limb, Anterior Humeral Circumflex Artery*, in *StatPearls*. 2021, StatPearls Publishing Copyright © 2021, StatPearls Publishing LLC.: Treasure Island (FL).
21. Gorthi, V., et al., *Life-threatening posterior circumflex humeral artery injury secondary to fracture-dislocation of the proximal humerus*. Orthopedics, 2010. 33(3).
22. Graham, J.M., et al., *Vascular injuries of the axilla*. Ann Surg, 1982. 195(2): p. 232-8.
23. Janjua, M.S. and A. Pak, *Axillary Block*, in *StatPearls*. 2022: Treasure Island (FL).
24. Yang, H.J., et al., *Novel findings of the anatomy and variations of the axillary vein and its tributaries*. Clin Anat, 2012. 25(7): p. 893-902.
25. Armstrong A, D.C., Vest L, et al., *A unique ipsilateral axillary artery variation*. Int J Anat Var, 2021. 14(1): p. 47-50.




Figure 1. Arterial branching from the first part of the AA. The pectoralis minor muscle has been detached from its origin along the anterior aspect of the upper ribs and the arm has been abducted and extended to best show the three branches originating from the first part of the AA. The LTA branches first, followed by the TAT and CT. Both the CT and the AA continue deep to the pectoralis minor.

Abbreviations: AA (axillary artery), CT (common trunk), LTA (lateral thoracic artery), TAT (thoracoacromial trunk).

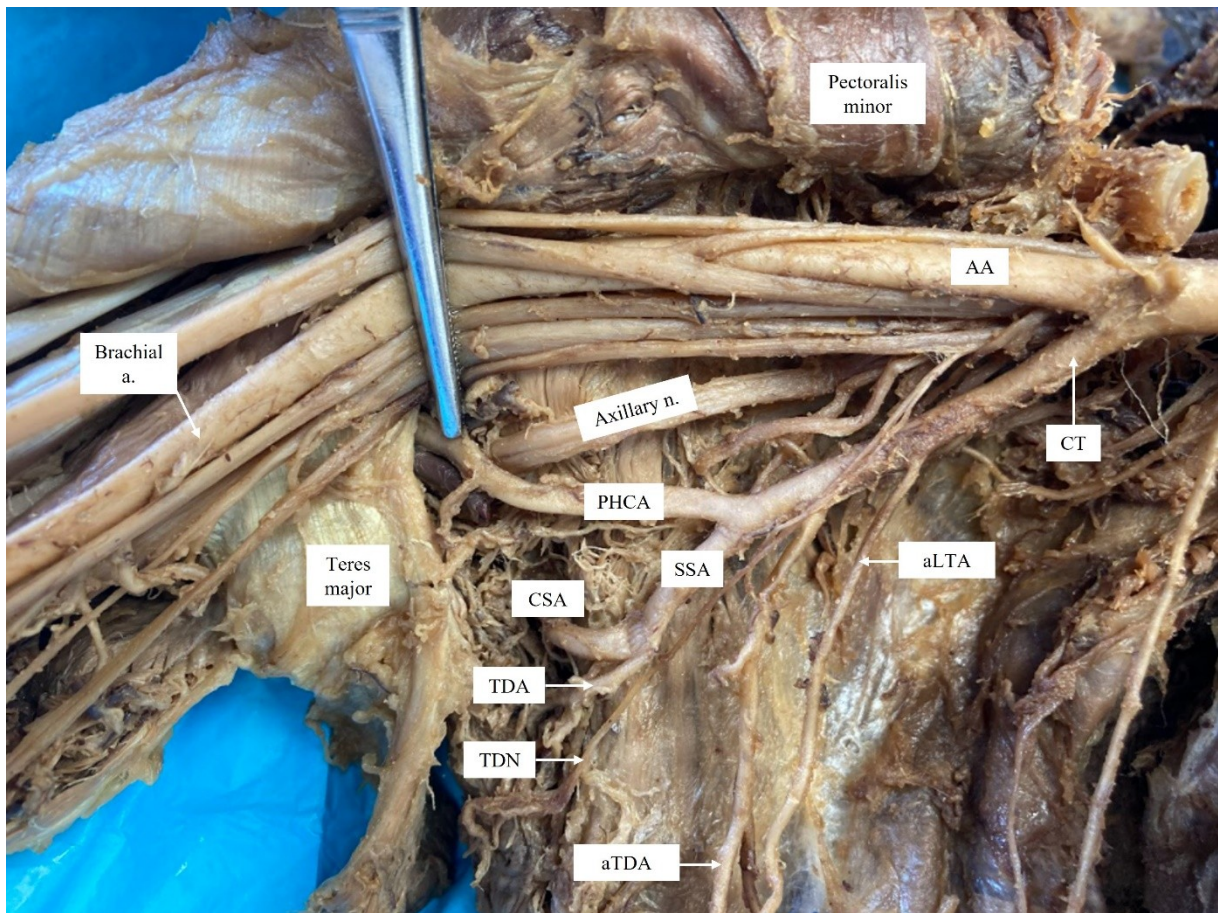


Figure 2. Common trunk from the first part of the AA. The CT provides the aLTA and aTDA before terminating as the SA (which bifurcates into the CSA and TDA) and the PHCA artery. The TDA travels with the TDN and the PHCA travels with the axillary nerve. The AA was observed continuing as the brachial artery distal to the teres major muscle. Abbreviations: AA (axillary artery), aLTA (accessory lateral thoracic artery), aTDA (accessory thoracodorsal artery), CSA (circumflex scapular artery), CT (common trunk), PHCA (posterior humeral circumflex artery), SSA (subscapular artery), TDA (thoracodorsal artery), TDN (thoracodorsal nerve).

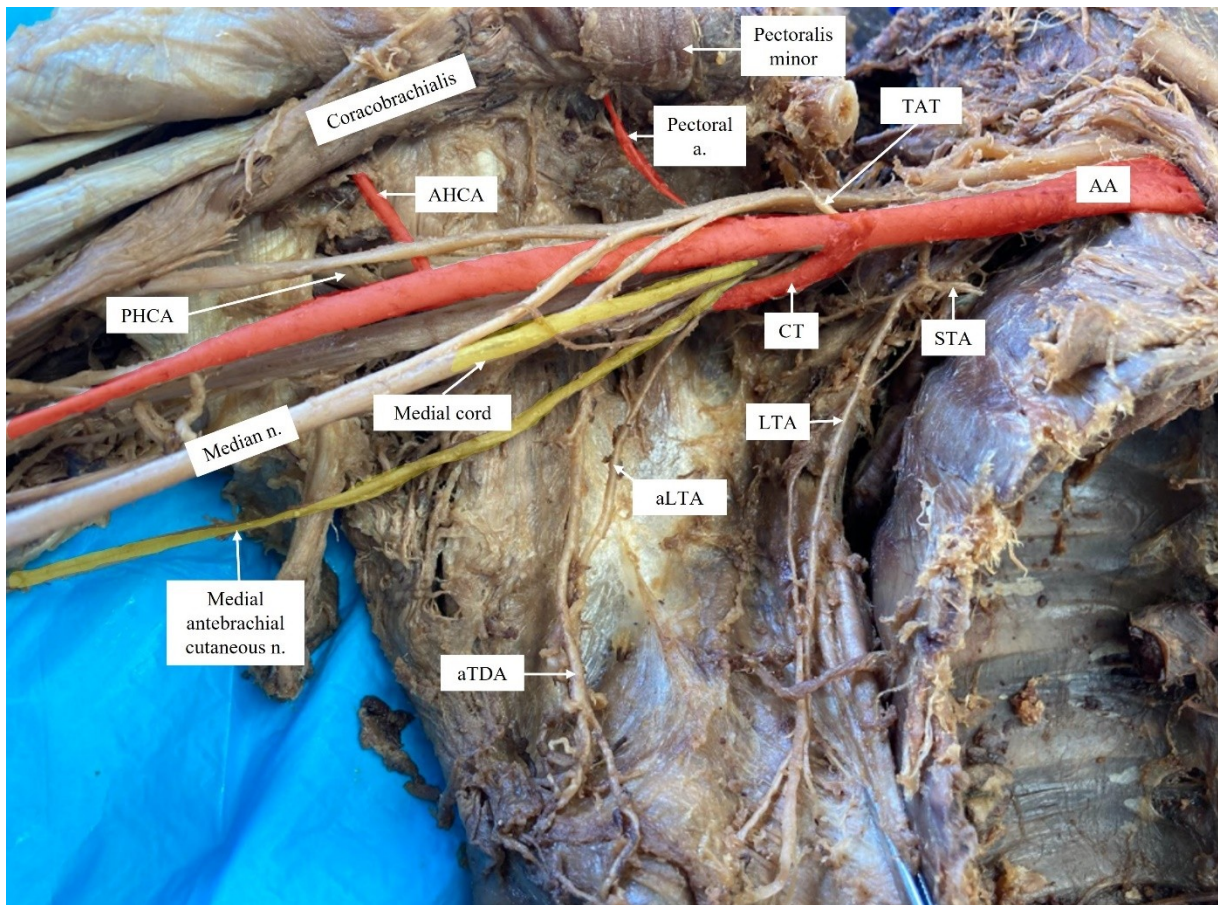


Figure 3. Unique neurovascular relationship between brachial plexus and AA. The pectoral artery and AHCA can be observed branching from the second and third parts of the AA, respectively. Arterial structures have been shaded in red to emphasize the unique anatomical relationship of the AA and the CT with two neural structures, the medial cord and the medial antebrachial cutaneous nerve, that are shaded yellow. The two branches from the second and third parts of the AA are also in red. This image also allows one to appreciate the LTA supplying the STA.

Abbreviations: AA (axillary artery), CT (common trunk), STA (superior thoracic artery), LTA (lateral thoracic artery), aLTA (accessory lateral thoracic artery), AHCA (anterior humeral circumflex artery), PHCA (posterior humeral circumflex artery), aTDA (accessory thoracodorsal artery).

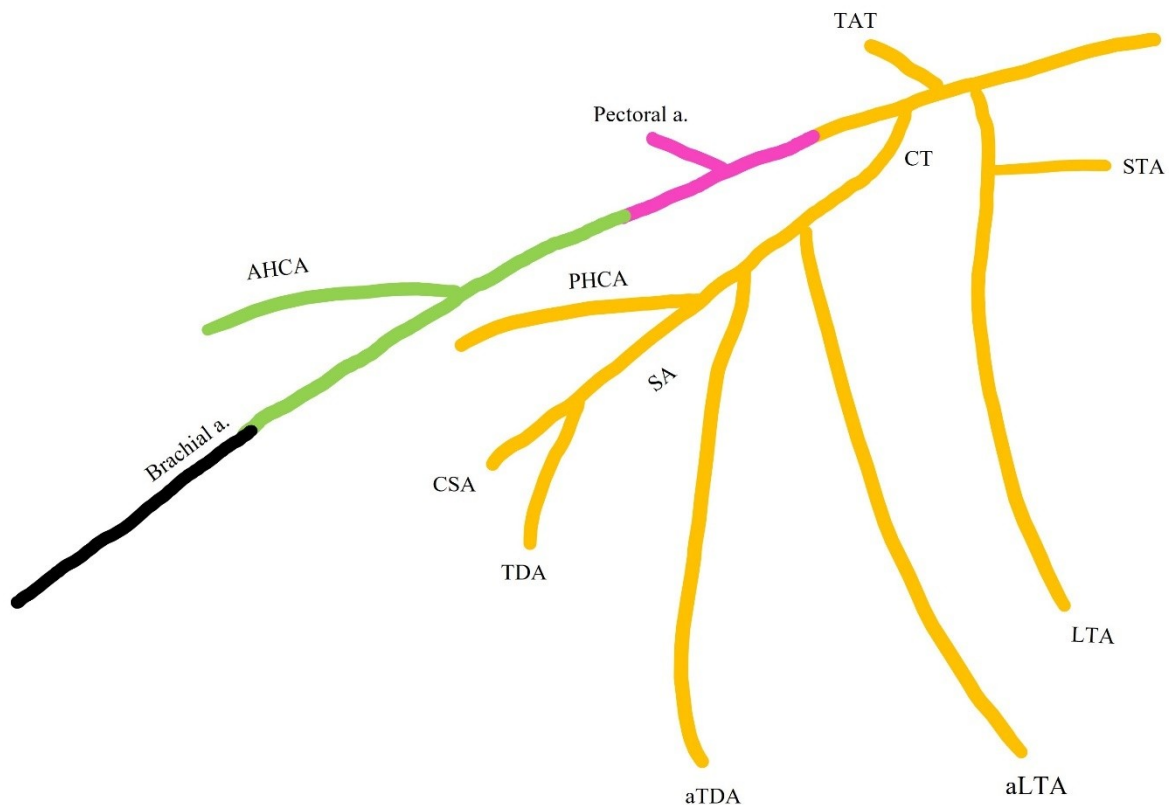


Figure 4. Representation of the AA branching variation in the current case. This sketch (not drawn to scale) summarizes the AA branching in the current case. The branches are colored based on the part of the AA from which they originate (orange – first part, pink – second part, green – third part). Notice that the LTA, the TAT, and the CT all have a high origin from the AA. The CT continues distally and provides two accessory branches before bifurcating as the PHCA and SA. The AA second part continues posterior to the pectoralis minor and gives an isolated pectoral artery before providing its final branch, the AHCA, from the third part of the AA. The AA then continues as the brachial artery (black). Abbreviations: AA (axillary artery), AHCA (anterior humeral circumflex artery), aLTA (accessory lateral thoracic artery), aTDA (accessory thoracodorsal artery), CSA (circumflex scapular artery), CT (common trunk), LTA (lateral thoracic artery), PHCA (posterior humeral circumflex artery), SA (subscapular artery), STA (superior thoracic artery), TDA (thoracodorsal artery).

AA Parts	Typical Branching Pattern	Current Variation Branching Pattern	Reported Variants Branching Patterns
First	STA	LTA TAT CT: aLTA, aTDA, PHCA, and SA.	TAT and SA (described in the Discussion) [8].
Second	TAT	Pectoral artery	SA gave the LTA and PHCA [14].
	LTA		CT for the SA and LTA [15].
Third	SA: CSA and TDA PHCA AHCA	AHCA	Common subscapular trunk was the origin for the SA, AHCA and PHCA [1].
			CT bifurcated into the PHCA and SA [12].
			A common subscapular trunk provided the CSA, TDA, PHCA, LTA and TAT [13].
			A CT divided into the deep brachial artery, AHCA, PHCA, and SA [9].
			A CT divided into the SA and a common stem for the AHCA, PHCA and the deep brachial artery [25].

Table 1. Summary of AA variations that differ from the current case, with brief descriptions of the AA variations identified in other individual case studies. This table compares other AA variations similar to the current case while highlighting differences based on reports in the literature. For comparison, note also the branches that typically arise from each part of the AA.

Abbreviations: AA (axillary artery), AHCA (anterior humeral circumflex artery), aLTA (accessory lateral thoracic artery), aTDA (accessory thoracodorsal artery), CSA (circumflex scapular artery), CT (common trunk), LTA (lateral thoracic artery), PHCA (posterior humeral circumflex artery), SA (subscapular artery), STA (superior thoracic artery), TDA (thoracodorsal artery).