

Surgical-orthodontic Treatment of Skeletal Class III Malocclusion and Concomitant Open Bite: A Case Report

DANIELA GOMES DE REZENDE AZEVEDO¹, SERGIO LUIZ MOTA-JÚNIOR², TARIZA GALLICCHIO MOREIRA³, THIAGO GALLICCHIO MOREIRA⁴, MARCO ABDO GRAVINA⁵



ABSTRACT

Surgical-orthodontic treatment for the correction of skeletal Class III malocclusion and concomitant open bite is challenging due to the probability of postsurgical relapse. The present case (19 year-old male) describes successful surgical-orthodontic treatment for the correction of Class III malocclusion with anterior and posterior open bite. Treatment consisted of the use of an Edgewise fixed appliance (0.022" × 0.028") and bimaxillary orthognathic surgery. Treatment resulted in bilateral Class I molar and canine relationships, normal overjet and overbite, the correction of anterior and posterior open bite, alignment of the midlines, leveling of the curve of Spee, satisfactory facial harmony, and passive lip seal. The correct diagnosis as well as the proper indication and execution of orthodontic and surgical treatments enabled the achievement of satisfactory functional and facial results and smile esthetics.

Keywords: Angle class III malocclusion, Corrective, Edgewise fixed appliance

CASE REPORT

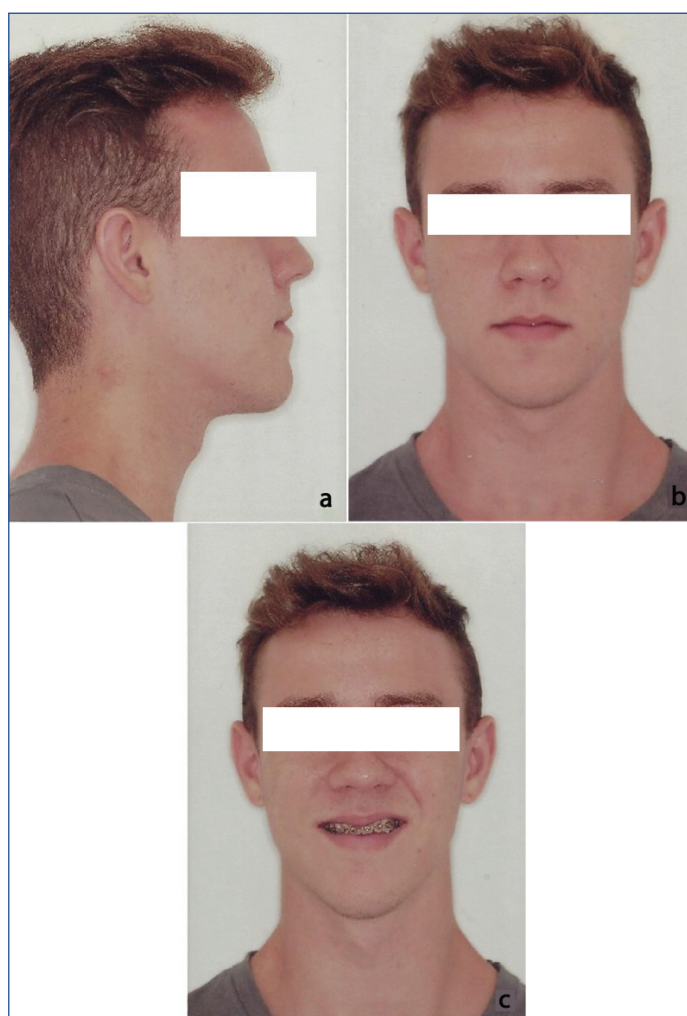
A 19-year-old male patient sought an orthodontic assessment because he had been in orthodontic treatment with another professional for 4.5 years and was discontent with the results. The patient's main complaints were the inability to chew properly and aesthetic dissatisfaction.

Extraoral examination revealed a concave profile associated with anteroposterior deficiency of maxilla, long face with the lower third increased, and little exposure of the maxillary incisors at rest and when smiling [Table/Fig-1]. Intraorally, the patient presented a Class III molar relationship bilaterally, overbite of -2.5 mm, overjet of -1 mm, anterior and posterior open bite with contact only between the first maxillary molars and second mandibular molars, maxillary midline deviated 1 mm to the right, accentuated curve of Spee, all permanent teeth erupted but with an important space deficiency for the correct positioning of teeth 35 and 45, and moderate gingival recession on tooth 23. An orthodontic appliance was bonded to both arches (from tooth 15 to 26 in the upper arch with a continuous archwire and from tooth 36 to 46 in the lower arch and a continuous archwire positioned from tooth 34 to 36). Teeth 16, 17, 27, 35, 45, 37, and 47 were not included in the assembly of the appliance [Table/Fig-2].

The panoramic radiograph revealed a lack of root parallelism in both arches, an evident lack of space for the proper positioning of the mandibular second premolars, and all maxillary and mandibular third molars erupted [Table/Fig-3]. The cephalometric analysis revealed skeletal Class III malocclusion (ANB: -2° and Wits: -5.7 mm) with maxillary (SNA: 74.6°) and mandibular (SNB: 76.6°) retrusion as well as a dolichofacial pattern (SN.GoGn: 46.8°; FMA: 39.6°). The maxillary incisors were protruded and projected (1-NA: 7.8 mm; 1.NA: 25.3°), whereas the mandibular incisors were slightly protruded and retroclined (1-NB: 4.5 mm; 1.NB: 21.6°), with an interincisal angle of 135.2°. The upper and lower lips were retracted (UL-S: -5 mm; LL-S: -2 mm) [Table/Fig-4].

Treatment Objectives

The treatment objectives were to achieve satisfactory functional occlusion, aesthetic smile, and face balance.

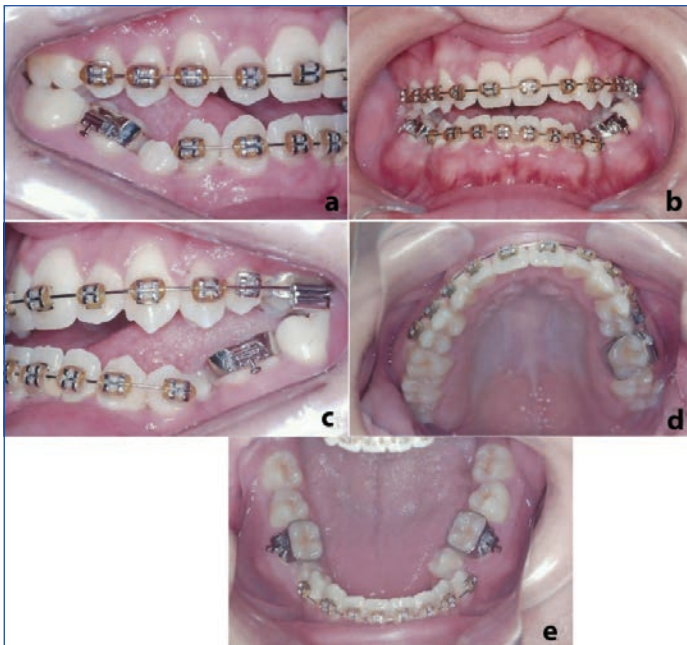


[Table/Fig-1]: Pretreatment extraoral photographs. a: Lateral, b: Frontal, c: Smile.

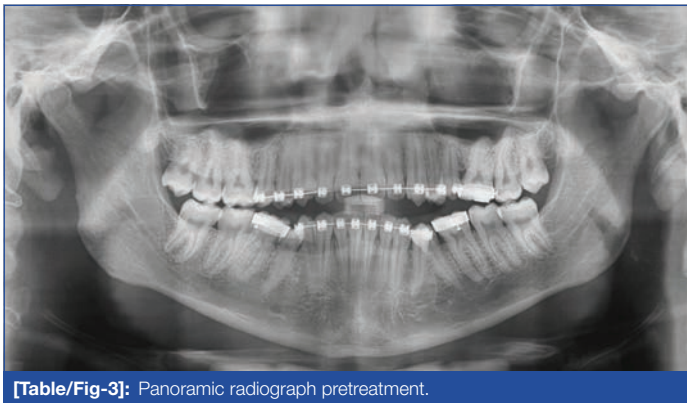Treatment Alternatives

Alternative 1: orthognathic surgery with traditional presurgical orthodontic preparation and postsurgical finalization

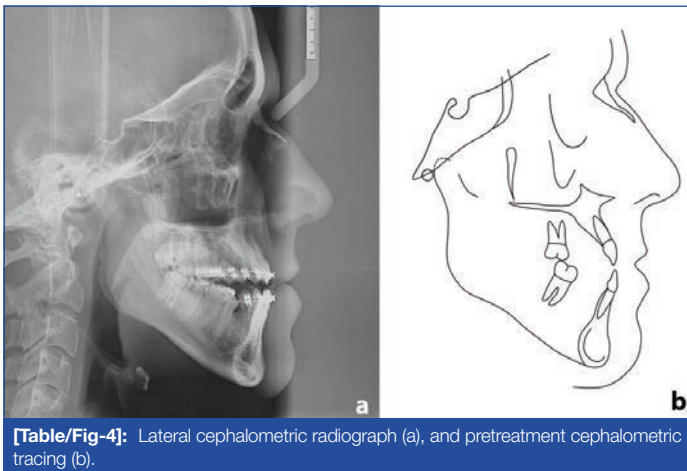
Alternative 2: orthognathic surgery with anticipated benefit ("surgery first")



[Table/Fig-2]: Pretreatment intraoral photographs. a: Right-side, b: Frontal, c: Left-side, d: Upper occlusal, e: Lower occlusal.



[Table/Fig-3]: Panoramic radiograph pretreatment.



[Table/Fig-4]: Lateral cephalometric radiograph (a), and pretreatment cephalometric tracing (b).

Alternative 3: no intervention

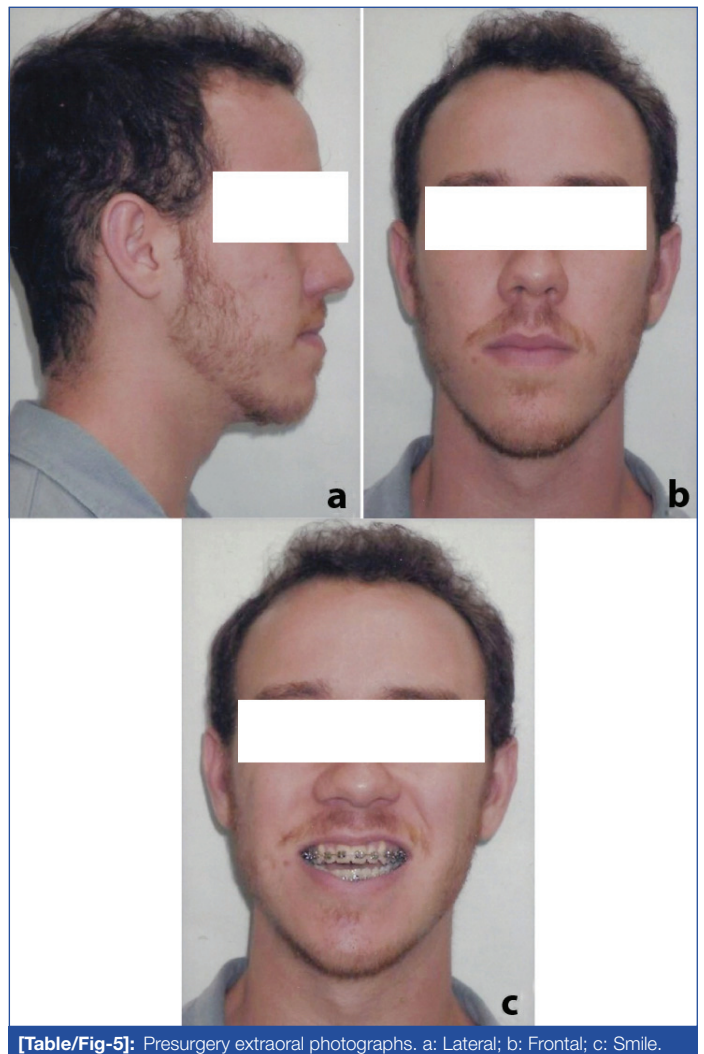
The first alternative was selected because of the expertise of the orthodontist and the surgeon. This treatment plan with fixed appliance could resolve the patient's malocclusion and wishes.

Treatment Process

New Edgewise Standard orthodontic brackets (Abzil Edgewise Standard 0.022"x0.028", Sumaré, São Paulo, Brazil) were used including all teeth. In this phase, extractions of the maxillary and mandibular third molars were performed, followed by the alignment and leveling phase with 0.012" and 0.014" Nickel Titanium (NiTi) archwire and coordinated upper and lower 0.016", 0.018", and 0.020" stainless-steel archwires.

The space opening for the positioning of teeth 35 and 45 was performed by verticalization and distalization of the mandibular first and second molars with boot loops and tip back bends using 0.016" to 0.020" stainless-steel wires, combined with decompensation and projection of the mandibular incisors. After the space opening, teeth 35 and 45 were included in the orthodontic archwires using mesial and distal boot loops. The deviation of the mandibular occlusal plane was corrected by the proper positioning of the orthodontic accessories. Leveling of the curve of Spee of the lower arch was achieved by intrusion of the antero-inferior segment, verticalization and intrusion of the second molars, verticalization of the first molars and extrusion of the premolars bilaterally. All movements were performed without the use of Temporary Anchorage Devices (TADs).

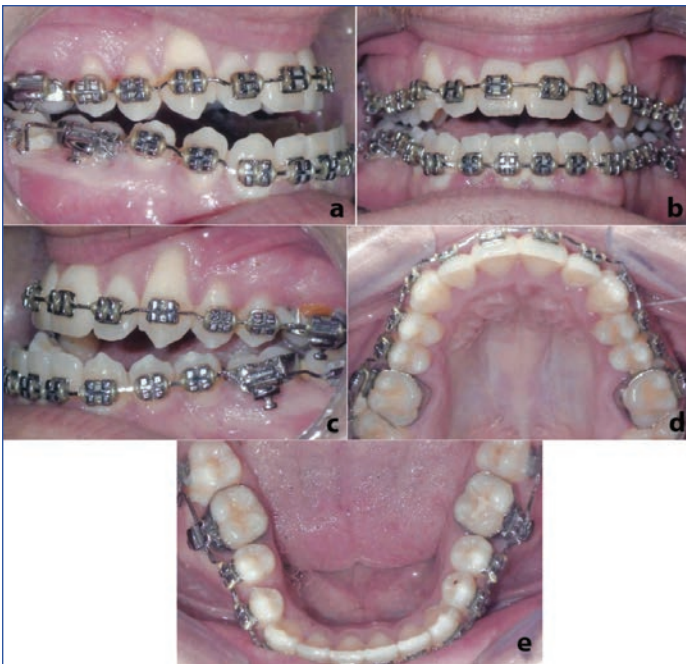Coordinated maxillary and mandibular presurgical 0.019" × 0.025" stainless-steel archwires were placed. In this step, presurgical molding was performed for the evaluation of the orthodontic preparation. This step lasted three years and two months and overjet of -3 mm was achieved [Table/Fig-5-7].



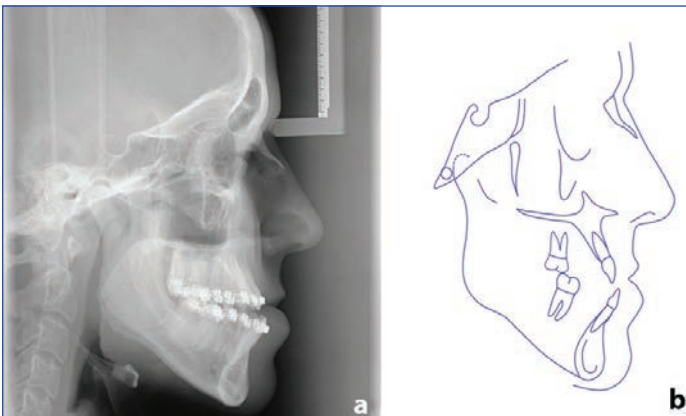
[Table/Fig-5]: Presurgery extraoral photographs. a: Lateral; b: Frontal; c: Smile.

With the occlusion prepared, the patient was advised for bimaxillary orthognathic surgery, with the advancement, posterior impaction and anterior lowering of the maxilla as well as the mild advancement and counterclockwise turn of the mandible and advancement of the chin [Table/Fig-8,9]. The postsurgical orthodontic phase of treatment lasted seven months, in which new stainless-steel 0.020" and 0.019" × 0.025" archwires were used until the achievement of ideal occlusion, functional, and aesthetic results.

After the removal of the fixed appliance, a wrap-around maxillary retainer was made with 0.9 mm wire, with the indication for use 24 hours per day for the first 12 months and night-time use from the 12th to 24th month. In the lower arch, retention was performed with



[Table/Fig-6]: Presurgery intraoral photographs. a: Right-side; b: Frontal; c: Left-side; d: Upper occlusal; e: Lower occlusal.



[Table/Fig-7]: Lateral cephalometric radiograph (a), and presurgery cephalometric tracing (b).

0.020" wire bonded canine to canine, as well as wires of the same caliber bonded vestibularly on teeth 36 to 34 and 46 to 44 to ensure the positioning of teeth 35 and 45.

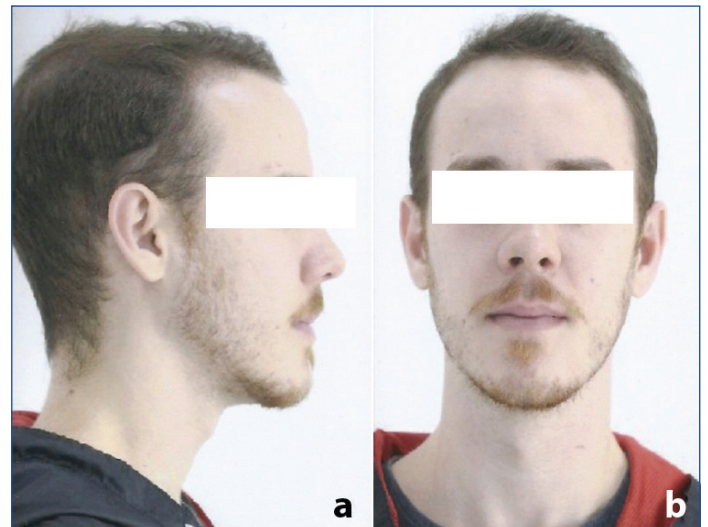
Treatment Results

Treatment resulted in bilateral Class I molar and canine relationships, 30% overbite and overjet of 2 mm, the correction of anterior and posterior open bite, alignment of the midlines, leveling of the curve of Spee, decompensation of the lower incisors, and the inclusion of teeth 35 and 45 in the dental arch. Despite all efforts to avoid its progression, an increase in gingival recession occurred on tooth 23.

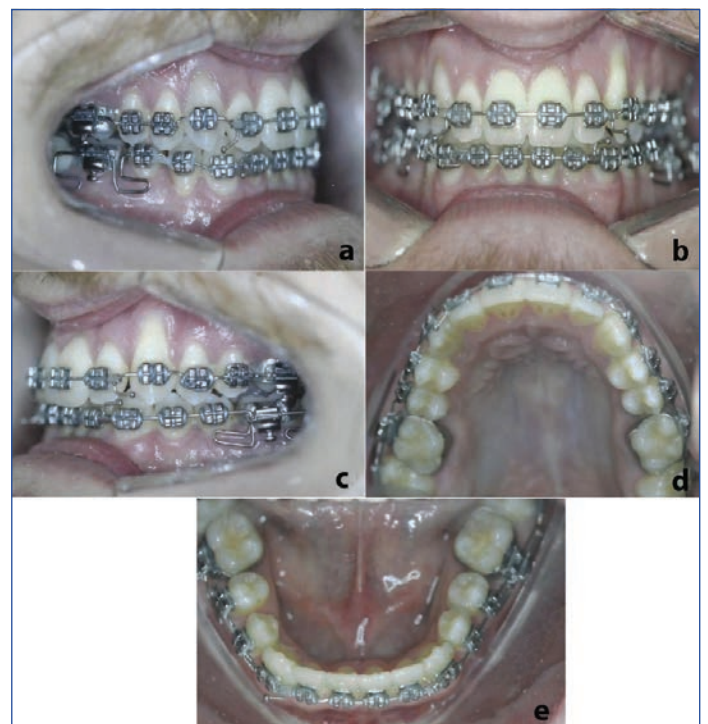
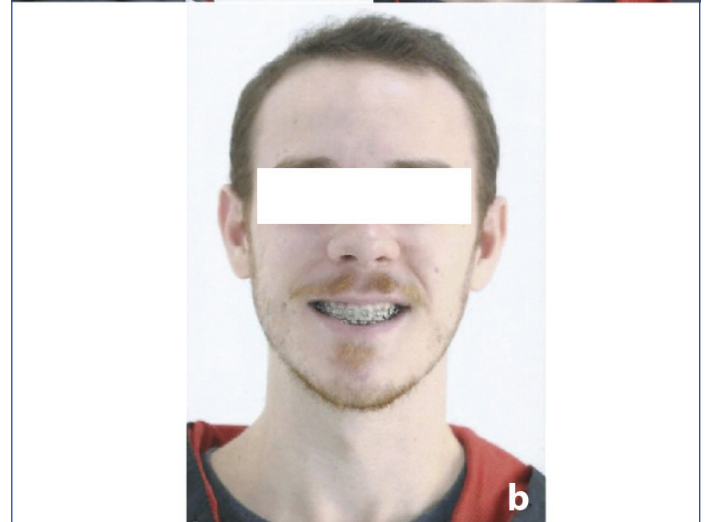Satisfactory facial harmony and passive lip seal were obtained [Table/Fig-10,11]. The lower third of the face was reduced. The final panoramic radiograph revealed satisfactory root parallelism and apical root rounding on some teeth, as expected at the end of orthodontic treatment [Table/Fig-12]. [Table/Fig-13] shows the cephalometric measurements from the beginning to the end of the treatment.

DISCUSSION

Class III malocclusion, which was first described by Angle E [1], is considered a clinical challenge for orthodontists even today [2], as anterior open bite [3-6]. The treatment of Class III malocclusion with concomitant anterior open bite by orthodontics alone may not achieve satisfactory functional and aesthetic results if the underlying causes of the deformity are not addressed [7,8]. Thus, the

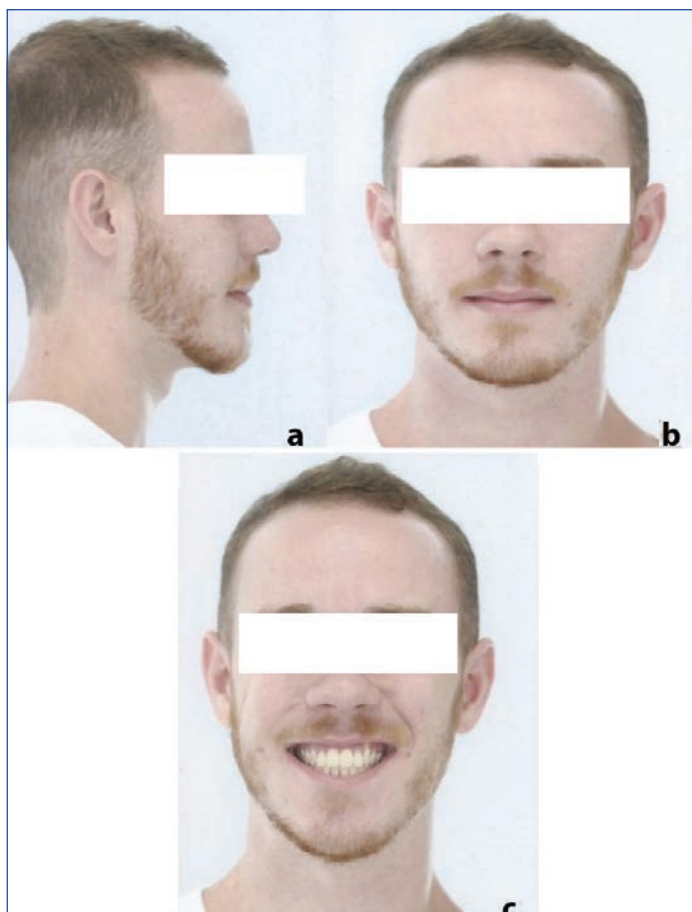

[Table/Fig-8]: Postsurgery extraoral photographs. a: Lateral; b: Frontal; c: Smile.

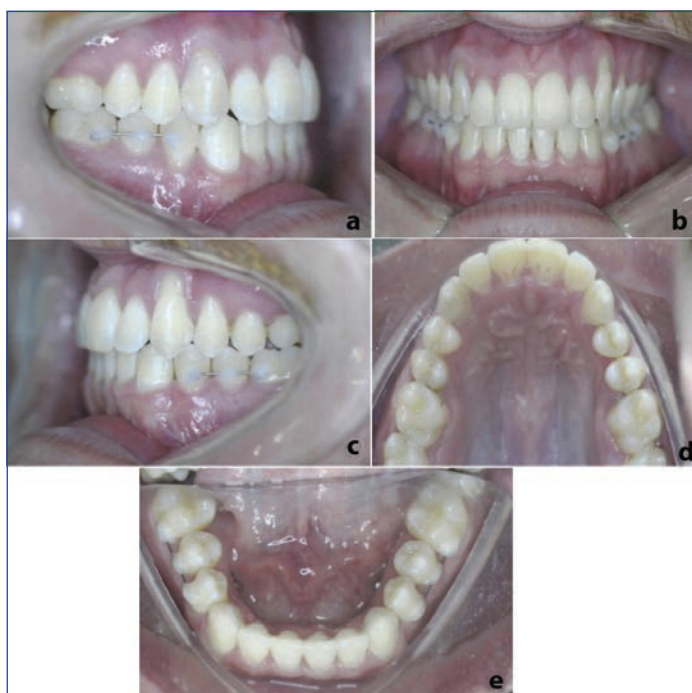

[Table/Fig-9]: Postsurgery intraoral photographs. a: Right-side; b: Frontal; c: Left-side; d: Upper occlusal; e: Lower occlusal.

orthodontic-surgical approach is indicated for such cases [9]. In the present case report, the patient presented with an increased vertical dimension, skeletal Class III malocclusion and skeletal anterior open bite, suggesting the need for orthodontic-surgical intervention to achieve satisfactory functional and aesthetic results.

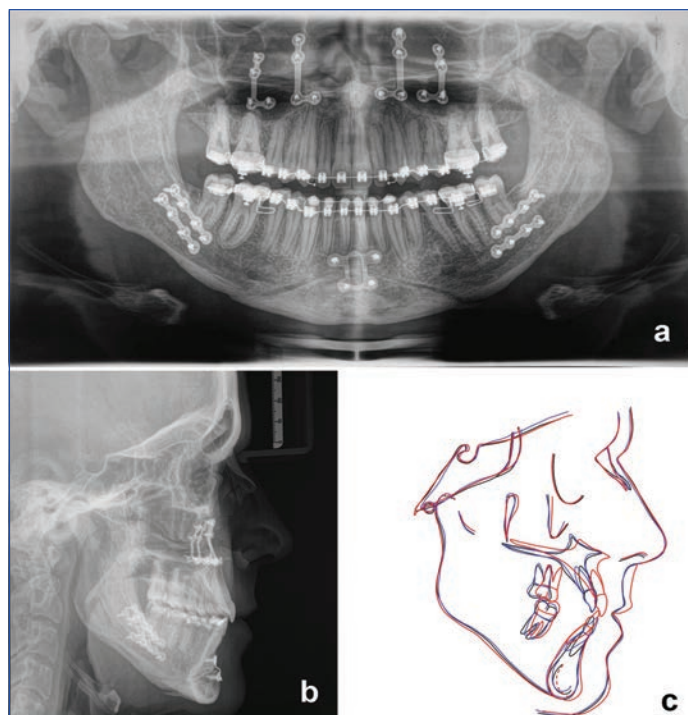


[Table/Fig-10]: Post-treatment extraoral photographs. a: Lateral, b: Frontal, c: Smile.



[Table/Fig-11]: Post-treatment intraoral photographs. a: Right-side, b: frontal, c: Left-side, d: Upper occlusal, e: Lower occlusal.

Regarding the surgical technique, rotation of the occlusal plane in the clockwise direction can generate a more stable result for the correction of the anterior open bite compared to the upward repositioning of the maxilla as a whole together with mandibular rotation in the counterclockwise direction [10,11]. In the present clinical case, clockwise rotation on the palatal plane was performed, favouring the stability of the correction of the anterior open bite. Moreover, conventional presurgical orthodontic preparation was chosen in this case due to the need for leveling the curve of Spee and creating space for the positioning of teeth 35 and 45, which



[Table/Fig-12]: Final panoramic radiograph (a), lateral cephalometric radiograph (b), and superimposition cephalometric tracing (c).

Measure	Norm	Author	Pretreatment	Presurgery	Post-treatment
SNA (°)	82	Steiner	74.6	75.6	77.8
SNB (°)	80	Steiner	76.6	78.2	78.7
ANB (°)	2	Steiner	- 2	- 2.6	- 0.9
AO-BO (mm)	-1 a 0	Jacobson	- 5.7	-11	-5
Convex (°)	0	Downs	-6.2	-7.8	4
Y-axis (°)	59.9	Downs	70.8	72.1	70.9
Facial (°)	87.8	Downs	83	88.2	82.3
SN.GoGn (°)	32	Steiner	46.8	40.2	40.4
SN.OcPI (°)	14	Steiner	17.4	24	17.8
FMA (°)	25	Tweed	39.6	39.7	35.1
IMPA (°)	87	Tweed	78.1	93.1	83
1.NA (°)	22	Steiner	25.3	30.3	23.6
1-NA (mm)	4	Steiner	7.8	7.2	8.6
1.NB (°)	25	Steiner	21.6	31.5	24.2
1-NB (mm)	4	Steiner	4.5	6.9	3
1.1 (°)	131	Steiner	135.2	121.1	133.1
LS-S (mm)	0	Steiner	- 5	- 7	-4
LI-S (mm)	0	Steiner	- 2	- 0.8	-3.1
Z-Angle (°)	75	Marrifield	74	74.7	76.4

[Table/Fig-13]: Cephalometric measurements.

SNA: Sella, Nasion, A point; SNB: Sella, Nasion, B point; ANB: A point, Nasion, B point; IMPA: Angle between long axis of lower incisor and mandibular plane angle; FMA: Frankfort Mandibular plane Angle; SN.OcPI: SN to Occlusal Plane Angle; NA: Nasion; SN.GoGn: SN to Gonion Gnathion

could generate important premature contacts if surgery has been performed first. Obviously, such a decision was made jointly between the orthodontist and oral-maxillofacial surgeon.

CONCLUSION(S)

The main factors that contributed to the favourable functional and aesthetic results of this treatment were the correct diagnosis, adequate orthodontic and surgical approaches, the application of precise forces, as well as the indication and appropriate use of the planned retention.

REFERENCES

[1] Angle, E. Classification of malocclusion. Dental Cosmos 1899;41:248-64. [https://www.scirp.org/\(S\(oyulxb452alnt1aej1nfow45\)\)/reference/ReferencesPapers.aspx?ReferenceID=628276](https://www.scirp.org/(S(oyulxb452alnt1aej1nfow45))/reference/ReferencesPapers.aspx?ReferenceID=628276).

- [2] Martin M, Lipani E, Lorenzo A, Martinez L, Aiuto R, Dioguardi M, et al. The effect of maxillary protraction, with or without rapid palatal expansion, on airway dimensions: A systematic review and meta-analysis. *Eur J Paediatr Dent.* 2020;21(4):262-70.
- [3] Lopez-Gavito G, Wallen T, Little R, Joondeph D. Anterior open-bite malocclusion: A longitudinal 10-year postretention evaluation of orthodontically treated patients. *Am J Orthod.* 1985;87(3):175-86.
- [4] Huang G. Long-term stability of anterior open-bite therapy: A review. *Semin Orthod.* 2002;8:162-72. <https://www.moroortodontia.com.br/leitura/huang%20revisao%20estabilidade%20seminars%202003.pdf>.
- [5] Remmers D, Hullenaar R, Bronkhorst E, Bergé S, Katsaros C. Treatment results and long-term stability of anterior open bite malocclusion. *Orthod Craniofac Res.* 2008;11(1):32-42.
- [6] Gallego-Romero D, Llamas-Carrera JM, Torres-Lagares D, Paredes V, Espinar E, Guevara E, et al. Long-term stability of surgical-orthodontic correction of class III malocclusions with long-face syndrome. *Med Oral Patol Oral Cir Bucal.* 2012;17(3):e435-441.
- [7] Ellis E, McNamara J. Components of adult class III open-bite malocclusion. *Am J Orthod.* 1984;86(4):277-90.
- [8] Denison T, Kokich V, Shapiro P. Stability of maxillary surgery in openbite versus nonopenbite malocclusions. *Angle Orthod.* 1989;59(1):05-10.
- [9] Hoppenreijts T, Freihofner H, Stoelinga P, Tuinzing D, van't Hof M, van der Linden F, et al. Skeletal and dentoalveolar stability of Le Fort I intrusion osteotomies and bimaxillary osteotomies in anterior open bite deformities. A retrospective three-centre study. *Int J Oral Maxillofac Surg.* 1997;26(3):161-75.
- [10] Moldez M, Sugawara J, Umemori M. Long-term dentofacial stability after bimaxillary surgery in skeletal Class III open bite patients. *Int J Adult Orthodon Orthog Surg.* 2000;15(4):309-19.
- [11] Ooi K, Inoue N, Matsushita K, Yamaguchi H, Mikoya T, Kawashiri S, et al. Comparison of postoperative stability between BSSRO and Le Fort 1 osteotomy with BSSRO in Skeletal class III malocclusion with severe open bite. *J Maxillofac Oral Surg.* 2019;19(4):591-95.

PARTICULARS OF CONTRIBUTORS:

1. Department of Orthodontics, Universidade Federal de Juiz de Fora, Juiz de Fora, MG, Brazil.
2. PhD, Department of Orthodontics, Universidade Federal de Juiz de Fora, Juiz de Fora, MG, Brazil.
3. Department of Clínica de CTBMF, Odontoclínica Central da Marinha, Rio de Janeiro, RJ, Brazil.
4. Private Practitioner, Rio de Janeiro, RJ, Brazil.
5. Department of Orthodontics, Universidade Federal de Juiz de Fora, Juiz de Fora, MG, Brazil.

NAME, ADDRESS, E-MAIL ID OF THE CORRESPONDING AUTHOR:

Sergio Luiz Mota-Júnior,
Avenida Barão do Rio Branco, 2595/1307, ZIP-36010-907, Juiz de Fora,
MG, Brazil.
E-mail: sergiomotajr_orto@yahoo.com.br

PLAGIARISM CHECKING METHODS: [Lain H et al.]

- Plagiarism X-checker: Aug 03, 2022
- Manual Googling: Aug 30, 2022
- iThenticate Software: Sep 13, 2022 (8%)

ETYMOLOGY: Author Origin**AUTHOR DECLARATION:**

- Financial or Other Competing Interests: None
- Was informed consent obtained from the subjects involved in the study? Yes
- For any images presented appropriate consent has been obtained from the subjects. Yes

Date of Submission: **Aug 02, 2022**Date of Peer Review: **Aug 31, 2022**Date of Acceptance: **Sep 14, 2022**Date of Publishing: **Oct 01, 2022**