

# Gliosarcoma in a Paediatric Patient: A Rare Entity and Review of Literature

MEENAKSHI SHANKAR<sup>1</sup>, SACHIN KOLTE<sup>2</sup>, KB SHANKAR<sup>3</sup>, VIVEK YADAV<sup>4</sup>

## ABSTRACT

Primary Gliosarcoma is a rare malignant tumour of central nervous system in adults. It is usually a variant of Isocitrate Dehydrogenase (IDH) wild type glioblastoma. Its incidence is approximately 2% of glioblastomas and has a dismal prognosis. Most common age group is between 40-60 years of age is commonly seen in males. Paediatric gliosarcoma is even rarer than adults ones. Most common location is temporal and frontal lobes (cerebral hemisphere). Histologically, it shows biphasic pattern and is composed of both glial and mesenchymal components. Both these components has monoclonal proliferations. Here, a 20-month-old boy resident of Gorakhpur, presented with persistent crying for short duration in neurosurgery emergency. On magnetic resonance studies a frontotemporal lesion was found, for which he underwent tumour excision. The tumour proved to be a primary gliosarcoma. Due to malignant nature of tumour patient did not survive. Gliosarcoma is rare adult tumour, but can rarely occur in children. A differential diagnosis of gliosarcoma should be kept in mind, while dealing with congenital tumours in children, due its aggressive nature with poor survival outcome.

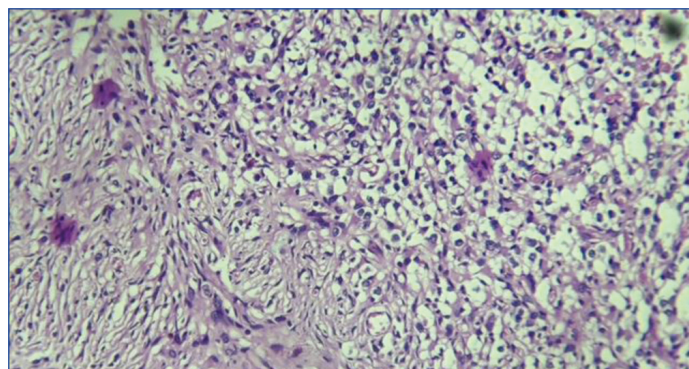
**Keywords:** Biphasic lesion, Central nervous system, Glioblastoma, Isocitrate dehydrogenase

## CASE REPORT

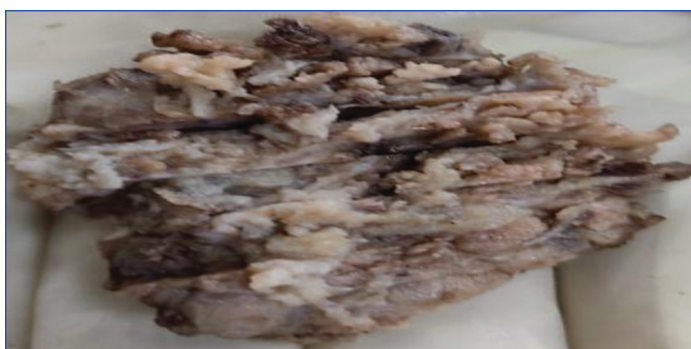A 20-month-old boy resident of Gorakhpur, presented with persistent crying of very short duration in neurosurgery emergency. Child was fully vaccinated till his age. No significant past history, family and medical history were unremarkable. On physical examination, patient was conscious, oriented, afebrile, no pallor, icterus, cyanosis, oedema. On systemic examination cardiovascular system, respiratory system per abdomen examination were unremarkable. Central nervous system examination was also normal. His blood pressure and sugar was normal. The brain Magnetic Resonance Imaging (MRI) with contrast revealed a heterogenous appearing lesion in left frontotemporal region of brain measuring 6.10×5.26×3.10 cm. A provisional diagnosis of Primary Neuroectodermal Tumour (PNET) or meningioma, was made. Tumour was removed and sent for histopathological examination.

**Gross examination-**Received a single globular grey brown soft tissue piece measuring 6×4×2 cm [Table/Fig-1]. On serial sectioning, grey white areas were identified. Microscopic examination showed biphasic pattern. Tumour was infiltrating in surrounding brain parenchyma. Tumour cells are arranged in sheets, fascicle and bundle, composed of spindle shape cells having mild to moderate eosinophilic cytoplasm, nuclei were elongated showing mild to moderate pleomorphism. Another component seen comprised of pleomorphic glial cells intermixed gemistocyte. These cells have moderate amount of amphiphilic cytoplasm, hyperchromatic nuclei irregular nuclear membrane and inconspicuous nucleoli.

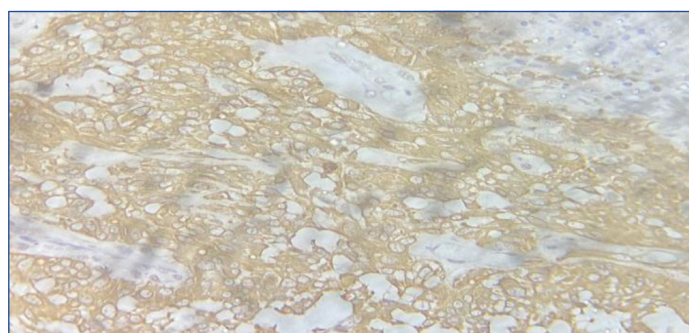
Atypical mitosis 5-6/10 HPF were seen. Areas of necrosis and vascular proliferation was also identified. A differential diagnosis of glioblastoma, sarcoma primary or secondary was made [Table/Fig-2]. Immunohistochemical (IHC) staining was performed and tumour cells were positive for vimentin [Table/Fig-3] and p53 [Table/Fig-4]. Glial Fibrillary Acidic Protein (GFAP) was positive in glial component [Table/Fig-5] and mesenchymal component was positive for Desmin. Both the component were negative for IDH-1 (Isocitrate Dehydrogenase). On the basis of morphology and immunohistochemistry diagnosis of gliosarcoma {World Health Organisation (WHO) grade 4} was made. Baby expired three days after surgery because of aggressive nature of tumour.



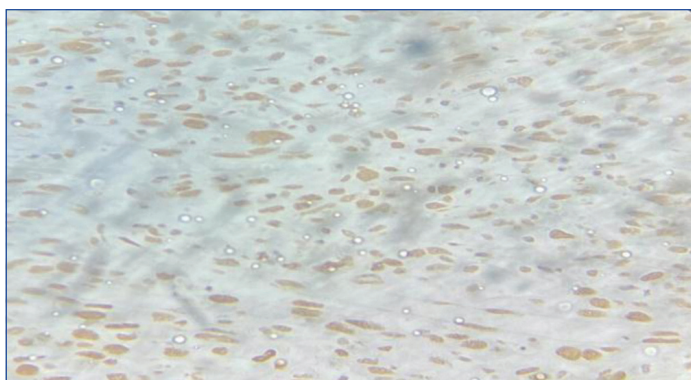
**[Table/Fig-2]:** Microscopic examination showing biphasic appearance of gliosarcoma. Glial component at top right is sharply demarcated from mesenchymal component at the left bottom (H&E; 40X).



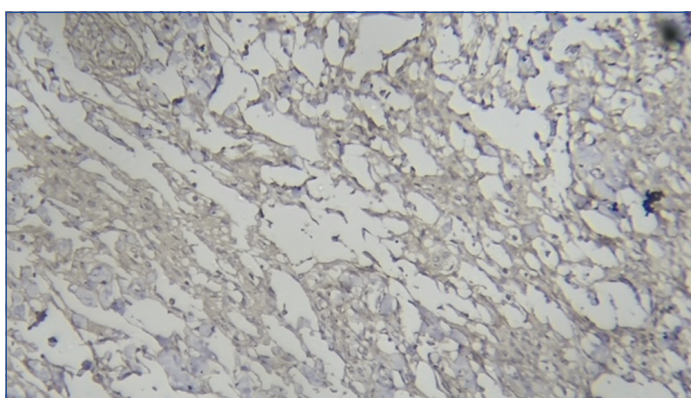
**[Table/Fig-1]:** Gross examination-A single globular grey brown soft tissue piece measuring 6×4×2 cm.



**[Table/Fig-3]:** Microscopic examination showing vimentin positivity in tumour cells (IHC; 40X).



[Table/Fig-4]: Microscopy examination showing p53 positive tumour cells (IHC; 40X).



[Table/Fig-5]: Microscopic examination showing GFAP (Glial fibrillary acidic protein) positivity in glial components (IHC; 40X).

## DISCUSSION

Gliosarcoma is a rare malignant tumour of central nervous system. It is usually a variant of IDH wild type glioblastoma. Its incidence is approximately 2% of glioblastomas and has a dismal prognosis. Most common age group is between 40-60 years of age is commonly seen in male. Paediatric gliosarcoma is even rarer than adult ones [1,2]. Most common location is temporal and frontal lobes (cerebral hemisphere). Histologically, it shows biphasic pattern and composed of both glial and mesenchymal (sarcomatous) components. Both these components have monoclonal proliferations. The tumour usually appeared to be circumscribed and superficial located.

Microscopically, glioblastoma like differentiation was seen in glial component. This glial part showed astrocytic differentiation with less commonly oligodendroglial and ependymomal differentiation, was also reported. Mesenchymal (sarcomatous) component was composed of spindle cells arranged in fascicle with nuclear atypia along with atypical mitoses and necrosis. The mesenchymal component was reticulin rich (highlighted on reticulin stain) whereas the glial areas was reticulin poor. On IHC staining, glial fibrillary acidic

protein was positive in glial areas while the mesenchymal areas were negative [1]. Vimentin and p53 seen positive in both component. While IDH-1 was negative in both the tumour cells.

Paediatric gliosarcoma, is extremely rare and has worse prognosis, than glioblastoma. Clinical presentation and histological feature are same as that of adult gliosarcomas. On imaging studies, these tumours may mimic meningioma due its relative discreteness [3,4]. Similarly, on gross examination, it may mimic as a meningioma or metastases, as it appearance as firm, circumscribed mass with some attachment to dura [1]. In the present case, a PNET was given as provisional radiological diagnosis. The diagnosis is made when the classic biphasic pattern is well developed and confirmed on immunohistochemistry. However, the sarcomatous areas in both paediatric and adult gliosarcoma can resemble fibrosarcoma. Mesenchymal differentiation can be other types such as striated muscle and smooth differentiation (resembling rhabdomyosarcoma and leiomyosarcoma), lipomatous differentiation (similar to liposarcoma) cartilage and bone formation (resembling chondro or osteosarcoma), and primitive neural differentiation. In paediatric gliosarcoma, if cartilage or bone, other mesenchymal differentiation are seen they can be mistaken for teratoma [5-10]. Another differential diagnosis was Desmoplastic Infantile Astrocytoma (DIA). It is rare slow-growing tumour, which commonly occurs in infants. However, DIA is WHO grade 1 tumour, unlike gliosarcoma which WHO grade 4 with poor prognosis. It appears as a large cystic mass in the supratentorial cerebral cortex, with some attachment to the dura. Histologically, as the name suggests, tumour is composed of a desmoplastic stroma, which is very prominent and streams of neoplastic astrocytes are lying in them. Mitotic activity is very low and necrosis is not seen. Ki-67 proliferating index is always <2% [1]. At the molecular level, both adult and paediatric gliosarcomas exhibits Phosphatase and Tensin homologue (PTEN) and TP53 mutations and Cyclin-Dependent Kinase inhibitor 2A (CDKN2A) deletions.

In the present case, tumour was located in frontotemporal region, similar to reported by Din NU et al., [11], Okami N et al., [18]. Granados AM et al., [14] reported a pineal gliosarcoma in a five-year-old girl, the first reported case in this unusual location. Mangement includes total resection of tumour, if possible. In this case, tumour was en-toto removed and child died in perioperative period similar to Rizk T et al., [19]. When literature was reviewed authors found that only 14 case reports of paediatric gliosarcoma under five years of age have been reported till date [Table/Fig-6] [11-23]. However, paediatric gliosarcomas can be seen in other locations like thalamus [24]. In the present case report, patient was less than two years of age. On histopathological examination, tumour proved to be a primary gliosarcoma. Due to malignant nature of tumour, patient did not survive.

S. No.	Authors	Age (years)/ Gender (M/F)	Location/Site	Resection (Total/partial)	Chemo/radiotherapy	Survival after resection
1.	Present case	20 months/M	Frontotemporal lobe	Total	No/no	Died after 3 days of age
2.	Din NU et al., 2021 [11]	3/M	Frontotemporal lobe	-	No/yes	Died after 6 months resection
		5/M	Right frontal lobe	-	Yes/yes	3 months after removal
3.	Dogan GM et al., 2020 [12]	3/M	Left parietal lobe extending to the vortex	Palliative resection	Yes/yes	Recurred 8 months after removal, alive
5.	Bouali S et al., 2020 [13]	5 months/M	Right lobe	Total removal	No/no	Alive after 17 months of follow-up
6.	Granados AM et al., 2017 [14]	5/F	Pineal	NA	Radio and chemotheapy	Metastatic dissemination
7.	Savant HV et al., 2015 [15]	5/F	Left parieto-occipital lobe	Total	Yes/no	Died after 9 months
8.	Moscote-Salazara LR et al., 2014 [16]	4/M	NA	NA	No/yes	Alive
9.	Hocwald O et al., 2009 [17]	1 day old/M congenital	Left anterior cerebral hemisphere	NA	No/no	Baby died at day 1 of age
10.	Okami N et al., 2002 [18]	2/M	Left frontal lobe	Total	No/yes	Died after 3 months of surgery
11.	Rizk T et al., 2000 [19]	Neonate/NA	Left temporoparieto-occipital lobes	Total	No/no	Perioperative death

12.	Ono N et al., 1990 [20]	3 months/F	Left temporoparietal lobes and basal ganglion	Total	No/yes	Died 34 months after resection
13.	Rodkowski MA et al., 1988 [21]	60 days/M	Right temporal lobe	NA	NA	Alive at 34 months after surgery
14.	Chaddock WM et al., 1987 [22]	2/M	Right cerebral cortex diffuse widespread involvement	Partial	No/no	NA
15.	Goldstein SJ et al., 1981 [23]	4 months/F	Left cerebral hemisphere (diffuse wide spread involvement)	NA	NA	NA

**[Table/Fig-6]:** Summary of review of literature of paediatrics gliosarcoma (≤5 years of age) [11-23].

## CONCLUSION(S)

Primary gliosarcomas are malignant tumours in young children. A differential diagnosis of gliosarcoma should be kept in mind while dealing with congenital tumours, due to its aggressive nature and poor survival outcome.

## REFERENCES

- Alatakis S, Stuckey S, Siu K, McLean C. Gliosarcoma with osteosarcomatous differentiation: Review of radiological and athological features. *J Clin Neurosci*. 2004;11:650-56.
- Han SJ, Yang I, Tihan T, Prados MD, Parsa AT. Primary gliosarcoma: Key clinical and pathologic distinctions from glioblastoma with implications as a unique oncologic entity. *J Neurooncol*. 2010;96:313-20.
- Swaidan MY, Hussaini M, Sultan I, Mansour A. Radiological findings in gliosarcoma. A single institution experience. *Neuroradiol J*. 2012;25:173-80.
- Romero-Rojas AE, Diaz-Perez JA, Ariza-Serrano LM, Amaro D, Lozano-Castillo A. Primary gliosarcoma of the brain: Radiologic and histopathologic features. *Neuroradiol J*. 2013;26:639-48.
- Ravisankar S, Chander RV, Devadoss PK. Paediatric gliosarcoma with fibrosarcomatous differentiation: Report of a rare case. *Indian J Pathol Microbiol*. 2012;55:521-24.
- Kepes JJ, Fulling KH, Garcia JH. The clinical significance of "adenoid" formations of neoplastic astrocytes, imitating metastatic carcinoma, in gliosarcomas. A review of five cases. *Clin Neuropathol*. 1982;1:139-50.
- Tada T, Katsuyama T, Aoki T, Kobayashi S, Shigematsu H. Mixed glioblastoma and sarcoma with osteoid-chondral tissue. *Clin Neuropathol*. 1987;6:160-63.
- Mørk SJ, Rubinstein LJ, Kepes JJ, Perentes E, Uphoff DF. Patterns of epithelial metaplasia in malignant gliomas. II Squamous differentiation of epithelial-like formations in gliosarcomas and glioblastomas. *J Neuropathol Exp Neurol*. 1988;47:101-18.
- Hayashi K, Ohara N, Jeon HJ, Akagi S, Takahashi K, Akagi T, et al. Gliosarcoma with features of chondroblastic osteosarcoma. *Cancer*. 1993;72:850-55.
- Fukuda T, Yasumichi K, Suzuki T. Immunohistochemistry of gliosarcoma with liposarcomatous differentiation. *Pathol Int*. 2008;58:396-01.
- Din NU, Ishtiaq H, Rahim S, Abdul-Ghaffar J, Ahmad Z. Gliosarcoma in patients under 20 year. *BMC Paediatrics*. 2021;21:101.
- Dogan GM, Sigirci A, Cengiz A, Erbay MF, Gokce H. A case of gliosarcoma in a child with neurofibromatosis type 1. *Ann Med Res*. 2020;27:2214-17.
- Bouali S, Bahri K, Zehani A, Haj AB, Said IB, Kallel J, et al. Complete surgical resection of a congenital gliosarcoma with long time survival: Case report and review of the literature. *Human Pathology: Case Reports*. 2020;21:200375.
- Granados AM, Ospina C, Paredes S. Pineal gliosarcoma in a 5-year-old girl. *Radiol Case Rep*. 2017;13:244-47.
- Savant HV, Balasubramaniam S, Mahajan V. Giant parietal lobe infantile gliosarcoma in a 5-year-old child. *J Pediatr Neurosci*. 2015;10:159-61.
- Moscote-Salazara LR, Alcalá-Cerra G, Gutierrez-Paternina JJ, Penagos Gonzelezc PJ, Zubieta Vega C, Chater-Cure G, et al. Paediatric gliosarcoma: Case report and literature review. *Bol Asoc Med PR*. 2014;106:43-47.
- Hocwald O, McFadden D, Oslovich H, Dunham C. Congenital gliosarcoma: Detailed clinicopathologic documentation of a rare neoplasm. *Pediatr Dev Pathol*. 2009;12:398-03.
- Okami N, Kawamata T, Kubo O, Yamane F, Kawamura H, Hori T, et al. Infantile gliosarcoma: A case and a review of the literature. *Childs Nerv Syst*. 2002;18:351-55.
- Rizk T, Nabbout R, Koussa S, Akatcherian C. Congenital brain tumor in a neonate conceived by in vitro fertilization. *Childs Nerv Syst*. 2000;16:501-02.
- Ono N, Nakamura M, Inoue HK, Tamura M, Murata M. Congenital gliosarcoma; So-called sarcoglioma. *Childs Nerv Syst*. 1990;6:416-20.
- Radkowski MA, Naidich TP, Tomita T, Byrd SE, McLone DG. Neonatal brain tumors: CT and MR findings. *J Comput Assist Tomogr*. 1988;12(1):10-20.
- Chaddock WM, Gollin SM, Gray BA, Norris JS, Araoz CA, Tryka AF, et al. Gliosarcoma with chromosome abnormalities in a neonate exposed to heptachlor. *Neurosurgery*. 1987;21:557-59.
- Goldstein SJ, Young B, Markesberry WR. Congenital malignant gliosarcoma. *AJNR Am J Neuroradiol*. 1981;2:475-76.
- Neelima R, Abraham M, Kapilamoorthy TR, Hingwala DR, Radhakrishnan VV. Paediatric gliosarcoma of thalamus. *Neuro India*. 2012;60:674-76.

### PARTICULARS OF CONTRIBUTORS:

- Senior Resident, Department of Pathology, VMMC and Safdarjung Hospital, Delhi, India.
- Professor, Department of Pathology, VMMC and Safdarjung Hospital, Delhi, India.
- Professor and Head, Department of Neurosurgery, VMMC and Safdarjung Hospital, Delhi, India.
- Associate Professor, Department of Neurosurgery, VMMC and Safdarjung Hospital, Delhi, India.

### NAME, ADDRESS, E-MAIL ID OF THE CORRESPONDING AUTHOR:

Dr. Sachin Kolte,  
405, Main Building, VMMC and Safdarjung Hospital, Delhi, India.  
E-mail: drsachinkolte@gmail.com

### PLAGIARISM CHECKING METHODS:

- Plagiarism X-checker: Apr 27, 2022
- Manual Googling: Jun 17, 2022
- iThenticate Software: Jun 20, 2022 (5%)

### ETYMOLOGY: Author Origin

### AUTHOR DECLARATION:

- Financial or Other Competing Interests: None
- Was informed consent obtained from the subjects involved in the study? No
- For any images presented appropriate consent has been obtained from the subjects. NA

Date of Submission: **Apr 26, 2022**

Date of Peer Review: **May 09, 2022**

Date of Acceptance: **Jun 22, 2022**

Date of Publishing: **Dec 01, 2022**