

Histopathological and Immunohistochemical Analysis of Rare Parotid Tumours: A Case Series

SAYANTAN DE¹, PIYALI KUNDU², SONA DAS³, MADHUMITA MONDAL⁴

ABSTRACT

Malignant salivary gland tumours are rare representing only 2% of all head and neck malignancies. The most common malignant salivary gland tumour is mucoepidermoid carcinoma followed by adenoid cystic carcinoma while parotid is the most common site. But there are presence of other rare variants with diverse biological feature of malignancy including Salivary Duct Carcinoma (SDC), basal cell adenocarcinoma, Carcinoma ex Pleomorphic Adenoma (CXPA), polymorphous adenocarcinoma which represent 1-5% of all salivary gland neoplasm. They typically are high-grade carcinomas with presence lymph nodal metastases. Hereby, author report 5 rare cases of parotid gland malignancy detected by histopathological examination along with confirmation by immunohistochemical examination. A 60-year-old and 65-year-old male diagnosed with salivary duct carcinoma of left parotid and right parotid respectively with ipsilateral cervical lymph node involvement but peripheral resection margins were free from tumour invasion. A 50-year-old female diagnosed with basal cell adenocarcinoma of left parotid with lymph node metastasis and resection margin was involved by the tumour. A 60-year-old male presented with recurrent swelling in left parotid region, diagnosed as carcinoma ex pleomorphic adenoma with lymph node involvement in a case of pleomorphic adenoma of parotid, reported previously. A 52-year-old male presented with right-sided parotid region swelling for last six months having Fine Needle Aspiration Cytology (FNAC) report of pleomorphic adenoma. Parotidectomy revealed diagnosis of polymorphous adenocarcinoma while surgical resection margins were free. Surgery is the main mode of treatment in these tumours. Involvement of resection margins, extraparotid extension, lymphovascular and perineural invasion along with lymph node metastasis are the common indicator for postoperative radiation therapy.

Keywords: Cytology, Carcinoma, Microscopic examination, Salivary gland

INTRODUCTION

The parotid gland is most common site for salivary gland tumours. Primary carcinomas of the salivary glands are uncommon, fewer than 0.3% of all cancers. Though most common presentation is parotid region swelling, pain, facial palsy, lymph node involvement, fixity, and deep lobe involvement indicate malignant behaviour. Parotidectomy is the main modality of treatment in addition to that preoperative imaging and Fine Needle Aspiration Cytology (FNAC) report may be helpful in correct diagnosis and in early management also [1].

Malignant tumour occurs in older age compared to its benign counterpart while mean age ranges from 41.9 to 43 years. Although majority of the tumour occur in parotid gland (60-84%), malignancy rate is lower than benign one. Out of all cases pleomorphic salivary adenoma is the most prevalent salivary gland tumour in approximately 42% cases while three most common malignant tumours are adenoid cystic carcinoma, mucoepidermoid carcinoma and acinic cell carcinoma [2]. There are rare other malignant tumours include adenocarcinoma, squamous cell carcinoma, poorly differentiated carcinoma and Lymphoma also. of salivary glands is rare and commonly involves parotid gland [3].

Hereby authors discusses five rare cases of parotid gland malignancy detected by histopathological examination of parotidectomy specimen with or without lymph node dissection from January 2021 in the Department of Pathology. Two were salivary duct carcinoma, others were basal cell adenocarcinoma, carcinoma ex pleomorphic adenoma and polymorphous adenocarcinoma with emphasis on resection margin involvement, lymph node metastasis and lymphovascular or perineural invasion, depicting their aggressiveness and prognostic outcome. Detailed clinical history, previous biopsy report, FNAC report, hematological, biochemical parameters along with relevant radiological reports were documented. Various

immunohistochemical markers like HER2/neu, S100, vimentin, Ki67, P63, ER, PR, CK7 and EMA were being used to confirm the diagnosis of those five parotid tumours.

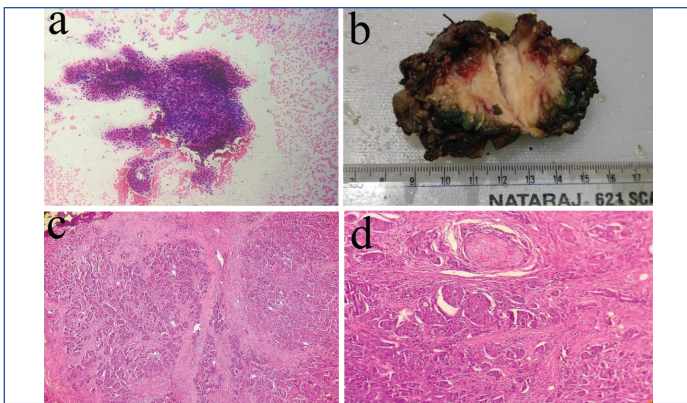
CASE SERIES

Case 1

A 60-year-old male had rapidly growing large left-sided parotid swelling for last one year with left cervical lymphadenopathy. The swelling was hard in nature with mild tenderness and overlying skin showed no ulceration. In FNAC from parotid, it described as malignant epithelial neoplasm [Table/Fig-1a]. On gross examination superficial parotid lobe measuring 6x4x3 cm [Table/Fig-1b], on cutting it showed variegated appearance. Microscopic examination showed pleomorphic epithelial cells having abundant eosinophilic cytoplasm, vesicular chromatin and prominent nucleoli and in situ component of cribriform pattern with comedonecrosis with presence of marked desmoplasia [Table/Fig-1c]. Lymphovascular and perineural invasion were seen with free resection margins [Table/Fig-1d]. 10 cervical lymph node showed metastatic deposit. Histological features were resembled like infiltrating duct carcinoma of breast-so it diagnosed as salivary duct carcinoma of left parotid with stage being T3N2Mx. Postoperatively patient was closely followed up for any signs of recurrence or any other lymph node involvement. Any features of prolonged facial palsy was absent. Patient was also undergone radiation therapy in the Department of Radiotherapy.

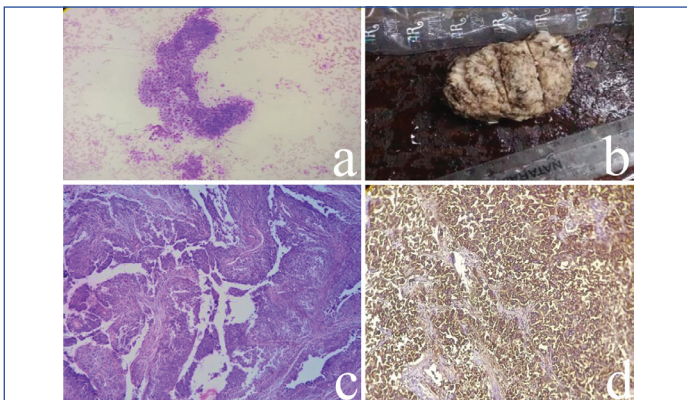
Case 2

A 65-year-old male presented with huge rapidly increasing firm to hard right parotid swelling with bilateral cervical lymphadenopathy for last 10 months. There was no history of skin ulceration, fever, night sweats or drastic weight loss but decreased appetite was



[Table/Fig-1]: (a) Cytology Papanicolaou smear shows pleomorphic hyperchromatic epithelial cells arranged in glandular pattern-possibility of malignant epithelial neoplasm; (b): Gross picture of parotidectomy specimen-cut section is solid whitish; (c) Shows pleomorphic epithelial cells having abundant eosinophilic cytoplasm, vesicular chromatin and prominent nucleoli arranged in glands with presence of marked desmoplasia (H&E stain, 40X); (d) Shows presence of malignant gland like structure with perineural invasion (H&E stain, 100X).

described. Preoperative FNAC reported as malignant epithelial neoplasm [Table/Fig-2a]. On gross whitish growth with areas of cystic changes and necrosis measuring 6×5×3 cm [Table/Fig-2b]. Microscopic examination revealed comedonecrosis and pleomorphic cells with eosinophilic cytoplasm arranged in glands, cords, nests-suggestive of salivary duct carcinoma [Table/Fig-2c]. Lymphovascular invasion was present but margins were free. Two right nodes showed metastatic deposit with stage of T3N2Mx. Patient died on day two due to postoperative complication.



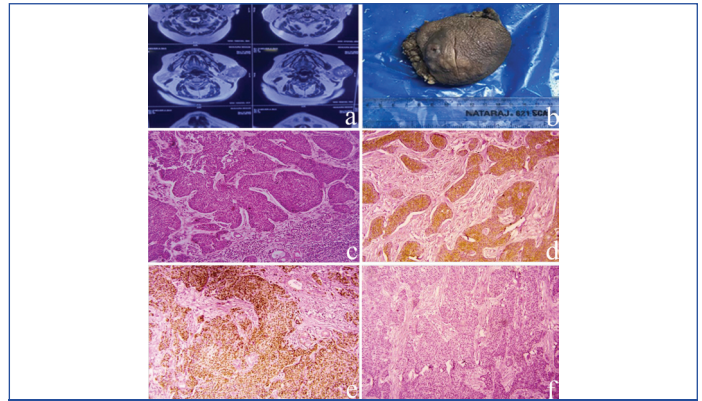
[Table/Fig-2]: (a) Cytology smear (LGG) shows pleomorphic hyperchromatic epithelial cells with abundant eosinophilic cytoplasm arranged in glandular pattern-possibility of malignant epithelial neoplasm (b) Gross examination- whitish growth measuring 6x5x3 cm; (c) Shows pleomorphic epithelial cells arranged in glands, cords with areas of comedonecrosis (H&E stain, 40X); (d) HER2/neu shows strong membrane positivity.

Immunohistochemically in both cases showed HER2/neu was positivity [Table/Fig-2d] along with expression of CK7 and EMA but CK 20, ER and PR were negative.

Case 3

A 50-year-old female presented with left parotid swelling for last five year. The swelling was firm in nature which increase in size rapidly last four months. There was no tenderness, skin ulceration or palpable lymph node clinically. Imaging study revealed possibility of pleomorphic salivary adenoma with multiple cervical lymphadenopathy [Table/Fig-3a]. Parotidectomy with modified radical neck dissection was done. After receiving the specimen whitish growth noted measuring 5×5×3 cm [Table/Fig-3b]. Histopathology revealed a tumour mass composed of basaloid cells in nests arranged in jigsaw puzzle appearance with cells showing peripheral palisading-consistent with basal cell adenocarcinoma [Table/Fig-3c]. Peripheral resection margins were involved by the tumour. Total one lymph node out of 13 was involved by neoplastic cells with stage of T3N1Mx. Immunohistochemical expression of HER2/neu [Table/Fig-3d], CK7 and P63 [Table/Fig-3e] were positive although Ki67 expression level were below 5%

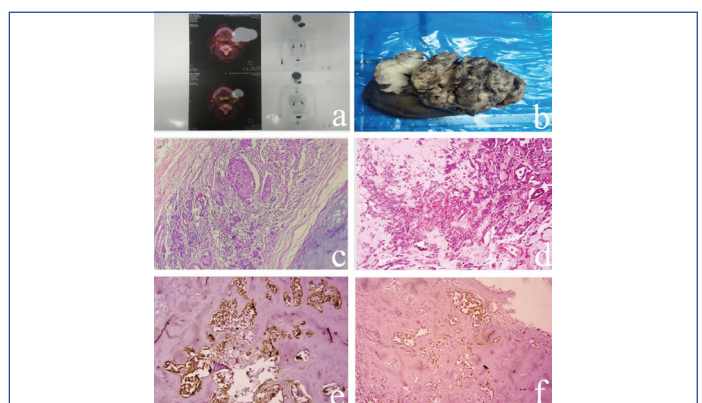
[Table/Fig-3f]. Patient was doing well postoperatively and no signs of facial palsy noted while she was regularly followed-up in Outpatient Department.



[Table/Fig-3]: (a): MRI picture showed lobulated lesion of altered signal intensity-? Pleomorphic adenoma; (b): Gross examination showed skin covered tissue piece measure 5x5x3 cm; (c): Shows basaloid cells in nests arranged in jigsaw puzzle appearance with cells showing peripheral palisading (H&E, 100X); (d): HER2/neu shows positivity (3+); (e): P63 shows nuclear positivity; (f): Ki67 less than 5%.

Case 4

A 60-year-old male presented with sudden increase of painful, firm to hard left parotid region swelling for four months with history of pleomorphic adenoma of parotid diagnosed seven years back. Skin ulceration with weight loss noted but no signs of facial palsy was documented. Positron Emission Tomography and Computed Tomography (PET-CT) scan revealed large lesion probably neoplastic in nature in left parotid region [Table/Fig-4a]. On gross fungating whitish growth noted measuring 17×15×12 cm [Table/Fig-4b]. Microscopy revealed pleomorphic hyperchromatic epithelial cells arranged mainly in glands with areas of pleomorphic adenoma with free margins but having lymphovascular invasion [Table/Fig-4c,d]. Total five lymph nodes showed tumour deposit. Diagnosed as carcinoma ex pleomorphic adenoma with stage of T4aN2Mx. Immunohistochemical expression of HER2/neu was 3+ (positive) but ki67 expression was not that significant [Table/Fig-4e,f]. The CK7 and EMA were also expressed but ER and PR were negative. Postoperatively patient was doing well and he was referred to Radiotherapy Department where he received radiation therapy and follow-up also done by the Radiotherapy department also.

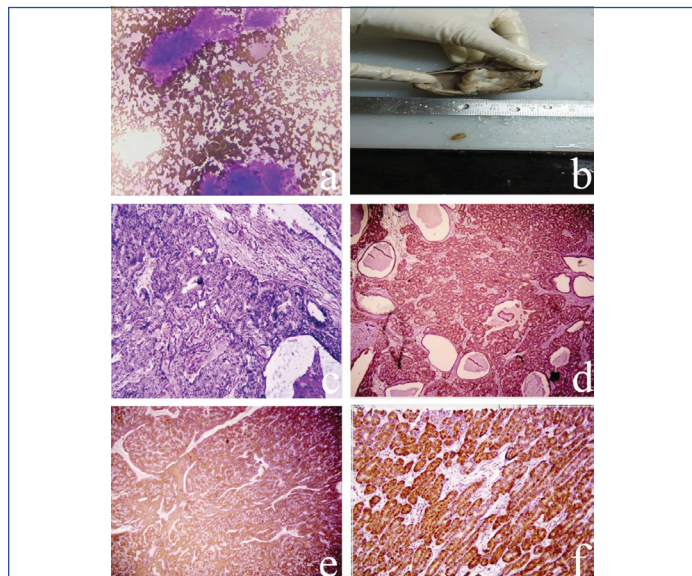


[Table/Fig-4]: (a) Positron emission tomography computed tomography scan showed large lesion probably neoplastic in nature in left parotid region; (b): Gross examination showed fungating whitish growth noted measuring 17x15x12 cm; (c): Shows adenocarcinoma with presence of pleomorphic salivary adenoma (H&E, 40X); (d) Shows pleomorphic epithelial cells arranged in glands (H&E, 100X); (e): HER2/neu showed 3+ membranous positivity; (f): Ki67-10% cells show nuclear positivity.

Case 5

A 52-year-old male had right parotid region swelling for last six months. Swelling was firm in nature with no tenderness, skin ulceration or any other palpable neck swelling. FNAC from parotid region showed features suggestive of pleomorphic adenoma of salivary gland [Table/Fig-5a]. Superficial parotidectomy was done only. Solid-cystic tissue piece

measuring 6x5x4 cm with cut section of solid area was whitish and homogenous [Table/Fig-5b]. Microscopically, tumour mass arranged in tubular and papillary pattern with lining cells having pleomorphic vesicular nuclei with eosinophilic secretion intraluminally but and free surgical resection margin [Table/Fig-5c]. Diagnosed as polymorphous adenocarcinoma with stage T3N2Mx. Immunohistochemical expression of CK7 and HER2/neu were positive [Table/Fig-5d] along with vimentin [Table/Fig-5e] and S100 [Table/Fig-5f]. Although postoperative status was uneventful but patient did not come for further follow-up. All the above five cases are summarised in [Table/Fig-6].



[Table/Fig-5]: (a) Cytology shows chondromyxoid areas (L-G stain, 40X); (b) Gross examination Solid-cystic tissue piece measuring 6x5x4 cm with cut-section of solid area was whitish and homogenous; (c) Shows tubular and papillary pattern with lining cells having pleomorphic vesicular nuclei with eosinophilic secretion intraluminally in cystic areas (H&E stain, 100X); (d) S100 shows positivity, HER2/neu shows membranous positivity; (e) Vimentin positivity; (f) S100 shows positivity.

breast, but immunohistochemistry may require to confirm diagnosis and for therapy also [7,8]. Immunohistochemically, tumour cells are diffusely positive for cytokeratin 7 and androgen receptor. HER2/neu positivity occurs in 15-40% of patients with SDC. Postoperative radiotherapy after wide surgical excision along with lymph node dissection is most standard treatment for SDC [9].

In present case series two cases that diagnosed histologically as salivary duct carcinoma, were male having age above 60 with size of being 6 cm. Lymphovascular invasion and perineural invasion was observed while margin being free microscopically. Both cases cervical lymph node involvement was observed with stage of T3N2Mx. Immunohistochemically HER2/neu was positive along with CK7 but CK 20 was negative. Adjuvant radiation therapy was given postoperatively in one patient while other patient died due to sepsis.

Basal cell adenocarcinoma comprises only less than 2% of all major salivary gland malignancy, mostly from parotid either de novo or from pre-existing basal cell adenoma [10]. The peak incidence was in the sixth decade and parotid was the predominant site. A solid type growth configuration along with membranous, trabecular, and tubular types were also found [11]. The tumour sizes ranged from 0.9 to 8.5 cm. Histologically, tumour cells had basophilic nuclei, scanty cytoplasm and palisading. Tumour that metastasized had higher nuclear grade features. High mitotic count was one of the notable features. Ki-67 antigen interpretation ranged from 0.4 to 53.3 % [12]. Morphologically it showed histologic features of invasion, mitotic activity, and neural or vascular involvement which helps to differentiate from basal cell adenoma. The differential diagnosis of pleomorphic adenoma is also kept in mind [13]. In the present case series a 50-year-old female presented with left parotid swelling measuring 5 cm across and in imaging study reported as pleomorphic adenoma of salivary gland. Histopathologically tumour mass composed of basaloid cells in nests with cells showing

Case	Age (years)	Gender	Preoperative findings	Histological diagnosis	Stage	IHC	Follow-up
Case 1	60	Male	Hard swelling in left parotid region. FNAC: showed malignant epithelial neoplasm	Salivary duct adeno carcinoma	T3N2Mx	HER2/neu, CK7,EMA-Positive ER, PR-Negative	Radiation
Case 2	65	Male	Firm to hard selling in right parotid with lymphadenopathy FNAC: showed malignant epithelial neoplasm	Salivary duct adeno carcinoma	T3N2Mx	HER2/neu, CK7,EMA-Positive ER, PR-Negative	Death
Case 3	50	Female	Firm palpable swelling with rapid increase in size in last 4 months. Imaging-showed pleomorphic salivary adenoma	Basal cell adenocarcinoma	T3N1Mx	p63, CK7, HER2/neu-positive	No recurrence
Case 4	60	Male	Ulcerated large lesion in left parotid region. Positron emission tomography-computed tomography scan showed neoplastic in nature	Carcinoma ex pleomorphic adenoma	T4aN2Mx	HER2/neu, CK7,EMA-Positive ER, PR-Negative	Radiation
Case 5	52	Male	Firm swelling in right parotid region FNAC- showed pleomorphic salivary adenoma	Polymorphous adenocarcinoma	T3NxMx	CK7, HER2/neu S100, vimentin-positive	Lost to follow-up

[Table/Fig-6]: Summary of all five cases of parotid gland malignancy.

DISCUSSION

Malignant salivary gland tumours, heterogeneous group of malignancies with diverse biological behaviours are rare, representing only 2 % of all head and neck malignancies. In addition to age, type of tumour, lymphovascular involvement, perineural invasion and lymph node metastasis appear to be an important prognostic factor in parotid gland malignancy [4]. The most common malignant salivary gland tumour is mucoepidermoid carcinoma followed by adenoid cystic carcinoma, adenocarcinoma, malignant mixed tumour, Acinic cell carcinoma, squamous cell carcinoma. Other variant represent less than 3% of all salivary gland malignancy [5].

Salivary duct carcinomas are rare aggressive, high grade salivary tumours (0.2-2%) affecting parotid gland, with high mortality upto 70% of cases, commonly found in elderly males and has a propensity for early lymph node involvement [6,7]. SDC consist of solid invasive nests with polygonal cells surrounding a comedo-necrosis. It is usually diagnosed histopathologically as it looks like ductal carcinoma of

peripheral palisading. Total one lymph node out of 13 was involved by neoplastic cells, being stage of T3N1Mx while patient was doing well postoperatively and closely followed for any recurrence. Immunohistochemically, p63, CK7 and HER2/neu were positive, Ki67 expression level were below 5%.

Carcinoma ex Pleomorphic Adenoma (CXPA) is an epithelial and/or myoepithelial malignancy developing from primary or recurrent Pleomorphic Adenoma (PA) of parotid mainly- 3.6% of all salivary gland tumour [11]. Tumour mostly arises in the background of a recurrent pleomorphic adenoma and can be composed of various histologic categories. The level of invasion, lymph node involvement, and local or distant metastasis are one of the most notable pathological parameters to determine the prognosis [11]. The primary management is surgical resection followed by radiotherapy [14].

Carcinoma ex pleomorphic adenoma having component of salivary duct carcinoma component, showed strong positivity for HER2

protein [15]. In the present case series a 60-year-old male presented with sudden increase of painful, firm to hard large fungating whitish growth revealed pleomorphic hyperchromatic epithelial cells arranged in glands with areas of pleomorphic adenoma with free margins morphologically. Total five lymph nodes showed tumour deposit with stage of T4aN2Mx. Immunohistochemical expression of HER2/neu was 3+ (positive) but ki67 expression was not that significant and underwent for radiation therapy. Polymorphous adenocarcinoma is a rare salivary gland neoplasm having indolent behaviour, primarily occurring the minor salivary glands but can rarely present in the major glands also particularly in parotid [16]. In PAC, the tumour cells show round or polygonal, small to medium sized, slightly increased nuclear-cytoplasmic ratio, round or oval vesicular nuclei and eosinophilic cytoplasm. It may show various cytoarchitectural patterns include solid sheets, cords, tubules, cribriform. PAC cells stain for vimentin, CK 7 and S-100 also. Ki67 proliferation index is usually less than 5%. Primary wide surgical excision was mainstay of treatment for PAC. The prognostic factors include site, angiolymphatic-invasion, perineural-invasion or bone invasion, necrosis, size, stage, papillary and pseudocribriform components, positive resection margins and the use of radiotherapy without surgery [17].

Here, 52-year-old male patient, on parotidectomy cystic tissue piece measuring 6x5x4 cm with a nodular area of 2.5 cm in maximum dimension noted having cut section of whitish, homogenous. Microscopically this cystic tumour cells arranged in branching tubular and focal papillary areas with eosinophilic secretion noted intraluminally. Resection margins are also free from invasion. As may be because of preoperative FNAC reported it as benign condition, no lymph node dissection was done and patient did not come for further treatment. Immunohistochemical expression of CK7 and HER2/neu were positive along with S100 and vimentin also but Ki67 proliferation index was less than 5%.

CONCLUSION(S)

Primary malignant salivary gland are rare malignancy and Salivary duct carcinoma, basal cell adenocarcinoma, carcinoma ex pleomorphic adenoma and polymorphous adenocarcinoma are one of the uncommon and rare malignancy occur in the parotid. Although sometime preoperative imaging or cytology findings may be beneficial but histopathological features along with immunohistochemical diagnosis of parotidectomy specimen are helpful for correct diagnosis as well as early treatment while emphasis on surgical resection margin, lymphovascular invasion,

lymph node metastasis and stage should be prioritised for disease free survival of the patient.

REFERENCES

- Venkatesh S, Srinivas T, Hariprasad S. Parotid gland tumors: 2-year prospective clinicopathological study. *Ann Maxillofac Surg*. 2019;9(1):103-09.
- Galdirs TM, Kappler M, Reich W, Eckert AW. Current aspects of salivary gland tumors-a systematic review of the literature. *GMS Interdiscip Plast Reconstr Surg DGPW*. 2019;8:Doc12.
- Chidananda-Murthy G, Chandran J. Salivary duct carcinoma of parotid gland: A rare tumor. *Indian J Surg Oncol*. 2019;10(2):313-17.
- Erovic BM, Shah MD, Bruch G, Johnston M, Kim J, O'Sullivan B, et al. Outcome analysis of 215 patients with parotid gland tumors: A retrospective cohort analysis. *J Otolaryngol Head Neck Surg*. 2015;44:55.
- Ho K, Lin H, Ann DK, Chu PG, Yen Y. An overview of the rare parotid gland cancer. *Head Neck Oncol*. 2011;3:40.
- Acharya S, Padmini S, Koneru A, Krishnapillai R. Intraoral salivary duct carcinoma: A case report and a brief review. *J Oral Maxillofac Pathol*. 2014;18(Suppl 1):S121-S127.
- Xie S, Yang H, Bredell M, Shen S, Yang H, Jin L, et al. Salivary duct carcinoma of the parotid gland: A case report and review of the literature. *Oncol Lett*. 2015;9(1):371-74.
- Hsu CC, Li WY, Chu PY. Salivary duct carcinoma of the supraglottis with a distinct presentation: A case report and literature review. *Medicine (Baltimore)*. 2018;97(11):e0095.
- Kantamani D, Bandaru SS, Miatech JL, Stagg MP. Salivary duct carcinoma: Case reports and brief review of the literature. *Case Rep Oncol Med*. 2021;2021:2672772.
- Ülkü ÇH, Öltulu P, Avunduk MC. High-grade basal cell adenocarcinoma arising from the parotid gland: A case report and review of the literature. *Turk Arch Otorhinolaryngol*. 2017;55(4):187-90.
- Antony J, Gopalan V, Smith RA, Lam AK. Carcinoma ex pleomorphic adenoma: A comprehensive review of clinical, pathological and molecular data. *Head Neck Pathol*. 2012;6(1):01-09.
- Wilson TC, Robinson RA. Basal cell adenocarcinoma and Basal cell adenoma of the salivary glands: A clinicopathological review of seventy tumors with comparison of morphologic features and growth control indices. *Head Neck Pathol*. 2015;9(2):205-13.
- Kanaujia SK, Singh A, Nautiyal S, Ashutosh K. Basal Cell Adenoma of Parotid Gland: Case Report and Review of Literature. *Indian J Otolaryngol Head Neck Surg*. 2015;67(4):430-33.
- Chooback N, Shen Y, Jones M, Kasaian K, Martin M, Ng T, et al. Carcinoma ex pleomorphic adenoma: case report and options for systemic therapy. *Curr Oncol*. 2017;24(3):e251-e254.
- Kadowaki S, Yatabe Y, Hirakawa H, Komori A, Kondoh C, Hasegawa Y, et al. Complete response to trastuzumab-based chemotherapy in a patient with human epidermal growth factor receptor-2-positive metastatic salivary duct carcinoma ex pleomorphic adenoma. *Case Rep Oncol*. 2013;6:450-55.
- Khosla D, Verma S, Gupta N, Punia RS, Kaur G, Pandey AK, et al. Polymorphous low-grade adenocarcinoma of the parotid in a teenager. *Iran J Otorhinolaryngol*. 2017;29(94):299-302.
- Vander Poorten V, Triantafyllou A, Skálová A, Stenman G, Bishop JA, Hauben E, et al. Polymorphous adenocarcinoma of the salivary glands: Reappraisal and update. *Eur Arch Otorhinolaryngol*. 2018;275(7):1681-95.

PARTICULARS OF CONTRIBUTORS:

- Senior Resident, Department of Pathology, Institute of Post Graduate Medical Education and Research, Kolkata, West Bengal, India.
- Demonstrator, Department of Pathology, Institute of Post Graduate Medical Education and Research, Kolkata, West Bengal, India.
- Senior Resident, Department of Pathology, Institute of Post Graduate Medical Education and Research, Kolkata, West Bengal, India.
- Assistant Professor, Department of Pathology, Institute of Post Graduate Medical Education and Research, Kolkata, West Bengal, India.

NAME, ADDRESS, E-MAIL ID OF THE CORRESPONDING AUTHOR:

Madhumita Mondal,
QR. No. C-12, 242, AJC Bose Road, Kolkata, West Bengal, India.
E-mail: rgkarmadhumita@gmail.com

AUTHOR DECLARATION:

- Financial or Other Competing Interests: None
- Was informed consent obtained from the subjects involved in the study? Yes
- For any images presented appropriate consent has been obtained from the subjects. Yes

PLAGIARISM CHECKING METHODS: [Jain H et al.]

- Plagiarism X-checker: Sep 15, 2022
- Manual Googling: Oct 08, 2022
- iThenticate Software: Oct 17, 2022 (11%)

ETYMOLOGY: Author Origin

Date of Submission: **Sep 13, 2022**
Date of Peer Review: **Sep 24, 2022**
Date of Acceptance: **Oct 18, 2022**
Date of Publishing: **Dec 01, 2022**