

An Unusual middle ear foreign body in a welder; our experience

Sabih Nadeem Qamar¹, Vandana Eswarappa², Arunachalam Iyer³

Abstract

Introduction: Welding accidents commonly present as burns, electrocution, skin injuries, and penetrating foreign body in the eyes, face, and neck. Ears are usually uninvolved, but the possibility of foreign bodies in the **external ear canal** or even in the middle ear should always be considered in non-resolving ear infections in welders.

Case Presentation: A thirty-year old welder presented with ear discomfort and swollen ear canal and was initially diagnosed and managed as otitis externa. But since it failed to resolve, he was extensively investigated and a metallic foreign body was identified in the middle ear, which was removed via endoscopic tympanotomy.

Conclusion: This case highlights the fact that small sharp foreign bodies can penetrate through the tympanic membrane and leave an almost invisible perforation that heals completely. But in suspicious or symptomatic cases further investigations such as an X-ray or Computed Tomography [CT] scan might be needed to confirm the diagnosis.

Keywords: Foreign ear, middle ear, endoscopic ear surgery.

¹ Department of Otolaryngology Head & Neck Surgery, Forth Valley Royal Hospital, Larbert, United Kingdom; ^{2,3} Department of Otolaryngology head & neck surgery, University Hospital Monklands, Airdrie, North Lanarkshire, United Kingdom.

Correspondence: Dr. Sabih Nadeem Qamar, Forth Valley Royal Hospital, Larbert, United Kingdom. Email: sabihnadeem@gmail.com

Cite this Case Report: Qamar, S.N., Eswarappa, V., Iyer, V. An Unusual middle ear foreign body in a welder; our experience. International Journal of Rawalpindi Medical College. 30 Jun. 2022; 1(1): 44-47.

Received December 15, 2021; accepted January 29, 2022; published online June 30, 2022

1. Introduction

Usually, foreign bodies in the ear occur in the external auditory canal in children and older people with hearing aids and it is very uncommon to get foreign bodies in the middle ear.¹ Industrial accident can cause foreign bodies to be lodged in the ear nose and throat.² The severity of the injury depends on the foreign body, underlying trauma, and delay in reaching the diagnosis.³

Welding accidents can range from superficial skin burns, electrocution, ultraviolet exposure, and toxic fumes inhalation to penetrating head and neck injuries resulting in foreign body penetrating eyes despite eye protection and are managed by the accidents & emergency and ophthalmology.^{3,4} There have been case reports of complex penetrating foreign bodies in difficult anatomical locations such as the Optic nerve head⁴, pre-vertebral muscles⁵, and Eustachian tube.⁶ The high velocity and small size of these projectile foreign bodies result in penetration of unusual tissue planes making it difficult to be identified on clinical examination resulting in delayed diagnosis and potentially serious complications.

Similarly, undiagnosed foreign bodies in the ear can lead to complications such as recurrent infections, perforations, hearing loss, facial nerve injury, and a lot of discomforts. It is important to identify the possibility of penetrating the middle ear foreign body from the clinical presentation for early identification

and management of such cases. This is the first unusual case report with a metallic foreign body in the middle ear with a healed tympanic membrane concealing the presence of a foreign body and has not been described in the literature before.

2. Case Presentation

A 30-year welder came to the emergency department with a complaint of sudden onset of otalgia while welding. There was no definite history of any trauma, foreign body in the ear, or previous ear infections. He had no history of vertigo, hearing loss, or bleeding from the ear at that time. On examination, the external auditory canal was swollen, and the limited view of the tympanic membrane appeared intact but congested in the posterior-superior quadrant. There was no evidence of any foreign body in the ear canal. He was treated for otitis externa with topical antibiotics. The patient was reviewed regularly in the subsequent three weeks and the ear canal was still mildly swollen with an intact tympanic membrane (Figure 1). As the patient still felt pain and discomfort and considering his occupation, a plain x-ray was done to check for any metallic foreign bodies in the external auditory canal. But surprisingly this showed a dense shadow in the middle ear highly suspicious of a foreign body (Figure 2). An urgent referral was made to the consultant otologist. At the otology consultation, although the tympanic membrane was intact on microscopy, due to strong suspicion of a foreign body in the middle ear, a CT scan of the temporal bone was done which showed a small foreign

body measuring around 1.2mm in the post aspect of the middle ear (Figure 3).

Under general anesthesia exploration of the middle ear was done using a zero-degree rigid endoscope via a trans-canal approach to elevate the tympano-meatal flap. The middle ear showed an intact ossicular chain and chorda tympani. There was a small black metallic foreign body inferior and posterior to the oval window (Figure 4). Crocodile forceps and Rosen needle were used to dislodge and remove the foreign body (Figure 5). The tympano-meatal flap was replaced and a silastic sheet was placed in the external auditory canal which was removed after two weeks.

The patient was followed up in the clinic after three months and was completely asymptomatic. His tympanic membrane was intact, the audiogram was normal, and he was discharged.

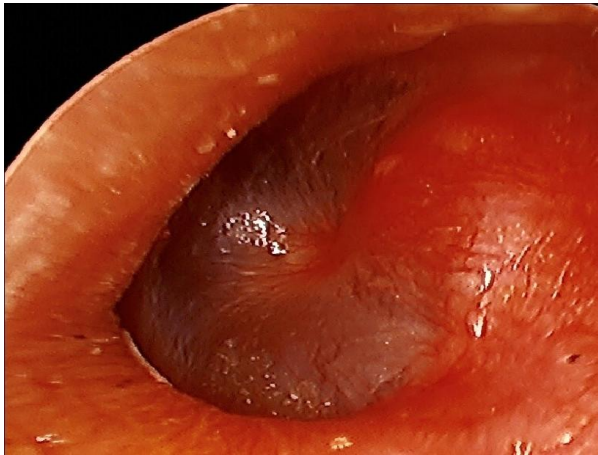


Figure 1: Normal-looking tympanic membrane

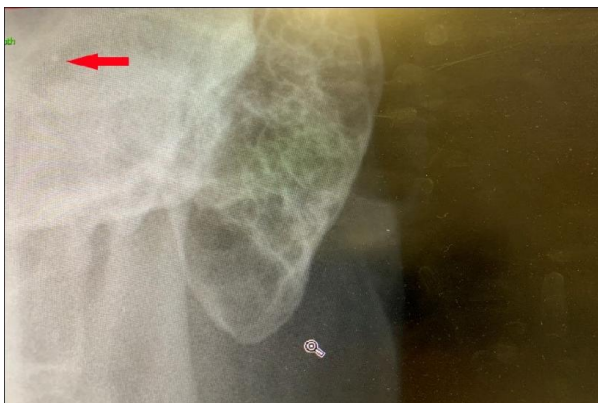


Figure 2: X-ray of mastoid showed suspected metal FB

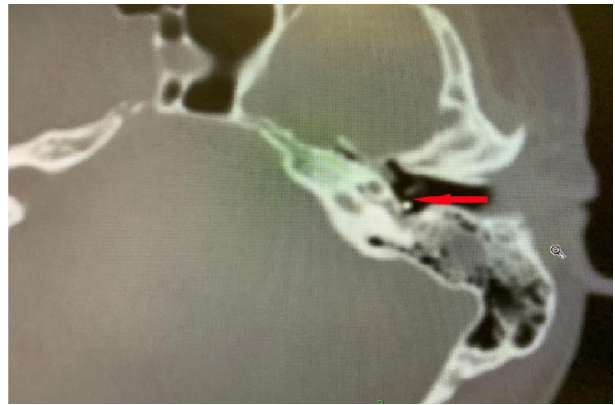

Figure 3: CT temporal bone showing metallic FB behind the tympanic membrane

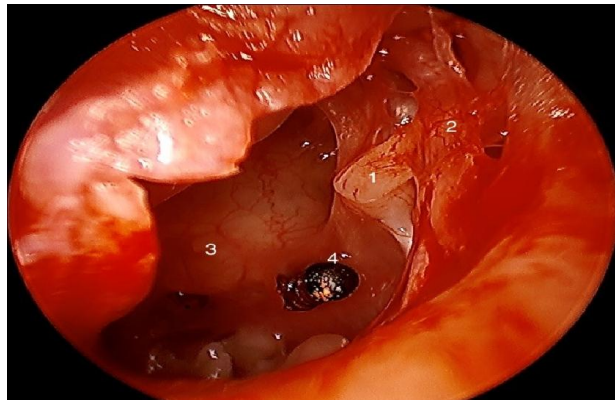


Figure 4: Middle ear showing 1) incus, 2) Chorda tympani nerve, 3) Promontory, 4) Metallic FB



Figure 5: Metal piece removed from the middle ear

3. Discussion

Foreign bodies are more common in the external ear canal than in the middle ear and are easily removed. The middle ear foreign bodies are complex and require removal under general anesthesia. Common ear canal foreign bodies include pea, bead, cotton bud, and dome of hearing aid in contrast to middle ear foreign bodies which usually result from penetrating metallic fragments damaging the tympanic membrane and middle ear Ossicles.⁷

Only a few publications describe metallic foreign bodies in the middle ear. These usually present with otitis media, perforation of the tympanic membrane, dizziness, or tinnitus. They can usually be missed on examination due to swelling of the external ear canal or post-traumatic healing of small perforations of the tympanic membrane. The possibility of a foreign body should always be considered in cases of non-resolving otitis media despite adequate medical therapy, especially in welders and metal workers. Alexander et al² in their study describe a significantly higher incidence of complications such as skin burns, eye injuries, and sensorineural deafness in welders as compared to non-welders.

Simons and Eibling⁸ described the unique case of retained slag in the context of a persistent tympanic membrane perforation from a welding injury that occurred 30 years ago. Pansonian et al⁹ reported transtympanic facial nerve injury in welders due to a hot spark falling into the ear canal. Similarly, facial paralysis and hearing loss are presented by Stage and Vinding¹⁰ due to metal spark perforation of the tympanic membrane. Purnell et al⁶ described a case of Eustachian tube foreign body resulting from a penetrating metallic fragment resulting in damage to the tympanic membrane. Eleftheriadou et al⁷ described an unusual case of hearing loss secondary to a penetrating middle ear foreign body. In all of these reported cases, the tympanic membrane showed a perforation, unlike our case where an almost invisible perforation occurred at the time of injury which could not be detected even with microscopic examination. This perforation later healed fully hiding the foreign body in the middle ear.

Endoscopic ear surgery is a safe day case procedure that can effectively aid in middle ear exploration and retrieval of foreign bodies with minimum morbidity. Endoscopic tympanotomy had the advantage of better

visualisation of difficult areas that are normally hidden from view such as sinus tympani and also avoids any external incisions. This technique can simultaneously address ossicular damage and repair the tympanic membrane. Endoscopic ear surgery reports no risks to the facial nerve or dead ear with the mentioned technique for such cases¹¹

In our case, the patient, fortunately, didn't have facial nerve injury or ossicular damage even though the foreign body was very close to the facial nerve. The main complaint was persistent ear discomfort with a normal-appearing tympanic membrane and the diagnosis could have been easily missed leading to further complications.

4. Conclusion

Welding accidents can rarely result in a foreign body penetrating the eardrum into the middle ear. A high degree of clinical suspicion and investigations including X-ray mastoids and CT scans helped to identify the exact reason for this patient's symptoms. Long-term complications can thus be avoided such as recurrent ear infections and perforation of the tympanic membrane. Minimally invasive trans-canal endoscopic ear surgery might be a suitable solution for such cases.

Key Points:

1. *Persistent aural symptoms in welders even with normal-looking tympanic membrane might require investigation with an X-ray or CT scan.*
2. *Delayed diagnosis can lead to problems such as perforations.*
3. *Endoscopic ear surgery is minimally invasive, aids better visualization of hidden areas, and leads to faster recovery in such cases.*

CONFLICTS OF INTEREST- None

Financial support: None to report.

Potential competing interests: None to report

Contributions:

S.N.Q, A.I- Conception of study

S.N.Q, V.E- Experimentation/Study conduction

V.E- Analysis/Interpretation/Discussion

S.N.Q- Manuscript Writing

A.I- Critical Review

S.N.Q, A.I- Facilitation and Material analysis

References

- [1] Lotterman S, Sohal M. Ear Foreign Body Removal. [Updated 2020 Mar 25]. In: StatPearls [Internet]. Treasure Island (FL): StatPearls Publishing; 2020
- [2] Alexander V, Sindhu KN, Zechariah P, Resu AV, Nair SR, Kattula D, et al. Occupational safety measures and morbidity among welders in Vellore, Southern India. *Int J Occup Environ Health*. 2016;22(4):300-306. DOI: 10.1080/10773525.2016.1228287
- [3] Lombardi DA, Pannala R, Sorock GS, Wellman H, Courtney TK, Verma S, et al. Welding related occupational eye injuries: a narrative analysis. *Inj Prev*. 2005;11(3):174-179. DOI: 10.1136/ip.2004.007088
- [4] Mehta A, Jain C, Anjum N, Virk RS. *BMJ Case Rep* 2020;13:e238443. DOI: 10.1136/bcr-2020-238443
- [5] Verma, R. K., & Panda, N. K. (2014). Metallic foreign body migrating into prevertebral muscles: how we did it?. *Oman medical journal*, 29(1), 64–66. DOI: <https://doi.org/10.5001/omj.2014.14>
- [6] Phillip R. Purnell, Adam Bender-Heine, Habib Zalzal, Abdul R. Tarabishy, Adam Cassis, "Eustachian Tube Foreign Body with Endoscopic-Assisted Surgical Removal", *Case Reports in Otolaryngology*, vol. 2019, Article ID 5236429, 4 pages, 2019. DOI: <https://doi.org/10.1155/2019/5236429>
- [7] Eleftheriadou A, Chalastras T, Kyrmizakis D, Sfetsos S, Dagalakis K, Kandiloros D. Metallic foreign body in middle ear: an unusual cause of hearing loss. *Head Face Med* 3, 23 (2007). DOI: <https://doi.org/10.1186/1746-160X-3-23>
- [8] Simons J, Eibling D. Tympanic Membrane Perforation and Retained Metal Slag after a Welding Injury. *Otolaryngol Head Neck Surg*. 2005;133:635–636. DOI: 10.1016/j.otohns.2005.05.007. [PubMed] [CrossRef]
- [9] Panosian M, Dutcher J. Transtympanic facial nerve injury in welders. *Occup Med*. 1994;44:99–101. DOI: 10.1093/occmed/44.2.99. [PubMed] [CrossRef] [Google Scholar]
- [10] Stage J, Vinding T. Metal spark perforation of the tympanic membrane with deafness and facial paralysis. *J Laryng Otol*. 1986;100:699–700. [PubMed] [Google Scholar]
- [11] Yiannakis, C., Sproat, R., & Iyer, A. (2018). Preliminary outcomes of endoscopic middle-ear surgery in 103 cases: A UK experience. *The Journal of Laryngology & Otology*, 132(6), 493-496. DOI: 10.1017/S0022215118000695