

# Fungal Species Detection in Onychomycosis by Culture and Direct Microscopy at Tertiary Care Hospital, Bahawalpur, Pakistan

Muhammad Wajid Khurshid Sipra<sup>1</sup>, Muhammad Abdul Raziq<sup>2</sup>, Zia Ullah<sup>3</sup>

<sup>1</sup> 1 Associate Professor, QAMC, Bahawalpur

<sup>3</sup> Assistant Professor, D.G.Khan Medical College,

<sup>2</sup> Assistant Professor, QAMC, Bahawalpur

Dera Ghazi Khan.

## Author's Contribution

<sup>1</sup> Conception of study

<sup>1,2,3</sup> Experimentation/Study conduction

<sup>1,2,3</sup> Analysis/Interpretation/Discussion

<sup>1,2,3</sup> Manuscript Writing

<sup>1</sup> Critical Review

<sup>1</sup> Facilitation and Material analysis

## Corresponding Author

Dr. Muhammad Wahid Khurshid Sipra,

Associate Professor,

Pathology,

Quaid-e-Azam Medical College,

Bahawalpur

Email: wajidkhurshid@gmail.com

## Article Processing

Received: 11/11/2021

Accepted: 12/05/2022

**Cite this Article:** Sipra, M.W.K., Raziq, M.A., Ullah, Z. Fungal Species Detection in Onychomycosis by Culture and Direct Microscopy at Tertiary Care Hospital, Bahawalpur, Pakistan. *Journal of Rawalpindi Medical College*. 30 Jun. 2022; 26(2): 261-265.

DOL: <https://doi.org/10.37939/jrmmc.v26i2.1836>

**Conflict of Interest:** Nil

**Funding Source:** Nil

**Access Online:**



## Abstract

**Objective:** This study aimed to detect the common organisms by culture and KOH mount microscopy of nail infections.

**Materials & Methods:** It was a cross-sectional study. Three hundred sixty clinically diagnosed cases were collected from 1<sup>st</sup> July 2018 to 31<sup>st</sup> July 2021 from Dermatology OPD of Bahawal Victoria Hospital and clinics. The samples were processed in the Microbiology section of the Pathology department of Quaid-e-Azam Medical College Bahawalpur, Pakistan.

The nail specimen was directly inoculated on SDA culture media and aerobically incubate at 25 °C to 30 °C for 3 to 4 weeks. The growth was identified in colony characteristics by using cotton blue stains. Whereas the nail is immersed in 20% KOH solution. The microscopic study revealed the hyphae or spores and that is considered a positive for the test.

**Result:** out of three hundred sixty cases the culture positivity was 56.94% of a specimen while KOH mount was positive in 60.83% of specimens and the combination of Culture with KOH was 66.67%.

**Conclusion:** The fungal culture and KOH mount microscopy combination are subtle laboratory methods for the detection of organisms causing onychomycosis. The species detection and precise usage of anti-mycological agents to prevent the complications raised public health considerably.

**Keywords:** KOH (Potassium hydroxide), Outpatient Department (OPD), Mycological culture, SDA (Sabouraud's dextrose agar).

## Introduction

Fungal nail infections are common, affecting mostly over 40 years of age and especially in the 20% elderly population. The Specified fungal treatment needs the precise isolation of fungal elements for the eradication of the disease.<sup>1</sup> Onychomycosis is a superficial cutaneous fungal infection that affected more than one nail. The identified causative agent as Dermatophytes (Trichophyton. Rubrum and Mentagrophytes) yeast or moulds (Fusarium, Chrysosporium, Aspergillus, etc.) on mycological culture. The Greek word “onyx” a nail and “mykes” known as onychomycosis a fungal infection.<sup>2</sup> it affects the toenail in 80% of cases which was identified on clinical grounds and confirmed on culture as Trichophyton rubrum a dermatophyte which is mostly occurring agents. It is counted as a public health problem and should be considered for decreasing complications like cellulitis in diabetics and peripheral vascular disease that affect the quality of life.<sup>3</sup> Onychomycosis is clinically remembered as superficial white onychomycosis (SWO), proximal subungual onychomycosis (PSO), distal and lateral subungual onychomycosis (DLSO), candidal onychomycosis (CO) and total dystrophic onychomycosis(TDO).<sup>4</sup> The alteration of immune and genetic makeup defects is the causation of onychomycosis. The large nail surface for invasion and slow nail growth was observed in adults. Keratin is a horn-like envelope that covers the dorsal aspect of the nail bed. The infection starts from the nail bed and progresses to dystrophic nature if not treated appropriately with anti-mycotic agents.<sup>5</sup> Onychomycosis is now considered no more a cosmetic problem The risk factors generally increased worldwide widely in fungal infection as in nail trauma, hyperhidrosis, compromised immunity, a metabolic disorder like diabetes, peripheral vascular diseases, poor hygiene and more water exposure of nails, especially in candidal onychomycosis.<sup>6</sup> Initially, onychomycosis starts as discoloration of the nail that may thicken, become rough and crumbly and separate its bed, and debris may accumulate under the nail. The thickening and dystrophy of nails result from the pressure erosions on the nail bed and Hyponychium.<sup>7</sup> In diabetes, the risk was observed 1.9 to 2.8 times higher in persons in the general population while in human immunodeficiency virus (HIV) infection that ranges from 15% to 40%.<sup>8</sup> The phenotypic characteristics of Onychomycosis varies with geographically and more dermatophytes cases are

reported in a temperate zone while Aspergillus and Fusarium species are prevalent in tropical and subtropical countries.<sup>9</sup> Middle age adults' dermatophytes species Trichophyton rubrum while non-dermatophytes like Candida albicans are mostly identified species of onychomycosis.<sup>10</sup> Clinically identified cases of onychomycosis required laboratory confirmation and on KOH mount microscopy of nails that labeled as fungal detection but the recognition of the fungus species whereas culture specifies the genus that needed the drug for curing the disease.<sup>11</sup> The physical limitations are severe pain and discomfort in the nail-affected area. The dermatophytes are the main etiological agents and Trichophyton rubrum are common isolating pathogen.<sup>12</sup>

**Objective:** The purpose of this study is to identify the causative agent, by mycological culture and with the combination of 20% KOH mount microscopy deceptive as the “gold standard” to diagnose onychomycosis. The appropriate drugs for a specified organism that cure the disease which limits the resistance against drugs.

## Materials and Methods

**Settings:** Clinical diagnosis of 360 patients of onychomycosis included a detailed history of trauma, occupation, sharing of common facilities, personal habits such as smoking and drinking, personal hygiene, hyperhidrosis, and different predisposing diseases reported at the dermatology outpatient department of Bahawal Victoria Hospital Bahawalpur, a tertiary care hospital and performed at Microbiology section of pathology department Quaid-e-Azam Medical College Bahawalpur were included in this study. Non-probability convenience sampling technique was applied. The study was carried out from 1<sup>st</sup> July 2018 to 31<sup>st</sup> July 2021.

**Inclusion Criteria:** The specimens of severely affected nails diagnosed with Onychomycosis were selected for processing in the study.<sup>13</sup>

**Exclusion Criteria:** Patients whose history of antifungal therapy were excluded from the study.<sup>13</sup>

The variable of the study was age groups, genders were included with more than one affected nail and KOH mount, and culture positivity diagnostic techniques were adapted.<sup>14</sup>

**Direct Microscopy:** The nail clipping specimen that immersed in 20% KOH and slightly warmed and examined under both low and high-power of microscopy. Fungal elements' presence may be

hyphae, spores, budding cells, and pseudo-hyphae were noted.

Mycological Culture: The detected fungal sample was placed on Sabouraud's dextrose agar and incubated at 25°C to 30°C. The growth with colony characteristics was observed periodically for 4 weeks follow-up and by using cotton blue reagent for the final identification of species.<sup>15</sup>

## Results

Out of three hundred sixty patients, the distribution of 200 cases was male while 160 was female (Figure 1). The study age ranged between 10 to 70 years. The positivity of fungal infection was reported at 54%, 30%, and 7% in 21 to 30-year age, 31 to 50 years, and above 50 years of age respectively (Figure 2).

Mycological culture and 20% KOH mount microscopy in combination showed positive results in 205 (56.94%), 219 (60.83%), and 240 (66.67%) patients respectively (Table 1).

The positive culture showed Dermatophytes in 116/205 (56.58%) specimens predominately *Trichophyton rubrum* while 89/205 (43.42%), were Non- Dermatophytes. among non-dermatophytes 49 specimens reveal yeast, predominately 45 *Candida albicans* while 40 specimens were fungi which includes *Fusarium* in 13 samples, *Chrysosporium* spp in 06 samples, *Aspergillus* in 05 samples, *Aspergillus nigar* in 05, *scytalidium* spp 03, *scopulariopsis* spp 02, *cladosporium* spp in 02 samples each, *cryptococcus* spp and Miscellaneous actinomycete spp in 02 samples (Table 2). In this study, *Trichophyton rubrum* was the higher most isolated organism while second was *Candida albicans*. The combination technique (mycological culture with KOH) positivity was 240 (66.67%).

This study showed that fungal culture with KOH in combination is considerably effective either in single laboratory methods for revealing onychomycosis.

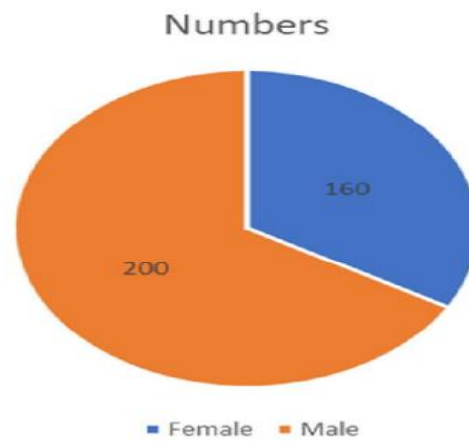
**Table 1: Descriptive Analysis of Diagnostic Methods in Comparison (n=360)**

Test	Positive	Negative
KOH	219(60.83%)	141(39.17%)
Culture	205(56.94%)	155 (43.06%)
KOH and Culture	240(66.67%)	120 (33.33%)

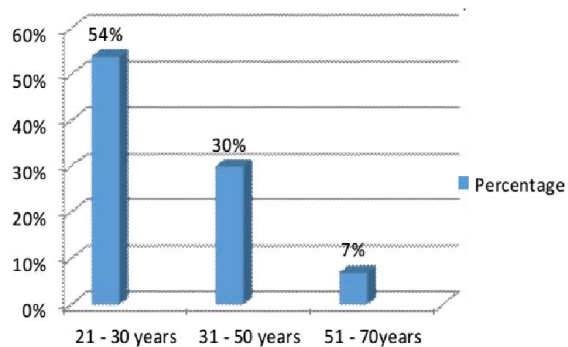
**Table 2: Isolated Organisms of Cultured Nails infections**

S.No	Organism	Number (%)
1	Dermatophyte	116 (56.58%)
	Trichophyton. Rubrum	80
	Trichophyton. Mentagrophytes	36

2 Non-Dermatophytes 89 (43.42%)	
a. Fungi	40
Fusarium	13
Chrysosporium	06
Aspergillus	05
Aspergillus niger	05
Scytalidium	03
Scopulariopsis	02
Cladosporium	02
Cryptococcus	02
b. Yeast	49
Candida albicans	45
Candida spp	04
c. Miscellaneous	02
Actinomycete	02



**Figure 1: Distribution of Gender**



**Figure 2: Distribution of Age affecting**

## Discussion

The fungal nail is a public health problem that is difficult to treat without proper isolation of causative organisms and laboratory investigation. It is not a cosmetic problem and the prevalence of the disease is rising worldwide.

The factors contributing to the etiology of onychomycosis that was nail trauma, diabetes mellitus, peripheral vascular disease, immune-compromised, contaminated swimming pools, footwear, and genetic alteration. The microscopy screening for the presence of fungus or not whereas mycological culture reveals the isolation of pathogens at the species level for the proper selection of drugs. The combination of KOH and Culture was better to reach the fungal diagnosis that helps eradicate the cosmetic problem

The finding of Shenoy M et al;<sup>16</sup> determined the KOH positivity was 53% and culture was 35%. That lower in consistence with our study results KOH was 60.83% and mycological culture was 56.94%. Our study concluded that KOH positivity was 60.83%, culture was positive in 56.94% of samples in lower concord with Agrawal A et al;<sup>17</sup> (KOH 89.23%, culture 84.62%). Moreover, our study revealed in a combination of KOH with culture was 66.67% and Dermatophytes was 56.58% is consistent (KOH and culture 65% and dermatophytes 57%) with Agrawal A et al.<sup>17</sup>

Our results were lower compared with other authors Alkhayat et al<sup>18</sup> that showed KOH was positive in 57% and culture in 41%. An author Weinberg et al<sup>19</sup> that evaluated known onychomycosis cases from different diagnostic tests and found, KOH of 80%, and culture of 59% are comparable in upper concordance with our findings. Another accurate result for the diagnosis of the suspected onychomycosis by Ahmad R et al<sup>20</sup> KOH in 59% and Culture in 40% is consistent with our study results was KOH 60.83% and mycological culture was 56.94%. The direct microscopy and fungal culture in combination by Wilsmann-Theis D et al<sup>21</sup> concluded that the sensitivity of culture was 53% very much consistent with our study that showed culture was revealed at 56.94%. An investigation of the techniques for the diagnosis of onychomycosis by Gianni C et al<sup>22</sup> found fungal culture was a positivity of 52.9%, showing a dermatophyte 50% and KOH positive in 59.3% cases is closely matched with our study that showed mycological culture positive in 56.94% and among them 56.58% dermatophyte, and KOH direct microscopic was revealed 60.83%. A study conducted by Lilly KK et al<sup>23</sup> compared the different Laboratory techniques and found mycological culture was 57.3% which is very much consistent with our study culture of 56.94% and KOH with culture combination 94.3% high in accordance with our study results was 66.67%. Jung MY et al<sup>24</sup> compared the different routine mycological diagnoses by using culture, and KOH for onychomycosis in nail clippings. In the study, it was

concluded that KOH was alone 55.9% positive results which were consistent with our study showed 60.83%. The KOH and culture showed 70% which was much more consistent with our study of 66.67. Our study is compared with the study of Lawry MA et al<sup>25</sup> et al who showed culture results of 32% positive was concluded by our study was 56.94% in highly consistent.

## Conclusion

1. A combination of fungal culture and KOH mount microscopy is a subtle laboratory method for the eradication of onychomycosis precisely.
2. The sensitivity of diagnosis that limits the complications and quality of public health considerably raised.
3. Dermatophytes are by far the commonest causal organisms.
4. The yeasts and non-dermatophyte moulds should be interpreted carefully in each individual case. In the majority, yeasts are likely to be a secondary infection and non-dermatophyte moulds to be saprophytic in previously damaged nails

**Recommendation:** Fungal culture is the gold standard and combination with KOH mount microscopy is a delicate laboratory method for onychomycosis diagnostic sensitivity. It is a routinely performed technique in pathology laboratory for improving the accuracy of diagnosis of onychomycosis.

**Limitation of Study:** Anti-mycotic susceptibility is the stephead for further projects.

## References

1. Barros M. E. S, Santos D. A. and Hamdan J. S. Evaluation of Susceptibility of Trichophyton mentagrophytes and Trichophyton rubrum clinical isolates to antifungal drugs using a modified CLSI microdilution method (M38-A). Journal of Medical Microbiology 2007, 56; 514–518. DOI 10.1099/jmm.0.46542-0
2. Kaur. R, Kashyap. B and Bhalla. P. Onychomycosis-epidemiology, diagnosis and management. Indian Journal of Medical Microbiology (2008); 26(2):108-16.
3. Roberts D. T, Taylor W. D. and Boyle J. Guidelines for treatment of onychomycosis. British Journal of Dermatology 2003; 148: 402–410.
4. Lone R, Showkat H. I, Bashir D, Khursheed S, Sarmast A. H. Clinico-Mycological Pattern of Onychomycosis. A single center one-year study in Kashmir-North India. European Journal of General Medicine 2013; 10(3):150-153.
5. Ahmed R, Kharal S.A, Durrani M.A, CHANG A.H, IQBAL.S.M, FAKHARUDDIN, et al. Comparison of KOH Mount & Fungal Culture in the Diagnosis of Onychomycosis. P J M H S, 2012 VOL, 6 (1) 143-48

6. Ahmed R, Kharal S.A, Durrani M.A, Sabir.M, Abid Hussain Chang. A.H, Fakharruddin, et al; Frequency of Candida in onychomycosis. *J Pak Med Assoc.* 2013; 63(3),350-353.
7. Rich P. Onychomycosis and tinea pedis in patient with diabetes. *J Am Acad Dermatol* 2000; 3:130-134. DOI: 10.1067/mjd.2000.110376
8. Westerberg D.P, Voyack M.J. Onychomycosis: Current Trends in Diagnosis and Treatment. *Indian Journal of Clinical Practice*, Vol. 25, No. 4, September 2014,309-319.
9. Ellabib M.S, Agaj M, Khalifa Z, and Kavanagh K. Yeasts of the genus Candida are the dominant cause of onychomycosis in Libyan women but not men: results of a 2-year surveillance study. *British Journal of Dermatology* 2002; 146: 1038–1041.
10. Zisova L, Chokoeva A, Sotiriou. E, Valtchev. V and D. and Gospodinov. D. Onychomycosis and children a multicenter study. *Acta Medica Bulgarica*, 2015, Vol. XLII: 23-33. doi:10.1515/amb-2015-0004.
11. Piraccini B.M and Alessandrini A. Onychomycosis: A Review. *J. Fungi* 2015, 1, 30-43 doi:10.3390/jof1010030
12. D'Hue Z, Perkins S.M, Billings S. D. GMS is superior to PAS for diagnosis of Onychomycosis. *Cutan Pathol* 2008; 35; 745-747. DOI: 10.1111 /) J600-0560.2007. 00890.x
13. Satpathi P, Achar A, Banerjee. D, Maiti. A, Sengupta. M. Mohata. A. Onychomycosis in Eastern India - study in a peripheral tertiary care Centre. *Journal of Pakistan Association of Dermatologists* 2013; 23 (1):14-19.
14. Bonifaz A, Rios-Yuil J.M, Arenas R, Araizaa.J, Fernándezb.R, Mercadillo-Pérez. P et al; Comparison of direct microscopy, culture and calcofluor white for the diagnosis of Onychomycosis. *Rev Iberoam Micol.* 2013; 30(2):109–111.
15. Ahmad M, Gupta S and Gupte S.A Clinico-mycological Study of Onychomycosis. *Egyptian Dermatology Online Journal*, June 2010; 6 (4):1-9. <http://www.edoj.org.eg>.
16. Shenoy M.M, Teerthanath.S, Karnaker V K, Girisha B.S, Krishna Prasad M. S, Pinto J. Comparison of potassium hydroxide mount and mycological culture with histopathologic examination using periodic acid –Schiff staining of nail clipping in the diagnosis of onychomycosis. *Indian J Dermatol Venereol Leprol* 2008; 74: 226-29.
17. Agrawal A, Shanker U, Goyal. A, Singh. P.K, Bhooshan. S and Pandey. D.N. Clinical and Microbiological study of Tinea unguium in a tertiary care Centre. *Int J Curr Microbiol App Sci* (2015) 4(4): 899-905.
18. Alkhatay H, Al-Sulaili N, O'Brien, E, McCuaig C, Watters K. The PAS Stain for Routine Diagnosis of Onychomycosis. *Bahrain Medical Bulletin* 2009; 31(2):1-7.
19. Weinberg J M, Koestenblat E K, Tutrone W D, Tishler H.R, Najarian. L. Comparison of diagnostic methods in the evaluation of onychomycosis. *J AM Acad Dermtol* 2003;49:193-7.
20. Ahmad. R, Kharal. SA, Durani. MA, Siddiqui. k J, Khurshid. W, Muhammad. A, et al. Comparison of different laboratory methods in the diagnosis of onychomycosis. *Ann Abbasi Shaheed Hosp.Karachi*, 2010;15(2):127-32.
21. Wilsmann-Theis D, Sareika F, Bieber T, Schmid-Wendtner. M-H, Wenzel. J. New reasons for histopathological nail-clipping examination in the diagnosis of onychomycosis. *J Eur Acad Dermatol Venereol.* 2011; 25(2):235. DOI: 10.1111/j.1468-3083.2010.03704.x
22. Gianni C, Morelli V, Cerri A, Greco. C, Rossini. P, Guiducci. A, et al. Usefulness of histological examination for the diagnosis of onychomycosis. *Dermatology* 2001; 202(4):283-8. DOI: 10.1159/000051659
23. Lilly KK, Koshnick RL, Grill JP, et al; Cost-effectiveness of diagnostic tests for toenail onychomycosis: a repeated-measure, single-blinded, cross-sectional evaluation of 7 diagnostic tests. *J Am Acad Dermatol.* 2006; 55(4): 620. DOI: 10.1016/j.jaad.2006.03.033
24. Jung MY, Shim JH, Lee JH, et al; Comparison of diagnostic methods for onychomycosis, and proposal of a diagnostic algorithm. *Clin Exp Dermatol.* 2015; 40(5):479-84. DOI: 10.1111/ced.12593.
25. Lawry MA, Haneke E, Strobeck K, et al; Methods for diagnosing onychomycosis: a comparative study and review of the literature. *Arch Dermatol.* 2000; 136(9):1112. DOI: 10.1001/archderm.136.9.1112