

## Status of the Sentinel Lymph Node in Patients with Endometrial Cancer Stage I-II

Irina Tripac<sup>1,2\*</sup>, Jean Calleja Agius<sup>3</sup>, Klejda Harasani<sup>4</sup>, Paul Kubelac<sup>5</sup>, Valentina Stratan<sup>1</sup>, Valeriu Tutuianu<sup>1</sup>, Victor Sitnic<sup>1</sup>, Aliona Dobrovolskaia<sup>2,6</sup>

<sup>1</sup>Institute of Oncology of Moldova

<sup>2</sup>Polyvalent Hospital Novamed

<sup>3</sup>University of Malta

<sup>4</sup>University of Medicine of Tirana, Albania

<sup>5</sup>Oncology Institute "Prof. Dr. Ion Chiricuta" Cluj-Napoca, Romania

<sup>6</sup>State University of Medicine and Pharmacy of Moldova "N. Testemitanu"

\*Corresponding author:

Irina Tripac, MD

Institute of Oncology of Moldova

E-mail: [i\\_jacovlev@yahoo.com](mailto:i_jacovlev@yahoo.com)

### Rezumat

#### *Statutul ganglionului santinelă la pacienții cu cancer endometrial în stadiul I-II*

Cancerul endometrial (CE) este cel mai frecvent cancer ginecologic din țările dezvoltate. În literatură, există date cu privire la valoarea terapeutică a limfadenectomiei sistematice, în timp ce este strict necesară evaluarea statusului ganglionilor limfatici pentru determinarea prognosticului și necesitatea tratamentului adjuvant. Având în vedere riscul scăzut de metastaze ganglionare în stadiul I-II al EC și riscurile chirurgicale intra- și postoperatorii semnificative la efectuarea unei limfadenectomii pelvine complete, abordarea chirurgicală la aceste paciente este controversată, variind de la evaluarea fără limfadenectomie până la efectuarea limfadenectomiei pelvine și aortice complete. Introducerea recentă a detectării ganglionului santinelă reprezintă calea intermediară între executarea și omiterea disecției ganglionare la paciențele cu CE. Într-adevăr, detectarea ganglionului santinelă a apărut rapid ca o alternativă la limfadenectomia completă pentru a reduce morbiditatea. În studiul nostru, discutăm rolul detectării ganglionului santinelă în managementul chirurgical al CE în stadiu incipient.

**Cuvinte cheie:** cancer endometrial, prognostic, depistarea ganglionului santinelă, disecția ganglionilor limfatici, metastazarea ganglionilor limfatici

Received: 14.09.2022

Accepted: 12.11.2022

## Abstract

Endometrial cancer (EC) is the most common gynecological cancer in developed countries. In literature, there are discordant data regarding the therapeutic value of systematic lymphadenectomy whereas the importance of lymph node status for determining prognosis and the need for adjuvant treatment is undoubted. Given the low risk of lymph node metastases in stage I-II of EC and the significant surgical and postoperative risks when performing a complete pelvic lymphadenectomy, the surgical approach in these patients is controversial, ranging from no nodal evaluation to comprehensive pelvic and aortic lymphadenectomy. The recent introduction of sentinel node detection represents the mid-way between the execution and omission of node dissection in EC patients. Indeed, the sentinel node mapping has rapidly emerged as an alternative to complete lymphadenectomy to reduce morbidity. In the present research, we discuss the role of sentinel node mapping in the surgical management of EC in early stage. Results of study on SLN in EC in early stages seem to be promising, but only a small series have been published so far.

**Key words:** endometrial cancer, prognosis, sentinel node detection, lymph node dissection, lymph node metastasis

## Introduction

Endometrial cancer (EC) is today the most common gynecologic neoplasm in developed countries, accounting for 60,050 new cases in the US in 2021, causing death in 10,470 cases (1). According to the statistical data provided by the Registry National Cancer Center in the Republic of Moldova, in 2021 the incidence of endometrial cancer was 420 cases, the mortality being 92 cases (2). According to statistical data, in the Republic of Moldova, over 77.0% of cases are diagnosed in the early stages (stages I-II), with a high rate of 5-year survival (1). As a result of a detailed analysis, we can observe that 5-year survival results vary within limits stage I and constitutes in stage IA – 91-95%, and in stage IB – 80-65% (1, 2). Survival at 5 years in stage II constituted 50.6% (5).

The increasing incidence of EC drives the need for early detection of this disease, but also of the indication of an adequate treatment, arising from the biological and molecular nature of CE. Surgery remains the key treatment method for CE today. The status of the lymph nodes is the most important prognostic factor for this condition. It has been shown that the lymph nodes

determine the risks of EC recurrence (1), and the results of the global rate of 5-year survival in nodal involvement pelvic or para-aortic lymphatics constitute 44-52% (1).

In the GOG-33 study, the surgical pathological characteristics of 621 patients with CE stage I. All patients underwent primary surgery in the volume of hysterectomy total abdominal, bilateral salpingo-oophorectomy, pelvic and paraaortic lymphadenectomy. The factors of multiple prognosis, especially grade and depth invasion, contributes to the occurrence of metastases in the pelvic and para-aortic lymph nodes (*Table 1*).

A series of retrospective studies indicate the important prognostic and therapeutic role of retroperitoneal staging (3), which does not coincide with the results of the prospective study which examined the role of hysterectomy with or without lymphadenectomy in early CE, which also showed an increase in the incidence of surgical complications without improving oncological results (4).

Therefore, the sentinel lymph node study (SNL), which is found between performing a standard lymphadenectomy and leaving the retroperitoneal lymph nodes without any morphological examination, is an acceptable

**Table 1.** The clinical-pathological factors of prognosis of metastases in the pelvic and para-aortic lymph nodes

Pelvic lymph nodes	Grade I	Grade 2	Grade 3
Endometrium	0%	3%	0%
Invasion < 50%	3%	5%	9%
Invasion 50%	0%	9%	4%
Invasion > 50%	11%	19%	34%

Para-aortic lymph nodes	Grade I	Grade 2	Grade 3
Endometrium	0%	3%	0%
Invasion < 50%	1%	4%	4%
Invasion 50%	5%	0%	0%
Invasion > 50%	6%	14%	23%

and very promising procedure, which has the efficacy of retroperitoneal lymphadenectomy in identifying patients with positive lymph nodes while minimizing the risk of surgical complications.

This is especially appropriate for female patients from the older age group or in patients with metabolic syndrome in whom the benefit of performing an actual lymphadenectomy has not yet been established (5).

Results of 2 retrospective multicenter studies presented by Eriksson et al. (6) and Ducie et al. (7), which compared systemic lymphadenectomy and removal GLS, have demonstrated safety, feasibility, accuracy and oncologic efficacy of the last procedure in both low-risk and high-risk EC patients.

A promising direction in the treatment of patients with CE is the determination of the "sentinel" lymph nodes (SLN), that is, the lymph nodes that are the first in the way of the lymphatic flow from the area affected by tumor and are the first to be affected by tumor cells which migrate with the lymphatic flow. According to the existing concept, if the sentinel lymph node is not affected by metastasis, then all other regional lymph nodes are intact (3).

Another direction to optimize the treatment of EC patients in clinical stage I currently consists of studying the prognostic parameters of lymph node metastasis in these patients. According to ESGO consensus data, ESMO, ESTRO (2014), indications for lymph dissection in the case of clinical stage I-II endometrial cancer are determined by the risk

assessed depending on the results of preoperative examination, including depth of invasion and degree of tumor differentiation. But this model has several limitations, especially in patients with intermediate risk of lymph node metastasis.

Adequate surgical staging is now recognized by most oncologists as the standard for differentiated moderate and weak CE treatment, as well as for adenocarcinoma with clear and serous cells.

However, for highly differentiated CE these recommendations remain the subject of discussion with great variability in the intraoperative evaluation of retroperitoneal lymph nodes. Some patients are not surgically staged at all, some are staged limited to the discretion of the surgeon, and surgical staging standards vary from institution to institution.

### Objective

The aim of the research was to study the possibility of the use of a pharmaceutical preparation (PF) for the determination of sentinel lymph nodes and for optimizing the prognosis of the risk of lymph node metastasis in patients with stage I endometrial cancer.

### Materials and Methods

The study included 15 patients with stage I endometrial cancer (mean age:  $57 \pm 9.8$  years) who received surgical treatment in the extirpation volume of the uterus with appendages with pelvic lymphadenectomy in the Surgical Gynecology Department of the NOVAMED Polyvalent Hospital. The diagnosis was histologically verified in all patients at the preoperative stage. The stage of the disease was determined according to the FIGO and TNM systems edition 7. Based on a comprehensive examination, all patients were subjected to a physical status assessment according to the ASA classification: patients with endometrial cancer belonged to class III according to the ASA, taking into account severe concomitant diseases, such as metabolic syndrome with severe obesity ( $BMI \geq 40$ ), mild controlled

hypertension, undercompensated diabetes. In all the patients, the sentinel lymph nodes were detected using the indigo carmine pharmaceutical preparation.

The study was carried out successively at the preoperative stage. The finished pharmaceutical preparation (PF) was injected into the cervix - in 4 points, at 3, 6, 9 and 12 o'clock of the conventional dial, the administered dose being 5 ml.

## Results

One of the important aspects in understanding the problem we are mapping SLN in RE patients is knowledge ways of lymph drainage and principles of metastasis. Anatomy of the lymphatic system of the uterus studied in the 19<sup>th</sup> century and the first half of the 20<sup>th</sup> century.

First, the corpses of women who died after childbirth due to fever were examined, and pus was used as an indicator during the autopsy. Later, various injection methods were developed, such as injection mercury (7-9). Many studies have been performed in newborns (10). Were visualized the following lymphatic pathways:

1. the superior paracervical tract (also called the external iliac, preurethral, or primary pedicle), which runs along the uterine artery and collects lymph to external iliac and obturator lymph nodes;
2. the inferior paracervical pathway (also called the posterior, hypogastric, or retrourethro-urethral leg), which passes along the uterine vein and collects lymph to the internal iliac and presacral lymph nodes;
3. a non-pelvic pathway that runs along the infundibulopelvic ligament to the para-aortic lymph nodes.

Some authors describe the 4<sup>th</sup> way, which passes through the round ligaments of the uterus and ends outside the small pelvis, in the femoral node (11).

Often lymphatic drainage from the cervix described separately from the uterus, although it has the same embryonic origin, and

described anastomoses between the upper and lower paracervical pathways in parametric tissue (7-9).

Historically, there have been disputes about the presence of LN in parametric tissue, although this has not been reported how many authors (11,12).

Some authors failed to render lower paracervical tract. One of the possible reasons lies in the fact that the lymph nodes can atrophy due to age (11). Knowledge of the uterine lymphatic system helps understand the surgical algorithm for determining SLN. There are 2 consecutive lymphatic pathways, associated with SLN: upper paracervical and lower paracervical. Upper paracervical the path is well known. LAE is performed in patients with EC (12-15).

Knowledge of these pathways are important for 2 reasons. First, with more the use of the concept of SLN in EC and failure from the LAE, an algorithm should be applied, including diagnosis of all pelvic tracts, not just the upper paracervical. Secondly, the appearance of isolated bathing para-aortic metastases, which, presumably positive, spread along the infundibulum ligaments, is an argument for identifying paraaortic SLN (16). Metastasis of tumor cells does not always occur along the inferior paracervical pathway, which continues to the paraaortic areas. In addition, pathologic ultrastaging has been shown to increase the incidence detection of micrometastases in patients with EC (17).

Further research is needed to determine the clinical significance of SLN detection and implementation of the LAE (18). Although the most commonly used SLN detection algorithm is not in promoting the need to identify these nodes along both pelvic lymphatic pathways, examination using this algorithm allows identify presacral SLN (19-20).

The adequacy of the injection, the site of injection and the substance injected are fundamental for the rate of detection of SLNs. A dedicated surgical team for a successful SNL mapping is required (21).

The most studied, simple and in demand the method of introducing an identifying agent

is injection into the cervix. In 2011, prospective multicenter cohort study in which, for the introduction of an identifying means this method was used. He is considered to be the most common and most used to determine the SLN with EC. In addition, the frequency of detection of SLN at injection of drugs into the cervix is higher than with introduction into the body of the uterus: 62-100% versus 73-95% responsibly. It seems to be a lack of consensus about the optimal injection site. Three are the injection sites for sentinel node mapping described: subserosal/myometrial; subendometrial peritumoral (hysteroscopic guided injection); the cervix. The lymphatic drainage is ambiguous and complex and this makes the EC ideal for lymphatic mapping. Along the obturator, internal iliac, external iliac, common iliac, caval, and aortic vessels as well as in the parametrium and presacral space is possible found potential at-risk lymph node basins (21).

According to current guidelines (NCCN, v. 2.2018) in the detection of SLN in EC, there are several key points.

Two major ways of uterus lymph-node drainage are described. The main one follows the uterine vessels through the parametrium (the one identified through cervical injection); the other follows the ovarian vessels to nodes located in the high para-aortic area. This path of lymphatic drainage is more effectively indicated by the uterine injection technique (21-24). The detection rates of the subserosal myometrial injection technique are around 45% (25). Altgassen et al. (2007) reported the highest detection rate (92%) described for subserosal injection with a new approach consisting of multiple subserosal injection sites (4 ventrally and 4 dorsally) (26). The positive results of the technique indicate that the detection rate increases with the number of injections. Hysteroscopic perilesional injections, although more challenging and demanding, guarantee a more accurate visualization of tumor lymphatic drainage of the lesion located in the fundus (27,28). Martinelli et al. (2017) recently reported a technique consisting in the peri-tumoral injection with ICG; the rate

of bilateral SNL detection was 89.5%. Interestingly, 47% mapped to the para-aortic nodes and 74.5% mapped to bilateral pelvic nodes (29). Hysteroscopic visualization of the endometrial cavity at low pressure is recommended to avoid tubal spillage. Gien et al. (2005) reported negative peritoneal washing for endometrial cells after hysteroscopy (30). A cervical injection of dye into the stroma and submucosa at 3 and 9 o'clock, as previously reported by the pioneer of SLN in EC (31), has the advantage to be easy and less time-consuming. It is associated with an excellent detection rate compared with uterine injection (31) but exposes the risk to ignore direct para-aortic drainage (31).

The analysis of patients with endometrial cancer by risk groups draws attention to the prevalence of low and intermediate risk among them, of 50% and 39%, respectively, that is, these are the patients in whom the usefulness of lymphadenectomy is questionable. In women from the low-risk group, adenocarcinomas predominated with an average degree of differentiation - 11 (55.0±11.41%) and low - 4 (30.0±10.51%) cases.

Regarding histopathological evaluation, the histological type of endometrial tumors was represented by endometrial adenocarcinoma (n = 15), predominating tumors with a moderate degree of differentiation in 61%. In this work, the degree of differentiation of endometrial cancer in different oncological risk groups was studied. In the patients from the group with increased oncological risk, adenocarcinomas with an average degree of differentiation predominated - 2 cases. In the intermediate risk group, adenocarcinomas predominated with a medium degree of differentiation - 8 and high - 2 cases. In the low-risk group, adenocarcinomas predominated with a medium degree of differentiation - 2 and high - 1 case. The use of PF staining in the pelvis and abdominal cavity in cases of endometrial cancer made it possible to identify sentinel lymph nodes (SLN) in 8 (97.2%) patients, 12 SLN being identified. At the same time, bilateral accumulation of PF in the case of intraoperative

detection was identified in 2 (33%) patients, unilateral accumulation in 12 (63.8%) patients, and in 1 patient SLNs were not detected, but in this one it a macroscopic metastatic lesion of the pelvic lymph nodes was detected. Most often, SLNs were located along the course of the internal iliac vessels – 12 (35.5%), along the course of the external iliac vessels – 2 (18.7%), along the course of the common iliac vessels – 1 (16.6%), and unique SLN were located in the area of the obturator fossa, bifurcation of the aorta and iliac arteries (*Fig. 1, 2*).

In patients with endometrial cancer, on postoperative histological examination of the removed tissues, metastases were detected in the SLN in all cases.

## Discussions

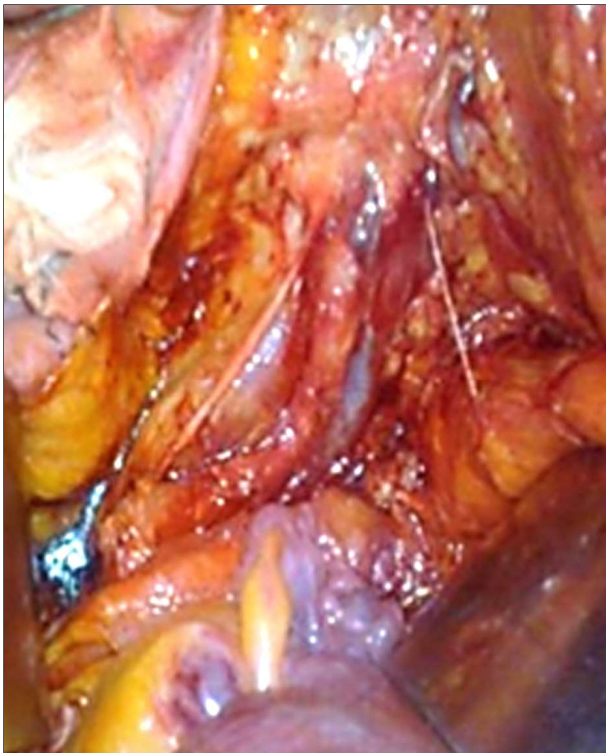
The importance of the topic is conditioned by the high level of morbidity due to endometrial cancer (EC), constituting a major problem with global impact on public health.

Endometrial cancer represents 4.8% of the cases of malignant tumors and ranks, worldwide, on the 6<sup>th</sup> place in the structure of the incidence of malignant tumors in women (32,33).

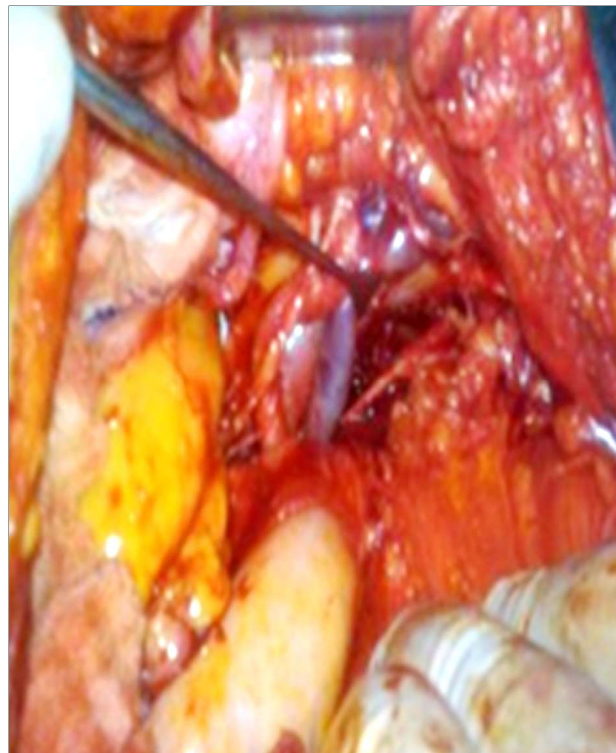In terms of increasing morbidity rate, EC consistently ranks 7<sup>th</sup> among malignant neoplasms in women (33). The constant increase in the incidence of CE is explained by the increase in the average life expectancy ("aging") among the population and the level of obesity (34-36). The incidence of this pathology is constantly increasing not only among elderly patients, but also among young women.

The treatment of endometrial cancer, especially stage I, which represents 70-75% of patients, remains a subject of debate. According to the current ESMO recommendations, for the management of patients with endometrial cancer, the treatment strategy is influenced by the results of risk stratification.

Regarding EC, a large number of prognostic factors are described, which creates certain difficulties in their application in clinical



**Figure 1.** SLN situated in external iliac vessels



**Figure 2.** SLN situated in common iliac vessels

practice. Most factors are morphological, and information about them is obtained on the basis of a standard histological examination. These data are used to assess the risk of lymph node metastases, to make predictions about the course of the disease and the life of EC patients, and to plan postoperative treatment.

In the last 30 years, debates regarding the assessment of regional lymph node status in EC clinical stage I have not stopped. This is explained by the fact that after the classification of surgical stages of UC was proposed in 1988, The International Federation of Obstetricians and Gynecologists (FIGO) did not determine what manipulations are necessary for this purpose. This would be one of the most important problems in the field of modern oncological gynecology, which is characterized by a stratification of specialist opinions: from the total denial of the need for lymphadenectomy to performing pelvic and lumbar lymphadenectomy in practically all patients.

There is conflicting evidence regarding the therapeutic benefit of lymphadenectomy in patients with EC stage I. Retrospective studies have shown a benefit for performing lymphadenectomy, which was not confirmed in 2 prospective studies. There seems to be a clear benefit of having a lymphadenectomy in clinically diagnosed metastatic or enlarged LN (40,41).

Probably, lymphadenectomy will also be useful in removing microscopic metastases, especially in combined pelvic and para-aortic PAE in high-risk EC lymphogenous metastasis (42,43).

SLN as anatomically constant located first lymph node on the path of inflammation outflow from organs was first given by E.A. Gould et al. in a work devoted to the study of lymphodissection treatment for tumors of the paraspinal gland. Results of the first practical studies R. M. Cabanas (1977) have been cited in this area in an article on the treatment of carcinoma of the genital member, where he formulated the concept of research SLN. When performing 100 lymphangiography was

the lymphatic center was identified, subsequently named sentry, through which the lymphatic drainage from the tumor. In the study it was demonstrated the absence of metastases in the lymphatic collectors in the absence of metastases in SLN and an increase in 5-year survival in patients without metastases in the SLN.

However, the ASTEC study by H. Kitchener et al., as well as the joint study by P. Benedetti et al. assessed the role of lymph node biopsy in EC predominantly low risk of lymphogenous metastasis and no benefit of pelvic LAE was shown (44,45).

In both studies, no differences in overall survival, but a large number of postoperative complications were identified, associated with LAE. Performing lymphadenectomy for all EC patients exposes a large proportion of patients with low risk of progression to an increased risk of surgical complications. The two most commonly used strategies in performing lymphadenectomy are assessment of risk factors for lymphogenous metastasis and assessment of sentinel lymphatic status node.

Determination of SLN may be equated to surgical staging in the absence of signs of LN damage according to preoperational examination or with the exclusion spread of the tumor outside the uterus.

Injection of the identifying agent into the cervix provides excellent penetration into the pelvic and para-aortic lymph nodes. Thus, this method of administration is the simplest and most popular SLN mapping method in EC.

Most often, radioactive labeled technetium-99m ( $^{99m}\text{Tc}$ ) colloid is injected into the cervix, while the detection rate of SLN remains quite high - from 80 to 100%; colored dyes are available in various forms (isosulfan blue 1% and methylene blue 1%, patented blue 2.5% sodium), however, they show a rather low SLN detection level (up to 60-70%). Not-long-established new dye - indocyanine green requires specialized infrared cameras for SLN localization.

Ultrastaging makes it possible to detect micro-metastasis, which is another significant

advantage of determining SLN for surgical staging.

Determination of SLN in EC is reliable, has a specificity of 100% and can be an additional factor in determining indications for adjuvant therapy, subject to an in-depth pathological and morphological study, which should be accompanied by an immunohistochemical microscopy and ultrastaging.

The sentinel lymph node detection method complements the current trends in modern invasive surgery of uterine cancer and has found wide application in clinical practice as a component of a comprehensive examination and treatment of patients with endometrial cancer. Further research in this direction will help to optimize the staging of regional tumor dissemination and, respectively, to choose an appropriate treatment (1,4). They will also allow to avoid extensive surgical interventions, limiting themselves only to the removal of sentinel lymph nodes in the early stages of the disease. And, on the contrary, to expand the volume of the intervention or to complete the treatment with chemotherapy or radiotherapy if lymph node metastases are detected outside the distant area by standard lymphadenectomy.

Thus, if we recognize that systemic lymphadenectomy has only a diagnostic role, then the detection of SLN for the identification of patients at high risk of EC recurrence and the planning of adjuvant therapy is sufficient.

This can be achieved with a lower incidence of surgical complications compared to lymphadenectomy and the long-term consequences of adjuvant therapy which is not always indicated.

## Conclusions

SLN mapping is increasingly used as an alternative to lymphadenectomy in surgical staging of women with endometrial carcinoma. The approach has gained significant acceptance and is applied in many centers. Currently, most authors recommend the use of existing protocols when addressing issues of SLN mapping. At the same time, recommendations

European Society of Gynaecological Oncology (ESGO) from 2018, SLN biopsy is still called experimental method, but numerous studies show that it is acceptable. SLN biopsy increases the incidence of micrometastases and isolated tumor cells in the lymph nodes, but the significance of these results is not yet fully understood.

## Conflicts of Interests

The authors declare no conflict of interests.

## References

- Colombo N, Preti E, Landoni F, Carinelli S, Colombo A, Marini C, et al. ESMO Guidelines Working Group. Endometrial cancer: ESMO Clinical Practice Guidelines for diagnosis, treatment and follow-up. *Ann Oncol*. 2013;24 Suppl 6: vi33-8.
- Papadia A, Gasparri ML, Buda A, Mueller MD. Sentinel lymph node mapping in endometrial cancer: comparison of fluorescence dye with traditional radiocolloid and blue. *J Cancer Res Clin Oncol*. 2017;143(10):2039-2048.
- Khoury-Collado F, St Clair C, Abu-Rustum NR. Sentinel lymph node mapping in endometrial cancer: an update. *Oncologist*. 2016;21(4):461-6.
- Ehrisman J, Secord AA, Berchuck A, Lee PS, Di Santo N, Lopez Acevedo M, et al. Performance of sentinel lymph node biopsy in high-risk endometrial cancer. *Gynecol Oncol Rep*. 2016;17:69-71.
- Levenback C. Update on sentinel lymph node biopsy in gynecologic cancers. *Gynecol Oncol* 2008;111(2 Suppl):S42-43.
- Khoury-Collado F, Glaser GE, Zivanovic O, Sonoda Y, Levine DA, Chi DS, et al. Improving sentinel lymph node detection rates in endometrial cancer: how many cases are needed? *Gynecol Oncol*. 2009;115(3):453-5.
- Frumovitz M, Bodurka DC, Broaddus RR, Coleman RL, Sood AK, Gershenson DM, et al. Lymphatic mapping and sentinel node biopsy in women with high-risk endometrial cancer. *Gynecol Oncol*. 2007;104(1): 100-3.
- Niikura H, Okamura C, Utsunomiya H, Yoshinaga K, Akahira J, Ito K, et al. Sentinel lymph node detection in patients with endometrial cancer. *Gynecol Oncol*. 2004;92(2):669-74.
- Creasman WT, Morrow CP, Bundy BN, Homesley HD, Graham JE, Heller PB. Surgical pathologic spread patterns of endometrial cancer. A Gynecol Oncol Group Study. *Cancer*. 1987;60(8 Suppl):2035-41.
- Lécuru F, Bats AS, Faraggi M. Sentinel node of endometrial cancer after hysteroscopic injection. *Gynecol Oncol* 2009;113:296-7; author reply 297.
- Altgassen C, Pagenstecher J, Hornung D, Diedrich K, Hornemann A. A new approach to label sentinel nodes in endometrial cancer. *Gynecol Oncol*. 2007;105(2):457-61.
- Biliatis I, Thomakos N, Koutroumpa I, Haidopoulos D, Sotiropoulou M, Antsaklis A, et al. Subserosal uterine injection of blue dye for the identification of the sentinel node in patients with endometrial cancer: a feasibility study. *Arch Gynecol Obstet*. 2017;296(3):565-570.
- Martinelli F, Ditto A, Bogani G, Signorelli M, Chiappa V, Lorusso D, et al. Laparoscopic Sentinel Node Mapping in Endometrial Cancer After Hysteroscopic Injection of Indocyanine Green. *J Minim Invasive Gynecol*. 2017;24(1):89-93.
- Gien LT, Kwon JS, Carey MS. Sentinel node mapping with isosulfan blue dye in endometrial cancer. *J Obstet Gynaecol Can* 2005;27:1107-12.
- Abu-Rustum NR, Khoury-Collado F, Gemignani ML. Techniques of sentinel lymph node identification for early-stage cervical and uterine cancer. *Gynecol Oncol* 2008;111:S44-50.
- Sahbai S, Taran FA, Fiz F, Staebler A, Becker S, Solomayer E, et al. Pericervical Injection of 99mTc-Nanocolloid Is Superior to Peritumoral



- Injection for Sentinel Lymph Node Detection of Endometrial Cancer in SPECT/CT. *Clin Nucl Med*. 2016;41(12):927-932.
17. Khoury-Collado F, Abu-Rustum NR. Lymphatic mapping in endometrial cancer: a literature review of current techniques and results. *Int J Gynecol Cancer* 2008;18:1163-8.
  18. Touhami O, Trinh XB, Gregoire J, Sebastianelli A, Renaud MC, Grondin K, et al. Predictors of non-sentinel lymph node (non-SLN) metastasis in patients with sentinel lymph node (SLN) metastasis in endometrial cancer. *Gynecol. Oncol.* 2015;138:41-45.
  19. [https://www.glowm.com/section\\_view/heading/TheEpidemiologyofEndometrialCancer/item/236](https://www.glowm.com/section_view/heading/TheEpidemiologyofEndometrialCancer/item/236).
  20. Ferlay J, Soerjomataram I, Dikshit R, Eser S, Mathers C, Rebelo M, et al. Cancer incidence and mortality worldwide: sources, methods and major patterns in GLOBOCAN. *Int J Cancer*. 2015;136(5):E359-86.
  21. Pike MC, Pearce CL, Wu AH. Prevention of cancers of the breast, endometrium and ovary. *Oncogene*. 2004;23(38):6379-91.
  22. Key TJ, Pike MC. The dose-effect relationship between 'unopposed' oestrogens and endometrial mitotic rate: its central role in explaining and predicting endometrial cancer risk. *Br J Cancer*. 1988;57(2):205-12.
  23. Pike MC, Peters RK, Cozen W, Probst-Hensch NM, Felix JC, Wan PC, et al. Estrogen-progestin replacement therapy and endometrial cancer. *J Natl Cancer Inst*. 1997;89(15):1110-6.
  24. Grady D, Gebretsadik T, Kerlikowske K, Ernster V, Petitti D. Hormone replacement therapy and endometrial cancer risk: a meta-analysis. *ObstetGynecol*. 1995;85(2):304-13.
  25. Liao C, Zhang D, Mungo C, Tompkins DA, Zeidan AM. Is diabetes mellitus associated with increased incidence and disease-specific mortality in endometrial cancer? A systematic review and meta-analysis of cohort studies. *GynecolOncol*. 2014;135(1):163-71.
  26. Morice P, Leary A, Creutzberg C, Abu-Rustum N, Darai E. Endometrial cancer. *Lancet*. 2016;387(10023):1094-108.
  27. Havrilesky LJ, Cragun JM, Calingaert B, Synan I, Alvarez Secord A, Soper JT, et al. Resection of lymph node metastases influences survival in stage IIIC endometrial cancer. *Gynecol Oncol*. 2005;99(3):689-95.
  28. Bristow RE, Zahurak ML, Alexander CJ, Zellars RC, Montz FJ. FIGO stage IIIC endometrial carcinoma: resection of macroscopic nodal disease and other determinants of survival. *Int J Gynecol Cancer*. 2003;13(5):664-72.
  29. Todo Y, Kato H, Kaneuchi M, Watari H, Takeda M, Sakuragi N. Survival effect of para-aortic lymphadenectomy in endometrial cancer (SEPAL study): a retrospective cohort analysis. *Lancet*. 2010;375(9721):1165-72.
  30. Chan JK, Cheung MK, Huh WK, Osann K, Husain A, Teng NN, et al. Therapeutic role of lymph node resection in endometrioid corpus cancer: a study of 12,333 patients. *Cancer*. 2006;107(8):1823-30.
  31. ASTEC study group, Kitchener H, Swart AM, Qian Q, Amos C, Parmar MKB. Efficacy of systematic pelvic lymphadenectomy in endometrial cancer (MRC ASTEC trial): a randomised study. *Lancet* 2009;373(9658):125-36.
  32. Benedetti P, Basile S, Maneschi F, Lissoni AA, Signorelli M, Scambia G, et al. Systematic pelvic lymphadenectomy vs. no lymphadenectomy in early-stage endometrial carcinoma: randomized clinical trial. *J Natl Cancer Inst* 2008;100(23):1707-16.