



Contents lists available at ScienceDirect

# AAACE Clinical Case Reports

journal homepage: [www.aaaceclinicalcasereports.com](http://www.aaaceclinicalcasereports.com)



## Case Report

# Methimazole Desensitization in a 4-Year-Old With Refractory Graves Disease

Rebecca Schneider Aguirre, MD, PhD <sup>1,2,\*</sup>, Ariba Khalid, BS <sup>1</sup>, Heba M. Ismail, MD <sup>1</sup>, Zeina Nabhan, MD <sup>1</sup>

<sup>1</sup> Department of Pediatrics, Division of Diabetes and Endocrinology

<sup>2</sup> Department of Medicine, Division of Diabetes, Endocrinology and Metabolism, Indiana University School of Medicine, Indianapolis, Indiana

### ARTICLE INFO

#### Article history:

Received 29 December 2020

Received in revised form

5 February 2021

Accepted 14 February 2021

Available online 20 February 2021

Previously submitted in abstract form for a poster presentation at the 2020 Pediatric Endocrine Society Annual Meeting, which was canceled due to the COVID19 pandemic.

#### Key words:

Graves disease  
methimazole  
allergy  
desensitization  
pediatrics

### ABSTRACT

**Objective:** To describe a 4-year-old girl with Graves disease and methimazole allergy who underwent desensitization, allowing continued methimazole use when other treatments were contraindicated.

**Methods:** We formulated a desensitization plan utilizing cetirizine and prednisone for a patient with previously diagnosed Graves disease who developed urticaria and arthralgias from methimazole. She was admitted for monitoring of rash, urticaria, angioedema, and anaphylaxis. Her methimazole dose was increased as tolerated and then titrated as an outpatient.

**Results:** A 4-year-old girl presented with a heart rate of 195 beats/minute, blood pressure of 145/108, and subsequent labs of undetectable thyroid stimulating hormone (TSH), free T4 5.8 ng/dL, thyroid peroxidase antibody 11.5 IU/ml, and TSH receptor antibody 39.03 IU/L, consistent with Graves disease. She developed urticaria and arthralgias after 2.5 weeks on methimazole, which resolved with drug cessation. Because of her age, the risks of radioactive iodine ablation and surgery were concerning; therefore, methimazole desensitization was attempted. Prednisone (1 mg/kg/day) and cetirizine (5 mg/day) were started prior to low-dose methimazole reintroduction and continued for 7 days. Methimazole was then gradually increased to a final dose of 15 mg daily (0.8 mg/kg/day). Free T4 normalized within a month (1.12 ng/dL), and her TSH normalized within 10 months (4.61 mIU/mL). Except for 2 possible breakthrough allergic responses that resolved with pulse steroids, she continues to tolerate methimazole.

**Conclusion:** We describe a case of methimazole desensitization. In this patient, pretreatment with prednisone, coupled with daily cetirizine, successfully induced methimazole tolerance when other treatment modalities were contraindicated.

© 2021 AAACE. Published by Elsevier Inc. This is an open access article under the CC BY-NC-ND license (<http://creativecommons.org/licenses/by-nc-nd/4.0/>).

## Introduction

The most common cause of hyperthyroidism in pediatrics, Graves disease, usually occurs after 11 years of age.<sup>1</sup> The incidence increases with age with an estimated 0.1 per 100 000 person-years rate in young children and a 3 per 100 000 person-years rate in adolescents.<sup>2</sup> Antithyroid drug therapy with thionamides is recommended as first-line treatment but is associated with rare, albeit significant, side effects. Methimazole is the preferred antithyroid

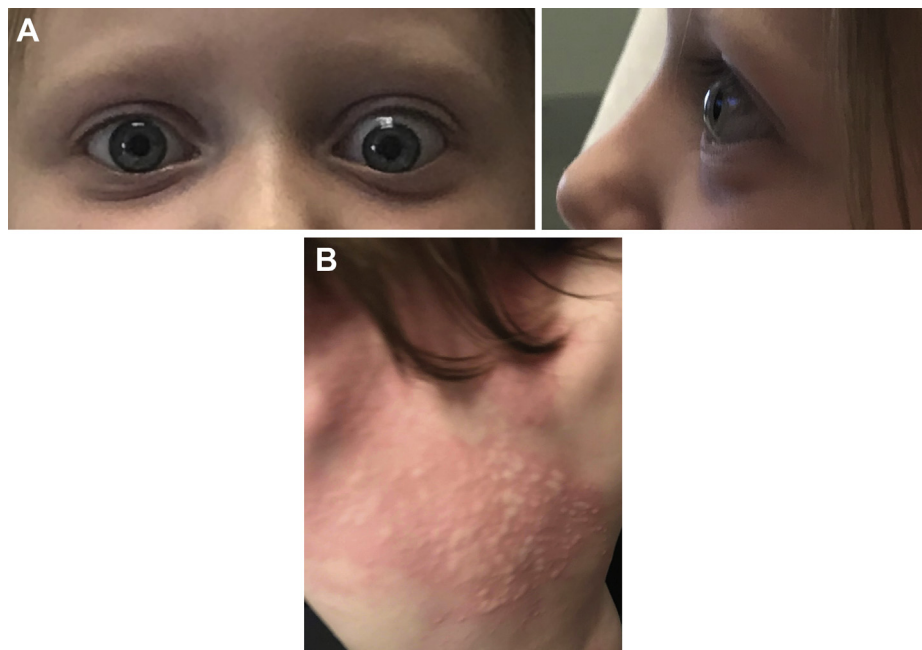
drug therapy because propylthiouracil has the risk of severe hepatotoxicity in children.<sup>3,4</sup> However, up to 19% of patients experience methimazole-associated side effects, mostly limited to minor allergic reactions, including urticarial skin rashes, arthralgias, and nausea. A very small percentage will develop diffuse arthralgia, agranulocytosis, and Stevens-Johnson syndrome.<sup>5</sup> In cases of adverse reaction, contraindication, patient/family preference, or clinician judgment, definitive therapy may be pursued.

Definitive therapy options include radioactive iodine ablation (RAI), sufficient to cause hypothyroidism, and total thyroidectomy. While RAI is overall safe and well-tolerated, it has risks, including possible long-term increased risks of thyroid cancers, breast cancers, and hyperparathyroidism from parathyroid hyperplasia.<sup>6,7</sup> Because RAI-related adverse events are associated with both dose and patient size, RAI is generally restricted to children older than 10 years or used at a low dose in children aged 5 to 10 years<sup>8</sup> and

*Abbreviations:* ATA, American Thyroid Association; PTU, propylthiouracil; RAI, radioactive iodine ablation; TSH, thyroid stimulating hormone.

\* Address correspondence and reprint requests to Rebecca Schneider Aguirre, Indiana University School of Medicine, 705 Riley Hospital Drive, Indianapolis, IN 46202.

E-mail address: [rsaguirr@iupui.edu](mailto:rsaguirr@iupui.edu) (R. Schneider Aguirre).



**Fig. 1.** Physical exam findings in the patient. A, Exophthalmos. B, Urticarial rash (throughout body, back shown here).

contraindicated in children less than 5 years old.<sup>9</sup> In these cases, thyroidectomy is an option. However, surgery carries the risk of hypocalcemia, hypoparathyroidism, and nerve injury resulting in vocal cord palsy, especially in younger children given their size and anatomy.<sup>2,6</sup> Best outcomes are obtained with high-volume centers. Furthermore, the patient should be euthyroid prior to surgery.<sup>9</sup>

We describe a case report of a 4-year old girl with Graves disease who developed an allergy to methimazole, in whom methimazole desensitization was successful.

### Case Report

A 4 year, 1-month-old girl presented with a heart rate in the 190s, respiratory rate in the 30s, blood pressure 145/108, agitation, diaphoresis, heat intolerance, tremor, arthralgia, and myalgia. Physical examination showed exophthalmos (Fig. 1 A), thyromegaly, and thyroid bruit. Her laboratory results showed undetectable thyroid stimulating hormone (TSH) (0.4–4.2 mIU/mL), total T3 464 ng/dL (82–179 ng/dL), free T4 > 6.0 ng/dL (0.6–1.5 ng/dL), TSH receptor antibody 39.0 IU/L (<=1.75 IU/L), thyroid peroxidase antibody 11.5 IU/mL (0.0–9.0 IU/mL), and thyroglobulin antibody <0.9 IU/mL (0.0–4.0). Graves disease was diagnosed. After 2.5 weeks on methimazole, she developed widespread urticaria and debilitating arthralgias (Fig. 1 B). Stopping methimazole resulted in symptom resolution, but with persistent thyrotoxicosis requiring hospital admission.

We considered definitive therapy. The clinical team was wary of RAI considering her young age. All agreed that surgery would be technically challenging given her age, small neck size, and hyperemic gland. Furthermore, the American Thyroid Association (ATA) guidelines recommend euthyroid state prior to thyroidectomy, not feasible in this case. We discussed using propylthiouracil, but were reluctant considering the relatively high risk of hepatotoxicity and cross-reactivity. Therefore, we consulted an allergist for methimazole desensitization (outlined in Fig. 2). This process was further guided by literature review of general desensitization guidelines and specifically for methimazole desensitization. A regimen using prednisone (1 mg/kg/day) and cetirizine (5 mg/day) during a 3-day elective hospitalization was adopted. These medications were

started 1 day prior to methimazole reintroduction. Prednisone was continued for 7 days and cetirizine indefinitely. Methimazole was restarted at 2.5 mg daily (0.15 mg/kg/d) and gradually increased to a final dose of 15 mg daily (0.8 mg/kg/day). The patient tolerated this regimen and was discharged.

After 2 weeks on methimazole and cetirizine, the patient redeveloped myalgias and arthralgias but without rash. Restarting 1 mg/kg/day prednisone (for 5 days) resolved her pain after 1 dose. Labs at that time showed leukocytes  $8.3 \times 10^3/\mu\text{L}$  (4.3–12.4/ $\mu\text{L}$ ) with 58% neutrophils, alkaline phosphatase 232 IU/L (133–309 IU/L), aspartate aminotransferase 30 IU/L (0–75 IU/L), alanine aminotransferase 18 IU/L (0–28 IU/L), creatine kinase 55 U/L (24–173 U/L), and free T4 1.12 ng/dL (0.95–1.75 ng/dL). As this seemed to be a methimazole side effect rather than myositis, and considering normal T4, methimazole was reduced to 0.4 mg/kg/d in hopes of better tolerance; however, she later required an increase to 0.8 mg/kg/d methimazole for hyperthyroidism control (free T4 of 3.31 ng/dL). After 10 months on 0.8 mg/kg/d methimazole, her thyroid labs normalized (TSH 4.61 mIU/mL [0.700–5.970] and free T4 1.19 ng/dL [0.85–1.75]) and the methimazole dose was reduced to 0.4 mg/kg/d. She experienced a widespread urticarial rash 11 months after desensitization (1 month after dose decrease) that was treated with 1 mg/kg/day prednisone for 5 days (plus rapid taper to avoid rebound allergy) while continuing methimazole, with subsequent resolution of her rash. It is unclear if methimazole caused her urticarial rash considering the recent dose decrease; the prednisone was used out of an abundance of caution. Parents wished to reconsider definitive therapy and remained hesitant to utilize RAI. They consulted with a surgeon, deciding to defer surgery in favor of continued medical management. She is now 5 years old and continues to tolerate her methimazole. Parents stopped the cetirizine after 17 months without allergy reappearance. Her medical course is outlined in Figure 3.

### Discussion

Here, we present a case of methimazole desensitization when RAI was contraindicated and thyroidectomy posed significant risks. According to the ATA hyperthyroidism guidelines,<sup>9</sup>

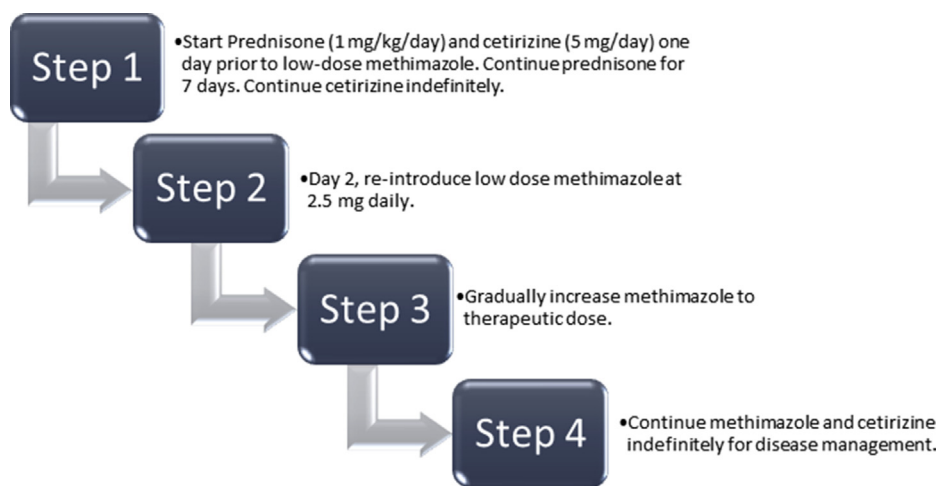


Fig. 2. Protocol for Methimazole Desensitization

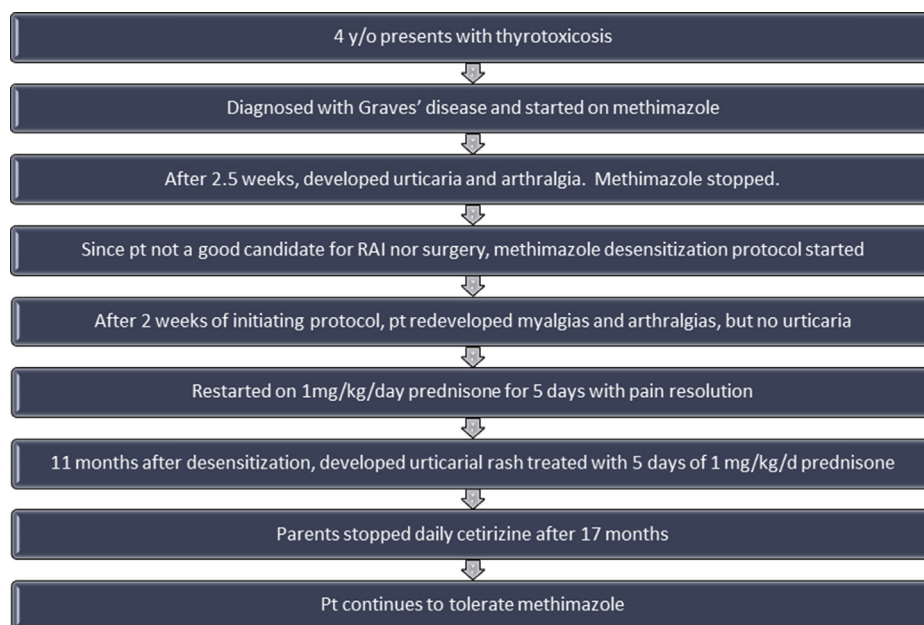


Fig. 3. Outline of patient's medical course.

methimazole is the preferred, first-line treatment option; propylthiouracil (PTU) is associated with an **unacceptable** risk of hepatotoxicity in children” (emphasis added). The ATA guidelines also recommend proceeding with definitive therapy if a significant adverse event occurs, because the risks of PTU are greater than the aforementioned options. However, definitive therapy options were also problematic.

RAI is contraindicated in children younger than 5 years, largely due to lack of strong data in children, especially of this age group.<sup>9</sup> One concern pertains to the theoretically increased risk of thyroid cancer, but few studies have addressed this. One study showed no increased risk in thyroid cancers or leukemias in 30+ years of follow-up after RAI, but it did not have adequate statistical power.<sup>10</sup> Another group analyzed nearly 19 000 individuals, showing a dose-dependent positive association with RAI and mortality from solid cancers.<sup>7</sup> However, this cohort was composed of adults, so the

pediatric risk is unknown. Based upon modeling, the radiation exposure is negatively correlated with body size; thus, the ATA recommends “avoiding” RAI in those less than age 5 while using RAI with caution in those aged 5 to 10 years. Naturally, extenuating circumstances could justify utilizing RAI in a child <5 years. In our case, we discussed the option of RAI, but were reluctant given her age and uncontrolled hyperthyroidism. Importantly, the patient's parents wished to avoid RAI.

Surgical complication rates are higher in children, more so in younger children, and ideally performed by a high-volume thyroid surgeon.<sup>6,9</sup> Moreover, the patient should be rendered euthyroid as the hyperemic, hyperthyroid gland poses even more risk.<sup>9</sup> This goal was not attainable in our patient. We considered utilizing PTU prior to surgery but were reluctant considering the hepatotoxicity risk. Therefore, after discussion with her parents, we pursued desensitization.

As outlined above, she had 2 reactions after restarting methimazole, 1 within weeks and 1 nearly a year later. She was treated with pulse-dosed prednisone out of caution both times. The first time, there was no rash but rather arthralgias and/or myalgias, which are not typical allergic reactions. Vasculitis or myositis were possibilities, although her normal creatine kinase was reassuring. We did not obtain a sedimentation rate nor antineutrophil cytoplasmic antibodies; however, in clinic, she was well-appearing and her symptoms resolved after 1 day of prednisone. Thus, the likelihood of vasculitis was low.

To our knowledge, reports of methimazole rechallenge following urticaria have been described twice. In 1 case,<sup>11</sup> an adolescent developed an anaphylactic reaction but was able to tolerate the methimazole with initial pretreatment of diphenhydramine. Another report<sup>12</sup> describes the slow reintroduction of low-dose methimazole in 9 patients with prior allergy after 6 to 21 years of PTU treatment; 8 patients had no allergic reactions after methimazole reintroduction. The youngest patient was 15 years old; thus, to our knowledge, this is the youngest reported case of successful desensitization. We chose a combination of pulse prednisone and a second-generation H1-antihistamine for the following reasons: (1) she would likely not tolerate prolonged methimazole up-titration due to thyrotoxicosis, (2) prednisone has the dual action of immunosuppression and mitigating hyperthyroidism, and (3) cetirizine is less sedating than diphenhydramine and can be continued indefinitely with minimal adverse effects. It appears that cetirizine facilitates overall tolerance while prednisone quells breakthrough reactions. We would only advocate for short-term burst prednisone use in this situation given the adverse effects of long-term therapy.

## Conclusion

Management of Graves disease in very young children with methimazole allergy is complicated by the limited treatment options. This case highlights that pretreatment with prednisone, coupled with daily cetirizine, and may be used to induce methimazole tolerance in a patient with an adverse reaction. This case is the first report of a patient who tolerated methimazole at therapeutic dose, after prednisone pretreatment and daily cetirizine. While replication of our results in more patients is needed to determine the general efficacy of our approach, we hope this case report provides a guide to physicians caring for patients in similar situations.

## Author Contributions

R.S.A. and A.K. contributed equally

## Disclosure

The authors have no multiplicity of interests to disclose.

## Acknowledgment

R.S.A. was supported by NIH/NIDDK grant 5T32-DK-065549-15. H.M.I. was supported by NIH/NCATS grants KL2TR002530 and UL1TR002529.

## References

- Williamson S, Greene SA. Incidence of thyrotoxicosis in childhood: a national population-based study in the UK and Ireland. *Clin Endocrinol (Oxf)*. 2010;72(3):358.
- Leger J, Carel JC. Hyperthyroidism in childhood: causes, when and how to treat. *J Clin Res Pediatr Endocrinol*. 2013;5(Suppl 1):50–56.
- Kahaly GJ, Bartalena L, Hegedus L, Leenhardt L, Poppe K, Pearce SH. European thyroid association guideline for the management of Graves' hyperthyroidism. *Eur Thyroid J*. 2018;7(4):167–186.
- Rivkees SA, Mattison DR. Ending propylthiouracil-induced liver failure in children. *N Engl J Med*. 2009;360(15):1574–1575.
- Rivkees SA, Stephenson K, Dinauer C. Adverse events associated with methimazole therapy of Graves' disease in children. *Int J Pediatr Endocrinol*. 2010;2010:176970.
- Breuer C, Tuggle C, Solomon D, Sosa JA. Pediatric thyroid disease: when is surgery necessary, and who should be operating on our children? *J Clin Res Pediatr Endocrinol*. 2013;5(Suppl 1):79–85.
- Kitahara CM, Berrington de Gonzalez A, Bouville A, et al. Association of radioactive iodine treatment with cancer mortality in patients with hyperthyroidism. *JAMA Int Med*. 2019;179(8):1034–1042.
- Rivkees SA, Sklar C, Freemark M. Clinical review 99: the management of Graves' disease in children, with special emphasis on radioiodine treatment. *J Clin Endocrinol Metab*. 1998;83(11):3767–3776.
- Ross DS, et al. 2016 American Thyroid Association guidelines for diagnosis and management of hyperthyroidism and other causes of thyrotoxicosis. *Thyroid*. 2016;26(10):1343–1421.
- Read Jr CH, Tansey MJ, Menda Y. A 36-year retrospective analysis of the efficacy and safety of radioactive iodine in treating young Graves' patients. *J Clin Endocrinol Metab*. 2004;89(9):4229–4233.
- Toderian AB, Lawson ML. Use of antihistamines after serious allergic reaction to methimazole in pediatric Graves' disease. *Pediatrics*. 2014;133(5):e1401–e1404.
- Kubota S. Successful re-administration of low-dose of methimazole (MMI) in Graves' disease patients who experienced allergic cutaneous reactions to MMI at initial treatment and had received long-term PTU. *Internal Med*. 2016;55(22):3235–3237.