


Sinonasal Squamous Cell Carcinoma Survival Outcomes Following Induction Chemotherapy vs Standard of Care Therapy

Alexander T. Murr, BS¹ , Nicholas R. Lenze, MD, MPH¹, Jared M. Weiss, MD², Juneko E. Grilley-Olson, MD², Shetal A. Patel, MD, PhD², Colette Shen, MD, PhD³, Bhisamjit S. Chera, MD³, Adam M. Zanation, MD¹, Brian D. Thorp, MD¹, and Siddharth H. Sheth, DO, MPH² 

Otolaryngology–
 Head and Neck Surgery
 2022, Vol. 167(5) 846–851
 © The Author(s) 2022



Reprints and permission:
sagepub.com/journalsPermissions.nav
 DOI: 10.1177/0194598221083097
<http://otojournal.org>



Abstract

Objective. To compare oncologic outcomes in sinonasal squamous cell carcinoma (SNSCC) treated with standard of care (SOC) definitive therapy, consisting of surgery or chemoradiotherapy, vs induction therapy followed by definitive therapy.

Study Design. Retrospective review.

Setting. Academic tertiary care hospital.

Methods. The medical records of patients with biopsy-proven SNSCC treated between 2000 and 2020 were reviewed for demographics, tumor characteristics, staging, treatment details, and oncologic outcomes. Patients were matched 1-to-1 by age, sex, and cancer stage according to treatment received. Time-to-event analyses were conducted.

Results. The analysis included 26 patients with locally advanced SNSCC who received either induction therapy (n = 13) or SOC (n = 13). Baseline demographics, Charlson Comorbidity Index, and median follow-up time were well balanced. Weekly cetuximab, carboplatin, and paclitaxel were the most common induction regimen utilized. Tolerance and safety to induction were excellent. Objective responses were observed in 11 of 13 patients receiving induction. No difference in disease-free survival was found between the induction and SOC groups at 1 or 3 years. However, when compared with SOC, induction therapy resulted in significant improvement in overall survival at 2 years (100% vs 65.3%, $P = .043$) and 3 years (100% vs 48.4%, $P = .016$) following completion of definitive therapy. Two patients in the SOC group developed metastatic disease, as compared with none in the induction group.

Conclusions. Induction therapy was safe and effective. When compared with SOC, induction therapy improved 3-year overall survival.

Keywords

sinonasal cancer, squamous cell carcinoma, induction chemotherapy, survival outcomes

Received October 7, 2021; accepted February 7, 2022.

Sinonasal squamous cell carcinomas (SNSCCs) are rare malignancies that represent about 3% of all head and neck cancers.^{1,2} Definitive therapy with either primary surgery or concurrent chemoradiation therapy is the standard of care (SOC).³⁻⁷ Despite improvements in both these modalities, the treatment of advanced locoregional disease results in high morbidity and a 5-year overall survival (OS) of 30%.^{2,4,8}

Sinonasal malignancies frequently develop in close proximity to important anatomic structures, posing significant challenges for treatment. For example, tumor involvement of the orbit necessitates orbital exenteration to ensure optimal surgical outcomes (R0 resection). Without randomized clinical trials investigating the efficacy of induction chemotherapy (IC) in SNSCC treatment, data supporting the use of IC in SNSCC are supported by retrospective studies and prospective studies involving mucosal head and neck cancers.⁹⁻¹⁵ Despite the limited data, IC can be utilized as a strategy to promote organ preservation.¹⁶⁻¹⁸ A review of 46 patients with untreated SNSCC found that a partial or complete tumor response to IC was associated with improved survival rates and the possibility for

¹Department of Otolaryngology–Head and Neck Surgery, The University of North Carolina at Chapel Hill, Chapel Hill, North Carolina, USA

²Division of Medical Oncology, Department of Medicine, The University of North Carolina at Chapel Hill, Chapel Hill, North Carolina, USA

³Department of Radiation Oncology, The University of North Carolina at Chapel Hill, Chapel Hill, North Carolina, USA

This article was presented at the AAO-HNSF 2021 Annual Meeting & OTO Experience; October 3-6, 2021; Los Angeles, California.

The content is solely the responsibility of the authors and does not necessarily represent the official views of the National Institutes of Health.

Corresponding Author:

Siddharth H. Sheth, DO, MPH, Division of Medical Oncology, Department of Medicine, The University of North Carolina at Chapel Hill, Houtp Building, Third Floor, 170 Manning Drive, CB 7305, Chapel Hill, NC 27599, USA.
 Email: Siddharth.Sheth@med.unc.edu

organ preservation.¹⁹ Furthermore, the use of IC may reduce the risk of metastasis from locoregionally advanced disease,²⁰ with tumor response to IC possibly aiding in prognostication.^{18,19,21-23} Additionally, a meta-analysis of 7 studies and 423 patients²⁴ found that stable or progressive disease following IC was associated with a poorer response to CRT.

We report our institutional experience with IC in the treatment of SNSCC. Using a 1:1 matched analysis, we compare oncologic outcomes in SNSCC treated with SOC definitive therapy vs IC followed by definitive therapy.

Materials and Methods

An Institutional Review Board–approved retrospective review was conducted with a prospective institutional database of patients treated for sinonasal and skull base tumors at the University of North Carolina. Between 2000 and 2020, 92 patients with biopsy-proven SNSCC were treated at our institution. Demographic information was reviewed, including comorbidities, tumor characteristics, staging, treatment details, and oncologic outcomes. Of the 92 patients, 13 were treated with IC. The IC cohort subsequently underwent 1:1 matching for TNM stage (American Joint Committee on Cancer), age, sex, and race with the 72 patients who received the SOC (control group) within the same period.

All patients had locoregionally advanced SNSCC (T3-T4) and were treated with curative intent. Of note, p16 status was not consistently available with tumor pathology and was thus not available for analysis. Definitive therapies permitted were either primary surgery followed by adjuvant therapy (if indicated) or concurrent chemoradiotherapy. IC response was assessed through radiographic comparison of images prior to and following termination of IC. Tumor response was defined according to RECIST (Response Evaluation Criteria in Solid Tumors). Time-to-event analyses were conducted with main outcome measures, including OS, disease-free survival (DFS), and response to IC. To account for the effect of coexisting diseases on mortality, we used the Charlson Comorbidity Index (CCI), which predicts 10-year survival based on 19 comorbid factors. Higher scores correlate with an increase in mortality.²⁵ The CCI has been validated when combined with age as a covariate²⁶ and can independently predict survival following surgery for head and neck cancer.²⁷ Additional post hoc analyses were performed with a median CCI score to assess the distribution of comorbidity burden: scores ≥ 4 were defined as low and >4 as high.

Statistical Analysis

Descriptive statistics were used to compare baseline characteristics in the control and induction groups. Bivariate testing methods consisted of a 2-sided *t* test, chi-square test, and Fisher exact test. Kaplan-Meier curves were used to compare OS and DFS in the induction vs control cohorts. Subset analyses based on Kaplan-Meier curves assessed the impact of comorbid conditions on OS and DFS by comparing high and low CCI scores. The log-rank test was used to compare survival curves. Statistical significance was set at $P < .05$ of all analyses. Stata 16.0 (StataCorp LP) was used for all analyses.

Table 1. Patient Baseline Characteristics.^a

	Control (n = 13)	Induction (n = 13)
Age, y	61 (11.7)	55 (10.2)
Sex		
Male	7	7
Female	6	6
Race		
White or Caucasian	11	9
White Hispanic or Latino	1	0
Black or African American	1	3
Asian or Pacific Islander	0	1
Disease status		
Primary	12	12
Recurrent	1	1
TNM		
T3N0M0	0	1
T4aN0M0	10	9
T4bN0M0	1	2
T4bN2M0	2	1
AJCC stage, 7th ed		
III	0	1
IVA	10	9
IVB	3	3
CCI score ^b	4.62 (1.66)	3.77 (1.48)
Smoking status		
Active smokers	9	8
Former smokers	0	1
Never smoker	4	4
Pack-years: all patients	18.5	14
Pack-years: only smokers	27.75	20.3

Abbreviations: AJCC, American Joint Committee on Cancer; CCI, Charlson Comorbidity Index.

^aValues are presented as mean (SD) or No.

^b $P = .183$.

Results

Patient Characteristics

Twenty-six patients were included and equally distributed in 2 groups: IC (n = 13) and control (n = 13). Of the 26 patients, 24 received treatment for their primary disease, while 2 were treated for recurrent disease (1 patient in each group). Baseline patient characteristics, including sex and cancer stage, were well matched in both treatment groups, with a majority having stage IVA or IVB disease. Mean (SD) age at the time of surgery was similar: 61 (11.7) years for the control group and 55 (10.2) for the IC group. The mean CCI scores were 4.62 (1.66) for the IC group and 3.77 (1.48) for the control group ($P = .183$), suggesting that comorbidity burden was not a major confounding variable (**Table 1**).

The most common reason for treatment with induction therapy was either organ preservation or improving the chance of obtaining negative surgical margins. Ten patients received multiagent systemic therapy consisting of carboplatin and paclitaxel with cetuximab (n = 8) or without (n = 2). Three

patients, all treated before 2010, received concurrent cisplatin (weekly or bolus) with radiation therapy as induction therapy prior to definitive surgery. Tolerance to induction therapy was excellent. Only 3 patients experienced grade 3 toxicities secondary to IC treatment: neutropenia, type 1 hypersensitivity reaction, and acute kidney injury resulting in dose reduction (Supplemental Table S1, available online). No grade 4 or 5 toxicities were observed. The objective response rate was 84.6%, with 1 complete response, 10 partial responses, 1 stable disease, and 1 progressive disease. Within the control group, 10 patients were treated with surgery while the remaining 3 patients received chemoradiotherapy for definitive therapy (Supplemental Table S2).

Survival Outcomes

Mean (SD) follow-up was 46.4 (48.0) months following definitive therapy, and median follow-up was 21 (49.2) and 26 (48.6) months for the IC and SOC groups, respectively. Treatment with IC did not improve DFS as compared with SOC at 1, 2, or 3 years (**Figure 1**); however, at the 2- and 3-year intervals, OS was significantly higher in patients treated with IC vs SOC. At 1 year, OS was 100% and 76.2% (95% CI, 42.7%-91.7%) for the IC and control groups ($P = .088$), respectively. At 2 years, OS was 100% and 65.3% (95% CI, 31.4%-85.5%) for the IC and control groups ($P = .043$). At 3 years, OS was 100% and 48.4% (95% CI, 18.7%-73.0%) for the IC and control groups ($P = .016$), respectively (**Figure 2**). Two patients from the IC group experienced locoregional recurrence, and 2 patients from the control group experienced metastatic recurrence.

Outcomes Based on CCI Score

Using CCI, we conducted subanalyses based on comorbidities calculated for each patient. In a global comparison of high vs low CCI scores, patients with higher CCI scores demonstrated worse OS outcomes at all follow-up intervals, independent of treatment group (Supplemental Figures S1-S5, available online). Similarly, DFS rates were significantly reduced for control patients with high vs low CCI scores at 1 year (37.5% vs 100%; 95% CI, 1.1%-80.8%; $P = .022$; **Figure 3A**). In this subanalysis, OS outcomes for the IC group could not be calculated due to the 100% survival rate at 3 years following treatment completion. Within the IC group, DFS rates were compared between patients with low and high CCI scores. Of note, patients receiving IC maintained comparable DFS rates at each interval, regardless of CCI score (**Figure 3B**).

Discussion

A growing body of literature suggests a role of induction therapy in SNSCC. Benefits include organ preservation, increasing surgical outcomes, and potential for improved OS, particularly in patients who experienced a favorable tumor response.¹⁹⁻²² Our findings in this single-institutional analysis indicate that induction therapy prior to definitive management of locally advanced SNSCC improved survival outcomes as compared with SOC. Induction therapy was well tolerated and safe and resulted in high responses rates (84.6%) with

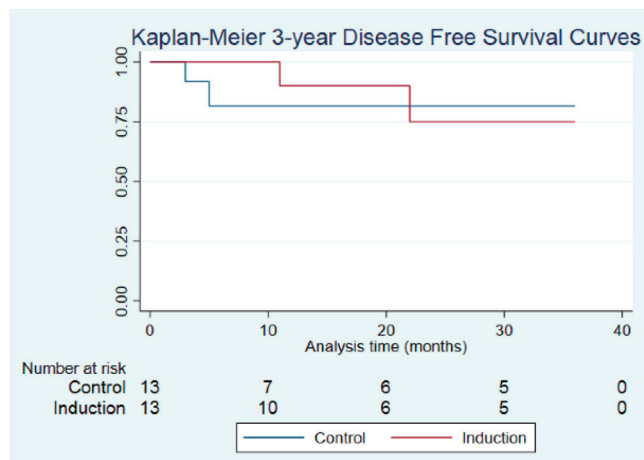


Figure 1. Comparison of disease-free survival in the control and induction chemotherapy (IC) groups: 1 year (90.0%, IC; 81.5%, control; $P = .428$), 2 years (75.0%, IC; 81.5%, control; $P = .857$), and 3 years (75.0%, IC; 81.5%, control; $P = .867$).

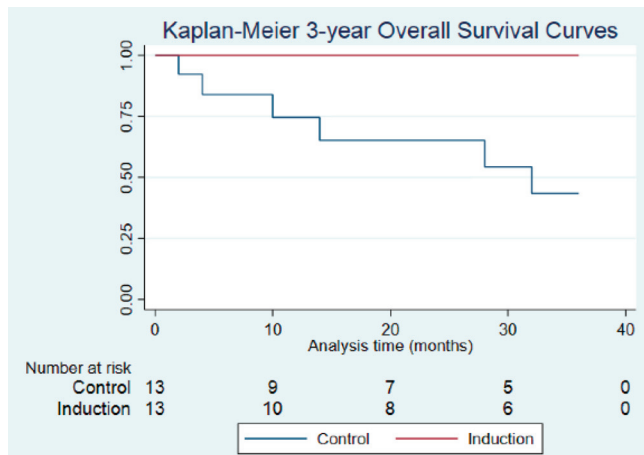


Figure 2. Comparison of overall survival in the control and induction chemotherapy (IC) groups: 1 year (100%, IC; 76.2%, control; $P = .088$), 2 years (100%, IC; 65.3%, control; $P = .043$), and 3 years (100%, IC; 48.4%, control; $P = .016$).

either a complete or partial response. Our high OS rates are similar to what has been observed in SNSCC studies in patients experiencing partial response or better to IC. Hanna et al reported 77% 2-year OS, and Ock et al reported 84.6% 3-year OS (**Table 2**).^{17,19}

In this study, we used the CCI to measure individual health based on a patient's comorbidities. While not statistically different, the IC cohort had a higher mean CCI score than the SOC cohort. Nevertheless, 3-year OS remains statistically improved in this group. This indicates that the combination of carboplatin, paclitaxel, and cetuximab is a well-tolerated induction regimen even in patients with multiple comorbidities.

While uncommon, recurrence patterns were different between the IC and control groups. Patients treated with IC had no occurrences of distant metastatic disease, while 2 patients in the control group ultimately progressed with

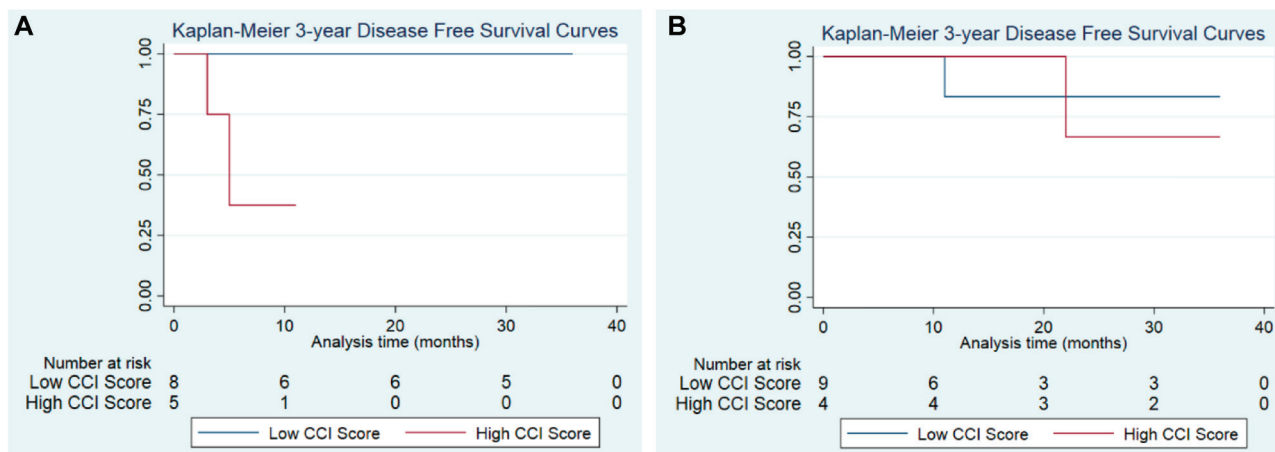


Figure 3. Disease-free survival by Charlson Comorbidity Index (CCI) scores. (A) For the induction chemotherapy group at 1 year, disease-free survival was observed at 83.3% for patients with low CCI scores and 100% for high CCI scores ($P = .414$). (B) For the control group, disease-free survival was as follows (by low vs high scores, respectively): 1 year, 100% vs 37.5% ($P = .022$); 2 years, 100% vs 37.5% ($P = .022$); and 3 years, 100% vs 37.5% ($P = .023$).

metastatic disease. A meta-analysis of head and neck squamous cell carcinoma showed that IC statistically reduced rates of distant metastasis but had no effect on locoregional control²⁸; this finding was also observed in our study. We hypothesize that this differential pattern of recurrence may have influenced OS outcomes.

Important limitations of this study must be acknowledged. First, the study analysis was retrospective and comprised patients treated over a 20-year period. During this time, there has been a shift in treatment practices, including the use of endoscopic approaches rather than an open approach. Second, given the rarity of the SNSCC, the sample size was small, and we were unable to include enough patients treated with IC to adequately power our study. Nevertheless, we report one of the largest cohorts with detailed IC regimens available in the current literature. In the modern era, induction therapy consists of only multiagent chemotherapy and not concurrent chemoradiation therapy. The small number of IC cases prompted our decision to include the 3 patients treated with neoadjuvant cisplatin and radiotherapy. All patients were treated prior to 2010, when this strategy was more commonly accepted. Additionally, no patients received induction therapy with a TPF regimen (5-fluorouracil, platinum, docetaxel). However, numerous studies have shown benefit from the Kies regimen IC in head and neck squamous cell carcinoma.⁹⁻¹² At our institution, the preference for the Kies regimen is driven by decreased toxicities, improved tolerability, and comparable efficacy to TPF.¹⁰ Third, the CCI tool is limited in its predictive capabilities and simply confers a crude estimate of 10-year mortality related to comorbid disease. Fourth, selection bias is inherently present in this study design, although we present findings on a clinically homogeneous high-risk population with >90% having T4 disease. These patients are most appropriate for consideration of IC.

At our institution and a growing number of academic centers, all patients with locally advanced SNSCC are evaluated

Table 2. Literature on Overall Survival Rates for Patients With SNSCC Treated With Induction Chemotherapy.

Study: induction regimen	No.	Overall survival, %
Abdelmeguid et al ³¹		2 y, 61.4; 3 y, 51.7
Platinum, taxane	41	
Platinum, taxane, 5FU	34	
Platinum, taxane, ifosfamide	26	
Platinum, taxane, cetuximab	8	
Platinum, 5FU	10	
Platinum, ifosfamide	2	
Platinum, gemcitabine	1	
Platinum, etoposide	1	
Ock et al ¹⁷		3 y, 84.6 (PR), 25 (SD/PD)
Docetaxel, 5FU, cisplatin	11	
Docetaxel, 5FU	8	
Docetaxel, cisplatin	2	
Noronha et al ³²		2 y, 41; 3 y, 35
Docetaxel, cisplatin	10	
Docetaxel, carboplatin	5	
Paclitaxel, cisplatin	15	
Paclitaxel, carboplatin	4	
Docetaxel, cisplatin, 5FU	7	
Farrell et al ³³		2 y, 64.1
Not specified		
Hanna et al ¹⁹		2 y, 67, 77 (PR)
Taxane, platinum	14	
Taxane, platinum, ifosfamide	14	
Taxane, platinum, 5FU	9	
Taxane, 5FU	9	

Abbreviations: 5FU, 5-fluorouracil; PD, progressive disease; PR, partial response; SD, stable disease; SNSCC, sinonasal squamous cell carcinoma.

for IC. Our threshold for treatment with IC is high, based on results from our data and as well as others (Table 2). Primary reasons to forgo IC include patient preference or existing

conditions such as severe peripheral neuropathy. While most patients are treated with surgery for their definitive therapy following induction therapy, the use of concurrent chemoradiation therapy in patients with a dramatic response to IC is gaining favor. In sinonasal undifferentiated carcinoma, patients with a response to IC received concurrent chemoradiation therapy while nonresponders received surgery.¹⁹ More data evaluating this topic are required and would benefit from a prospective clinical study.

Conclusion

The addition of induction therapy in the treatment of locoregionally invasive SNSCC shows promising survival outcomes. Our findings suggest that patients with high-risk disease who are treated with IC experience better OS outcomes as compared with similarly matched patients treated with the current SOC. This finding was consistent even among patients who had a higher burden of comorbidities. In light of these findings, we look to the results of a randomized clinical trial comparing IC vs non-IC treatment in SNSCC.^{29,30}

Author Contributions

Alexander T. Murr, data acquisition and interpretation, manuscript writing, review, and revisions; **Nicholas R. Lenze**, statistical analysis, manuscript review and revisions; **Jared M. Weiss**, data interpretation, manuscript review and revisions; **Juneko E. Grilley-Olson**, data interpretation, manuscript review and revisions; **Shetal A. Patel**, data interpretation, manuscript review and revisions; **Colette Shen**, data interpretation, manuscript review and revisions; **Bhishamjit S. Chera**, data interpretation, manuscript review and revisions; **Adam M. Zanation**, data acquisition, manuscript review and revisions; **Brian D. Thorp**, study design, data interpretation, manuscript review and revisions; **Siddharth H. Sheth**, study design, data interpretation, manuscript writing, review, and revisions.


Disclosures


Competing interests: None.

Sponsorships: None.

Funding source: The project described was supported in part by the Howard Holderness Medical Scholars Fellowship (awarded to Alexander T. Murr).

ORCID iDs

Alexander T. Murr  <https://orcid.org/0000-0003-1102-9477>

Siddharth H. Sheth  <https://orcid.org/0000-0002-1923-2309>

Supplemental Material

Additional supporting information is available in the online version of the article.

References

1. Paré A, Blanchard P, Rosellini S, et al. Outcomes of multimodal management for sinonasal squamous cell carcinoma. *J Craniomaxillofac Surg*. 2017;45(8):1124-1132. doi:10.1016/j.jcms.2017.05.006
2. Turner JH, Reh DD. Incidence and survival in patients with sinonasal cancer: a historical analysis of population-based data. *Head Neck*. 2012;34(6):877-885. doi:10.1002/hed.21830
3. Llorente JL, López F, Suárez C, Hermsen MA. Sinonasal carcinoma: clinical, pathological, genetic and therapeutic advances. *Nat Rev Clin Oncol*. 2014;11(8):460-472. doi:10.1038/nrclinonc.2014.97
4. Ansa B, Goodman M, Ward K, et al. Paranasal sinus squamous cell carcinoma incidence and survival based on Surveillance, Epidemiology, and End Results data, 1973 to 2009. *Cancer*. 2013;119(14):2602-2610. doi:10.1002/ncr.28108
5. Guntinas-Lichius O, Kreppel MP, Stuetzer H, Semrau R, Eckel HE, Mueller RP. Single modality and multimodality treatment of nasal and paranasal sinuses cancer: a single institution experience of 229 patients. *Eur J Surg Oncol*. 2007;33(2):222-228. doi:10.1016/j.ejso.2006.10.033
6. Michel J, Fakhry N, Mancini J, et al. Sinonasal squamous cell carcinomas: clinical outcomes and predictive factors. *Int J Oral Maxillofac Surg*. 2014;43(1):1-6. doi:10.1016/j.ijom.2013.07.741
7. Kang JH, Cho Pyeong SH, Kim J, et al. Treatment outcomes between concurrent chemoradiotherapy and combination of surgery, radiotherapy, and/or chemotherapy in stage III and IV maxillary sinus cancer: multi-institutional retrospective analysis. *J Oral Maxillofac Surg*. 2012;70(7):1717-1723. doi:10.1016/j.joms.2011.06.221
8. Robin TP, Jones BL, Gordon OM, et al. A comprehensive comparative analysis of treatment modalities for sinonasal malignancies. *Cancer*. 2017;123(16):3040-3049. doi:10.1002/ncr.30686
9. Kies MS, Holsinger FC, Lee JJ, et al. Induction chemotherapy and cetuximab for locally advanced squamous cell carcinoma of the head and neck: results from a phase II prospective trial. *J Clin Oncol*. 2010;28(1):8-14. doi:10.1200/JCO.2009.23.0425
10. Weiss J, Gilbert J, Deal AM, et al. Induction chemotherapy with carboplatin, nab-paclitaxel and cetuximab for at least N2b nodal status or surgically unresectable squamous cell carcinoma of the head and neck. *Oral Oncol*. 2018;84:46-51. doi:10.1016/j.oraloncology.2018.06.028
11. Bauman J, Langer C, Quon H, et al. Induction chemotherapy with cetuximab, carboplatin and paclitaxel for the treatment of locally advanced squamous cell carcinoma of the head and neck. *Exp Ther Med*. 2013;5(4):1247-1253. doi:10.3892/etm.2013.948
12. Shirasu H, Yokota T, Kawakami T, et al. Efficacy and feasibility of induction chemotherapy with paclitaxel, carboplatin and cetuximab for locally advanced unresectable head and neck cancer patients ineligible for combination treatment with docetaxel, cisplatin, and 5-fluorouracil. *Int J Clin Oncol*. 2020;25(11):1914-1920. doi:10.1007/s10147-020-01742-6
13. Oh JL, Vokes EE, Kies MS, et al. Induction chemotherapy followed by concomitant chemoradiotherapy in the treatment of locoregionally advanced nasopharyngeal cancer. *Ann Oncol*. 2003;14(4):564-569. doi:10.1093/annonc/mdg163
14. Ready NE, Rathore R, Johnson TT, et al. Weekly paclitaxel and carboplatin induction chemotherapy followed by concurrent chemoradiotherapy in locally advanced squamous cell carcinoma of the head and neck. *Am J Clin Oncol*. 2012;35(1):6-12. doi:10.1097/COC.0b013e3182019ee3
15. Zhong LP, Zhang CP, Ren GX, et al. Randomized phase III trial of induction chemotherapy with docetaxel, cisplatin, and fluorouracil followed by surgery versus up-front surgery in locally

- advanced resectable oral squamous cell carcinoma. *J Clin Oncol*. 2013;31(6):744-751. doi:10.1200/JCO.2012.43.8820
16. Chen NX, Chen L, Wang JL, et al. A clinical study of multimodal treatment for orbital organ preservation in locally advanced squamous cell carcinoma of the nasal cavity and paranasal sinus. *Jpn J Clin Oncol*. 2016;46(8):727-734. doi:10.1093/jjco/hyw064
 17. Ock CY, Keam B, Kim TM, et al. Induction chemotherapy in head and neck squamous cell carcinoma of the paranasal sinus and nasal cavity: a role in organ preservation. *Korean J Intern Med*. 2016;31(3):570-578. doi:10.3904/kjim.2015.020
 18. Björk-Eriksson T, Mercke C, Petruson B, Ekholm S. Potential impact on tumor control and organ preservation with cisplatin and 5-fluorouracil for patients with advanced tumors of the paranasal sinuses and nasal fossa: a prospective pilot study. *Cancer*. 1992;70(11):2615-2620. doi:10.1002/1097-0142(19921201)70:11<2615::AID-CNCR2820701108>3.0.CO;2-G
 19. Hanna EY, Cardenas AD, DeMonte F, et al. Induction chemotherapy for advanced squamous cell carcinoma of the paranasal sinuses. *Arch Otolaryngol Head Neck Surg*. 2011;137(1):78-81. doi:10.1001/archoto.2010.231
 20. Bossi P, Saba NF, Vermorken JB, et al. The role of systemic therapy in the management of sinonasal cancer: a critical review. *Cancer Treat Rev*. 2015;41(10):836-843. doi:10.1016/j.ctrv.2015.07.004
 21. Kim GE, Chang SK, Lee SW, et al. Neoadjuvant chemotherapy and radiation for inoperable carcinoma of the maxillary antrum: a matched-control study. *Am J Clin Oncol Cancer Clin Trials*. 2000;23(3):301-308. doi:10.1097/00000421-200006000-00020
 22. Lee MM, Vokes EE, Rosen A, Witt ME, Weichselbaum RR, Haraf DJ. Multimodality therapy in advanced paranasal sinus carcinoma: superior long-term results. *Cancer J Sci Am*. 1999;5(4):219-223.
 23. Hirakawa H, Hanai N, Ozawa T, et al. Prognostic impact of pathological response to neoadjuvant chemotherapy followed by definitive surgery in sinonasal squamous cell carcinoma. *Head Neck*. 2016;38(S1):E1305-E1311. doi:10.1002/hed.24217
 24. Kiong KL, de Souza NN, Sultana R, Iyer NG. Meta-analysis of induction chemotherapy as a selection marker for chemoradiation in the head and neck. *Laryngoscope*. 2018;128(7):1594-1601. doi:10.1002/lary.27011
 25. Charlson ME, Pompei P, Ales KL, MacKenzie CR. A new method of classifying prognostic comorbidity in longitudinal studies: development and validation. *J Chronic Dis*. 1987;40(5):373-383. doi:10.1016/0021-9681(87)90171-8
 26. Charlson M, Szatrowski TP, Peterson J, Gold J. Validation of a combined comorbidity index. *J Clin Epidemiol*. 1994;47(11):1245-1251. doi:10.1016/0895-4356(94)90129-5
 27. Singh B, Bhaya M, Stern J, et al. Validation of the Charlson Comorbidity Index in patients with head and neck cancer: a multi-institutional study. *Laryngoscope*. 1997;107(11, pt 1):1469-1475. doi:10.1097/00005537-199711000-00009
 28. Ma J, Liu Y, Huang XL, et al. Induction chemotherapy decreases the rate of distant metastasis in patients with head and neck squamous cell carcinoma but does not improve survival or locoregional control: a meta-analysis. *Oral Oncol*. 2012;48(11):1076-1084. doi:10.1016/j.oraloncology.2012.06.014
 29. ClinicalTrials.gov. Chemotherapy before surgery and radiation therapy or surgery and radiation therapy alone in treating patients with nasal and paranasal sinus cancer that can be removed by surgery. Accessed September 13, 2021. <https://clinicaltrials.gov/ct2/show/NCT03493425>
 30. ClinicalTrials.gov. Docetaxel, cisplatin and fluorouracil in treating patients with previously untreated stage II-IV nasal cavity and paranasal sinus cancer. Accessed September 14, 2021. <https://clinicaltrials.gov/ct2/show/NCT00707473?term=squamous+cell+carcinoma+induction+chemotherapy&cond=Sinonasal+Carcinoma&draw=2&rank=1>
 31. Abdelmeguid AS, Teeramatwanich W, Roberts DB, et al. Neoadjuvant chemotherapy for locoregionally advanced squamous cell carcinoma of the paranasal sinuses. *Cancer*. 2021;127:1788-1795.
 32. Noronha V, Patil VM, Joshi A, et al. Induction chemotherapy in technically unresectable locally advanced carcinoma of maxillary sinus. *Chemother Res Pract*. Published online May 11, 2014. doi:10.1155/2014/487872
 33. Farrell NF, Mace JC, Detwiller KY, et al. Predictors of survival outcomes in sinonasal squamous cell carcinoma: an analysis of the National Cancer Database. *Int Forum Allergy Rhinol*. 2021;11:1001-1011.