




Available online at  
**ScienceDirect**  
[www.sciencedirect.com](http://www.sciencedirect.com)

Elsevier Masson France  
**EM|consulte**  
[www.em-consulte.com/en](http://www.em-consulte.com/en)



## Case Report

# Osteoma of the mandibular condyle: a rare case report and review of the literature

M. Ostrofsky, J.A. Morkel, F. Titinchi \*

Department of Maxillo-Facial and Oral Surgery, Faculty of Dentistry and WHO Collaborating Centre, University of the Western Cape, Cape Town, South Africa

### ARTICLE INFO

*Historique de l'article :*  
 Received 30 September 2018  
 Accepted 20 January 2019  
 Available online 25 January 2019

*Keywords:*  
 Osteoma  
 Mandible condyle  
 Condylectomy  
 TMJ reconstruction

### ABSTRACT

**Introduction:** Osteoma is a rare slow-growing benign neoplasm which is often asymptomatic and composed of mature bone. Only 21 cases were previously reported in the mandibular condyle.  
**Observation:** A 60 year old male presented with gross asymmetry of the lower jaw and reduced function. He mentioned that he was involved in an accident to the head about 16 years ago. Upon examination, it was noticed that the chin deviated to the left with some discomfort during function. Computed tomography revealed a radiopaque mass medial to the left condylar pole. The lesion was gradually increasing in size and in close proximity to the middle cranial fossa. A condylectomy was performed using a pre-auricular approach. A diagnosis of osteoma was confirmed histopathologically. The defect was reconstructed with stock TMJ prostheses.  
**Discussion:** Osteomas affecting the condyle have significant functional implications and should be considered when deviation of the mandible is present.

© 2019 Elsevier Masson SAS. All rights reserved.

## 1. Introduction

Osteoma is a benign osteogenic neoplasm characterized by proliferation of compact or cancellous bone. Osteoma of the jaws may arise as polypoidal or sessiloid mass arising from periosteum called periosteal osteoma. They may also be located in the medullary bone (endosteum) and labelled central osteoma [1].

The pathogenesis of osteomas are unknown, but they are mostly referred to as developmental anomalies, true neoplasms or reactive lesions triggered by trauma, muscle traction or infection [2]. We present a rare case in the mandibular condyle in close proximity to the middle cranial fossa and its management. Due to the retrospective nature of this case report, no ethics approval was required and signed informed consent was obtained from patient. No identifiable photos of the patient are presented.

## 2. Observation

A 60 year old male presented with a main complaint of limited movement of the jaws and gross asymmetry as well as lack of function of his teeth accompanied by some discomfort. The patient has noticed that a few years previously that he started developing an asymmetry of the lower jaw with the chin being deviated to the left.

He mentioned that there was history of trauma to the right side of his lower jaw about 16 years previously. The situation had now become far worse and he was unable to function correctly and was aware of some discomfort in the right Temporomandibular joint (TMJ) as well as the presence of crepitus.

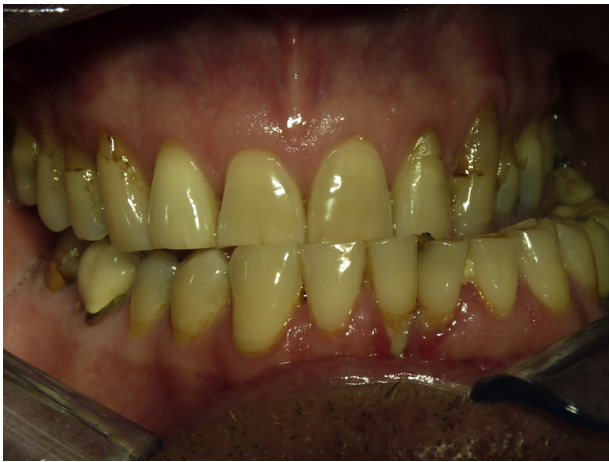Upon extra-oral examination, it was obvious that there is deviation of the lower jaw to the left side. Upon opening, the patient deviated to the left while there was limited movement on the right TMJ.

Intra-orally, the patient was fully dentate and had a gross cross-bite on the left side. A deviation of the dental midlines by 15 mm to the left side was also noted (Fig. 1).

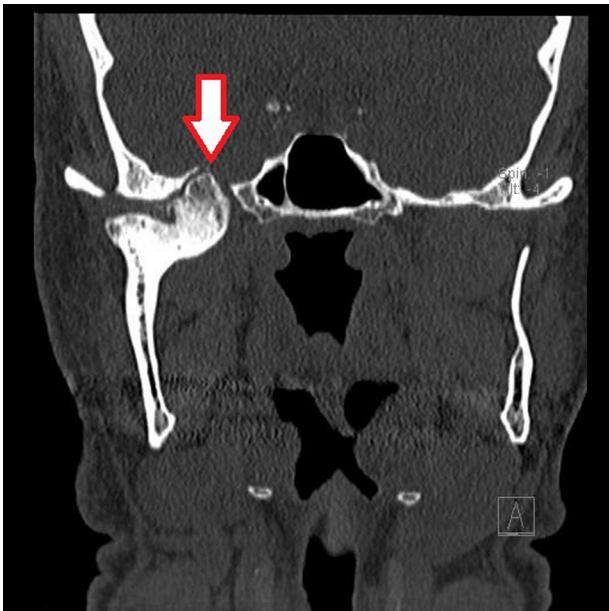
A CT scan demonstrated that there was a radiopaque lesion approximately 3 × 2 cm medial to and attached to the right mandibular condyle (Fig. 2). The right condyle was also positioned out of the glenoid fossa and near the eminence. The left mandibular condyle was also not in the fossa (Fig. 3). The lesion was well

\* Corresponding author at: Department of Maxillo-Facial and Oral Surgery, Faculty of Dentistry and WHO Collaborating Centre, University of the Western Cape, Private Bag X1, Tygerberg Oral Health Center, Francie-Van Zijl Drive, Cape Town, 7505 South Africa

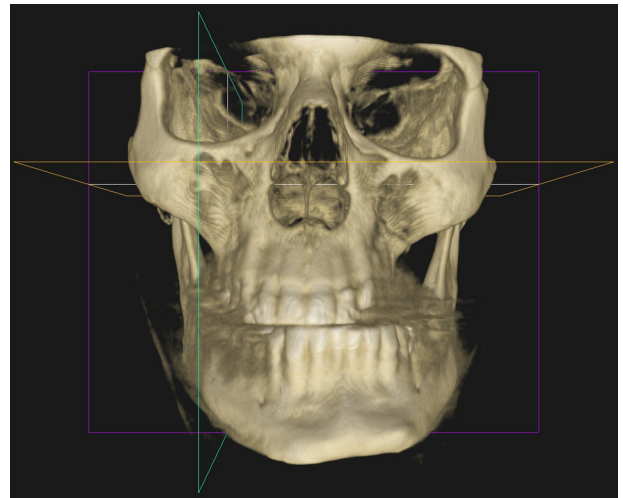
E-mail address: [ftitinchi@uwc.ac.za](mailto:ftitinchi@uwc.ac.za) (F. Titinchi).



**Fig. 1.** Intra-oral view showing left posterior cross-bite and deviation of mandibular midline to left.



**Fig. 2.** Coronal CT showing tumour on right condyle head extending medially and in close proximity to the middle cranial fossa.



**Fig. 3.** Frontal 3D CT reconstruction of the patient showing deviation of the mandible to the left side.

performed prior, hence there was a slight possibility that the lesion was more sinister in nature. Secondly, due to the size of the lesion and its medial extent, the largest possible access to the lesion was required to aid in resection of the tumour and possible intra-operative haemorrhage control. Lastly, this wider surgical access would also assist with the insertion of TMJ prosthesis following resection of the tumour.

The condyle head was then isolated and resected. Some difficulty was experienced when removing the condyle with the tumour and there was peruse haemorrhage from the lateral pterygoid muscle which was managed with haemostatic agents.

The specimen was sent for histopathological examination to establish a definitive diagnosis. The histological report indicated the lesion consisting of spongy osseous hard tissue contained in a capsule composed of coarse fibrous connective tissue (Fig. 4). Based on these histopathological features, a diagnosis of central osteoma was made.

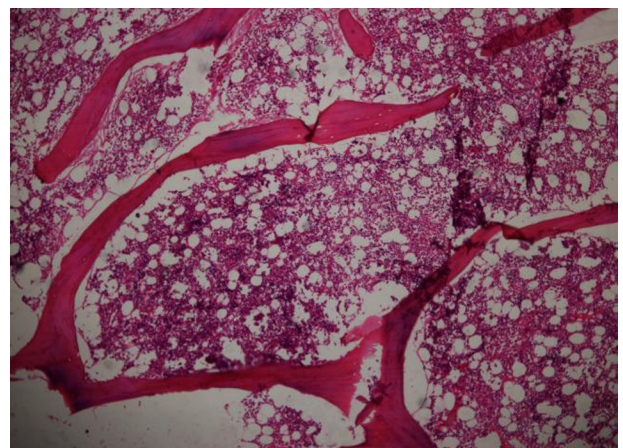
The patient was then placed in inter-maxillary fixation and class I stable occlusion was achieved. The defect was reconstructed with Biomet TMJ fossa prosthesis and a 50 mm condylar prosthesis and fixated to the ramus (Fig. 5).

At 4 week follow-up, the patient was able to open up to 37 mm with deviation to the right, which was expected. There was right partial facial nerve fallout without sensory fallout initially. At a

circumscribed and attached to the medial pole of the condyle. It was also in close proximity to the middle cranial fossa and there was a thin separation between the lesion and the fossa. The lesion appeared to be totally encapsulated. A radionuclide bone scan revealed that the lesion was still active growing. Bony exostoses, osteoid osteoma, osteoblastoma and peripheral osteoma were included in the list of differential diagnosis.

Treatment options discussed with the patient included a unilateral sagittal split osteotomy of the mandible along with orthodontic alignment. However, since the bone scan showed that the lesion was still actively growing, it was rather decided to perform right condylectomy along with the tumour. The defect would then be reconstructed with a prosthetic joint.

The patient was referred for pre-operative orthodontic treatment to align the dental arches. A wide exposure of the tumour was planned via a combined pre-auricular and parotidectomy approach with exposure and dissection of the facial nerve. This surgical approach was selected for three main reasons. Firstly, the diagnosis of the lesion was unknown at the time of surgery as no biopsy was



**Fig. 4.** H&E stained specimen showing spongy osseous hard tissue contained in a fibrous capsule.

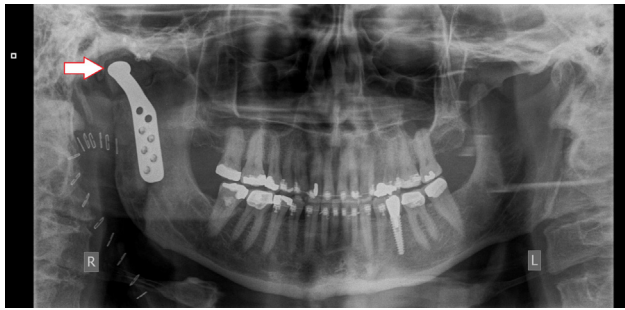

Fig. 5. Pantomograph showing reconstruction of the defect with prosthetic fossa and condyle.

second follow-up, there was some improvement in the lower branches of the right facial nerve.

Postoperatively the orthodontic treatment was continued to complete the alignment of his occlusion and the final result achieved a well-balanced Class I occlusion. After 6 month follow-up, the facial nerve fall out had completely resolved and the patient could open up to 37 mm. A cone beam CT was taken and no further abnormalities were detected. The patient has been advised to return for follow-up on yearly basis to detect any recurrences.

### 3. Discussion

Osteoma of the condyle was first described in 1927 [3] and since then, only 22 reported cases are present in the English literature (Table 1). Benign tumours of the TMJ tend to present less frequently than malignant lesions [4]. Although they can occur at any age (range: 19 to 74 years); they are most commonly found in patients over 35 years of age (mean age: 37.7 years). The lesion tends to occur more commonly in males ( $n$ : 12; 54.5%) than females [5].

The exact aetiology of osteoma remains unclear, but it appears that the lesion forms when there is uninhibited growth in bone.

The possibility of reactive mechanism, triggered by trauma or infection has been postulated [2]. One theory proposes that minor trauma may cause subperiosteal oedema or bleeding and the muscle traction could locally elevate the periosteum. This can trigger an osteogenic reaction that could be preserved by the continued muscle traction [6]. From all previous studies, trauma is a contributing factor in six (27.3%) of all cases. In this case, there was a known history of trauma, which could possibly explain the origin of this tumour. The period lapsed between time of injury and appearance of signs related to the lesion is generally long (more than 10 years).

There are numerous symptoms associated with osteomas. Generally, the most common presenting complaints include facial asymmetry ( $n$ : 10; 45.5%), Trismus ( $n$ : 9; 40.1%), malocclusion ( $n$ : 6; 27.3%), swelling in TMJ area ( $n$ : 7; 31.8%) and dull pain ( $n$ : 7; 31.8%). Only two cases were ever reported to have severe pain in the TMJ (9.1%) [7,8]. Contrary to osteoid osteomas where pain may be the chief complaint, patients with osteomas rarely have pain as a main complaint [9]. In this case, there was painless facial asymmetry and gross malocclusion which negatively impacted on the patient's appearance and function.

Radiographically, osteomas are well defined, densely sclerotic radio-opacities that can be detected on plain film radiography. Osteomas involving the condyle head can be difficult to differentiate from osteochondromas, osteophytes or condyle hyperplasia on a plain radiograph. CT views are vital in examining osteomas as they have the same density as the surrounding bone. Three-dimensional CT is helpful in assessing the dimensions of the lesion and planning the surgery as it was in this case.

The size of lesions tends to range between 15 mm–48 mm in diameter (mean size: 30.8 mm). The majority of larger lesions cause facial asymmetry and trismus however, no pattern of association between the size of the lesions and symptoms can be concluded. Most lesions were described as irregular ( $n$ : 7; 31.8%) in appearance while lesions located laterally were second most common ( $n$ : 6; 27.3%). Interestingly, only one lesion occurred anteriorly which caused severe pain and trismus. In our case, the

Table 1

Summary of all case reports on osteomas of the condyle in the literature.

Author	Age	Gender	History	Symptoms	Appearance	Size (mm)	Treatment
Ivy, 1927 [3]	35	F	Unknown	Dull pain, malocclusion	Irregular enlargement	30	Condylectomy
Worman et al, 1946 [10]	24	F	Trauma	Trismus, malocclusion	Irregular enlargement	30	Condylectomy
Miles, 1951 [11]	40	F	Unknown	Swelling	Irregular enlargement	N/A	N/A
Thoma, 1954 [12]	37	M	Unknown	Trismus, asymmetry	Irregular enlargement	30	Condylectomy
Nelson et al, 1972 [13]	49	M	Trauma	Swelling, dull pain	Enlargement anterior-medially	30	Excision
MacLennan and Brown, 1974 [14]	31	F	Unknown	Swelling, pain	Enlargement posterior-laterally	N/A	Excision
Nwoku and Koch, 1974 [15]	34	F	Unknown	Asymmetry, malocclusion	N/A	N/A	Condylectomy
Wang-Norderud and Ragab, 1976 [16]	35	M	Unknown	Asymmetry, dull pain	Enlargement anterior-medially	40	Condylectomy
Weinberg, 1977 [17]	31	M	Unknown	Malocclusion	Irregular enlargement	30	Condylectomy
Papavasilou et al, 1983 [7]	74	F	Unknown	Severe pain, trismus	Enlargement anteriorly	18	Condylectomy
Bessho et al, 1987 [18]	26	M	Trauma	Swelling	Enlargement laterally	34	Excision
Kondoh et al, 1998 [5]	40	M	Unknown	Asymmetry, Trismus	Enlargement anterior-medially	40	Excision
Chen et al, 2003 [19]	27	M	Trauma	Asymmetry, malocclusion	Irregular enlargement	28	Condylectomy
Siar et al, 2004 [20]	32	F	Unknown	Trismus	Irregular enlargement	48	Condylectomy
Mancini et al, 2005 [2]	19	F	Unknown	Asymmetry, malocclusion	N/A	28	Condylectomy
Yonezu et al, 2007 [8]	50	M	Unknown	Pain, trismus, swelling	Enlargement laterally	N/A	Condylectomy
Bjornland et al, 2009 [9]	46	M	Trauma	Swelling, asymmetry	Enlargement laterally	N/A	Excision
Chaurasia, 2009 [21]	45	F	Unknown	Swelling	Enlargement laterally	15	None
Misra et al, 2013 [6]	22	M	Unknown	Trismus	Enlargement medio-laterally	32	Condylectomy
Rajshekar et al, 2015 [1]	35	M	Trauma	Trismus, asymmetry	Enlargement medio-laterally	30	Condylectomy
Zafar et al, 2016 [4]	60	M	Unknown	Dull pain, asymmetry	Irregular enlargement	30	Excision
De Souza et al, 2017 [22]	67	F	Unknown	Trismus, asymmetry, pain	Enlargement laterally	20	Condylectomy
This case	60	M	Trauma	Asymmetry, malocclusion	Enlargement medially	30	Condylectomy

N/A: not available.

lesion occurred solely medially, which has not been described before. This was especially critical as the lesion was very close to invading the middle cranial fossa.

Surgical resection of osteomas is indicated in cases where function and aesthetics are compromised. Surgical removal with clear margins is advised to prevent recurrence. The approach to the lesion may be open surgery or endoscopic assisted access dependent upon the size and site of the lesion. Although recurrence is extremely rare (only one case reported), it is recommended to review the patient both clinically and radiographically after surgical excision of the tumour.

Condylectomy was performed in 14 (63.6%) of cases in the literature. In six cases (27.3%), surgical excision of the tumour was performed as the lesion was located laterally or anteriorly. In this case, the lesion was located medially and approaching the middle cranial fossa, hence a condylectomy was indicated to remove the entire lesion with clear margins.

In all previous cases, which underwent condylectomy, no further reconstructive efforts were performed either due to the surgery occurring prior to the availability of artificial TMJ prosthesis or limited resources. In this case, TMJ reconstruction was performed with alloplastic grafts in the form of glenoid fossa to prevent erosion of the artificial condyle through the temporal bone and into the middle cranial fossa. Orthodontic treatment was also necessary to aid the patient with the correct alignment of his dentition. The patient has been followed-up for the last 21 months following resection and reconstruction, without any symptoms or asymmetry and with a mouth opening of 37 mm and the patient continues to be an outpatient.

Osteoma of the condyle is a rare, benign, osteogenic tumour that can cause severe functional and aesthetic debilitation of patients. It should always be considered in patients with unexplained limited mouth opening and functional problems. Surgical resection is the treatment of choice while follow-up is vital.

#### Disclosure of interest

The authors declare that they have no competing interest.

#### Acknowledgments

The authors wish to acknowledge the assistance of Prof Johan Fagan (Head, Department of Ear, Nose and Throat Surgery, Groot

Schuur Hospital, University of Cape Town) and Dr Craig Greeff (Maxillofacial and Oral Surgeon, Cape Town).

#### References

- [1] Rajshekar VM, Basetty NR, Govindaraju R, David MP. Out of the ordinary: a case report of osteoma of mandibular condyle. *J Indian Acad Oral Med Radiol* 2015;27:441–4.
- [2] Mancini JC, Wolmann M, Felix VB, Freitas RR. Peripheral osteoma of the mandibular condyle. *Int J Oral Maxillofac Surg* 2005;34(1):92–3.
- [3] Ivy RH. Benign bony enlargement of the condyloid process of the mandible. *Ann surg* 1927;85(1):27–30.
- [4] Zafar E, Akbar Z, Niazi K, Pasha B. Osteoma of mandibular condyle – a case report. *Pak Oral Dental J* 2016;36(3):383–6.
- [5] Kondoh T, Seto K, Kobayashi K. Osteoma of the mandibular condyle: report of a case with a review of the literature. *J Oral Maxillofac Surg* 1998;56(8):972–9.
- [6] Misra N, Srivastava S, Bodade P, Rastogi V. Osteoma of temporomandibular joint: a rarity. *BMJ Case Rep* 2013;6 [bcr2013200268].
- [7] Papavasiliou A, Sawyer R, Lund V, et al. Benign conditions of the temporomandibular joint: A diagnostic dilemma. *Br J Oral Surg* 1983;21:222.
- [8] Yonezu H, Wakoh M, Otonari T, Sano T, Hashimoto S, Uchiyama T. Osteoma of mandibular condyle as cause of acute pain and limited-mouth-opening: case report. *Bull Tokyo Dent Coll* 2007;48(4):193–7.
- [9] Bjornland T, Berstad JR, Store G. Peripheral osteoma of the mandible mimicking an ectopic condyle: a case report. *Oral Surg* 2009;2013:178–81.
- [10] Worman HG, Waldron CW, Radsch DF. Osteoma of the mandibular condyle with deviation prognathic deformity: report of case. *J Oral Surg* 1946;4:27.
- [11] Miles AE. The use of the biopsy drill and punch in the diagnosis of oral lesions. *Br Dent J* 1951;91:7.
- [12] Thoma KH. Tumors of the condyle and temporomandibular joint. *Oral Surg* 1954;7:109.
- [13] Nelson DF, Gross BD, Miller FE. Osteoma of the mandibular condyle: Report of case. *J Oral Surg* 1972;30:761.
- [14] MacLennan WD, Brown RD. Osteoma of the mandible. *Br J Oral Surg* 1974;12:219.
- [15] Nwoku AL, Koch H. The temporomandibular joint: a rare location for bone tumours. *J Maxillofac Surg* 1974;2:113.
- [16] Wang-Norderud R, Ragab RR. Osteoma of the mandibular condyloid process: Case report. *Scand J Plast Reconstr Surg* 1976;10:77.
- [17] Weinberg S. Osteoma of the mandibular condyle: report of case. *J Oral Surg* 1977;35:929.
- [18] Bessho K, Murakami K, Iizuka T, et al. Osteoma in mandibular condyle. *Int J Oral Maxillofac Surg* 1987;16:372.
- [19] Chen YK, Lin LM, Lin CC, et al. Peripheral osteoma of the mandibular condyle. *J Chin Med Assoc* 2003;66(2):123–6.
- [20] Siar CH, Jalil AA, Ram S, et al. Osteoma of the condyle as the cause of limited mouth opening: a case report. *J Oral Sci* 2004;46:51–3.
- [21] Chaurasia A, Balan A. peripheral osteomas of jaws – a study of 6 cases. *Kerala Dent J* 2009;32:23–6.
- [22] de Souza NT, Cavalcante RC, de Albuquerque Cavalcante MA, et al. An unusual osteoma in the mandibular condyle and the successful replacement of the temporomandibular joint with a custom-made prosthesis: a case report. *BMC Res Notes* 2017;10(1):727.