

## Original Article

# Sagittal alignment differences on the operating room table compared to preoperative and postoperative imaging in anterior cervical discectomy and fusion

### ABSTRACT

**Study Design:** The study design used was a retrospective cohort.

**Objective:** The objective of this study is to determine if intraoperative improvements in sagittal alignment on the operating table persisted on postoperative standing radiographs.

**Summary of Background Data:** Cervical sagittal alignment may be correlated to postoperative outcomes. Since anterior cervical discectomy and fusions (ACDFs) can restore some cervical lordosis through intervertebral grafts/cages, it is important to understand if intraoperative radiographic measurements correlate with persistent postoperative radiographic changes.

**Materials and Methods:** Patients undergoing elective primary ACDF were screened for the presence of lateral cervical radiographs preoperatively, intraoperatively, and postoperatively. Patients were excluded if their first postoperative radiograph was more than 3 months following the procedure or if cervical lordosis was not able to be measured at each time point. Paired *t*-tests were utilized to compare differences in measurements between time points. Statistical significance was set at  $P < 0.05$ .

**Results:** Of 46 included patients, 26 (56.5%) were female, and the mean age was  $55.2 \pm 11.6$  years. C0-C2 lordosis significantly increased from the preoperative to intraoperative time point (delta  $[\Delta] = 4.49$ ,  $P = 0.029$ ) and significantly decreased from the intraoperative to postoperative time period ( $\Delta = -6.57$ ,  $P < 0.001$ ), but this resulted in no significant preoperative to postoperative change ( $\Delta = -2.08$ ,  $P = 0.096$ ). C2 slope decreased from the preoperative to the intraoperative time point ( $\Delta = -3.84$ ,  $P = 0.043$ ) and significantly increased from the intraoperative to the postoperative time point ( $\Delta = 3.68$ ,  $P = 0.047$ ), which also resulted in no net change in alignment between the preoperative and postoperative periods ( $\Delta = -0.16$ ,  $P = 0.848$ ). There was no significant difference in the C2-C7 SVA from the preoperative to intraoperative ( $\Delta = 0.85$ ,  $P = 0.724$ ) or intraoperative to postoperative periods ( $\Delta = 2.04$ ,  $P = 0.401$ ); however, the C2-C7 SVA significantly increased from the preoperative to postoperative period ( $\Delta = 2.88$ ,  $P = 0.006$ ).

**Conclusions:** Intraoperative positioning predominantly affects the mobile upper cervical spine, particularly C0-C2 lordosis and C2 slope, but these changes do not persist postoperatively.

**Keywords:** Alignment, anterior cervical discectomy and fusion, intraoperative positioning, lordosis

**MARK J. LAMBRECHTS, GREGORY R. TOCI, BRIAN A. KARAMIAN, ZACHARY KOZICK, JOHN PRODOEHL, DAVID REITER, RAHUL MUCHINTALA, ERIC TECCE, ALEXANDER VACCARO JR., PATRICK O'CONNOR, AMIT SYAL, DOMINIC LAMBO, JOSE A. CANSECO, I. DAVID KAYE, BARRETT I. WOODS, ALAN S. HILIBRAND, CHRISTOPHER K. KEPLER, ALEXANDER R. VACCARO, GREGORY D. SCHROEDER**

Department of Orthopaedic Surgery, Rothman Institute, Thomas Jefferson University, Philadelphia, PA, USA

**Address for correspondence:** Dr. Mark J. Lambrechts, Rothman Orthopaedic Institute at Thomas Jefferson University, 925 Chestnut St, 5<sup>th</sup> Floor, Philadelphia, PA - 19107, USA.  
E-mail: [mark.lambrechts@rothmanortho.com](mailto:mark.lambrechts@rothmanortho.com)

**Submitted:** 14-Aug-22  
**Published:** 07-Dec-22

**Accepted:** 14-Oct-22


This is an open access journal, and articles are distributed under the terms of the Creative Commons Attribution-NonCommercial-ShareAlike 4.0 License, which allows others to remix, tweak, and build upon the work non-commercially, as long as appropriate credit is given and the new creations are licensed under the identical terms.

**For reprints contact:** [WKHLRPMedknow\\_reprints@wolterskluwer.com](mailto:WKHLRPMedknow_reprints@wolterskluwer.com)

**How to cite this article:** Lambrechts MJ, Toci GR, Karamian BA, Kozick Z, Prodoehl J, Reiter D, *et al.* Sagittal alignment differences on the operating room table compared to preoperative and postoperative imaging in anterior cervical discectomy and fusion. *J Craniovert Jun Spine* 2022;13:415-20.

## INTRODUCTION

Optimizing cervical sagittal alignment may result in improved clinical outcomes following anterior cervical discectomy and fusion (ACDF).<sup>[1,2]</sup> Sagittal plane malalignment has been associated with pain, disability, and poor quality of life.<sup>[2,3]</sup>

Access this article online	
<b>Website:</b> <a href="http://www.jcvjs.com">www.jcvjs.com</a>	<b>Quick Response Code</b> 
<b>DOI:</b> 10.4103/jcvjs.jcvjs_100_22	

Further, the severity of symptoms, as measured by the Neck Disability Index, has been shown to have a linear relationship with radiographic parameters.<sup>[3]</sup> Compensation for cervical malalignment may lead to progressive degenerative changes, as patients seek to decrease pain by alleviating nerve root compression through maximization of the C2-C7 sagittal vertical axis (C2-C7 SVA).<sup>[11]</sup>

ACDFs can restore some cervical lordosis through intervertebral grafts or cages, but it is controversial if these changes correspond to improvements in clinical outcomes.<sup>[4-7]</sup> However, sagittal malalignment is known to increase the rates of adjacent segment disease, and as a result, significant attention has been aimed toward restoring or maintaining adequate sagittal alignment intraoperatively.<sup>[8-10]</sup> While previous research has predominantly focused on the lumbar spine including how intraoperative positioning corresponds to changes in the lumbar sagittal alignment, there is limited literature evaluating the effect of intraoperative positioning for cervical spine procedures and if intraoperative radiographs are predictive of postoperative cervical alignment.<sup>[11-14]</sup>

To optimize sagittal alignment parameters, it is worthwhile to determine the influence of patient positioning on radiographic parameters before, during, and after surgery. This may provide surgeons with important information regarding the improvements obtained intraoperatively, and if they can expect these changes to persist postoperatively. Therefore, the primary purpose of this study was to compare intraoperative radiographs to postoperative radiographs. We secondarily sought to compare preoperative radiographs to intraoperative radiographs and preoperative radiographs to postoperative radiographs to observe if improvements were noted intraoperatively and to determine if the intraoperative changes persisted after the patient was moved off the operating table.

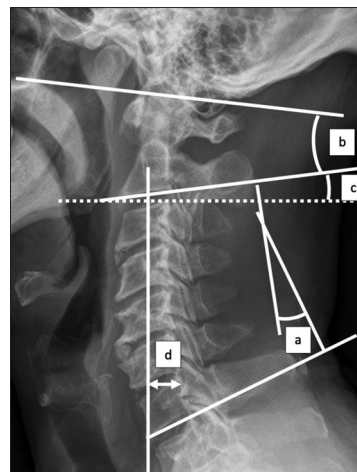
## MATERIALS AND METHODS

### Data collection and study design

A retrospective review of electronic medical records (EMRs) was conducted after the institutional review board approval. Patient consent was not deemed necessary due to the minimal risk to subjects and the retrospective nature of the study. All patients who underwent ACDF between January 2016 and December 2019 were identified using a Structured Query Language search from the current procedural terminology code 22551. Inclusion criteria were adult ( $\geq 18$  years) patients who underwent primary elective anterior cervical decompression and fusion on an AMSCO® surgical table (Steris Corporation, Mentor, Ohio, USA). Patients were

screened to determine if they had standing lateral cervical spine radiographs at their preoperative and postoperative clinic visits, as well as intraoperative radiographs (on the operating room table) following procedure instrumentation. Following screening for the presence of radiographs, the adequacy of radiographs was reviewed, which required visualization from C2-C7 at each time point for the assessment of overall cervical lordosis. Exclusion criteria included any patient without adequate preoperative, intraoperative, or postoperative lateral radiographs and patients without C2-C7 lordosis measurements at each time point. Postoperative radiographs were required to be no later than 3 weeks following the procedure date. All but one interbody spacer was composed of an allograft. The one titanium interbody spacer, which otherwise met inclusion criteria, was therefore excluded to minimize cohort heterogeneity.

Patient demographic data were obtained from the EMR, including age, sex, body mass index (BMI), smoking status (yes, no, and former), and race (white, black, and other). Disease characteristics, including preoperative diagnosis (myelopathy, radiculopathy, and/or deformity), and postoperative outcomes (hospital readmission, need for reoperation) were also collected from EMR. Construct levels and interbody spacers were obtained from operative notes and confirmed on radiographic analysis. Lateral cervical radiographic images were reviewed through our institution's picture archiving and communication system (PACS; Sectra AB, Linköping, Sweden). Eight radiographic parameters were measured, including C0-C2 lordosis, C2-C7 lordosis, C2-C7 sagittal vertical axis (SVA), T1 minus C2-C7 lordosis (T1 minus CL), C2 slope, upper C7 slope, lower C7 slope, and T1 slope, as defined by previous literature [Figure 1].<sup>[3]</sup> The



**Figure 1:** Lateral cervical spine radiograph with examples of radiographic parameter measurement techniques. (a) C2-C7 lordosis, (b) C0-C2 lordosis, (c) C2 slope (a similar technique for upper and lower C7 slope and T1 slope), and (d) cervical sagittal vertical axis

preoperative radiographic measurements were all recorded before instrumentation, whereas the intraoperative and postoperative radiographs were all recorded following instrumentation.

### Statistical analysis

Descriptive statistics including mean and standard deviation were used to report radiographic parameters at the preoperative, intraoperative, and postoperative time points. Continuous data comparing the differences (delta [ $\Delta$ ]) between preoperative and intraoperative time points, intraoperative and postoperative time points, and preoperative and postoperative time points were compared using paired *t*-tests with 95% confidence intervals also reported. Two-sample *t*-tests were utilized to compare continuous data between groups, when applicable. A *P* < 0.05 was considered to be statistically significant. All statistical analyses were performed using RStudio version 4.0.2 (Boston, MA, USA).

## RESULTS

### Cohort description

Of 1351 patients identified, 447 patients (33.1%) had preoperative, intraoperative, and postoperative lateral cervical spine radiographs. Forty-seven of these patients (10.5%) were able to have C2-C7 lordosis measured at each of the three time points. One patient had a titanium interbody spacer and was excluded. Of the 46 included patients, 26 (56.5%) were female. The mean age was  $55.2 \pm 11.6$  years with a mean BMI of  $27.0 \pm 5.20$  [Table 1]. The mean number of levels fused was  $1.98 \pm 0.95$ . Compared to the 400 patients excluded for inadequate visualization of the cervical spine, our study group had a lower BMI ( $27.0 \pm 5.20$  vs.  $30.7 \pm 6.04$ , *P* < 0.001), but there was not a significant difference in age ( $55.2 \pm 11.6$  years vs.  $54.7 \pm 12.1$  years, *P* = 0.655) or number of levels fused ( $1.98 \pm 0.95$  vs.  $2.13 \pm 0.90$ , *P* = 0.340).

The majority of patients had a preoperative diagnosis of myelopathy (52.2%) or radiculopathy (67.4%), whereas three patients (6.52%) had a preoperative diagnosis of deformity. Only one patient (2.17%) was readmitted to the hospital, and eight patients (17.4%) ultimately underwent reoperation on their cervical spine. The most common construct levels were C5-C6 (11 patients, 23.9%) and C5-C7 (11 patients, 23.9%) [Table 2].

### Time point comparisons

The preoperative, intraoperative and postoperative radiographic measurements for each parameter of interest are listed in [Table 3]. C0-C2 lordosis significantly increased from the preoperative to intraoperative time point ( $\Delta$  = 4.49,

**Table 1: Patient demographics**

Variable	Cohort (n=46), n (%)
Sex	
Female	26 (56.5)
Male	20 (43.5)
Age (years)	55.2 (11.6)
BMI	27.0 (5.20)
Smoking status	
Current smoker	9 (19.6)
Former smoker	10 (21.7)
Nonsmoker	27 (58.7)
Race	
Black	6 (13.0)
Other	7 (15.2)
White	33 (71.7)

BMI – Body mass index

**Table 2: Surgical characteristics**

Variable	Cohort (n=46), n (%)
Number of levels	1.98 (0.95)
Preoperative diagnosis	
Myelopathy	24 (52.2)
Radiculopathy	31 (67.4)
Deformity	3 (6.52)
Hospital readmission	1 (2.17)
Reoperation	8 (17.4)

**Table 3: Radiographic measurements for each group**

Parameter	n	Preoperative, n (%)	Intraoperative, n (%)	Postoperative, n (%)
C0-C2 Cobb	37	27.2 (9.96)	31.7 (9.36)	25.2 (8.03)
C2-C7 lordosis	46	11.2 (8.36)	12.3 (8.49)	11.0 (8.19)
C2-C7 SVA (mm)	44	27.5 (9.73)	28.4 (15.5)	30.4 (8.17)
T1 minus CL	30	19.4 (10.1)	16.1 (11.1)	19.6 (7.29)
C2 slope	46	21.7 (8.15)	17.9 (11.5)	21.5 (7.41)
Upper C7 slope	46	26.7 (6.58)	27.0 (10.5)	27.7 (6.92)
Lower C7 slope	46	29.0 (7.01)	28.7 (10.7)	28.4 (7.59)
T1 slope	30	30.8 (8.18)	30.1 (11.2)	31.3 (5.92)

CL – Cervical lordosis; SVA – Sagittal vertical axis

*P* = 0.029) and significantly decreased from the intraoperative to postoperative time point ( $\Delta$  = -6.57, *P* < 0.001), which ultimately resulted in no significant difference between the preoperative and postoperative measurements ( $\Delta$  = -2.08, *P* = 0.096). C2 slope also significantly decreased from the preoperative to the intraoperative period ( $\Delta$  = -3.84, *P* = 0.043) and significantly increased from the intraoperative to the postoperative time point ( $\Delta$  = 3.68, *P* = 0.047), which also resulted in no net change in alignment between the preoperative and postoperative periods ( $\Delta$  = -0.16, *P* = 0.848). There was no significant difference in the C2-C7 SVA from the preoperative to intraoperative ( $\Delta$  = 0.85, *P* = 0.724) or intraoperative to postoperative periods ( $\Delta$  = 2.04, *P* = 0.401); however, the

**Table 4: Radiographic parameter comparisons between time points**

Parameter	n	Preoperative to intraoperative			Intraoperative to postoperative			Preoperative to postoperative		
		Delta, n (%)	95% CI	P	Delta, n (%)	95% CI	P	Delta, n (%)	95% CI	P
C0-C2 lordosis	37	4.49 (12.0)	0.50-8.48	0.029*	-6.57 (8.22)	-9.31--3.83	<0.001*	-2.08 (7.41)	-4.55-0.39	0.096
C2-C7 lordosis	46	1.05 (10.4)	-2.05-4.15	0.499	-1.32 (9.07)	-4.01-1.37	0.329	-0.27 (9.76)	-3.17-2.63	0.852
C2-C7 SVA (mm)	44	0.85 (15.8)	-3.96-5.66	0.724	2.04 (15.9)	-2.80-6.87	0.401	2.88 (6.64)	0.87-4.90	0.006*
T1 minus CL	30	-3.27 (12.2)	-7.85-1.30	0.154	3.50 (11.2)	-0.69-7.70	0.098	0.23 (9.82)	-3.44-3.90	0.899
C2 slope	46	-3.84 (12.5)	-7.55--0.13	0.043*	3.68 (12.2)	0.05-7.31	0.047*	-0.16 (5.75)	-1.87-1.55	0.848
Upper C7 slope	46	0.28 (10.7)	-2.89-3.44	0.861	0.77 (11.9)	-2.77-4.31	0.664	1.05 (6.43)	-0.86-2.96	0.276
Lower C7 slope	46	-0.28 (10.3)	-3.42-2.87	0.861	-0.32 (11.5)	-3.82-3.19	0.856	-0.59 (7.30)	-2.81-1.63	0.593
T1 slope	30	-0.63 (10.8)	-4.67-3.41	0.752	1.20 (9.66)	-2.41-4.81	0.503	0.57 (5.40)	-1.45-2.58	0.570

\*Statistical significance ( $P < 0.05$ ). CI – Confidence interval; CL – Cervical lordosis; SVA – Sagittal vertical axis

C2-C7 SVA significantly increased from the preoperative to postoperative period ( $\Delta = 2.88, P = 0.006$ ) [Table 4].

## DISCUSSION

Intraoperative radiographs are important in evaluating sagittal alignment during ACDF as sagittal malalignment has been associated with greater pain, disability, and worse quality of life, as well as the progression of adjacent segment pathology.<sup>[1-3,8-10]</sup> However, it is unknown how intraoperative lateral radiographs compare to standing lateral radiographs pre- and postoperatively. Our study found that intraoperative positioning exaggerated C0-C2 lordosis and decreased C2 slope, but neither measurement was retained postoperatively. Further, intraoperative radiographs may have concealed differences in C2-C7 SVA since our study did not identify significant differences between preoperative to intraoperative measurements or intraoperative to postoperative measurements, but there was a significant difference between the preoperative to postoperative periods.

Intraoperative surgical positioning is effective at recreating physiologic lordosis in the lumbar spine, but it is unclear how positioning for ACDF affects intraoperative radiographic parameters.<sup>[11-14]</sup> Our study suggests that operative positioning has minimal effect on C2-C7 lordosis, but a large effect on C0-C2 lordosis. The reason for this finding is unclear, but may be related to the greater degree of spondylosis seen in the subaxial cervical spine compared to the upper cervical spine.<sup>[15]</sup> As the cervical spine ages, the relatively equal distribution of sagittal motion between the upper cervical and subaxial cervical spine dissipates.<sup>[16]</sup> This is likely predominantly due to disc degeneration, which decreases available sagittal motion in the subaxial spine requiring the upper cervical spine to compensate by increasing its net flexion and extension motion.<sup>[17]</sup> During the procedure, the patient is positioned with slight neck hyperextension; therefore, cervical lordosis is emphasized. However, once the patient is transferred off the operating table, lordosis is restored to preoperative ranges.

C2 slope is of increasing interest in cervical spine surgery. C2 slope strongly correlates with patient-reported outcomes postoperatively, which may be due to its link between the upper cervical and subaxial cervical spine.<sup>[18,19]</sup> Thus, as surgeons more frequently rely on C2 slope as a marker of cervical deformity, it is important to consider how C2 varies between the operating room and standing lateral radiographs. We speculate C2 variability may be due to the upper cervical spine's association with occipital parameters and positioning, similar to the subaxial cervical spine's relationship with thoracolumbar and pelvic parameters.<sup>[20]</sup> Intraoperatively, head positioning may differ significantly from its physiologic alignment when standing, as a patient's head positioning intraoperatively is at the discretion of both the anesthesia and surgical teams to maintain an adequate airway and allow for visualization of the anterior cervical spine. Thus, intraoperative head positioning may differ from that of preoperative or postoperative measurements, leading to changes in C0-C2 lordosis and C2 slope intraoperatively as demonstrated in our findings.

We found no difference in C2-C7 lordosis between preoperative and postoperative time points. Whether ACDF increases C2-C7 lordosis is controversial, as numerous studies have demonstrated statistically significant differences between preoperative and postoperative measurements, whereas others have not.<sup>[4,5,7,8,21]</sup> Our findings align with a similar study from our institution, which found no differences in C2-C7 lordosis in 230 patients who underwent ACDF.<sup>[7]</sup> We did find a significant increase in C2-C7 SVA between preoperative and postoperative time points, which also supports previous studies.<sup>[5,7,22]</sup> Interestingly, our study was unable to detect differences between preoperative and intraoperative time points, suggesting intraoperative measurements may mask the expected change postoperatively. C2-C7 SVA is a marker for the head position in relation to the cervical spine, and changes in C2-C7 SVA may result from postural compensation to degenerative changes of the cervical spine.<sup>[23]</sup> As C2-C7 SVA increases, the head moves forward, and this forward head



positioning is associated with increased pain. C2-C7 SVA relies on a variety of factors, including C0-C2 lordosis (which we found to significantly change between positioning), T1 tilt, and head positioning, which serves to limit the pain and maintain horizontal gaze.<sup>[23,24]</sup> Due to the dynamic nature of C2-C7 SVA, it is possible that it was increased in our cohort following surgery due to our short-term postoperative radiographs where patients continued to experience postoperative pain.<sup>[25]</sup>

The limitations in this study include those inherent to retrospective study design, but comparisons were made within groups which limited the effects of confounding variables. Further, our sample size was small and many patients were excluded for either a lack of radiographs at each time point (66.9%) or for an inability to visualize the entire cervical spine on each of these corresponding radiographs (89.5%). This may introduce selection bias, particularly in patients with higher BMIs, as they were more likely to be excluded, commonly due to difficulty in visualizing the lower segments of the cervical spine. The overwhelming majority of our cohort utilized allograft interbody spacers so we excluded one patient with a different type of interbody spacer (titanium). Finally, our study focused on short-term interval changes in sagittal alignment, but longer intervals may provide insight into the variability of these sagittal parameters and if their intraoperative changes persist following surgery.

## CONCLUSIONS

The effect of sagittal alignment in routine degenerative ACDF is unclear. The current study finds that intraoperative measurements, with the exception of those localized to the upper cervical spine, were no different compared to preoperative or postoperative standard lateral radiographs. Surgeons can continue to utilize intraoperative radiographs in ACDFs to guide surgical decision-making due to their lack of differences compared to preoperative or postoperative time points, but surgeons should understand that intraoperative changes in C0-C2 lordosis and C2 slope are unlikely to be maintained.

## Financial support and sponsorship

Nil.

## Conflicts of interest

There are no conflicts of interest.

## REFERENCES

- Patwardhan AG, Khayatadeh S, Havey RM, Voronov LI, Smith ZA, Kalmanson O, *et al.* Cervical sagittal balance: A biomechanical perspective can help clinical practice. *Eur Spine J* 2018;27:25-38.
- Villavicencio AT, Babuska JM, Ashton A, Busch E, Roeca C, Nelson EL, *et al.* Prospective, randomized, double-blind clinical study evaluating the correlation of clinical outcomes and cervical sagittal alignment. *Neurosurgery* 2011;68:1309-16.
- Iyer S, Nemani VM, Nguyen J, Elysee J, Burapachaisri A, Ames CP, *et al.* Impact of cervical sagittal alignment parameters on neck disability. *Spine (Phila Pa 1976)* 2016;41:371-7.
- Quek CX, Goh GS, Soh RC. Does cervical alignment matter? the effect of 2-level anterior cervical discectomy and fusion on sagittal alignment and patient-reported outcomes. *Clin Spine Surg* 2021;34:E545-51.
- Guo S, Lu S, Kong C, Li X, Liu C. Comparison of clinical outcomes and sagittal alignment after different levels of anterior cervical discectomy and fusion in patients with cervical spondylotic myelopathy: From one-level to three-level. *Spine (Phila Pa 1976)* 2021;46:E153-60.
- Kim HJ, Choi BW, Park J, Pesenti S, Lafage V. Anterior cervical discectomy and fusion can restore cervical sagittal alignment in degenerative cervical disease. *Eur J Orthop Surg Traumatol* 2019;29:767-74.
- Karamian BA, Mao JZ, Viola A 3<sup>rd</sup>, Ju DG, Canseco JA, Toci GR, *et al.* Patients with preoperative cervical deformity experience similar clinical outcomes to those without deformity following 1-3 level anterior cervical decompression and fusion. *Clin Spine Surg* 2022;35:E466-72.
- Katsuura A, Hukuda S, Saruhashi Y, Mori K. Kyphotic malalignment after anterior cervical fusion is one of the factors promoting the degenerative process in adjacent intervertebral levels. *Eur Spine J* 2001;10:320-4.
- Patwardhan AG, Khayatadeh S, Nguyen NL, Havey RM, Voronov LI, Muriuki MG, *et al.* Is cervical sagittal imbalance a risk factor for adjacent segment pathomechanics after multilevel fusion? *Spine (Phila Pa 1976)* 2016;41:E580-8.
- Yang X, Bartels RH, Donk R, Arts MP, Goedmakers CM, Vleggeert-Lankamp CL. The association of cervical sagittal alignment with adjacent segment degeneration. *Eur Spine J* 2020;29:2655-64.
- Peterson MD, Nelson LM, McManus AC, Jackson RP. The effect of operative position on lumbar lordosis. A radiographic study of patients under anesthesia in the prone and 90-90 positions. *Spine (Phila Pa 1976)* 1995;20:1419-24.
- Guanciale AF, Dinsay JM, Watkins RG. Lumbar lordosis in spinal fusion. A comparison of intraoperative results of patient positioning on two different operative table frame types. *Spine (Phila Pa 1976)* 1996;21:964-9.
- Stephens GC, Yoo JU, Wilbur G. Comparison of lumbar sagittal alignment produced by different operative positions. *Spine (Phila Pa 1976)* 1996;21:1802-6.
- Tan SB, Kozak JA, Dickson JH, Nalty TJ. Effect of operative position on sagittal alignment of the lumbar spine. *Spine (Phila Pa 1976)* 1994;19:314-8.
- Tao Y, Galbusera F, Niemeyer F, Samartzis D, Vogele D, Wilke HJ. Radiographic cervical spine degenerative findings: A study on a large population from age 18 to 97 years. *Eur Spine J* 2021;30:431-43.
- Goel VK, Clark CR, Gallaes K, Liu YK. Moment-rotation relationships of the ligamentous occipito-atlanto-axial complex. *J Biomech* 1988;21:673-80.
- Hayashi T, Daubs MD, Suzuki A, Phan K, Shiba K, Wang JC. Effect of Modic changes on spinal canal stenosis and segmental motion in cervical spine. *Eur Spine J* 2014;23:1737-42.
- Protosaltis TS, Ramchandran S, Tishelman JC, Smith JS, Neuman BJ, Gregory MM Jr, *et al.* The importance of C2 slope, a singular marker of cervical deformity, correlates with patient-reported outcomes. *Spine (Phila Pa 1976)* 2020;45:184-92.
- Divi SN, Bronson WH, Canseco JA, Chang M, Goyal DK, Nicholson KJ, *et al.* How do C2 tilt and C2 slope correlate with patient reported outcomes in patients after anterior cervical discectomy and fusion?

- Spine J 2021;21:578-85.
20. Zhu W, Sha S, Liu Z, Li Y, Xu L, Zhang W, *et al.* Influence of the occipital orientation on cervical sagittal alignment: A prospective radiographic study on 335 normal subjects. *Sci Rep* 2018;8:15336.
  21. Hyun SJ, Kim KJ, Jahng TA, Kim HJ. Clinical impact of T1 slope minus cervical lordosis after multilevel posterior cervical fusion surgery: A minimum 2-Year follow up data. *Spine (Phila Pa 1976)* 2017;42:1859-64.
  22. Katsuura Y, Lemons A, Lorenz E, Swafford R, Osborn J, Cason G. Radiographic analysis of cervical and spinal alignment in multilevel ACDF with lordotic interbody device. *Int J Spine Surg* 2017;11:13.
  23. Patwardhan AG, Havey RM, Khayatzaeh S, Muriuki MG, Voronov LI, Carandang G, *et al.* Postural consequences of cervical sagittal imbalance: A novel laboratory model. *Spine (Phila Pa 1976)* 2015;40:783-92.
  24. Hofler RC, Muriuki MG, Havey RM, Blank KR, Frazzetta JN, Patwardhan AG, *et al.* Neutral cervical sagittal vertical axis and cervical lordosis vary with T1 tilt. *J Neurosurg Spine* 2020. p. 1-7. doi: 10.3171/2020.2.SPINE191363.
  25. Chen HY, Yang MH, Lin YP, Lin FH, Chen PQ, Hu MH, *et al.* Impact of cervical sagittal parameters and spinal cord morphology in cervical spondylotic myelopathy status post spinous process-splitting laminoplasty. *Eur Spine J* 2020;29:1052-60.