


Ligaclip for Preauricular Skin Tags in the Newborn

Fabrizio Schonauer¹ Antonio Guastafierro²  Elisabetta Grasso¹ Sara Izzo²
Giovanni Francesco Nicoletti² Francesco D'Andrea¹

¹Division of Plastic, Reconstructive and Aesthetic Surgery, Università degli Studi di Napoli Federico II Scuola di Medicina e Chirurgia, Federico II University, Naples, Campania, Italy

²Department of Plastic Surgery, Università degli Studi della Campania Luigi Vanvitelli, Caserta, Italy

Address for correspondence Antonio Guastafierro, MD, Department of Plastic Surgery, Università degli Studi della Campania Luigi Vanvitelli, Caserta 81100, Italy
(e-mail: antonio.guastafierro.15@gmail.com).

Eur J Pediatr Surg 2021;31:273–275.

Abstract

Introduction Skin tags are benign lesions, that often represent only an aesthetic problem; if subjected to trauma, they can occasionally bleed with possible infection and pain. When they occur in the preauricular region, attention should be paid to the diagnosis and approach; in fact, controversy exists in the differential diagnosis between hair follicle nevi, accessory tragus, and skin tag. Misdiagnosis and failure of treatment can lead to serious consequences, such as chondritis.

Materials and Methods In our retrospective study, we evaluated 19 newborns affected by single, unilateral skin tag in the preauricular region. Each patient underwent a careful clinical examination; lesions without a pilosebaceous unit and with a thin, soft pedicle were treated in the nursery with Ligaclip (Johnson & Johnson).

Results Skin tag falls between day 7 and 10. We had no cases of edema, cellulitis, clip loss, or bleeding. Scarring results were extremely satisfactory at 3-month follow-up.

Conclusion We believe that after a careful clinical examination, cases of skin tags in the preauricular area can be selected and treated with Ligaclip. This procedure can be considered rapid, safe, economical, and simple in the newborn patients.

Keywords

- ▶ skin tag
- ▶ newborn
- ▶ Ligaclip
- ▶ preauricular

Introduction

Skin tags are skin colored or hyperpigmented, usually pedunculated cutaneous lesions, that occur in different body regions, from the face to the limbs, up to the fingers.^{1,2} These benign lesions often represent only an aesthetic problem, but if subjected to trauma, they can occasionally bleed, with possible infection and pain. Many treatment options exist for skin tag in adult patients, such as cryosurgery, surgical excision, and electrosurgery, while ligation or excision are preferred for the newborns.¹ However, when they occur in the preauricular region, attention should be paid to the diagnosis and right approach.^{3,4} The purpose of this paper is to offer a new approach to the soft-pedicated skin tags of the preauricular region, showing our ligation technique with Ligaclip in the newborn patients.

Materials and Methods

Each patient underwent a careful clinical examination, in the nursery, evaluating the presence of comorbidities or any cranial facial malformations. The lesion was evaluated for the presence of pilosebaceous units and the consistency of the pedicle by palpation. Lesions without a pilosebaceous unit and with a thin and soft pedicle were treated in the nursery. Ultrasound examination was not performed. Patients underwent a minimal subcutaneous injection of an anesthetic solution (0.1 mL of mepivacaine with adrenaline 1/100,000) at the base of the skin tag pedicle. Then a small-sized metal clip (Ligaclip, Johnson & Johnson) was applied at the very base of the lesion (**→ Fig. 1**). Patients returned to follow-up after 1 week and then after 10 days. All patients attended the 3-month follow-up appointment; one independent surgeon blindly evaluated scar

received
January 7, 2020
accepted
April 26, 2020
published online
June 8, 2020

© 2020, Thieme. All rights reserved.
Georg Thieme Verlag KG,
Rüdigerstraße 14,
70469 Stuttgart, Germany

DOI <https://doi.org/10.1055/s-0040-1712931>.
ISSN 0939-7248.

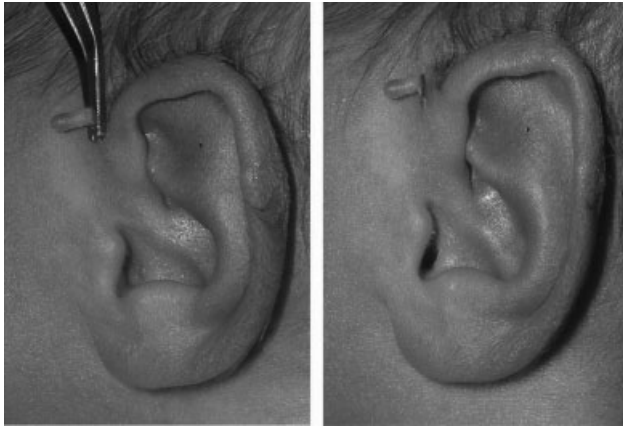


Fig. 1 A subcutaneous injection of an anesthetic solution (0.1 mL of mepivacaine with adrenaline 1/100,000) was performed at the base of the skin tag pedicle and then a small-sized metal clip was applied.

outcomes. The method used for scar evaluation was the Stony Brook Scar Evaluation Scale.⁵

Results

In this study, we enrolled 19 patients (9 females and 10 males), affected by single, unilateral lesion in the preauricular region. The mean age was 9.3 days (range 3–15). All these lesions clinically appeared as soft-pediced, skin-colored papule. These patients had no comorbidities. Skin tag pedicles appeared mobile; there was no solid consistency at the bottom and absence of pilosebaceous units. All patients were treated with single or two clips Ligaclip (Johnson & Johnson). Ischemic necrosis was obtained with skin tag fall between day 7 and 10. We had no cases of edema, cellulitis, clip loss, or bleeding. Ligaclip fall occurred after day 9. All patients completed the follow-up at 3 months; all residual scars obtained the highest score (mean value: 5).

Discussion

To date, controversy exists in the differential diagnosis between hair follicle nevi, accessory tragus, and skin tag. Ban et al reported that hair follicle nevi may look like an accessory tragus without cartilage.^{6,7} Typical histology of an accessory tragus reveals abundant subcutaneous fat, a prominent connective tissue framework, with or without cartilage which in depth can be in continuity with external ear structures⁸; an accessory tragus can be accompanied or not by a pilosebaceous unit.³ For these characteristics, accessory tragus can be misdiagnosed as skin tag.³ A skin tag, also called acrochordon, is composed, instead, of fibrovascular tissue with elastic fibers and adipose tissue, without pilosebaceous units, eccrine glands, or cartilage.⁹ Chander et al¹⁰ identified with the term cartilaginous choristoma, any lesion characterized by cartilage in the subcutis or deep dermis, covered by dermis and skin. So, he joined the terms chondrocutaneous branchial remnants, accessory pinna/tragus, and cartilaginous choristoma on the basis of their histological composition; in our

opinion, this is the most appropriate definition of these lesions of the preauricular region.

In fact, it is fundamental for the therapeutic approach of preauricular lesions to distinguish lesions with cartilaginous skeleton (cartilaginous choristoma) from lesions with fibrovascular skeleton (nevi or skin tags). Some authors proposed the use of metal clips in cases of polydactyly in the newborn,¹¹ and analyzed the differences between suture ligation and surgical excision. Suture ligation is indicated for postaxial polydactyly type B; it refers to the nonfunctional, floppy extra digit on the ulnar border of the hand when the base is narrow or pedicled.¹² Patillo and Rayan cautioned against suture ligation because of early frequent complications, such as failure of separation, cellulitis, or edema.¹³ Furthermore, Mills et al proposed surgical metal clip application for polydactyly.¹² They argued that the use of metal clips is safer and more practical than suture ligation. In their 15 years of experience, they reported minimal morbidity and low incidence of scar revision. There were no reports of wound infections, including cellulitis or failure of treatment with the surgical clip falling off. They also considered metallic clip economically sound for both the family and health care fronts.

Based on our experience, the use of metal clips to remove skin tags of the preauricular region is an easy technique, better tolerated than the suture ligation, that more often tends to give away. Ligation of an unknown cartilaginous axis can lead to serious consequences, such as chondritis or osteochondritis.³ For this reason, we recommend a thorough evaluation of the pedicle consistency and a possible follicle sebaceous unit presence, to differentiate the skin tag from an accessory tragus or more seldom from a follicular nevus. In doubtful cases, an ultrasound examination can help for the definitive diagnostic solution.

Conclusion

An appropriate diagnostic approach is important for the treatment of congenital skin lesions in the preauricular area. We believe that ligation by Ligaclip is indicated for the removal of skin lesions with a thin, narrow, and non-cartilaginous pedicle. This technique can be performed in the nursery in just a few minutes, avoiding the use of the operating room, that creates anxiety to the parents of the newborns. This procedure can be considered rapid, safe, economical, and simple in the newborn patients.

Ethical Approval

Written informed consent for patient information and images was provided by a legally authorized representative. All the procedures performed in this study were in accordance with the 1964 Helsinki declaration and its later amendments or comparable ethical standards.

Funding

None.

Conflict of Interest

None declared.

References

- 1 Görgülü T, Torun M, Güler R, Olgun A, Kargi E. Fast and painless skin tag excision with ethyl chloride. *Aesthetic Plast Surg* 2015;39(04):644–645
- 2 Lee JA, Khodae M. Enlarging, pedunculated skin lesion. *Acrochordon*. *Am Fam Physician* 2012;85(12):1191–1192
- 3 Sebben JE. The accessory tragus—no ordinary skin tag. *J Dermatol Surg Oncol* 1989;15(03):304–307
- 4 McGrath BM, Ashton BD. Dermacase: can you identify this condition? Accessory tragus. *Can Fam Physician* 2012;58(07):767
- 5 Fearmonti R, Bond J, Erdmann D, Levinson H. A review of scar scales and scar measuring devices. *Eplasty* 2010;10:e43
- 6 Ban M, Kamiya H, Yamada T, Kitajima Y. Hair follicle nevi and accessory tragi: variable quantity of adipose tissue in connective tissue framework. *Pediatr Dermatol* 1997;14(06):433–436
- 7 Asahina A, Mitomi H, Sakurai N, Fujita H. Multiple accessory tragi without cartilage: relationship with hair follicle naevi? *Acta Derm Venereol* 2009;89(03):316–317
- 8 Rankin JS, Schwartz RA. Accessory tragus: a possible sign of Goldenhar syndrome. *Cutis* 2011;88(02):62–64
- 9 Brownstein MH, Wanger N, Helwig EB. Accessory tragi. *Arch Dermatol* 1971;104(06):625–631
- 10 Chander B, Dogra SS, Raina R, Sharma C, Sharma R. Chondrocutaneous branchial remnants or cartilaginous choristoma: terminology, biological behavior and salience of bilateral cervical lesions. *Turk Patoloji Derg* 2014;30(03):195–200
- 11 Chopan M, Sayadi L, Chim H, Buchanan PJ. To tie or not to tie: a systematic review of postaxial polydactyly and outcomes of suture ligation versus surgical excision. *Hand (N Y)* 2020;15(03):303–310
- 12 Mills JK, Ezaki M, Oishi SN. Ulnar polydactyly: long-term outcomes and cost-effectiveness of surgical clip application in the newborn. *Clin Pediatr (Phila)* 2014;53(05):470–473
- 13 Patillo D, Rayan GM. Complications of suture ligation ablation for ulnar polydactyly: a report of two cases. *Hand (N Y)* 2011;6(01):102–105



THIEME