

REVIEW ARTICLE

Dystonia in veterinary neurology

Koen M. Santifort¹  | Paul J. J. Mandigers^{1,2} 

¹Evidensia Referral Hospitals, Arnhem, The Netherlands

²Department of Clinical Sciences, Faculty of Veterinary Medicine, Utrecht University, Utrecht, The Netherlands

Correspondence

Paul J. J. Mandigers, Department of Clinical Sciences, Faculty of Veterinary Medicine, University Utrecht, Yalelaan 108, 3584 CM Utrecht, The Netherlands.

Email: p.j.j.mandigers@uu.nl

Funding information

University Utrecht Open Access Publishing Funding

Abstract

Dystonia is a clinical sign and main feature of many movement disorders in humans as well as veterinary species. It is characterized by sustained or intermittent involuntary muscle contractions causing abnormal (often repetitive) movements, postures, or both. This review discusses the terminology and definition of dystonia, its phenomenology, and its pathophysiology, and provides considerations regarding the diagnosis and treatment of dystonia in dogs and cats. In addition, currently recognized or reported disorders in dogs and cats in which dystonia is a particular or main feature are discussed and comparisons are made between disorders featuring dystonia in humans and animals. We suggest that when describing the phenomenology of dogs and cats with dystonia, if possible the following should be included: activity being performed at onset (e.g., resting or running or exercise-induced), body distribution, duration, responsiveness (subjective), severity, temporal pattern (i.e., paroxysmal or persistent, severity at onset and at later stages), presence or absence of autonomic signs (e.g., salivation), presence or absence of preceding signs (e.g., restlessness), presence or absence of signs after dystonia subsides (e.g., sleepiness), coexistence of other movement disorders, any other neurological manifestations, and possible links to administered medications, intoxications or other associated factors. We also suggest that dystonia be classified based on its etiology as either structural genetic, suspected genetic, reactive, or unknown.

KEYWORDS

dyskinesia, hyperkinetic, movement disorder, muscle tone

1 | INTRODUCTION

Dystonia refers to abnormal muscle tone and can be a feature of many disorders. This review focusses on dystonia as a feature of movement disorders. Movement disorders (dyskinesias) including

paroxysmal dyskinesias (PxD) are recognized in clinical veterinary neurology with increasing frequency. Many terms have been used to describe dyskinesias in veterinary literature. A recent consensus statement recommended “defining the disorder simply as a dyskinesia and providing a description of the movements.”¹ Dystonia frequently is the predominant clinical sign of movement disorders in dogs. Dystonic features, although usually consistent for a specific patient, show considerable variability in severity, forcefulness, speed, amplitude, and localization.²⁻⁵ This variability, including sometimes paroxysmal

Abbreviations: ASM, anti-seizure medication; BSP, bovine spastic paresis; BSS, bovine spastic syndrome; CNS, central nervous system; ERH, equine reflex hypertonia; PKD, paroxysmal kinesigenic dyskinesia; PxD, paroxysmal dyskinesia(s).

This is an open access article under the terms of the [Creative Commons Attribution-NonCommercial-NoDerivs](https://creativecommons.org/licenses/by-nc-nd/4.0/) License, which permits use and distribution in any medium, provided the original work is properly cited, the use is non-commercial and no modifications or adaptations are made.

© 2022 The Authors. *Journal of Veterinary Internal Medicine* published by Wiley Periodicals LLC on behalf of American College of Veterinary Internal Medicine.

occurrence, can make it difficult for clinicians to recognize dystonia. To recognize and understand dystonia in veterinary species, it is important to have knowledge of the phenomenology as well as postulated etiology or pathophysiology. This review will elaborate upon the terminology and definition of dystonia, its phenomenology, and its pathophysiology. In addition, PxD in dogs featuring dystonia, drug-induced dystonia in dogs and selected disorders in some other species in which dystonia is a particular or main feature are discussed. Considerations are provided regarding diagnosis and treatment of dystonia in veterinary patients. Lastly, short case discussions are provided and videos are included. As suggested in the recent consensus report, use of terms employed in the human medical literature to describe particular features of movement disorders (eg, athetosis, chorea, ballism) is avoided in this review.¹ Considerations with particular relevance to domestic animals (in contrast to humans) are provided.

2 | TERMINOLOGY

The term dystonia comes from Greek, “dys-” meaning bad, ill, or abnormal, and “-tonia” from “tonos” meaning tension or tone. It pertains specifically to muscle tone when used in the medical sense. Dystonia refers to dysregulation of muscle tone and can be a feature of many disorders. Dystonia is a clinical sign often used in human and veterinary patients with paroxysmal dyskinesic disorders, but not exclusively.^{2,6-9} Although the term “dys-” may refer to “too little” (hypotonia) as well as “too much” (hypertonia), dystonia is classically and almost exclusively used to describe excess muscle tone. As such, its visual and tactile description may be noted as muscle hypertonicity. As an element of dyskinesia, dystonia can be classified as hyperkinetic (i.e., too much movement or muscle activity) or too little muscle activity (hypotonicity). When dystonia is the only relevant clinical sign in a patient, the term sometimes is used to refer to a solitary disorder. This condition has been called “isolated dystonia” in contrast to “dystonia plus” when dystonia is the main but not sole feature of the patient's disorder.^{2,5,8} The term “primary dystonia” has been used in the human medical literature to describe genetic or idiopathic cases in which dystonia is the only motor feature (isolated dystonia) and consistent pathologic changes are absent.^{5,10} The term dystonias (plural) refers to a group of disease states that are mainly or exclusively characterized by dystonia. To avoid confusion, we recommend the term “dystonia” to refer to a clinical sign in any context when applicable to veterinary species. The context in which this clinical sign is mentioned will dictate whether dystonia is the main feature of the disorder or if it is 1 of many features. For example, when dystonia is the main feature of a PxD, the disorder may be referred to as “paroxysmal dyskinesia characterized by dystonia.”^{7,11}

3 | CLASSIFICATION

Although dystonia may be classified in many different ways, we suggest implementing 2 classification systems. The first is a practical

classification based on temporal pattern and localization characteristics (Figure 1). As suggested in the consensus report on dyskinesia in dogs, description of the actual witnessed or video-recorded signs is recommended in each individual case.¹ However, when dystonia is a feature of dyskinesia or a predominant clinical sign in any other disorder, it is preferable to include a minimum classification of dystonia in these cases to facilitate future retrospective and prospective studies on the subject. Examples of intermittent focal, intermittent segmental, intermittent generalized dystonia or focal dystonia evolving to become segmental or generalized can be found in many cases of PxD in dogs (see Videos S1–S3). An example of constant focal dystonia can be found in spastic paresis of cattle (discussed later in this review; Video S4). In the evolution of tetanus cases, dystonia may progress to constant segmental and generalized dystonia. However, the more comprehensive and specific term of tetanus is preferred to describe these cases. Constant “primary” dystonia (focal, segmental, or generalized) has not been reported in veterinary medicine.

The second suggested classification consistent with human medical literature and with the classification of epilepsy in dogs, is based on etiology. Dystonia can be classified as structural (Figure 2) when a lesion of the nervous system is found, genetic “confirmed” when a genetic cause is confirmed or “suspected” when a genetic cause is suspected, reactive (when dystonia is the result of metabolic or toxic disorders) or unknown.^{5,12} We believe too little information on dystonia in veterinary species currently is available to justify the term idiopathic. The use of the term idiopathic eventually may be indicated when extensive investigations have been performed to exclude other possible causes in a breed for which no indications of genetic causes exist.

4 | PHENOMENOLOGY

Dystonia is characterized by sustained or intermittent involuntary muscle contractions causing abnormal (often repetitive) movements, postures, or both.^{1-4,6-8} Dystonic postures or movements typically are patterned, cause twisting (torsion) of a body part and may be associated with trembling of the affected body part because of concurrent activation of antagonistic muscles.^{2,5,8,10} Patterned refers to a recognizable repetitive recurrence of the posture or movements. Although sometimes difficult to confirm in veterinary patients, dystonia can be initiated or worsened by voluntary action.¹³ Mainly noted in human patients but likely of relevance to veterinary species, considerable variability of speed of onset and development of dystonic movements exists. Dystonic movements may be very short-lived (<1 to several seconds) whereas dystonic postures are typically longer in duration (minutes to hours).¹³ Intermittent worsening, although difficult to detect in veterinary species sometimes, also is possible.²⁻⁴ Persistent dystonic posturing as reported in affected humans has not yet been described in veterinary species. As a feature of PxD, dystonia is limited in duration and might recur in short successive episodes, or with longer intervening periods of normality. A rapid onset or resolution of dystonia may prompt an owner to suspect epileptic seizures. Slow

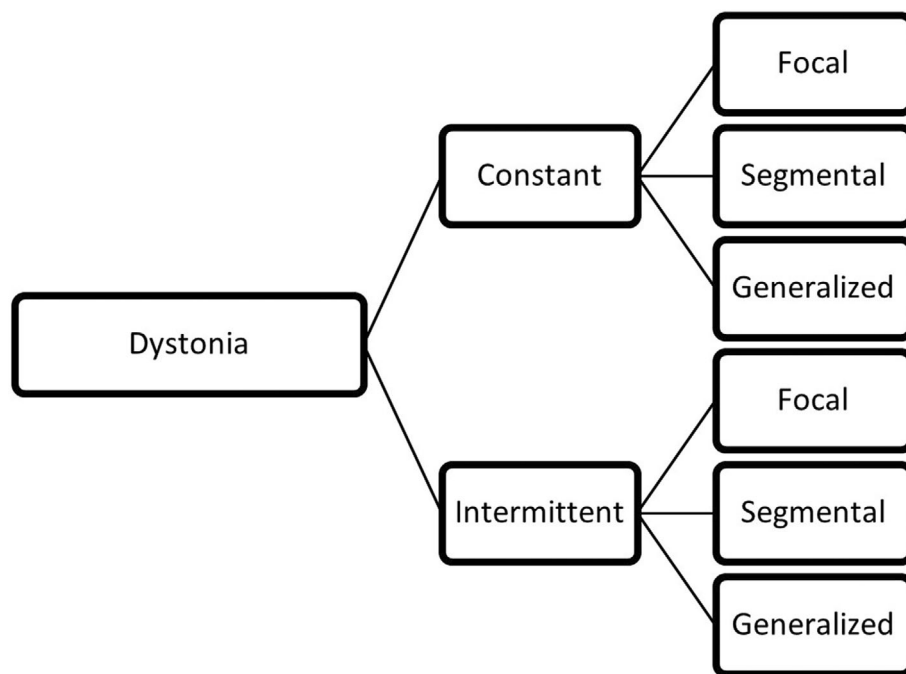


FIGURE 1 Classification algorithm of dystonia based on temporal pattern and localization

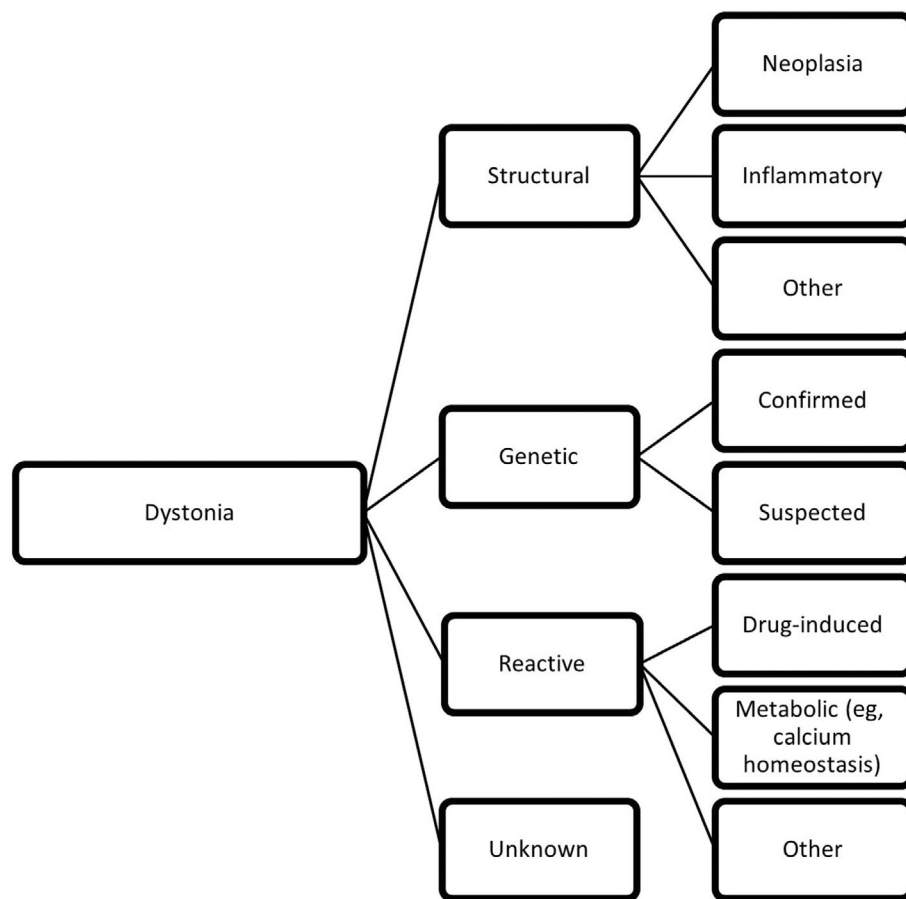


FIGURE 2 Classification algorithm of dystonia based on etiology

onset, combined with mild severity, may result in an episode going unnoticed. The body parts affected by dystonia usually, but not always, are consistent in an individual patient, but variable among patients, even when the same cause is identified, such as in

genetically confirmed cases of dyskinesia.^{1,5} The descriptors focal, segmental, multifocal, unilateral, or multifocal may be added in descriptions of clinical cases, although identifying a particular limb that is involved, is likely more useful. We suggest that when

TABLE 1 Checklist for characterizing dystonia

Dystonia phenomenology checkpoint	Example based on the case of Video S1
Activity being performed at onset (or any other particular circumstances or “trigger”)	Rest (wakeful, usually lying down or just getting up)
Body distribution	The right thoracic limb is affected
Duration	Between 15 s and 5 min
Responsiveness	Able to respond to auditory cues, owner commands and tries to walk during an episode
Severity	Fairly consistent and representative of what is seen in the video. The right thoracic limbs are still somewhat capable to support weight and be used for ambulation
Temporal pattern	Paroxysmal: episodes themselves abruptly start, severity may wax and wane during the event, and abruptly ceases eventually
The presence or lack of autonomic signs	No autonomic signs reported
The presence or lack of preceding signs	No preceding signs reported
The presence or lack of signs following the subsidence of dystonia	Seeks attention of owner
Coexistence of other movement disorders	None reported
Other neurological manifestations	The dog has (presumed idiopathic) epilepsy and is treated with phenobarbital 2.5 mg/kg q12h
Possible links to administered medications, intoxications or other	Signs of dystonia were first noticed after start of treatment with phenobarbital

Note: In the first column, factors or “checkpoints” to take into account when describing the phenomenology of a patient with dystonia are listed. In the second column, an example of outputs is given for the case seen in Video S1.

describing the phenomenology of dogs with dystonia, the following should be included: activity being performed at onset (e.g., resting, running, or exercise-induced), body distribution, duration, responsiveness, severity, temporal pattern (i.e., paroxysmal or persistent, severity at onset and at later stages), the presence or lack of autonomic signs (e.g., salivation), the presence or lack of preceding signs (e.g., restlessness), the presence or lack of signs after resolution of dystonia (e.g., sleepiness), coexistence of other movement disorders, and other neurologic manifestations.^{1,14} A checklist is provided in Table 1. Owners may be prompted to add their perception of whether or not the dog is responsive. Videos are very useful when evaluating a patient with PxD characterized by dystonia. Certain aspects always must be evaluated subjectively, but the subjective assessment of responsiveness (a less specific term than “consciousness”) is nonetheless important

when differentiating between PxD and epileptiform seizures. Additional information, such as signalment and age at onset, should be included.

5 | PATHOPHYSIOLOGY

Much remains unknown regarding the pathophysiology of the clinical sign of dystonia. Dystonia referring to either hypo- or hypertonicity of muscles may arise at various levels, including the central nervous system (CNS), peripheral nervous system (PNS), neuromuscular junction and muscles. The CNS usually is implicated, but the PNS also can be involved. Indeed, the role of other components of the nervous system and effector organs (i.e., muscles) also should be considered when selecting diagnostic tests and treatment modalities in clinical patients. The alpha-motor neurons (lower motor neurons) in the ventral gray horns of the spinal cord (i.e., final common pathway) always are involved in transmitting signals from higher order neurons (upper motor neurons) to the muscles. The activity of these neurons, signal transmission, and the activity of the muscles can be modulated or disrupted to ameliorate the clinical signs of disorders featuring dystonia. Examples include the reported positive effect of anti-seizure medications and muscle-relaxing drugs such as diazepam on the severity and duration of PxD in dogs.^{1,15-18} Another example is treatment of spastic paresis in cattle by partial tibial neurectomy. The recent consensus report on dyskinesias in dogs discusses neuroanatomic structures involved in the control of movement and posture, in particular the basal nuclei (e.g., caudate nucleus, putamen) and cerebellum.¹ Lesion in these areas have been correlated with dystonia in animal models and affected humans.³ When considering the pathophysiology of dystonia in PxD, identification of genetic causes of PxD with dystonia as a feature has helped formulate hypotheses to explain the occurrence of dystonia in those cases. However, gene products (proteins) may have several functions (known and unknown) and frequently are expressed not only in the CNS, but also the PNS or other tissues (e.g., muscle). Even when a brain-specific protein is found to be involved (e.g., brevicin resulting from a BCAN mutation in episodic falling syndrome [EFS] in Cavalier King Charles spaniels), the exact mechanisms leading to the clinical manifestation of dystonia are subject to debate.^{1,19}

Regarding dystonia in general, concurrent activation of antagonistic muscles suggests a breakdown of the normal pattern of reciprocal innervation between opposing muscles, and it produces the sustained quality of dystonic movements.¹ The patterned movements that are observed in an affected individual usually are triggered by specific actions or positions of the body. When dystonia is preceded by activity, the process of inducing dystonia with activity in remote body parts is designated as overflow muscle activation. Dystonic movements usually cease during sleep, which suggests a role for the sleep center and associated areas such as the locus coeruleus and thalamic nuclei. However, certain dystonic postures can persist during various sleep stages.^{3,20-22} The severity of dystonic movements or postures may be temporarily ameliorated in human patients by sensory input

TABLE 2 Additional publications (not included in the consensus report on canine dyskinesia¹) related to canine and feline dyskinesia and synopsis of the presented findings^{15–18,71}

Publication	Synopsis
Mandigers PJJ, Van Steenbeek FG, Bergmann W, Vos-Loohuis M, Leegwater PA. A knockout mutation associated with juvenile paroxysmal dyskinesia in Markiesje dogs indicates SOD1 pleiotropy. <i>Hum Genet.</i> 2021 Nov;140(11):1547–1552	Case series—Dystonia was a main feature of this PxD. Clinical signs became apparent around 10 wk of age. Most dogs were euthanized before 3 mo of age. Routine histopathology revealed only mild, random Wallerian-like degeneration in the brain stem and spinal cord with mild denervation atrophy of the skeletal muscle. A frameshift mutation in the superoxide dismutase 1 (SOD1) gene was identified (NM001003035.1: c.12delinsCAC).
Green M, Garosi L, Bessant C, Lowrie M. Phenotypic characterisation of paroxysmal dyskinesia in Sphynx cats. <i>J Feline Med Surg.</i> 2021 Jul 27:1098612X211032123	Case series—The first publication of PxD in cats. All affected cats were <4 y of age at the onset of the episodes. Episodes were characterized by dystonia affecting limbs. Spontaneous resolution was noticed in some cases.
Green S, Olby N. Levetiracetam-responsive paroxysmal exertional dyskinesia in a Welsh Terrier. <i>J Vet Intern Med.</i> 2021 Mar;35(2):1093-1097	Case report—Exercise preceded episodes of up to 30 min duration. Diazepam and levetiracetam were reported as effective in stopping or preventing episodes, respectively.
Packer RA, Wachowiak I, Thomovsky SA, Berg J, Vasquez L, O'Brien DP. Phenotypic characterization of PIGN-associated paroxysmal dyskinesia in Soft-coated wheaten terriers and preliminary response to acetazolamide therapy. <i>Vet J.</i> 2021 Mar;269:105606	Case series—Twenty-five genetically confirmed cases were included. Affected dogs had episodes of involuntary, hyperkinetic movements and dystonia. A single limb was sometimes involved. Duration and frequency were variable. Some episodes were possibly triggered by excitement or stress. Acetazolamide was effective in 9/11 cases were it was prescribed.
Whittaker DE, Volk HA, De Decker S, Fenn J. Clinical characterisation of a novel paroxysmal dyskinesia in Welsh terrier dogs. <i>Vet J.</i> 2022 Feb 9;281:105801. Epub ahead of print	Case series and questionnaire-based study—Clinical presentation and diagnostic findings in 5 cases are documented, with some magnetic resonance imaging abnormalities of uncertain relationship to the paroxysmal dyskinesia. Dogs demonstrated “episodes of dystonia with dyskinesia (writhing or abrupt involuntary limb movements).” Twenty-three percent of 142 dog owners reported presence of signs consistent with dyskinesia featuring dystonia in the questionnaire-part of the study.

(e.g., stroking the affected area).³ Anecdotal reports from pet owners of dogs with PxD suggest similar features in veterinary patients. The neurophysiological explanation for this phenomenon is not known. Although overt neuropathology often is not identified at necropsy suggesting a functional disorder, subtle cell loss or minor structural defects can be overlooked, as shown in rodent models of dystonia.²³ Also, few cases are submitted for histopathologic examination of the CNS and limits to techniques allowing for detailed examinations can be factors influencing the lack of neuropathology identified in cases of dystonia. Some neuroimaging studies in humans have identified minor changes in cases of isolated dystonia. These abnormalities were found in basal ganglia, cerebellum, cerebral cortex, brainstem and thalamus.^{10,24} Despite many different causes and manifestations of dystonia, common pathogenetic mechanisms may underly many cases featuring dystonia. Such similarities exist at several biological levels.³ At the cellular level, irregularities in the dopaminergic system, mitochondrial function and calcium regulation frequently are found.²³ At the anatomical level, the cerebellum and basal ganglia often are suspected to be involved. Global CNS dysfunction, particularly abnormal neuronal plasticity, inhibition and sensorimotor integration, also has been observed. Identifying such shared pathways may provide insight into the mechanisms that underlie etiologically diverse disorders characterized by dystonia and help identify new treatments that may be effective.³

Examples of reactive dystonia (often as a feature of PxD or associated with other neurologic signs) can be found in both the human

and veterinary medical literature.^{21,22,25–29} Suspected drug-induced dystonia has been reported in a dog after propofol administration.²⁷ In addition to gluten-associated dystonia in Border Terriers, other gastrointestinal disorders have been linked to PxD characterized by dystonia.³⁰ Structural causes also may play a role (e.g., syringomyelic dystonia), but remain uncommon in veterinary literature.^{21,28–31}

6 | PAROXYSMAL DYSKINESIAS IN DOGS

After publication of the recent consensus report on PxD in dogs,¹ additional reports on dyskinesias in dogs and cats have been published (Table 2). Examples of PxD characterized by dystonia are EFS in Cavalier King Charles Spaniels (genetic cause identified), PxD reported in Soft-Coated Wheaten Terriers (genetic cause identified) and the PxD named “Scottie Cramp” (genetic cause suspected).^{19,32,33} Although most reports focus on particular breeds exhibiting PxD, cases of PxD in mixed breed dogs are anecdotally recognized and reported.¹¹

7 | DRUG-INDUCED DYSTONIA

Propofol-induced dystonic movements have been reported anecdotally in dogs (so-called “propofol shakes”). The nature of these shakes

(epileptiform or not) is unknown. A single case report describes propofol-induced dystonia in a Golden Retriever.²⁷ The action of propofol on CNS structures likely is involved. Many other drugs or toxins may affect regulation of muscle tone, including those acting centrally (e.g., tetanospasmin) and those acting peripherally (e.g., acetylcholinesterase inhibitors). Reports on drug-induced dystonia as a feature of PxD are limited, but its occurrence is possible and clinicians should assess the relationship of suspected clinical signs to ingested substances or prescribed medications. Phenobarbital-associated dyskinesia has been reported, but twitching was the main clinical sign in that case.³⁴ Extrapyramidal signs in humans, dogs and horses including dystonia have been reported to occur after the use of various anesthetic (including propofol), antipsychotic, dopamine-blocking opioid, antiemetic and sedative drugs (phenothiazine derivatives such as fluphenazine).³⁵⁻³⁷ These are important considerations for any patient with dystonia occurring after administration or inadvertent exposure to such drugs.

8 | MOVEMENT DISORDERS IN OTHER SPECIES WITH DYSTONIA A FEATURE

8.1 | PxD in cats

We have identified dystonia as a feature in PxD in cats. A single scientific publication describing PxD in cats (Sphynx cats) is available, and dystonia was the main feature of that case.¹⁵ The recent publication on Sphynx cats documented abnormal posture and stiffness in 10/10 and 8/10 cases, respectively.¹⁵ The authors considered PxD in these cats comparable to paroxysmal kinesigenic dyskinesia (PKD) in humans, typified by dystonic attacks.^{38,39} These descriptions along with footage of affected cases justify the use of the term dystonia, and dyskinesia of cats may be referred to as a PxD characterized by dystonia.

8.2 | Bovine spastic paresis and spastic syndrome

Bovine spastic paresis (BSP or Elso heel) clinically manifests as dystonic posturing of 1 or both pelvic limbs, often exacerbated by attempted movement (Video S4).^{40,41} The description of clinical signs of bovine spastic syndrome (BSS), a similar disorder, shows why the term dystonia may be suitable to describe this disorder⁴²: "... severe signs include prolonged spastic periods, the inability to eat while standing, weight loss, and for breeding bulls the inability to copulate. The spastic contraction of the muscles can last from several seconds to a few minutes or even longer, and the hindlimbs are cramped or flexed and often extended caudally. During flexion, the hindleg may lift laterally from the floor and the spasm is often accompanied by kyphosis."

In BSP, different muscles may be involved, including the gastrocnemius and quadriceps muscles.⁴⁰ Many breeds of cattle are reported to be affected, such as the Holstein-Friesian.^{40,42} The term spastic here refers to disinhibition of extensor motor neurons resulting in

dystonia (hypertonia or increased muscle tone) clinically noticeable as stiffness in gait, typical postures (e.g., extended pelvic limb) and resistance to passive manipulation. Lesions in the CNS and genetic mutations have been found in affected cattle.⁴⁰⁻⁴⁵ Several genetic studies have reported findings that have provided insight into the pathogenesis of these disorders. In BSP, treatment, when attempted, is mostly surgical, focusing on the effectors of the clinical signs: the involved nerves (e.g., tibial nerve in the case of gastrocnemius muscle involvement; tibial neurectomy) or muscles and tendons (e.g., the gastrocnemius tendon; tenotomy or tenectomy). In some cases, tibial neurectomy may result in adequate relief of clinical signs and resumption of milk production.⁴¹ However, breeding affected animals or their offspring is not advisable because a genetic cause is responsible.

8.3 | Stringhalt and nigropallidal encephalomalacia in horses

Stringhalt, also referred to as equine reflex hypertonia (ERH), is characterized by dystonic movements primarily of the pelvic limbs, either bilaterally or unilaterally (Video S5). Two forms are reported: idiopathic (classic or sporadic) and acquired (epidemic or plant-associated).^{46,47} The latter is related to plant toxins affecting the PNS. The pathogenesis of the idiopathic form is largely unknown. Although the term ERH is used in the literature, it may not be the best descriptive term because reflexes themselves cannot be hypertonic. Diagnostic tests usually are focused on finding any possible associated disorders and treatable causes and excluding the acquired form (i.e., excluding access to plants associated with that form, such as the Australian or European dandelion).⁴⁶ In some cases, trauma is suspected to be associated with the occurrence of clinical signs. Spontaneous resolution is possible. Chewing-like jaw movements and dystonia of facial and tongue muscle is a feature of equine nigropallidal encephalomalacia, the plant-associated toxic encephalopathy also sometimes referred to as equine parkinsonism although it is not the same as Parkinson's disease in humans.⁴⁸ Dystonia of the facial muscles result in a wooden expression, which is reminiscent of people with parkinsonism who struggle to express emotions with facial musculature.⁴⁹⁻⁵¹ However, the pathomechanism of the resultant facial expression may not be the same. In horses, a problem seems to occur in facial muscle tone regulation (i.e., dystonia). Structures mainly affected are the globus pallidus and substantia nigra. This disease is an example of a direct link between pathology of the basal nuclei and clinical manifestations of dystonia.

8.4 | Other

Many laboratory animal species, mainly rodents but also primates, serve as research models for dystonia.^{23,52-57} Several genetic models have improved knowledge of the pathophysiology of dystonia or have provided insights into possible treatment modalities, including deep brain stimulation. The dystonic rat (dt rats), dystonic (Syrian) hamster

(dtsz hamster), and tottering mouse are examples of rodent models on which considerable literature is available.^{23,52-57} Although these species (with specific mutations in most cases) are unlikely to be presented to clinicians, these affected species provide insight relevant to clinicians.

9 | DIAGNOSTIC AND TREATMENT CONSIDERATIONS

Dystonia is a clinical sign rather than a disorder in itself. A possible exception is primary dystonia as reported in human medicine. Aside from BSP, analogous veterinary disorders are yet to be described in detail. Diagnostic testing is useful to identify any underlying causes of dystonia and characterize the disorder in more detail. Descriptions of the use of electrophysiological diagnostic testing in dystonia patients are available in veterinary literature.²⁸ In human medicine, electromyography and electroencephalography findings are reported in patients with specific types of dystonia.^{20,22,58-61} Considering the implications of brain structures in the pathogenesis of PxD in dogs and a differential diagnosis list that includes epilepsy in many cases, diagnostic tests such as those proposed in the consensus report on canine epilepsy should be considered.⁶² However, in most movement disorder cases, a structural lesion is not found and a functional disorder is suspected. The phenomenology is vital in establishing a suspected diagnosis of PxDs in dogs.¹ Differential diagnoses for PxDs (often characterized by dystonia) and their differentiating characteristics are largely based on phenomenology and have been discussed in other reviews and include syncope, PxD and other movement disorders, narcolepsy, cataplexy, neuromuscular weakness, paroxysmal behavioral disorders (compulsive disorders), vestibular dysfunction and epileptic seizures.^{1,8,35} The clinical sign of dystonia itself should be differentiated from similar clinical signs that can have similar phenomenology consisting of sustained or intermittent involuntary muscle contractions causing abnormal (often repetitive) movements, postures, or both. For instance, a dog with severe lameness may hold a limb in a flexed position off the ground, but does so voluntarily and the dystonia may be countered intermittently by the dog or by manipulation of the limb by the owner or clinician. Mechanical causes for abnormal limb positions, such as coxofemoral luxation, also will result in sustained abnormal positioning, but upon careful clinical examination may be easily differentiated from dystonia. A dog presented with spinal shock and Schiff-Sherrington posturing as a consequence of acute myelopathy caused by thoracolumbar intervertebral disc extrusion will have dystonia of the pelvic limbs (hypotonia) as well as thoracic limbs (extensor hypertonia). In such a case, the cause of the dystonia will be found after neuroanatomical localization based on the clinical signs of dystonia in addition to other neurological deficits and appropriate diagnostic tests (e.g., diagnostic imaging). In such cases, specific differential diagnostic considerations will not be needed for the clinical sign of dystonia.

Various medical treatments have been reported for dogs with PxD featuring dystonia with variable results.¹ These variable results are not surprising when the pathogenesis of dystonia (which is largely

unknown) is kept in mind. Indeed, treatment of affected human patients is largely based on clinical experience and trial and error.⁶³ Because CNS structures are implicated and PxD bears resemblance to epilepsy, the use of anti-seizure medication (ASM) has been of particular interest. Some patients with PxD are responsive, leading to descriptions of phenobarbital-responsive PxD, levetiracetam-responsive PxD or more general anticonvulsant responsive PxD.^{17,64} Other effective treatments are reported for specific cases or breed-related PxD (eg, acetazolamide-responsive PxD).^{18,65} The use of clonazepam in EFS has been reported to be effective in many cases.^{9,66} Although these reports provide some empirical evidence for possible efficacy, no clear recommendations can be made for the treatment of PxD featuring dystonia at this time. Also, spontaneous remission is a possibility and has been noted to occur in several breeds of dogs with PxD, which impacts ability to accurately assess whether or not treatment is efficacious or if clinical signs have disappeared spontaneously. Regarding intermittent dystonia, treatment may not be necessary when episodes are infrequent, short in duration or both. When deemed necessary, the existing literature should be consulted for reports providing empirical evidence for the effectiveness of specific medications in specific breeds, species or types of movement disorders (e.g., PKD featuring dystonia in a Welsh terrier may lead to a trial of levetiracetam based on empirical evidence of effectiveness¹⁷). Most reports however are single case reports, case series or cohort studies and effectiveness usually is gauged from reports of owners. Regarding constant dystonia, treatment is likely to be necessary, and constant focal dystonia (eg, BSP) may lead to considerations of disrupting signal transmission or effector organ (muscle) function by surgical means. Of note, drug-induced extrapyramidal signs in humans, dogs and horses have been treated successfully using anticholinergic or antihistamine drugs such as chlorphenamine, diphenhydramine and benzotropine.^{35,36,46} Inciting drugs and drugs used for treatment are postulated to exert their effects by influencing monoamine (e.g., dopamine) neurotransmitter receptors. These observations may be considered for treatment of nondrug-induced dystonia cases, but no large studies on dogs with PxD characterized by dystonia and treated with such medications are available. Gluten-free diets are indicated for Border Terriers with confirmed or suspected paroxysmal gluten-associated dyskinesia and may be considered for other (typically small breed or terrier) dogs with PxD.^{1,7,67} Finally, electrical deep brain stimulation (of basal nuclei for instance) has been implemented in some animal models.⁶⁸⁻⁷⁰

10 | SHORT CASE DISCUSSIONS

10.1 | Case 1—Video S1

A mixed breed dog (6-year-old, female neutered) was presented for recurrent episodes of right thoracic limb dystonia. This dystonia was variable in duration (seconds to minutes) and severity (as seen in the video, the dog was intermittently able to use the limb for ambulation or weight bearing). This dog was treated for presumptive idiopathic epilepsy with phenobarbital and although generalized tonic-clonic seizures had abated, episodes of thoracic limb dystonia had been noticed since treatment was started. See Table 1 for a detailed description of

the phenomenology of the dystonia seen in this patient. Differential diagnoses considered for this case were focal epileptic seizure activity, phenobarbital-induced PxD or idiopathic PxD. Treatment with phenobarbital was continued and frequency of limb dystonic movements gradually decreased over the next weeks to months. The dystonia was not considered to be sufficient reason to taper treatment with phenobarbital for the presumptive idiopathic epilepsy because it was satisfactorily controlled.

10.2 | Case 2—Video S2

A Labrador retriever (2-year-old male) was presented for paroxysmal episodes characterized by recurrent episodes of dystonia mostly affecting the cranial aspect of the body (thoracic trunk, thoracic limb and cervical muscles) while remaining responsive to the environment. The dystonia was variable in duration (3–10 minutes), but fairly consistent in severity. Although the cranial aspect of the dog was mostly affected, pelvic limbs were noticed to progressively be involved toward the end of an episode (not included in the video) before fairly abruptly ending, possibly meriting classification as a segmental dystonia evolving to become generalized. Differential diagnoses such as epileptic seizures were dismissed because of clear signs of responsiveness to the owners during an episode (notice the tail wagging after verbal responses from the owner—audio not included).

10.3 | Case 3—Video S3

A Border terrier (8-year-old, female neutered) was presented for paroxysmal episodes characterized by recurrent generalized dystonia. The dystonia was variable in duration (minutes), but fairly consistent in severity. The entire body (with exception of the facial muscles) was involved. The dog was able to remain standing and ambulate short distances with a high-stepping and dysmetric gait. Episodes started suddenly and regressed quickly after a duration of 5–7 minutes. This dog was on a gluten-free diet, but had possibly ingested a sandwich. The main differential diagnosis was paroxysmal gluten-associated dyskinesia. A response to gluten-free diet or occurrence of dyskinesia or dystonia after a (natural) challenge may be taken as preliminary evidence for this diagnosis and makes it more likely. Serological testing is available, and, although not performed in this case, may further corroborate the diagnosis.

10.4 | Case 4—Video S4

A Holstein-Friesian heifer (1-year-old) was presented for progressive difficulty ambulating with the left pelvic limb. Extension of the tarsus because of dystonia of the tarsal extensor muscles can be seen when the cow is viewed from the side. This extension had been noticed at an early age, progressed for a while and then had become static for the last few months and thus was constantly present. Lameness secondary to peritarsal bursitis and cellulitis also was present and presumed secondary to prolonged recumbency.

Bursitis had not been present upon evaluation some weeks earlier. Clinical examination disclosed continuous hypertonia of the gastrocnemius muscle of the left pelvic limb. The main differential diagnosis was BSP. Differential diagnoses such as patellar luxation or myositis were dismissed based on the clinical findings. The cow was treated surgically by partial tibial neurectomy, with improvement of clinical signs after surgery.

10.5 | Case 5—Video S5

A Royal Dutch Sport Horse mixed Arabian was presented for subacute progressive right pelvic limb dystonic movements. Dystonic movements of the right pelvic limb are evident on the videos, characterized by hyperflexion of all joints, variable in duration. The movements occurred mostly when ambulating on solid ground and were less apparent when on soft ground (eg, sand) or increasing speed to trot and canter. The typical expression of clinical signs was interpreted as stringhalt (which is not a specific diagnosis, but the name given to this clinical phenomenon in horses). The unilateral presentation and lack of access to toxic plants was suggestive of the idiopathic (classic or sporadic) form. The clinical signs waned over the next weeks.

11 | CONCLUSION

The clinical sign of dystonia in veterinary species is recognized in many disorders, but is particularly noticeable in dogs with PxD. Recently reported cases of PxD in cats also are characterized by dystonia. Additionally, some disorders of large animals, such as BSP and nigropallidal encephalomalacia in horses (in part) are characterized by dystonia. We propose adherence to descriptive terminology and inclusion of standard descriptors to document affected cases. Future studies focusing on clinical characteristics, etiologies, diagnostic testing and treatment modalities will serve to fill the gaps in our understanding of these enigmatic disorders.

ACKNOWLEDGMENT

Funding provided by University Utrecht Open Access Publishing Funding.

CONFLICT OF INTEREST DECLARATION

Authors declare no conflict of interest.

OFF-LABEL ANTIMICROBIAL DECLARATION

Authors declare no off-label use of antimicrobials.

INSTITUTIONAL ANIMAL CARE AND USE COMMITTEE (IACUC) OR OTHER APPROVAL DECLARATION

Authors declare no IACUC or other approval was needed.

HUMAN ETHICS APPROVAL DECLARATION

Authors declare human ethics approval was not needed for this study.

ORCID

Koen M. Santifort  <https://orcid.org/0000-0001-7552-216X>

Paul J. J. Mandigers  <https://orcid.org/0000-0003-2547-6673>

REFERENCES

- Cerda-Gonzalez S, Packer RA, Garosi L, et al. International veterinary canine dyskinesia task force ECVN consensus statement: terminology and classification. *J Vet Intern Med.* 2021;35:1218-1230.
- Albanese A. The clinical expression of primary dystonia. *J Neurol.* 2003;250:1145-1151.
- Balint B, Bhatia KP. Dystonia: an update on phenomenology, classification, pathogenesis and treatment. *Curr Opin Neurol.* 2014;27:468-476.
- Tarsy D, Simon DK. Dystonia. *N Engl J Med.* 2006;355(8):818-829.
- Albanese A, Bhatia K, Bressman SB, et al. Phenomenology and classification of dystonia: a consensus update. *Mov Disord.* 2013;28(7):863-873.
- Lowrie M, Garosi L. Natural history of canine paroxysmal movement disorders in Labrador retrievers and Jack Russell terriers. *Vet J.* 2016;213:33-37.
- Lowrie M, Garosi L. Classification of involuntary movements in dogs: paroxysmal dyskinesias. *Vet J.* 2017;220:65-71.
- Richter A, Hamann M, Wissel J, Volk HA. Dystonia and paroxysmal dyskinesias: under-recognized movement disorders in domestic animals? A comparison with human dystonia/paroxysmal dyskinesias. *Front Vet Sci.* 2015;30:65.
- Urkasemsin G, Olby NJ. Canine paroxysmal movement disorders. *Vet Clin North Am Small Anim Pract.* 2014;44(6):1091-1102.
- Jankovic J, Hallett M, Okun MS, et al. *Principles and Practice of Movement Disorders.* 3rd ed. St. Louis, MO: Elsevier; 2021.
- Santifort KM, Lowrie M. Paroxysmal non-kinesigenic dyskinesia characterised by dystonia in a crossbred dog. *Vet Rec Case Rep.* 2017;5(4):e000429.
- Berend M, Farquhar RG, Mandigers PJ, et al. International veterinary epilepsy task force consensus report on epilepsy definition, classification and terminology in companion animals. *BMC Vet Res.* 2015;28:182.
- Morgante F, Klein C. Dystonia. *Continuum (Minneapolis).* 2013;19(5 Movement Disorders):1225-1241.
- Thompson VB, Jinnah HA, Hess EJ. Convergent mechanisms in etiologically-diverse dystonias. *Expert Opin Ther Targets.* 2011;15(12):1387-1403.
- Green M, Garosi L, Bessant C, et al. Phenotypic characterisation of paroxysmal dyskinesia in Sphynx cats. *J Feline Med Surg.* 2021;27:1098612X211032123.
- Mandigers PJJ, Van Steenbeek FG, Bergmann W, et al. A knockout mutation associated with juvenile paroxysmal dyskinesia in Markiesje dogs indicates SOD1 pleiotropy. *Hum Genet.* 2021;140(11):1547-1552.
- Green S, Olby N. Levetiracetam-responsive paroxysmal exertional dyskinesia in a Welsh Terrier. *J Vet Intern Med.* 2021;35(2):1093-1097.
- Packer RA, Wachowiak I, Thomovsky SA, Berg J, Vasquez L, O'Brien DP. Phenotypic characterization of PIGN-associated paroxysmal dyskinesia in Soft-coated wheaten terriers and preliminary response to acetazolamide therapy. *Vet J.* 2021;269:105606.
- Gill JL, Tsai KL, Krey C, et al. A canine BCAN microdeletion associated with episodic falling syndrome. *Neurobiol Dis.* 2012;45(1):130-136.
- Berardelli A, Rothwell JC, Hallett M, et al. The pathophysiology of primary dystonia. *Brain.* 1998;121:1195-1212.
- Berg JM, Joseph RJ. Cerebellar infarcts in two dogs diagnosed with magnetic resonance imaging. *J Am Anim Hosp Assoc.* 2003;39(2):203-207.
- Borgeat A, Dessibourg C, Popovic V, Meier D, Blanchard M, Schwander D. Propofol and spontaneous movements: an EEG study. *Anesthesiology.* 1991;74(1):24-27.
- Richter F, Richter A. Genetic animal models of dystonia: common features and diversities. *Prog Neurobiol.* 2014;121:91-113.
- Stassen QEM, Koskinen LLE, van Steenbeek FG, et al. Paroxysmal dyskinesia in border terriers: clinical, epidemiological, and genetic investigations. *J Vet Intern Med.* 2017;31(4):1123-1131.
- Brewer GJ. Wilson disease and canine copper toxicosis. *Am J Clin Nutr.* 1998;67(5 Suppl):1087S-1090S.
- Lowrie M, Garden OA, Hadjivassiliou M, Sanders DS, Powell R, Garosi L. Characterization of paroxysmal gluten-sensitive dyskinesia in border terriers using serological markers. *J Vet Intern Med.* 2018;32(2):775-781.
- Mitek AE, Clark-Price SC, Boesch JM. Severe propofol-associated dystonia in a dog. *Can Vet J.* 2013;54(5):471-474.
- Pancotto TE, Rossmeisl JH Jr. A case of stiff dog syndrome associated with anti-glutamic acid decarboxylase antibodies. *J Clin Mov Disord.* 2017;10:5.
- Thomsen B, Garosi L, Skerritt G, et al. Neurological signs in 23 dogs with suspected rostral cerebellar ischaemic stroke. *Acta Vet Scand.* 2016;7:40.
- Poirier-Guay MP, Bélanger MC, Frank D. Star gazing in a dog: atypical manifestation of upper gastrointestinal disease. *Can Vet J.* 2014;55(11):1079-1082.
- Silva-Júnior FP, Santos JG, Sekeff-Sallem FA, et al. Cervical and axial dystonia in a patient with syringomyelia. *Arq Neuropsiquiatr.* 2012;70(9):742-743.
- Kolichski AL, Johnson GS, Mhlanga-Mutangadura T, et al. A homozygous PIGN missense mutation in soft-coated wheaten terriers with a canine paroxysmal dyskinesia. *Neurogenetics.* 2017;18(1):39-47.
- Urkasemsin G, Olby NJ. Clinical characteristics of Scottie Cramp in 31 cases. *J Small Anim Pract.* 2015;56(4):276-280.
- Kube SA, Vernau KM, LeCouteur RA. Dyskinesia associated with oral phenobarbital administration in a dog. *J Vet Intern Med.* 2006;20(5):1238-1240.
- Frias JM, Michou J, Fadda A. Chlorphenamine for prolonged drug-induced extrapyramidal side effects in a dog. *Vet Rec Case Rep.* 2020;8(4):e001205.
- Baird JD, Arroyo LG, Vengust M, et al. Adverse extrapyramidal effects in four horse given fluphenazine decanoate. *J Am Vet Med Assoc.* 2006;229:104-110.
- Caroff SN, Campbell EC. Drug-induced extrapyramidal syndromes: implications for contemporary practice. *Psychiatr Clin.* 2016;39(3):391-411.
- Demirkiran M, Jankovic J. Paroxysmal dyskinesias: clinical features and classification. *Ann Neurol.* 1995;38(4):571-579.
- Bruno MK, Hallett M, Gwinn-Hardy K, et al. Clinical evaluation of idiopathic paroxysmal kinesigenic dyskinesia: new diagnostic criteria. *Neurology.* 2004;63(12):2280-2287.
- De Vlamynck C, Pille F, Vlaminck L. Bovine spastic paresis: current knowledge and scientific voids. *Vet J.* 2014;202(2):229-235.
- De Vlamynck C, Pille F, Vlaminck L. Long term outcome of conservative management or surgical treatment of bovine spastic paresis: 79 cases. *Vet Surg.* 2016;45(2):187-193.
- Goeckmann V, Rothhammer S, Medugorac I. Bovine spastic syndrome: a review. *Vet Rec.* 2018;182(24):693.
- Goeckmann V, Rothhammer S, Medugorac I. Bovine spastic paresis: a review of the genetic background and perspectives for the future. *Vet J.* 2016;216:64-71.
- Krull F, Hirschfeld M, Wemheuer WE, Brenig B. Frameshift variant in novel adenosine-A1-receptor homolog associated with bovine spastic syndrome/late-onset bovine spastic paresis in Holstein sires. *Front Genet.* 2020;11:591794.
- Pariset L, Bongiorno S, Bueno S, et al. Microarray gene expression profiling of neural tissues in bovine spastic paresis. *BMC Vet Res.* 2013;9:122.
- Dawson DR. Toxins and adverse drug reactions affecting the equine nervous system. *Vet Clin North Am Equine Pract.* 2011;27(3):507-526.

47. de Lahunta A, Glass EN, Kent M. *de Lahunta's Veterinary Neuroanatomy and Clinical Neurology*. 4th ed. Philadelphia, PA: Elsevier Saunders; 2020.
48. Chang HT, Rumbleiha WK, Patterson JS, Puschner B, Knight AP. Toxic equine parkinsonism: an immunohistochemical study of 10 horses with nigropallidal encephalomalacia. *Vet Pathol*. 2012;49(2):398-402.
49. Furr M, Reed S. *Equine Neurology*. 2nd ed. Hoboken, NJ: John Wiley & Sons; 2015.
50. Bologna M, Fabbrini G, Marsili L, Defazio G, Thompson PD, Berardelli A. Facial bradykinesia. *J Neurol Neurosurg Psychiatry*. 2013;84(6):681-685.
51. Bono AD, Twaite JT, Krch D, et al. Mood and emotional disorders associated with parkinsonism, Huntington disease, and other movement disorders. *Handb Clin Neurol*. 2021;183:175-196.
52. Guehl D, Cuny E, Ghorayeb I, Michelet T, Bioulac B, Burbaud P. Primate models of dystonia. *Prog Neurobiol*. 2009;87(2):118-131.
53. Campbell DB, Hess EJ. L-type calcium channels contribute to the tottering mouse dystonic episodes. *Mol Pharmacol*. 1999;55(1):23-31.
54. Erickson MA, Haburčák M, Smukler L, Dunlap K. Altered functional expression of Purkinje cell calcium channels precedes motor dysfunction in tottering mice. *Neuroscience*. 2007;150(3):547-555.
55. Wahnschaffe U, Fredow G, Heintz P, Löscher W. Neuropathological studies in a mutant hamster model of paroxysmal dystonia. *Mov Disord*. 1990;5(4):286-293.
56. LeDoux MS. Animal models of dystonia: lessons from a mutant rat. *Neurobiol Dis*. 2011;42(2):152-161.
57. Harnack D, Hamann M, Meissner W, Morgenstern R, Kupsch A, Richter A. High-frequency stimulation of the entopeduncular nucleus improves dystonia in dtsz hamsters. *Neuroreport*. 2004;15(9):1391-1393.
58. Dressler D. Electromyographic evaluation of cervical dystonia for planning of botulinum toxin therapy. *Eur J Neurol*. 2000;7(6):713-718.
59. Jankovic J, Leder S, Warner D, Schwartz K. Cervical dystonia: clinical findings and associated movement disorders. *Neurology*. 1991;41(7):1088-1091.
60. Lugaresi E, Cirignotta F. Hypnogenic paroxysmal dystonia: epileptic seizure or a new syndrome? *Sleep*. 1981;4(2):129-138.
61. Toro C, Deuschl G, Hallett M. Movement-related electroencephalographic desynchronization in patients with hand cramps: evidence for motor cortical involvement in focal dystonia. *Ann Neurol*. 2000;47(4):456-461.
62. De Riso L, Bhatti S, Muñana K, et al. International veterinary epilepsy task force consensus proposal: diagnostic approach to epilepsy in dogs. *BMC Vet Res*. 2015;11:148.
63. Latorre A, Bhatia KP. Treatment of paroxysmal dyskinesia. *Neurol Clin*. 2020;38:433-447.
64. Harcourt-Brown T. Anticonvulsant responsive, episodic movement disorder in a German shorthaired pointer. *J Small Anim Pract*. 2008;49(8):405-407.
65. Royaux E, Bhatti S, Harvey R, Garosi L, Shelton GD, van Ham L. Acetazolamide-responsive paroxysmal dyskinesia in a 12-week-old female golden retriever dog. *Vet Q*. 2016;36(1):45-49.
66. Garosi LS, Platt SR, Shelton GD. Hypertonicity in Cavalier King Charles spaniels. *J Vet Intern Med*. 2002;16:330.
67. Lowrie M, Garden OA, Hadjivassiliou M, et al. The clinical and serological effect of a gluten-free diet in border terriers with epileptoid cramping syndrome. *J Vet Intern Med*. 2015;29(6):1564-1568.
68. Tisch S. Deep brain stimulation in dystonia: factors contributing to variability in outcome in short and long term follow-up. *Curr Opin Neurol*. 2022;35(4):510-517.
69. Loher TJ, Capelle HH, Kaelin-Lang A, et al. Deep brain stimulation for dystonia: outcome at long-term follow-up. *J Neurol*. 2008;255(6):881-884.
70. Aum DJ, Tierney TS. Deep brain stimulation: foundations and future trends. *Front Biosci (Landmark Ed)*. 2018;23(1):162-182.
71. Whittaker DE, Volk HA, De Decker S, et al. Clinical characterisation of a novel paroxysmal dyskinesia in Welsh terrier dogs. *Vet J*. 2022;281:105801.

SUPPORTING INFORMATION

Additional supporting information can be found online in the Supporting Information section at the end of this article.

How to cite this article: Santifort KM, Mandigers PJJ.

Dystonia in veterinary neurology. *J Vet Intern Med*. 2022;36(6):1872-1881. doi:10.1111/jvim.16532