



Title	Lateral lymph node recurrence of rectal cancer with a pathological complete response to chemotherapy confirmed by laparoscopic lateral lymph node dissection : A case report
Author(s)	Wakizaka, Kazuki; Homma, Shigenori; Ichikawa, Nobuki; Yoshida, Tadashi; Matsui, Hiroki; Khor, Lee Wee; Annen, Kazuya; Fukushima, Tsuyoshi; Taketomi, Akinobu
Citation	Asian journal of endoscopic surgery, 15(1), 216-219 <a href="https://doi.org/10.1111/ases.12975">https://doi.org/10.1111/ases.12975</a>
Issue Date	2022-01-02
Doc URL	<a href="http://hdl.handle.net/2115/87638">http://hdl.handle.net/2115/87638</a>
Rights	This is the peer reviewed version of the following article: Wakizaka, K, Homma, S, Ichikawa, N, et al. Lateral lymph node recurrence of rectal cancer with a pathological complete response to chemotherapy confirmed by laparoscopic lateral lymph node dissection: A case report. Asian J Endosc Surg. 2022; 15( 1): 216- 219, which has been published in final form at [Link to final article using the DOI]. This article may be used for non-commercial purposes in accordance with Wiley Terms and Conditions for Use of Self-Archived Versions. This article may not be enhanced, enriched or otherwise transformed into a derivative work, without express permission from Wiley or by statutory rights under applicable legislation. Copyright notices must not be removed, obscured or modified. The article must be linked to Wiley 's version of record on Wiley Online Library and any embedding, framing or otherwise making available the article or pages thereof by third parties from platforms, services and websites other than Wiley Online Library must be prohibited.
Type	article (author version)
File Information	Manuscript without tracked changes.pdf



[Instructions for use](#)

Case report

Title: Lateral lymph node recurrence of rectal cancer with a pathological complete response to chemotherapy confirmed by laparoscopic lateral lymph node dissection: A case report

Authors: Kazuki Wakizaka<sup>1</sup>, Shigenori Homma<sup>2</sup>, Nobuki Ichikawa<sup>2</sup>, Tadashi Yoshida<sup>2</sup>, Hiroki Matsui<sup>2</sup>,

Lee Wee Khor<sup>1</sup>, Kazuya Annen<sup>1</sup>, Tsuyoshi Fukushima<sup>1</sup>, Akinobu Taketomi<sup>2</sup>

Affiliations:

<sup>1</sup>Department of Surgery, Chitose City Hospital, Chitose, Japan

<sup>2</sup>Department of Gastroenterological Surgery I, Hokkaido University Graduate School of Medicine, Sapporo, Japan

Running title: Laparoscopic LLND for LLN recurrence

Contributions:

Kazuki Wakizaka: conceptualization, data curation, and writing the original draft. Shigenori Homma: supervision, writing review, and editing. Nobuki Ichikawa: data curation and supervision. Tadashi

Yoshida: data curation. Hiroki Matsui: data curation. Lee Wee Khor: data curation. Kazuya Annen: data curation. Tsuyoshi Fukushima: supervision. Akinobu Taketomi: project administration, supervision, writing review, and editing. All authors are in agreement with the content of the manuscript.

Corresponding author:

Shigenori Homma,

Department of Gastroenterological Surgery I, Hokkaido University Graduate School of Medicine, Kita

15 Nishi 7, Kita-ku, Sapporo, Hokkaido, 060-8638, Japan

E-mail: [homma.s@nifty.com](mailto:homma.s@nifty.com)

TEL: 011-706-5927

Word count: 1168 words

## Abstract

Lateral lymph node (LLN) metastasis is one of the forms of local recurrence after surgery for lower rectal cancer. We here present a case of LLN recurrence of rectal cancer that was shown by laparoscopic lateral lymph node dissection (LLND) to have a complete pathological response to chemotherapy. A 58-year-old man underwent open low anterior resection for lower rectal cancer. After detection of right LLN recurrence 43 months after the operation, 11 cycles of capecitabine, oxaliplatin, and bevacizumab chemotherapy were administered. Laparoscopic right LLND was performed 55 months after the first operation. Pathological examination revealed no viable tumor cells in the dissected lymph nodes. The patient remains alive without recurrence 61 months after the first surgery and 6 months after laparoscopic LLND. Laparoscopic LLND for LLN recurrence of rectal cancer is feasible and should be considered a valid treatment option.

**Key words:** laparoscopic, lateral lymph node dissection, rectal cancer

## Introduction

Lateral lymph node (LLN) metastasis is one of the forms of local recurrence after surgery for lower rectal cancer (1). Local therapy, such as resection and radiotherapy, or systemic chemotherapy is indicated for recurrence of rectal cancer. With advances in chemotherapy, there have been increasing reports that chemotherapy can achieve complete pathological responses (2). Here, we report a case of LLN recurrence of rectal cancer that was shown by laparoscopic lateral lymph node dissection (LLND) to have a complete pathological response to chemotherapy.

## Case Presentation

A 58-year-old man with rectal bleeding was referred to us for examination. Colonoscopy showed a type 2 tumor in the lower rectum and well to moderately differentiated adenocarcinoma was diagnosed by pathological examination of a biopsy specimen. Enhanced computed tomography (CT) showed no metastases, including lymph node metastases (Figure S1). The clinical stage was cT2N0M0 cStage I according to the Japanese classification of colorectal cancer 8th edition (3). Open low anterior resection and D2 lymph node dissection with covering ileostomy were performed and pathological examination of the operative specimen showed Rb, type 3, 60×45 mm, moderately differentiated tubular adenocarcinoma, pT3 (A:2mm), int, INFb, ly1, v1, pPM0 (150mm), pDM0 (15mm), pRM0 (4mm), pN1 (3/10), pStageIIIa according to the Japanese classification of colorectal cancer 8th edition

(Figure S2)(3). KRAS and NRAS genes were wild type. Adjuvant chemotherapy (2,100 mg capecitabine twice daily on Days 1 to 14 of eight × 21 day cycles) was administered and the ileostomy was closed 9 months after surgery. Laparoscopic ventral hernia repair was performed for an abdominal incisional hernia 31 months after the first operation. A right internal iliac lymph node recurrence was detected by enhanced CT 43 months after the low anterior resection (Figure 1a). Capecitabine plus oxaliplatin (CapeOX) plus bevacizumab chemotherapy (220 mg oxaliplatin and 480 mg bevacizumab on Day 1 and 1,800 mg capecitabine twice daily from Days 1 to 14 of 21 day cycles) was administered for a total of 11 cycles. At this point, enhanced CT showed the lymph node metastasis had decreased in size, and positron emission tomography/CT showed no accumulation in the tumor (Figure 1b and S3). There were no changes in tumor markers including carcinoembryonic antigen and carbohydrate antigen 19-9 during the course. Laparoscopic right LLND was performed 55 months after the first operation (Figure 2). The operation time was 184 minutes and there was no blood loss or intraoperative or postoperative complications. The postoperative length of hospital stay was 10 days. Pathological examination revealed no viable tumor cells in the dissected lymph nodes, and historical effect evaluation of chemotherapy was Grade 3 (Figure S4). The patient is currently receiving adjuvant chemotherapy (2,100 mg capecitabine twice daily from Days 1 to 14 of 21 day cycles) and remains alive without recurrence 61 months after the first surgery and 6 months after laparoscopic LLND.

## Discussion

Advances in preoperative chemoradiotherapy and surgical techniques for total mesenteric excision (TME) and LLND have recently improved rectal cancer outcomes. However, local recurrence reportedly occurs after surgery for rectal cancer in 5% to 10% of patients (4). LLN metastasis is now considered a major form of local recurrence of rectal cancer after curative resection (1). Pathological complete response (pCR) rate has been reported about 10% in rectal cancer with LLN metastasis by neoadjuvant chemoradiation (2). However, there are few studies on the response rate of chemotherapy in LLN recurrence of rectal cancer. Kusters et al. reported that 14% of patients with LLN recurrence of rectal cancer achieved pCR by chemoradiotherapy (5). Thus, treatment for LLN recurrence may be expected to be effective as synchronous LLN metastasis in rectal cancer. The treatment policy for our patient's recurrence in this case was to initially administer chemotherapy and confirm that no other metastatic lesions had appeared before surgery. In our patient, pathological examination showed pCR to chemotherapy: thus, resection may not have contributed to the prognosis. However, resection is the only reliable way of determining whether pCR has been achieved. After extensive chemotherapy, imaging studies showed a LLN as the only evaluable lesion, and it was decided to perform LLND.

Although the importance of LLND in the initial surgery for lower rectal cancer has been reported (6), there are few studies on outcomes of LLND for recurrence (7)(8)(9). Akiyoshi et al. reported that laparoscopic salvage LLND is safe and feasible, because there is minimal blood loss and the procedure

is minimally invasive. However, it may be technically difficult as a result of extensive adhesions caused by previous cancer surgery (9). Even after TME by open surgery, the LLN region is not affected by the first surgery, so if the adhesions around the site of initial surgery can be removed, LLND can be performed as usual. LLND can be performed with a good field of view in a narrow and deep pelvis, and is considered to be safer than open surgery. Although our patient's initial surgery was open low anterior resection, laparoscopic LLND was feasible. In addition, we considered that re-laparotomy would be difficult because mesh had been used to manage an abdominal incisional hernia. Laparoscopic surgery does not require mesh transaction or removal. Thus, we considered that laparoscopic surgery was preferable. As another way of LLND, a totally extraperitoneal approach to laparoscopic LLND may have been a reasonable, less invasive alternative because it would not have been affected by intra-abdominal adhesions (10).

In conclusion, we report a patient with LLN recurrence of rectal cancer that was shown by laparoscopic LLND to have a complete pathological response to chemotherapy. Laparoscopic LLND for LLN recurrence of rectal cancer is feasible and should be considered a valid treatment option even after open surgery.

#### Acknowledgment

We thank Dr Trish Reynolds, MBBS, FRACP, from Edanz Group (<https://en-author->



services.edanz.com/ac) for editing a draft of this manuscript.

#### Conflict of Interest

The authors declare that there are no conflicts of interest.

#### Data availability statement

The data that support the findings of this study are available from the corresponding author upon reasonable request.

#### Ethics statement

This study was conducted in accordance with the Declaration of Helsinki. Written informed consent was obtained from the patient and patient anonymity was preserved.

## References

1. Kim TH, Jeong SY, Choi DH, et al. Lateral lymph node metastasis is a major cause of locoregional recurrence in rectal cancer treated with preoperative chemoradiotherapy and curative resection. *Ann Surg Oncol*. 2008;15(3):729-737.
2. Wong JSM, Tan GHC, Chia CS, et al. Management of synchronous lateral pelvic nodal metastasis in rectal cancer in the era of neoadjuvant chemoradiation: A systemic review. *World J Gastrointest Surg*. 2020;12(5):247-258.
3. Japanese Society for Cancer of the Colon and Rectum, ed. *General Rules for Clinical and Pathological Studies on Cancer of the Colon, Rectum and Anus*. 8th ed. Tokyo: KANEHARA & Co., LTD.; 2013.
4. Nielsen MB, Laurberg S, Holm T. Current management of locally recurrent rectal cancer. *Color Dis*. 2011;13(7):732-742.
5. Kusters M, Bosman SJ, Zoggel DMGI Van, et al. Local Recurrence in the Lateral Lymph Node Compartment : Improved Outcomes with Induction Chemotherapy Combined with Multimodality Treatment. *Ann Surg Oncol*. 2016;23:1883-1889.
6. Nakanishi R, Yamaguchi T, Akiyoshi T, et al. Laparoscopic and robotic lateral lymph node dissection for rectal cancer. *Surg Today*. 2020;50(3):209-216.
7. Park SY, Choi GS, Jun SH, et al. Laparoscopic salvage surgery for recurrent and metachronous

- colorectal cancer: 15 years' experience in a single center. *Surg Endosc.* 2011;25(11):3551-3558.
8. Nagasaki T, Akiyoshi T, Ueno M, et al. Laparoscopic Salvage Surgery for Locally Recurrent Rectal Cancer. *J Gastrointest Surg.* 2014;18(7):1319-1326.
  9. Akiyoshi T, Nagata J, Nagasaki T, et al. Laparoscopic salvage lateral pelvic lymph node dissection for locally recurrent rectal cancer. *Color Dis.* 2015;17(10):O213-O216.
  10. Masubuchi S, Okuda J, Hamamoto H, et al. Totally extraperitoneal approach to laparoscopic lateral lymph node dissection for patients with recurrent lateral pelvic lymph nodes after rectal cancer surgery: a novel technique—M TEP LLND. *Surg Today.* 2019;49(11):981-984.

## Figure legends

### Figure 1

Representative enhanced computed tomography (CT) images. Follow-up CT 43 months after the operation showed right lateral lymph node recurrence (a, arrowhead) dorsal to the right internal iliac artery and vein (a, arrow). After 11 cycles of capecitabine, oxaliplatin, and bevacizumab chemotherapy, the lymph node metastasis had decreased in size (b, arrowhead).

### Figure 2

Laparoscopic view of the right lateral area after lateral lymph node dissection (LLND). Five ports were inserted, comprising an umbilical and upper and lower abdominal quadrants bilaterally. (a)

Laparoscopic view of obturator area after LLND. The obturator nerve has been preserved. The obturator vessels were clipped and divided, whereas the other branches of the internal iliac artery were preserved. The dissected area extended caudally to the level of the tendinous arch. (b) Laparoscopic view at the level of bifurcation of the common iliac artery after LLND. The para-aortic, aortic bifurcation, and right common iliac lymph nodes have been dissected.

## A list of Supporting Information

Figure S1 Enhanced computed tomography image before and after first operation.

Figure S2 Specimen obtained by low anterior resection and pathological findings.

Figure S3 Positron emission tomography/computed tomography image after chemotherapy.

Figure S4 Pathological findings of specimen resected by laparoscopic right lateral lymph node dissection.

#### Figure S1

Enhanced computed tomography before first operation showed a mainly right-sided tumor in the lower rectum (a, arrow) and no lymph node metastases, including in the internal iliac node (b, arrow) or other lateral lymph nodes. There was no obvious swelling of lymph node in the right internal iliac area 37 months after surgery (6 months before LLN recurrence) (c, arrow).

#### Figure S2

Specimen obtained by low anterior resection and pathological findings. Macroscopic findings showed type 2 advanced lower rectal cancer (a and b). Pathological examination showed moderately differentiated tubular adenocarcinoma invading over the muscularis propria with metastases in three of the 10 dissected lymph nodes (c, hematoxylin and eosin staining, original magnification, 10×).

#### Figure S3

After 11 cycles of capecitabine, oxaliplatin, and bevacizumab chemotherapy, positron emission tomography/CT showed no accumulation in the tumor (arrowhead).

#### Figure S4

Pathological findings of specimen resected by laparoscopic right lateral lymph node dissection. No

residual tumor cells were found in the dissected lymph nodes (a). Fat necrosis and myxoid change were found in some of the dissected tissue and were considered to be a result of tumor remission (b).

Figure 1

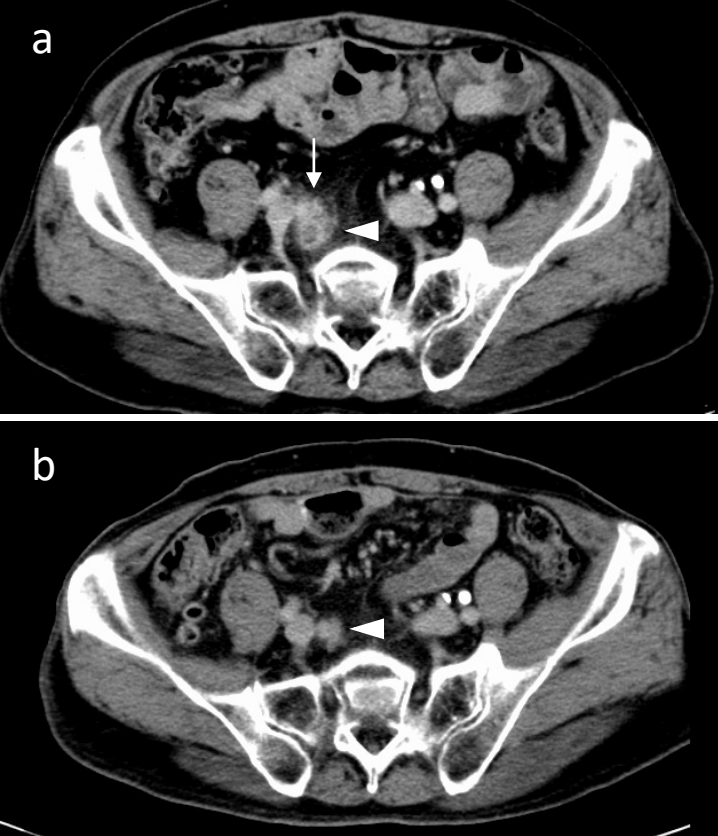




Figure 2

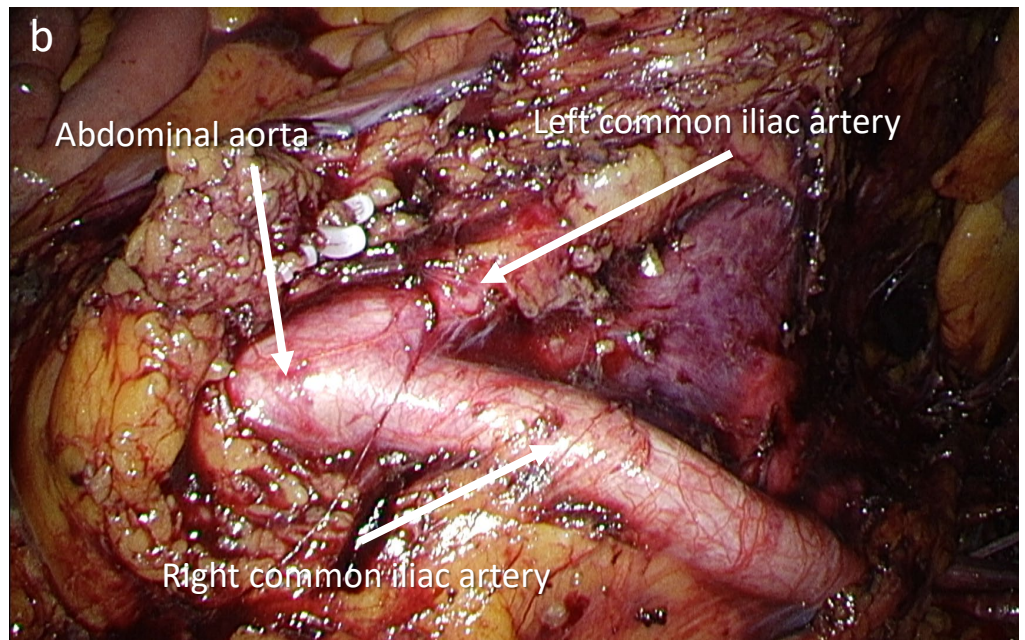
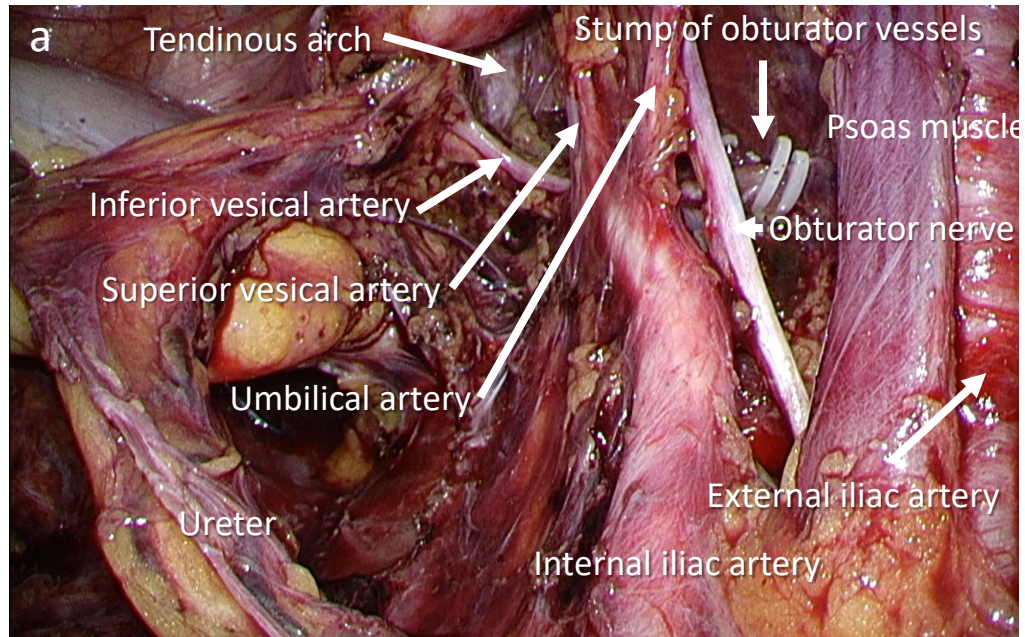


Figure S1

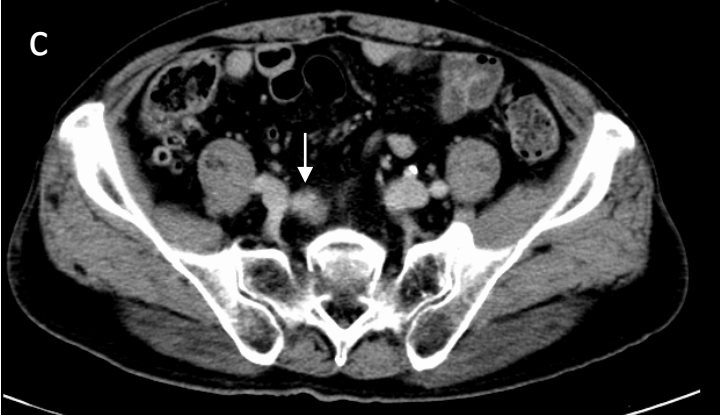
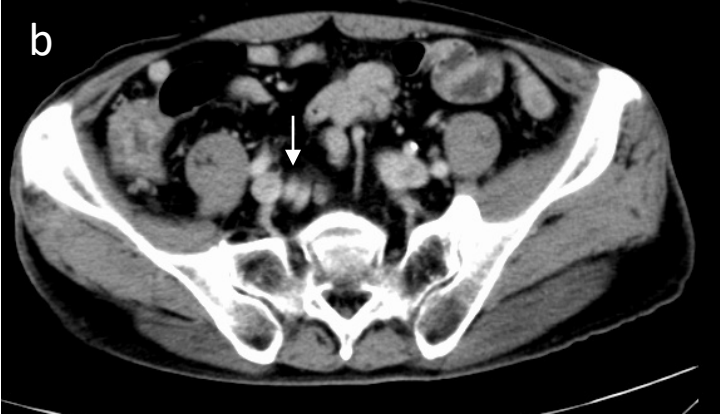
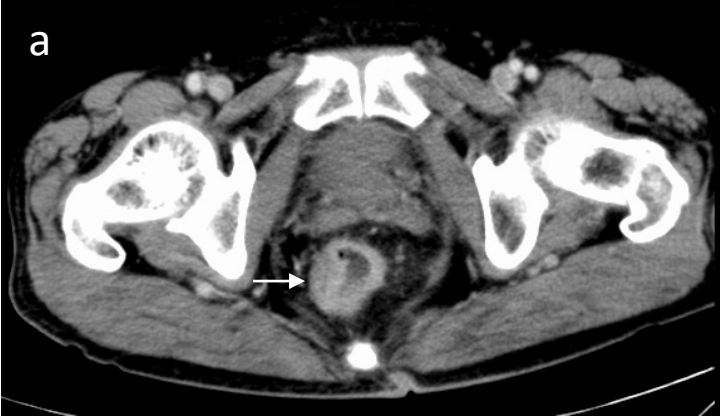
Figure S2

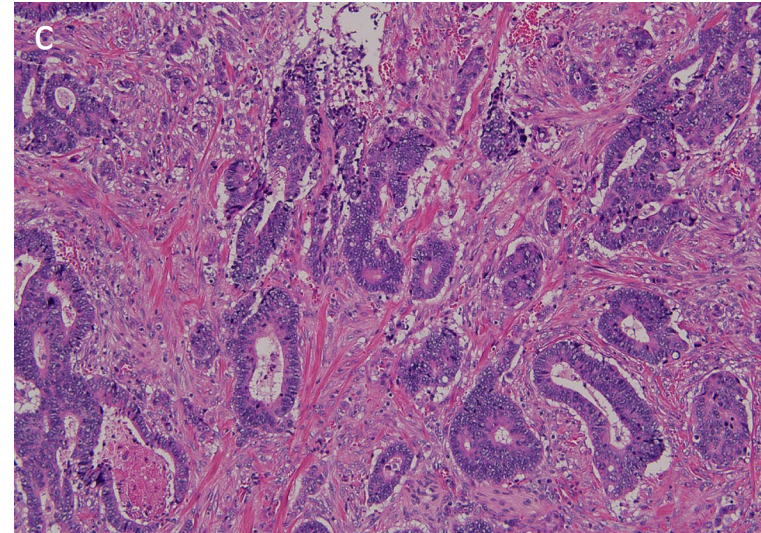
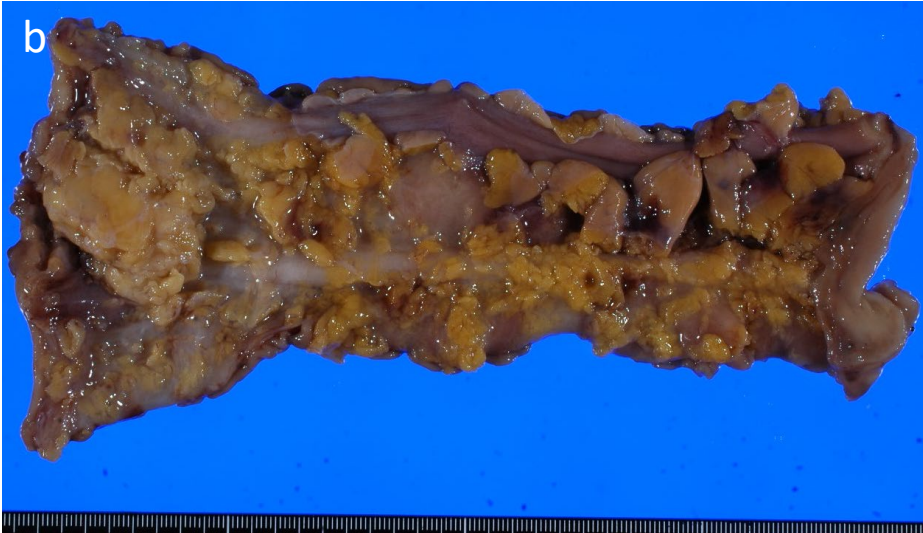
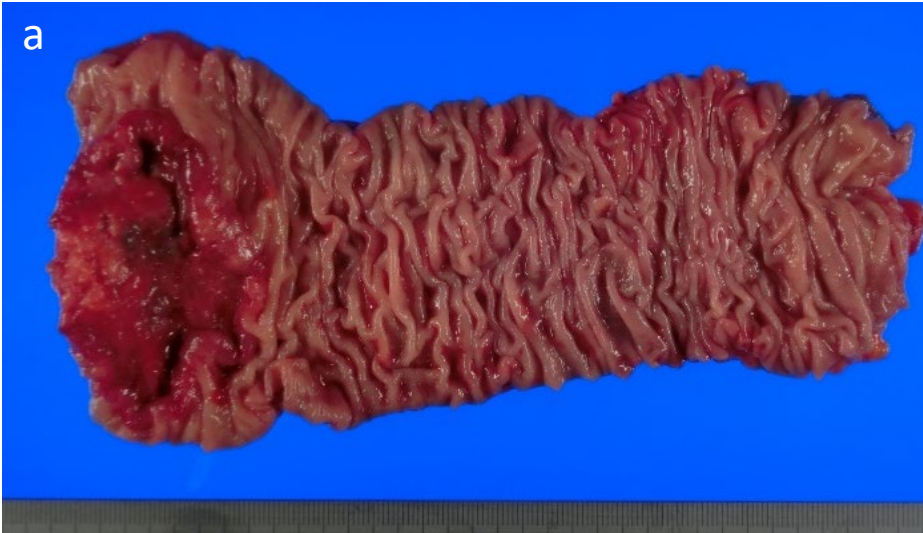
Figure S3

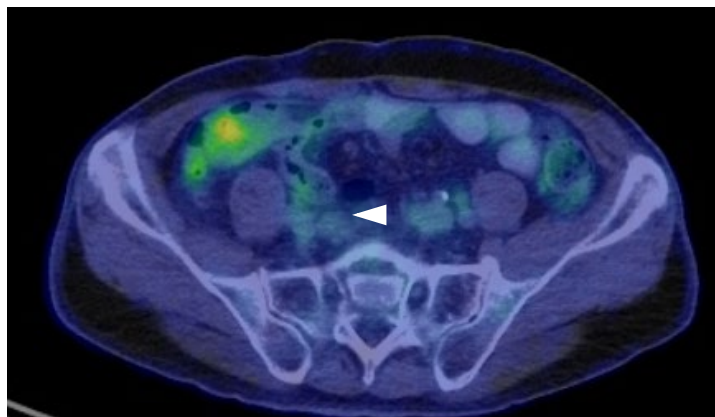


Figure S4

