

ORIGINAL ARTICLE

Intraoperative complications and early implant failure after transcrestal sinus floor elevation with residual bone height ≤ 5 mm: A retrospective multicenter study

Claudio Stacchi¹  | Fabio Bernardello²  | Sergio Spinato³  | Rossano Mura⁴  |
Michele Perelli⁵  | Teresa Lombardi⁶  | Giuseppe Troiano⁷  | Luigi Canullo⁸ 

¹Department of Medical, Surgical and Health Sciences, University of Trieste, Trieste, Italy

²Private Practice, Terranegra di Legnago (VR), Italy

³Private Practice, Sassuolo (MO), Italy

⁴Private Practice, Arco (TN), Italy

⁵Private Practice, Torino, Italy

⁶Department of Health Sciences, University "Magna Græcia", Catanzaro, Italy

⁷Department of Clinical and Experimental Medicine, University of Foggia, Foggia, Italy

⁸University of Bern, Bern, Switzerland

Correspondence

Luigi Canullo, Private Practice, Rome, Italy.
Email: luigi.canullo@gmail.com

Abstract

Objective: Clinical indications for maxillary sinus floor elevation with transcrestal techniques have increased in recent years even in sites with minimal residual bone height (RBH). Nevertheless, limited information is currently available on incidence of intraoperative complications and early implant failure in these cases.

Material and Methods: This retrospective multicenter study was performed on anonymized clinical and radiographic records of patients who underwent transcrestal sinus floor elevation in seven clinical centers. Influence of different factors related to patient, and sinus anatomy and surgical technique on the incidence of intraoperative complications and early implant failure rate after transcrestal sinus lift were investigated.

Results: A total of 430 patients treated with transcrestal sinus floor elevation for single-implant insertion in sites with RBH ≤ 5 mm were included in the final analysis. After 1 year of loading, 418 implants of 430 were satisfactorily in function. Early implant failure was recorded in 12 cases (2.8%); results were significantly associated with the presence of large sinus cavities and with the occurrence of membrane perforation.

The following adverse events were recorded: membrane perforation (7.2%), acute sinusitis (0.9%), implant displacement into the sinus cavity (0.7%), oro-antral fistula (0.2%), and benign paroxysmal positional vertigo (0.5% of osteotome cases). A strong direct correlation between sinus membrane perforation and bucco-palatal sinus width ($p = .000$) was demonstrated.

Conclusions: Early implant failure after transcrestal sinus elevation showed significant direct correlation with bucco-palatal maxillary sinus width and the presence of membrane perforation. Sinus membrane perforation was strongly associated with bucco-palatal sinus width (extremely low perforation rate in narrow and much higher incidence in wide sinuses).

This is an open access article under the terms of the [Creative Commons Attribution-NonCommercial-NoDerivs](https://creativecommons.org/licenses/by-nc-nd/4.0/) License, which permits use and distribution in any medium, provided the original work is properly cited, the use is non-commercial and no modifications or adaptations are made.

© 2022 The Authors. *Clinical Oral Implants Research* published by John Wiley & Sons Ltd.

1 | INTRODUCTION

The anatomical configuration of the edentulous posterior upper jaw is often characterized by severe bone shrinking resulting from the combination of both teeth extraction and sinus pneumatization. A widespread surgical option for treating these vertical bone deficiencies is sinus floor elevation with lateral or transcrestal approach (Boyne & James, 1980; Tatum, 1986). The criteria for choosing between these two techniques have been based on residual bone height (RBH), calculated as the distance from sinus floor to the bony crest. The Sinus Consensus Conference held in Boston (1996) and subsequent classifications suggested the transcrestal approach with RBH of 6–7 to 9 mm and lateral window sinus augmentation in the presence of 5 mm or less of bone below the sinus floor (Jensen et al., 1998; Wang & Katranij, 2008).

However, it should be considered that maxillary sinus involvement in the therapeutic plan increases morbidity, costs, and operative risk. A recent retrospective study conducted on 3900 patients who had oral and periodontal surgeries between 1990 and 2018 at the University of Michigan School of Dentistry indicated that lateral sinus floor elevation (together with surgical extraction of impacted teeth) is the procedure associated with more frequent and severe complications compared with other oral, periodontal, and implant surgeries (Askar et al., 2019).

In the last decade, minimally invasive options for the rehabilitation of the atrophic posterior maxilla have been extensively investigated. Recent evidence demonstrated as short and ultrashort implants in the atrophic posterior maxilla represent a rapid and predictable treatment alternative, both for splinted and single-unit implant-supported prostheses. Short implants showed a similar medium-term survival rate, lower morbidity and incidence of complications, better peri-implant marginal bone stability, and reduced treatment time and cost when compared to longer implants placed in augmented sinuses (Al-Moraissi et al., 2019; Ravidà et al., 2019; Ravidà et al., 2021; Yan et al., 2019).

Furthermore, clinical indications for maxillary sinus floor elevation with transcrestal approach have greatly increased in recent years (Block, 2016; Stacchi et al., 2020). Several studies explored the possibility to perform one-stage or two-stage transcrestal sinus augmentation even in sites with residual bone height ≤ 5 mm, resulting in minimal invasivity and excellent implant survival rate (Bernardello et al., 2011; Gonzalez et al., 2014; Lin et al., 2020; Lombardi et al., 2017; Sisti et al., 2012; Sonoda et al., 2020; Stacchi et al., 2018; Toffler, 2004). Clinical and histologic studies showed that the transcrestal technique is more predictable in terms of endo-sinus new bone formation in narrow than in wide sinuses, irrespective of crestal bone height (Lombardi et al., 2017; Spinato et al., 2015; Stacchi et al., 2018). Therefore, the distance between buccal and palatal sinus bone walls is fundamental when selecting the best surgical option, coupling minimal invasiveness with high predictability of clinical outcomes. A width between buccal and palatal bone walls of 12 mm represents the threshold dividing narrow (≤ 12 mm) and wide sinuses (> 12 mm) (Lombardi et al., 2017; Spinato et al., 2015; Stacchi et al., 2018; Zheng et al., 2016).

Nevertheless, limited information is currently available on the potential influence of anatomical and surgical variables on incidence of intraoperative complications and early implant failure after transcrestal sinus floor elevation with minimal residual bone height.

The present retrospective study aimed to analyze the possible influence of different factors (related to patient, sinus anatomy, and surgical technique) on early implant failure and intra- and post-operative complications in patients requiring sinus floor elevation with transcrestal approach in the presence of $RBH \leq 5$ mm.

2 | MATERIAL AND METHODS

2.1 | Patient recruitment

The present retrospective multicenter study was conducted on anonymized clinical and radiographic records of patients who underwent transcrestal sinus floor elevation between 2000 and 2020 in seven private clinical centers in Italy (C.S., Gorizia; F.B., Terranegra di Legnago (VR); S.S., Sassuolo (MO); T.L., Cassano allo Jonio (CS); R.M., Arco (TN); M.P., Torino; and L.C., Roma). In the informed consent prior to sinus surgery, patients were informed that their clinical and radiographic data could have been used anonymously for research purposes. This study has been reported according to the Strengthening the Reporting of Observational Studies in Epidemiology (STROBE) guidelines (von Elm et al., 2014). The study protocol was approved by the relevant Ethical Committee (Comitato Etico di Ateneo, University of Trieste, nr. 114-31/05/2021).

2.2 | Inclusion and exclusion criteria

All patients (>18 years old) treated in the aforementioned centers with unilateral transcrestal sinus floor elevation were considered eligible for inclusion.

Inclusion criteria were the following: (1) immediate post-operative periapical radiograph; (2) periapical radiograph after 6 months of healing; (3) well-documented medical charts reporting details of the surgical procedure and notes in relation to intra- and post-operative complications; and (4) minimum follow-up of 12 months after prosthetic crown delivery. Exclusion criteria included: (1) incomplete or low-quality clinical and radiographic documentation; (2) pre-operative residual bone height of the alveolar crest >5 mm at the planned augmentation site; and (3) no antibiotic therapy prescribed after sinus surgery.

2.3 | Data collection

Medical records were collected by one trained examiner per center (C.S., F.B., S.S., T.L., R.M., M.P., and L.C.). In order to standardize data collection and study variables assessment, examiners participated in

a calibration meeting prior to the beginning of the study. Data were recorded in a specific case report form.

The following patient-level information was collected:

- age;
- gender;
- systemic diseases;
- medications;
- smoking habits;
- history of periodontal disease.

The following sinus- and implant-level information was collected:

- bone height (BH) at the augmentation site before sinus floor elevation (mm);
- sinus floor inclination at the augmentation site (flat / sloped);
- presence of Underwood septa at the augmentation site;
- bucco-palatal sinus width (SW) at the augmentation site (mm), if pre-operative cone beam computed tomography (CBCT) was available;
- crestal antrostomy technique (rotary instruments / osteotomes / ultrasonic inserts);
- type of grafting material (allograft / xenograft / alloplastic);
- graft characteristics (≤ 1 mm granules / > 1 mm granules / sponge / injectable gel or paste);
- timing of implant placement (simultaneous/staged);
- implant surface treatment (minimally rough / moderately rough / rough) (Albrektsson & Wennerberg, 2004).

The occurrence of the following intra- and post-operative complications was recorded:

- sinus membrane perforation;
- benign paroxysmal positional vertigo (BPPV);
- oro-antral fistula;
- acute sinusitis;
- implant displacement into the sinus cavity;
- early implant failure (implant lost before loading or within the first year of prosthetic function).

2.4 | Radiographic measurements

Periapical radiographs were taken using the long-cone paralleling technique with a Rinn film holder. No attempt was made for further standardization. Pre-operative BH was measured on a 30-inch led-backlit color diagnostic display using a specific software (ImageJ 1.48a, National Institutes of Health, Bethesda, USA). Pre-operative BH was calculated on each periapical radiograph as the linear measurement of the distance between the most coronal point of the alveolar crest at implant site and the sinus floor.

When available, CBCT scan was used to evaluate sinus width (SW) at the augmentation site, defined as the distance between buccal and palatal wall measured at 10-mm height, comprising the alveolar crest (Avila et al., 2010; Lombardi et al., 2017; Soardi

et al., 2011; Spinato et al., 2015). Distance was measured by using the specific tool of an imaging software (OsiriX MD, Pixmeo, Bernex, Switzerland). Sinus cavity was defined narrow when SW was ≤ 12 mm, while it was defined wide when SW was > 12 mm (Stacchi et al., 2018).

All radiographic measurements were performed by a single trained examiner (C.S.), who underwent two calibration sessions on a sample of 10 periapical radiographs and 10 CBCTs not included in the study. The second session took place 1 week after the first one, and intraclass correlation coefficient (ICC) was used to assess intraexaminer reliability (Shrout & Fleiss, 1979).

2.5 | Predictor and outcome variables

The present retrospective study aimed to test the possible influence of different factors (related to patient, sinus anatomy, and surgical technique) on early implant failure and intra- and post-operative complications.

2.6 | Primary outcome measure

- early implant failure.

The predictor variables tested for the primary outcome were the following:

- patient level (age, gender, smoking habits, and history of periodontitis)
- sinus level (BH before augmentation, SW, sinus floor inclination, and presence of Underwood septa)
- surgical variables (surgical technique, implant surface treatment, timing of implant placement, and Schneiderian membrane perforation during surgery).

Secondary outcome measures:

- Schneiderian membrane perforation during surgery;
- any complications or adverse events.

The predictor variables tested for the secondary outcomes were the following:

- patient level (age, gender, smoking habits, and history of periodontitis)
- sinus level (BH before augmentation, SW, sinus floor inclination, and the presence of Underwood septa)
- surgical variables (surgical technique, implant surface treatment, and timing of implant placement).

2.7 | Statistical analysis

All statistical analyses have been performed by using the software Stata 16.0 (StataCorp LLC, College Station, USA). Descriptive

statistics has been performed by calculating frequencies for dichotomous data and means with standard deviations for continuous variables. Univariate logistic regression analysis was first performed to select factors associated with the presence of the primary and secondary outcomes of the present study. Subsequently, the predictor variables which resulted significant at the univariate analysis were inserted in a stepwise multivariate logistic regression model, setting a *p*-value of .157 in the stepwise backward model as suggested by Heinze and Dunkler (2017).

3 | RESULTS

3.1 | Clinical outcomes

A total of 783 patients treated with transcrestal sinus floor elevation and single-implant insertion matched inclusion criteria and were further screened. Three-hundred and thirty-six patients were excluded: 28 had incomplete clinical or radiographic documentation, 2 patients did not undergo post-operative antibiotic therapy,

and 306 presented pre-operative residual bone height >5 mm. A total of 447 patients were included in the preliminary analysis. Surgery and prosthesis were performed in seven clinical centers (F.B. = 108; L.C. = 20; T.L. = 41; R.M. = 96; M.P. = 68; S.S. = 63; and C.S. = 51), with a minimum follow-up of 1 year after prosthetic loading.

Transcrestal sinus access was performed with subtractive techniques [specific burs (Cosci & Luccioli, 2000) or ultrasonic inserts (Kim et al., 2014; Sentineri & Dagnino, 2011): 53.2% and 3.8% of the subjects, respectively] or by bone compaction [osteotomes (Franceschetti et al., 2014; Summers, 1994): 43.0% of the subjects] and sinus membrane elevation was obtained by incremental grafting material insertion. As only 3.8% of the subjects (*n* = 17) had the procedure performed with ultrasonic inserts, it was decided to exclude them from the logistic regression analysis to avoid possible skewing of results. Finally, 430 patients (207 males and 223 females; age range: 30–84 years; mean: 58.3 ± 11.5 years) were included in the final analysis. Selection process has been summarized in Figure 1. Demographic data of patients included in the study have been presented in Table 1, while maxillary sinus

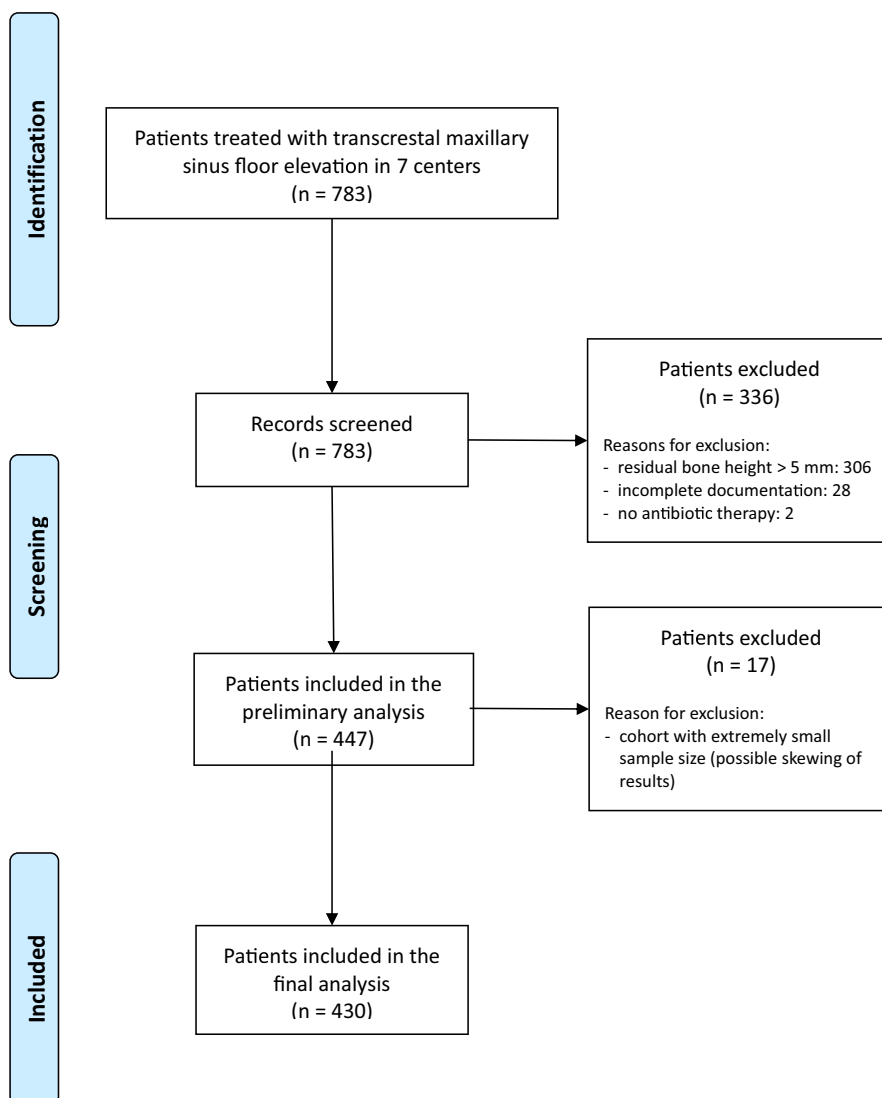


FIGURE 1 Patient selection process flowchart

TABLE 1 Demographic characteristics of the included patients. Data are expressed as mean ± standard deviation

Gender	207 males (48.1%)	223 females (51.9%)	
Age	58.3 ± 11.5 years – range 30–84 years		
		No (%)	Yes (%)
Smoking Status		317 (73.7%)	113 (26.3%)
History of Periodontitis		268 (62.3%)	162 (37.7%)
Systemic Disease		366 (85.1%)	64 (14.9%)
Medication		372 (86.5%)	58 (13.5%)

TABLE 2 Surgical site and surgical intervention characteristics. BH: bone height

Surgical site (n = 430)	
Sinus Floor Shape	
Flat	319 (74.2%)
Sloped	111 (25.8%)
Sinus Width	
Narrow (≤ 12 mm)	176 (40.9%)
Wide (> 12 mm)	161 (37.4%)
Not Available	93 (21.7%)
Underwood Septa	
Absent	383 (89.1%)
Present	47 (10.9%)
Pre-operative BH	
	mean 4.0 ± 0.9 mm range 1.0–5.0 mm
BH after 6 months	
	mean 9.4 ± 2.8 mm range 1.0–19.0 mm
Surgical intervention (n = 430)	
Technique	
Burs	238 (55.3%)
Osteotomes	192 (44.7%)
Graft Type	
Xenograft	289 (67.2%)
Allograft	68 (15.8%)
Collagen	61 (14.2%)
Synthetic	7 (1.6%)
No graft	5 (1.2%)
Graft Formulation	
Granules ≤ 1 mm	221 (51.4%)
Granules > 1 mm	112 (26.0%)
Sponge	61 (14.2%)
Gel	31 (7.2%)
No graft	5 (1.2%)
Implant Placement	
Simultaneous	385 (89.5%)
Staged	45 (10.5%)
Implant Surface	
Moderately Rough	414 (96.3%)
Rough	16 (3.7%)

characteristics and details of surgical technique have been listed in Table 2.

After 1 year of prosthetic loading, 418 of 430 implants were satisfactorily in function (97.2%). Early implant failure occurred in 12 cases (2.8%): stepwise multivariate logistic regression analysis demonstrated a significant correlation with the presence of large sinus cavities [OR = 8.50; 95%CI (1.02–70.42); *p* = .047] and with the occurrence of sinus membrane perforation [OR = 4.21; (95%CI: 1.10–16.05); *p* = .035] (Table 3).

3.2 | Radiographic outcomes

BH at the augmentation site before sinus floor elevation ranged from 1.0 to 5.0 mm (mean 4.0 ± 0.9 mm). BH at the augmented site 6 months after transcrestal sinus augmentation ranged from 1.0 to 19.0 mm (mean 9.4 ± 2.8 mm), with a mean vertical bone gain of 5.4 ± 2.9 mm (range 0 to 18.0 mm).

SW at the augmentation site, measured on CBCT at 10-mm level comprising the residual alveolar crest, was ≤ 12 mm (narrow sinus) in 176 patients and > 12 mm (wide sinus) in 161 patients. It was not possible to classify sinus width in 93 patients, due to CBCT unavailability.

ICC score for radiographic measurements (> 0.92) resulted in an excellent intraexaminer repeatability: mean difference in BH and SW was 0.12 and 0.17 mm, respectively.

3.3 | Intra- and post-operative complications

The most frequent adverse event was Schneiderian membrane perforation (*n* = 31; incidence 7.2%) (Figure 2): 2 perforations occurred in 176 narrow sinus cavities (incidence 1.1%), 26 perforations in 161 wide sinus cavities (incidence 16.1%), and 3 perforations in sinuses with unknown bucco-palatal width. When perforation was detected after crestal osteotomy, collagen sponges or resorbable membranes were inserted prior to implant placement, without the use of bone substitutes. Other complications comprised of acute sinusitis (*n* = 4; 0.9%), implant displacement into the sinus cavity (*n* = 3; 0.7%), and oro-antral fistula (*n* = 1; 0.2%). Benign paroxysmal positional vertigo was recorded in one case, following the use of osteotomes (0.5% of osteotome cases).

Univariate logistic regression analysis showed a strong direct correlation between sinus membrane perforation and bucco-palatal

TABLE 3 Univariate and multivariate stepwise logistic regression analysis for the outcome “Early Implant Failure”

Number of implants = 430	Univariate Analysis			Multivariate Analysis		
	OR	[95% CI]	p-value	OR	[95% CI]	p-value
Early implant failure						
Age	0.97	[0.92–1.02]	.185			
Gender						
Female	1.					
Male	2.22	[0.66–7.49]	.198			
Periodontal Disease	0.83	[0.25–2.81]	.766			
Smoking						
No	1.					
Yes	2.08	[0.64–6.68]	.220			
Underwood Septa						
Absent	1					
Present	2.76	[0.72–10.58]	.138			
Sinus Floor Shape						
Flat	1					
Sloped	0.49	[0.11–2.28]	.364			
Sinus Width						
Narrow	1			1.		
Wide	11.74	[1.49–92.82]	.02*	8.50	[1.02–70.42]	.047*
Residual Bone Height	1.21	[0.59–2.49]	.597			
Technique						
Burs	1					
Osteotomes	2.49	[0.74–8.41]	.141			
Membrane Perforation						
No	1			1.		
Yes	11.73	[3.46–39.69]	.000*	4.21	[1.10–16.05]	0.035*
Implant Placement						
Simultaneous	1					
Staged	0.78	[0.1–6.13]	.807			

Note: OR, Odds Ratio, *p-value < .05

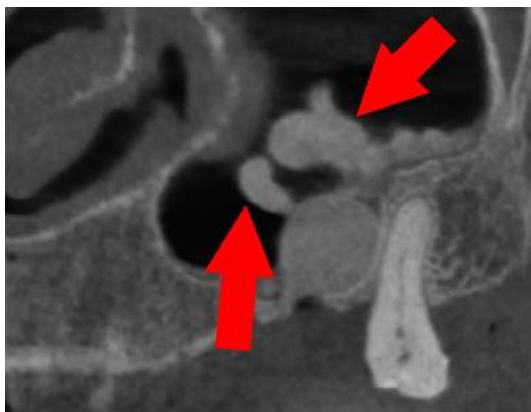

FIGURE 2 CBCT Panorex image taken immediately after grafting procedure. Red arrows indicate graft dissemination into the sinus cavity due to membrane perforation

sinus width [OR = 15.5; (95%CI: 3.59–56.59); $p = .000$] (Table 4). Multivariate analysis was not performed as no other predictor variable reached statistical significance. It was not possible to perform a statistical analysis for the post-operative complications due to their extremely low numerosity.

4 | DISCUSSION

In the present study, bucco-palatal maxillary sinus width seems to play a crucial role in the success of implant rehabilitations: wide sinus cavities (>12mm at 10-mm height, comprising the alveolar crest) resulted significantly associated with early implant failure. A wide sinus cavity has been shown by numerous studies to represent a biologically unfavorable environment for new bone formation after both lateral and crestal sinus lift (Avila et al., 2010;

TABLE 4 Univariate analysis for the outcome “Membrane Perforation”

Number of implants = 430	Univariate Analysis		
	OR	[95% CI]	p-value
Age	0.99	[0.96–1.03]	.711
Gender			
Female	1		
Male	1.59	[0.74–3.41]	.235
Periodontal Disease	1.19	[0.55–2.57]	.612
Smoking			
No	1		
Yes	1.54	[0.69–3.43]	.287
Underwood septa			
Absent	1		
Present	1.73	[0.63–4.78]	.287
Sinus Floor Shape			
Flat	1		
Sloped	0.78	[0.32–1.88]	.584
Sinus Width			
Narrow	1		
Wide	15.47	[3.59–56.59]	.000*
Residual Bone Height	0.76	[0.51–1.13]	.176
Technique			
Burs	1		
Osteotomes	1.33	[0.63–2.82]	.460
Implant Placement			
Simultaneous	1		
Staged	1.88	[0.68–6.13]	.224

Note: OR, Odds Ratio.*p-value <.05

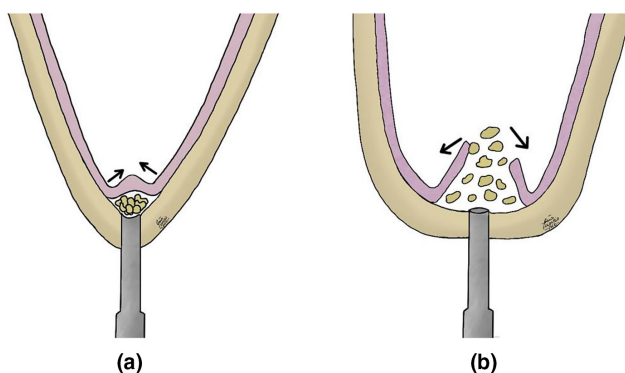


FIGURE 3 The force required for membrane detachment is directly correlated with the surface of the elevated area. Transcrestal techniques allow adequate membrane elevation in narrow sinuses (a), where elevated surface is smaller than in wide ones. In wide sinuses (b), the force required to properly elevate the membrane could exceed its deformation capacity, resulting in increased perforation risk

Kolerman et al., 2008; Lombardi et al., 2017; Soardi et al., 2011; Stacchi et al., 2018; Stacchi et al., 2022; Zhou et al., 2021). This situation is a consequence of the increased distance between the central part of the regeneration area (where the implant is usually inserted) and the bony walls, which are the primary source of osteoprogenitor cells and blood supply (Dragonas et al., 2020). Moreover, when transcresal sinus lift is performed in wide cavities, the indirect elevation of the sinus membrane is not always able to expose lateral and medial bone walls, further reducing the already low osteogenetic potential of the area (Cho et al., 2017; Stacchi et al., 2018). The combined action of these factors could result in a newly formed tissue with very low percentage of vital bone (Lombardi et al., 2017; Stacchi et al., 2018), which may explain the increased incidence of early implant failures in large sinus cavities.

The findings of the present study suggest that also the occurrence of sinus membrane perforation could significantly influence the primary study outcome, in accordance with recent meta-analyses and clinical studies (Al-Moraissi et al., 2018; Kim et al., 2019; Rammelsberg et al., 2020). Schneiderian membrane perforation may result in the dispersion of graft particles into the sinus cavity, possibly triggering local inflammation and infection leading to acute or subacute sinusitis, with subsequent graft failure and early implant loss. However, even in case of small perforations, slight dissemination of graft particles may elicit chronic infection, which is an obstacle to new bone formation and graft consolidation, predisposing to loss of graft volume and early implant failure (Croes et al., 2019).

Sinus membrane perforation rate recorded in the present study (7.2%) is consistent with data reported in literature for transcresal sinus floor elevation (0 to 10.8%) (Chen & Shi, 2018). Univariate logistic regression analysis indicated only one predictor variable showing significant direct correlation with membrane perforation rate: the bucco-palatal sinus width ($p = .000$). In the present sample, the incidence of membrane perforation was extremely low (1.1%) in narrow sinuses (≤ 12 mm) and much higher (16.1%) in wide cavities (> 12 mm). This finding, highlighted for the first time in this study, is the clinical confirmation of a principle described by Pommer et al. (2009), who demonstrated in vitro that the force required for membrane detachment during transcresal sinus elevation increases along with the dimensions of the elevated area: when the required detachment force exceeds the elastic properties of the sinus membrane, perforation occurs. In narrow sinuses, as the surface of the elevated area is smaller than in wide ones, the maximum elevation height achievable before membrane tearing is generally higher (Figure 3). It is interesting to note that this situation is exactly the opposite of what occurs in sinus floor elevation with lateral approach, where an inverse correlation between sinus width and risk of membrane perforation was demonstrated (Cho et al., 2001; Marin et al., 2019). This different scenario is a consequence of better visibility and easier use of manual instruments for membrane elevation through the lateral window in wide and flat cavities rather than narrow and deep ones.

Other anatomical features which are commonly considered as risk factors for membrane perforation (Underwood septa or sloped

sinus floor) (Tavelli et al., 2020) did not show in the present study significant correlation with the occurrence of membrane perforation. Residual bone height was also not significantly associated with perforation occurrence, in accordance with recent clinical studies on transcrestal sinus floor elevation (Boyacigil et al., 2021; Wen et al., 2015).

Main limitations of the present study are inherent to the retrospective study design as well as to the sample characteristics: as they were used records not designed for the study, some available data may be of poor quality and/or potential confounding factors may not have been properly controlled.

Moreover, Schneiderian membrane perforation during transcrestal sinus floor elevation may not have been always recognized and their final number could have been underestimated (Garbacea et al., 2012). Finally, possible heterogeneity in clinical practice among the seven clinical centers could be an additional confounding factor in interpreting the results of the present study.

ACKNOWLEDGMENTS

The authors would like to thank Gaia Olga Guercio for the drawings included in the present article. Open access funding provided by Universitat Bern.

AUTHOR CONTRIBUTIONS

Claudio Stacchi: Conceptualization (equal); formal analysis (equal); methodology (equal); project administration (equal); supervision (equal); validation (equal). **Fabio Bernardello:** Investigation (equal); resources (equal); validation (equal); writing – review and editing (equal). **Sergio Spinato:** Data curation (equal); investigation (equal); writing – review and editing (equal). **Rossano Mura:** Data curation (equal); investigation (equal); writing – review and editing (equal). **Michele Perelli:** Investigation (equal); writing – review and editing (equal). **Giuseppe Troiano:** statistical analysis (equal), review and editing (equal). **Luigi Canullo:** conceptualization (equal), methodology (equal); project administration (equal); investigation (equal); writing – review and editing (equal).

DATA AVAILABILITY STATEMENT

Data available on request from the authors

ORCID

Claudio Stacchi  <https://orcid.org/0000-0003-4017-4980>
 Fabio Bernardello  <https://orcid.org/0000-0001-6432-1549>
 Sergio Spinato  <https://orcid.org/0000-0002-9014-8732>
 Rossano Mura  <https://orcid.org/0000-0002-1757-0355>
 Michele Perelli  <https://orcid.org/0000-0002-8197-3546>
 Teresa Lombardi  <https://orcid.org/0000-0002-0334-6029>
 Giuseppe Troiano  <https://orcid.org/0000-0001-5647-4414>
 Luigi Canullo  <https://orcid.org/0000-0001-9875-2929>

REFERENCES

- Albrektsson, T., & Wennerberg, A. (2004). Oral implant surfaces: Part 1--review focusing on topographic and chemical properties of different surfaces and in vivo responses to them. *International Journal of Prosthodontics*, 17, 536–543.
- Al-Moraissi, E. A., Altairi, N. H., Abotaleb, B., Al-Iryani, G., Helboub, E., & Alakhali, M. S. (2019). What is the most effective rehabilitation method for posterior maxillae with 4 to 8 mm of residual alveolar bone height below the maxillary sinus with implant-supported prostheses? A frequentist network meta-analysis. *Journal of Oral and Maxillofacial Surgery*, 77, 70.e1–70.e33.
- Al-Moraissi, E., Elsharkawy, A., Abotaleb, B., Alkebsi, K., & Al-Motwakel, H. (2018). Does intraoperative perforation of Schneiderian membrane during sinus lift surgery causes an increased risk of implants failure? A systematic review and meta regression analysis. *Clinical Implant Dentistry and Related Research*, 20, 882–889.
- Askar, H., Di Gianfilippo, R., Ravidà, A., Tattan, M., Majzoub, J., & Wang, H. L. (2019). Incidence and severity of postoperative complications following oral, periodontal and implant surgeries: a retrospective study. *Journal of Periodontology*, 90, 1270–1278.
- Avila, G., Wang, H. L., Galindo-Moreno, P., Misch, C. E., Bagramian, R. A., Rudek, I., Benavides, E., Moreno-Riestra, I., Braun, T., & Neiva, R. (2010). The influence of the bucco-palatal distance on sinus augmentation outcomes. *Journal of Periodontology*, 81, 1041–1060.
- Bernardello, F., Righi, D., Cosci, F., Bozzoli, P., Soardi, C. M., & Spinato, S. (2011). Crestal sinus lift with sequential drills and simultaneous implant placement in sites with <5 mm of native bone: a multicenter retrospective study. *Implant Dentistry*, 20, 439–444.
- Block, M. S. (2016). Improvements in the crestal osteotome approach have decreased the need for the lateral window approach to augment the maxilla. *Journal of Oral and Maxillofacial Surgery*, 74, 2169–2181.
- Boyacigil, D. U., Er, N., Karaca, Ç., & Koç, O. (2021). The effect of residual bone height and membrane thickness on sinus membrane perforation in crestal sinus grafting: A prospective clinical study. *International Journal of Oral and Maxillofacial Surgery*, 50, 251–257.
- Boyne, P. J., & James, R. A. (1980). Grafting of the maxillary sinus floor with autogenous marrow and bone. *Journal of Oral Surgery*, 38, 613–616.
- Chen, M. H., & Shi, J. Y. (2018). Clinical and radiological outcomes of implants in osteotome sinus floor elevation with and without grafting: A systematic review and a meta-analysis. *Journal of Prosthodontics*, 27, 394–401.
- Cho, Y. S., Chong, D., Yang, S. M., & Kang, B. (2017). Hydraulic transcrestal sinus lift: Different patterns of elevation in pig sinuses. *Implant Dentistry*, 26, 706–710.
- Cho, S. C., Wallace, S. S., Froum, S. J., & Tarnow, D. P. (2001). Influence of anatomy on Schneiderian membrane perforations during sinus elevation surgery: three-dimensional analysis. *Practical Procedures and Aesthetic Dentistry*, 13, 160–163.
- Cosci, F., & Luccioli, M. (2000). A new sinus lift technique in conjunction with placement of 265 implants: a 6-year retrospective study. *Implant Dentistry*, 9, 363–368.
- Croes, M., van der Wal, B. C. H., & Vogely, H. C. (2019). Impact of bacterial infections on osteogenesis: Evidence from in vivo studies. *Journal of Orthopedic Research*, 37, 2067–2076.
- Dragonas, P., Katsaros, T., Schiavo, J., Galindo-Moreno, P., & Avila-Ortiz, G. (2020). Osteogenic capacity of the sinus membrane following maxillary sinus augmentation procedures: A systematic review. *International Journal of Oral Implantology (Berlin)*, 13, 213–232.
- Franceschetti, G., Farina, R., Stacchi, C., Di Lenarda, R., Di Raimondo, R., & Trombelli, L. (2014). Radiographic outcomes of transcrestal sinus floor elevation performed with a minimally invasive technique in smoker and non-smoker patients. *Clinical Oral Implants Research*, 25, 493–499.
- Garbacea, A., Lozada, J. L., Church, C. A., Al-Ardah, A. J., Seiberling, K. A., Naylor, W. P., & Chen, J. W. (2012). The incidence of maxillary sinus membrane perforation during endoscopically assessed crestal sinus floor elevation: A pilot study. *Journal of Oral Implantology*, 38, 345–359.
- Gonzalez, S., Tuan, M. C., Ahn, K. M., & Nowzari, H. (2014). Crestal approach for maxillary sinus augmentation in patients with ≤4 mm

- of residual alveolar bone. *Clinical Implant Dentistry and Related Research*, 16, 827–835.
- Heinze, G., & Dunkler, D. (2017). Five myths about variable selection. *Transplant International*, 30, 6–10.
- Jensen, O. T., Shulman, L. B., Block, M. S., & Iacono, V. J. (1998). Report of the Sinus Consensus Conference of 1996. *International Journal of Oral and Maxillofacial Implants*, 13, 11–45.
- Kim, J. S., Choi, S. M., Yoon, J. H., Lee, E. J., Yoon, J., Kwon, S. H., Yeo, C. D., Ryu, J. S., Lee, J. H., You, Y. S., Kim, S. G., Lee, M. H., & Han, B. H. (2019). What affects postoperative sinusitis and implant failure after dental implant: A meta-analysis. *Otolaryngology Head Neck Surgery*, 160, 974–984.
- Kim, J. M., Sohn, D. S., Bae, M. S., Moon, J. W., Lee, J. H., & Park, I. S. (2014). Flapless transcrestal sinus augmentation using hydrodynamic piezoelectric internal sinus elevation with autologous concentrated growth factors alone. *Implant Dentistry*, 23, 168–174.
- Kolerman, R., Tal, H., & Moses, O. (2008). Histomorphometric analysis of newly formed bone after maxillary sinus floor augmentation using ground cortical bone allograft and internal collagen membrane. *Journal of Periodontology*, 79, 2104–2111.
- Lin, X., Zhou, Z., Li, S. B., Gao, Y., Li, S. Y., Zhu, P. J., & Xu, S. L. (2020). Application of two-stage crestal approach sinus elevation in severe atrophic posterior maxilla. *Zhonghua Kouqiang Yixue Zazhi*, 55, 871–877.
- Lombardi, T., Stacchi, C., Berton, F., Traini, T., Torelli, L., & Di Lenarda, R. (2017). Influence of maxillary sinus width on new bone formation after transcrestal sinus floor elevation: a proof-of-concept prospective cohort study. *Implant Dentistry*, 26, 209–216.
- Marin, S., Kirnbauer, B., Rugani, P., Payer, M., & Jakse, N. (2019). Potential risk factors for maxillary sinus membrane perforation and treatment outcome analysis. *Clinical Implant Dentistry and Related Research*, 21, 66–72.
- Pommer, B., Unger, E., Sütö, D., Hack, N., & Watzek, G. (2009). Mechanical properties of the Schneiderian membrane in vitro. *Clinical Oral Implants Research*, 20, 633–637.
- Rammelsberg, P., Kilian, S., Büsch, C., & Kappel, S. (2020). The effect of transcrestal sinus-floor elevation without graft on the long-term prognosis of maxillary implants. *Journal of Clinical Periodontology*, 47, 640–648.
- Ravidà, A., Galli, M., Bianchi, M., Parisi, E., Saleh, M. H. A., Stacchi, C., Misch, C., & Wang, H.-L. (2021). Clinical outcomes of short implants (≤ 6 mm) placed between two adjacent teeth/implants or in the most distal position: A systematic review and meta-analysis. *International Journal of Oral Implantology (Berlin)*, 14, 241–257.
- Ravidà, A., Wang, I. G., Sammartino, G., Barootchi, S., Tattan, M., Troiano, G., Laino, L., Marenzi, G., Covani, U., & Wang, H. L. (2019). Prosthetic rehabilitation of the posterior atrophic maxilla, short (≤ 6 mm) or long (≥ 10 mm) dental implants? A systematic review, meta-analysis, and trial sequential analysis: Naples Consensus Report Working Group A. *Implant Dentistry*, 28, 590–602.
- Sentineri, R., & Dagnino, G. (2011). Sinus augmentation by crestal approach with the Sinus Physiolift device. *Journal of Osteology and Biomaterials*, 2, 69–75.
- Shrout, P. E., & Fleiss, J. L. (1979). Intraclass correlations: Uses in assessing rater reliability. *Psychological Bulletin*, 86, 420–428.
- Sisti, A., Canullo, L., Mottola, M. P., & Iannello, G. (2012). Crestal minimally-invasive sinus lift on severely resorbed maxillary crest: Prospective study. *Biomedical Technology (Berlin)*, 9, 45–51.
- Soardi, C. M., Spinato, S., Zaffe, D., & Wang, H. L. (2011). Atrophic maxillary floor augmentation by mineralized human bone allograft in sinuses of different size: An histologic and histomorphometric analysis. *Clinical Oral Implants Research*, 22, 560–566.
- Sonoda, T., Yamamichi, K., Harada, T., & Yamamichi, N. (2020). Effect of staged crestal maxillary sinus augmentation: A case series. *Journal of Periodontology*, 91, 194–201.
- Spinato, S., Bernardello, F., Galindo-Moreno, P., & Zaffe, D. (2015). Maxillary sinus augmentation by crestal access: a retrospective study on cavity size and outcome correlation. *Clinical Oral Implants Research*, 26, 1375–1382.
- Stacchi, C., Lombardi, T., Ottonelli, R., Berton, F., Perinetti, G., & Traini, T. (2018). New bone formation after transcrestal sinus floor elevation was influenced by sinus cavity dimensions: A prospective histologic and histomorphometric study. *Clinical Oral Implants Research*, 29, 465–479.
- Stacchi, C., Rapani, A., Lombardi, T., Bernardello, F., Nicolin, V., & Berton, F. (2022). Does new bone formation vary in different sites within the same maxillary sinus after lateral augmentation? A prospective histomorphometric study. *Clinical Oral Implants Research*, 33, 322–332.
- Stacchi, C., Spinato, S., Lombardi, T., Bernardello, F., Bertoldi, C., Zaffe, D., & Nevins, M. (2020). Minimally invasive management of implant-supported rehabilitation in the posterior maxilla. Part II. Surgical techniques and decision tree. *International Journal of Periodontics and Restorative Dentistry*, 40, e95–e102.
- Summers, R.B. (1994). A new concept in maxillary implant surgery: the osteotome technique. *Compendium*, 15, 152, 154–156, 158 passim; quiz 162.
- Tatum, H., Jr. (1986). Maxillary and sinus implant reconstructions. *Dental Clinics of North America*, 30, 207–229.
- Tavelli, L., Borgonovo, A., Saleh, M., Ravidà, A., Chan, H.-L., & Wang, H.-L. (2020). Classification of sinus membrane perforations occurring during transcrestal sinus floor elevation and related treatment. *International Journal of Periodontics & Restorative Dentistry*, 40, 111–118.
- Toffler, M. (2004). Minimally invasive sinus floor elevation procedures for simultaneous and staged implant placement. *New York State Dental Journal*, 70, 38–44.
- von Elm, E., Altman, D. G., Egger, M., Pocock, S. J., Gøtzsche, P. C., Vandenbroucke, J. P., & STROBE Initiative. (2014). The Strengthening the Reporting of Observational Studies in Epidemiology (STROBE) Statement: guidelines for reporting observational studies. *International Journal of Surgery*, 12, 1495–1499.
- Wang, H. L., & Katranij, A. (2008). ABC sinus augmentation classification. *International Journal of Periodontics and Restorative Dentistry*, 28, 383–389.
- Wen, S.-C., Lin, Y.-H., Yang, Y.-C., & Wang, H.-L. (2015). The influence of sinus membrane thickness upon membrane perforation during transcrestal sinus lift procedure. *Clinical Oral Implants Research*, 26, 1158–1164.
- Yan, Q., Wu, X., Su, M., Hua, F., & Shi, B. (2019). Short implants (≤ 6 mm) versus longer implants with sinus floor elevation in atrophic posterior maxilla: a systematic review and meta-analysis. *BMJ Open*, 9, e029826.
- Zheng, X., Teng, M., Zhou, F., Ye, J., Li, G., & Mo, A. (2016). Influence of maxillary sinus width on transcrestal sinus augmentation outcomes: radiographic evaluation based on cone beam CT. *Clinical Implant Dentistry and Related Research*, 18, 292–300.
- Zhou, W., Wang, F., Magic, M., Zhuang, M., Sun, J., & Wu, Y. (2021). The effect of anatomy on osteogenesis after maxillary sinus floor augmentation: a radiographic and histological analysis. *Clinical Oral Investigations*, 25, 5197–5204.

How to cite this article: Stacchi, C., Bernardello, F., Spinato, S., Mura, R., Perelli, M., Lombardi, T., Troiano, G., & Canullo, L. (2022). Intraoperative complications and early implant failure after transcrestal sinus floor elevation with residual bone height ≤ 5 mm: A retrospective multicenter study. *Clinical Oral Implants Research*, 33, 783–791. <https://doi.org/10.1111/clar.13959>