

Original Research Article

Comparison of plain X-ray and MRI findings by determining the sensitivity and specificity in the diagnosis of lumbar spinal stenosis in rural population

Soneshkumar R. Chougule*

Department of Radiology, BKL Walawalkar Rural Medical College, A/P-Sawarde, Tal-Chiplun, District. Ratnagiri, Maharashtra, India

Received: 01 November 2022

Revised: 06 December 2022

Accepted: 10 December 2022

***Correspondence:**

Dr. Soneshkumar R. Chougule,

E-mail: sonesh.chougule@yahoo.com

Copyright: © the author(s), publisher and licensee Medip Academy. This is an open-access article distributed under the terms of the Creative Commons Attribution Non-Commercial License, which permits unrestricted non-commercial use, distribution, and reproduction in any medium, provided the original work is properly cited.

ABSTRACT

Background: Lumbar spinal stenosis is the most frequent indication for spine surgery. The x-ray and MRI are the choice of investigation. Justified use of radiography can be cost effective in the management of lumbar spinal stenosis. Objective was to evaluate and compare the sensitivity and specificity of the plain x-ray and MRI in the diagnosis of the lumbar spinal stenosis.

Methods: A multicenter cross sectional analytical study was carried out from July 2021 to August 2022 on 70 patients of both sexes aged more than 25 years with chronic low back pain. A descriptive analysis was performed for all data.

Results: In the MRI, 35 (50.0%) cases had diskogenic spinal canal stenosis and 24 (34.3%) had both diskogenic and non diskogenic spinal canal stenosis. The validity of MRI evaluation for only diskogenic spinal canal stenosis was correlated, where the calculated values of plain x-ray were: sensitivity 80.0%, specificity 60.0%, accuracy 77.5%, positive predictive value 93.3% and negative predictive value 30.0%. The validity of MRI evaluation for both diskogenic and non diskogenic spinal canal stenosis was correlated, where the calculated values of plain x-ray were sensitivity 83.3%, specificity 66.7%, accuracy 80.0%, positive predictive value 90.9% and negative predictive value 50.0%.

Conclusions: Plain x-ray is a useful and reliable diagnostic modality for the evaluation, assessment and the subsequent appropriate management of lumbar spinal stenosis.

Keywords: MRI, Plain x-ray, Spinal stenosis

INTRODUCTION

Lumbar spinal stenosis is the most frequent indication for spine surgery in patients older than 65 years of age.¹ Clinically, the lumbar spinal stenosis is defined as the buttock or lower extremity pain with or without low back pain; with diminished space for available for neural and vascular elements in the lumbar spine.² But radiologically, stenosis of the spinal canal with or without clinical manifestation is known as spinal stenosis.³ In stenosis, narrowing of the spinal canal, the

lateral recesses and the intervertebral foramina may result in the nerve root compression. Spinal stenosis may primary and acquired. Primary stenosis may be idiopathic, congenital or with associated developmental disorders, like achondroplasia, hypochondroplasia, Morquio's mucopolysaccharidosis, Down's syndrome, etc. Acquired stenosis is mainly a degenerative condition; but may also be due to trauma, infection, previous spinal surgery, etc. Low back pain is a very common symptom, affecting about 60-85% adults during some points in their lives.⁴ Among them, the majority are mild and transient,

with 90% subsiding within 6 weeks.⁵ Chronic low back pain, which may persist beyond 3 months, affects about 15-45% population.⁶

Good history taking and thorough physical examination are essential for making a diagnosis of the cause of low back pain. Radiological imaging is regarded as the most important and essential investigation modality for the diagnosis, presurgical evaluation and follow up of patients with low back pain. Apart from the 'red flag' diagnoses, like cancer and fracture, there are so many cause of low back pain, including the extensive realm of degenerative changes within the axial spine.^{7,8} Large studies recognized that, aging process is the strongest risk factor for the degenerative changes in spine.⁹ But multiple studies have also demonstrated the presence of significant lumbar degeneration even within the first few decades.¹⁰ So, degenerative changes may appear in young individuals without the decades of spine loading, suggesting the influence of other contributing factors.¹¹

Imaging of the spinal stenosis began with the plain radiographs of the lumbar spine. It commonly shows the evidence of multilevel degenerative changes which correlate poorly with the presence of canal stenosis.^{12,13} Degenerative spondylolisthesis or lumbar scoliosis are the features more likely to be associated with lumbar spinal stenosis (LSS).^{14,15} In idiopathic developmental stenosis which commonly involves the lower 2 to 3 lumbar vertebrae, plain radiographs demonstrate short, bulky pedicles, reduction of inter pedicular distance and thickening of the laminae.¹⁶ The combined features result in a reduction in the cross sectional area of the canal and predispose to the individual to the effects of disc degeneration and herniation.

Magnetic resonance imaging (MRI) with high resolution and surface coils has the potential in the assessment of LSS, allowing clear differentiation of the various anatomical structures. MRI is non-invasive, lacks ionizing radiation, and hence has the advantages over CT and myelography. It has the ability to demonstrate the nerve root in the intervertebral foramen on direct para sagittal images and the inherent contrast between cerebrospinal fluid (CSF) and the intrathecal nerve root on T₂ weighted sequences.¹⁷

Central stenosis is manifested on MRI by a focal or generalized reduction in either antero-posterior (AP) dimension of the thecal sac on sagittal images or a reduction in the cross-sectional area in the axial images. Although it is unclear that what degree of thecal sac needs to be compromised before clinical stenosis becomes evident, in a study, less than 100 mm² measured cross sectional thecal sac areas at more than one level were highly associated with the presence of neurogenic claudication.¹⁸ In lateral recess stenosis, MRI findings are as good as CT, but CT is still better for the degenerative facet disease. Currently available high resolution axial

MR imaging is usually able to determine the relative contributions from soft tissue and bone.¹⁷

Foraminal stenosis is a relatively common finding after the sixth decade, and is often asymptomatic. Various grading systems have been developed for the assessment of foraminal stenosis, being based on a subjective assessment of reduction of foraminal fat.^{19,20} In severe foraminal stenosis, there is partial or total loss of fat around the nerve root. In lytic spondylolisthesis, MRI clearly demonstrates the direct compression of the nerve root in the foramen.^{21,22}

Extraforaminal stenosis especially in the transitional lumbo-sacral junction, where the nerve root can be compressed between the enlarged transverse process of the transitional vertebra and the sacral ala, has been demonstrated on coronal MR images.²³ At the L₅-S₁ level, it may also be caused by the lateral osteophytes from the vertebral bodies.²⁴

MRI of the lumbo-sacral spine gives a higher yield than conventional imaging in the investigation of low back pain, particularly in terms of disc degeneration, but it is relatively expensive. So, a cost-effective diagnostic plan is necessary for the management of low back pain, especially in the perspective of our country. The correlation between the clinical presentation, plain radiograph and the MRI findings should also be made well known, so that the maximum benefit can be achieved from MRI of the lumbo-sacral spine. Therefore, this study was to evaluate the usefulness of the plain radiograph in the evaluation of lumbar spinal stenosis, and to investigate the association of plain radiographic findings with the MRI features in the patients with low back pain.

METHODS

This cross-sectional analytical study was carried out from July 2021 to August 2022 in the department of radiology, BKL Walawalkar Rural Medical College and Hospital. The patients with chronic low back pain, attending in the department of radiology were the study population.

The target sample size was 70. Purposive consecutive sampling was applied.

Inclusion criteria

Patients of both sexes, and age more than 25 years suffering from low back pain for more than 3 months were included in the study.

Exclusion criteria

Patients with acute low back pain, LBP due trauma, fracture, infection, neoplasm, etc. and the patients with no prior conservative therapy, were excluded from the study.

Plain x-ray was performed using a 500 MA x-ray machine. Plain lumbosacral radiographs taken in at least the standard anteroposterior and lateral views were included. The posterior disc height less than 6 mm measured in plain radiograph indicated diskogenic lumbar spinal stenosis, and to detect non diskogenic lumbar spinal stenosis, canal to body (C/B) ratio was used.²⁵

Then MRI was done to confirm the diagnosis of low back pain. MRI was performed using a 1.5 Tesla machine, where the standard sequences included were, sagittal T1 fast spin echo (FSE), sagittal T2 FSE, axial T1 FSE and axial T2 FSE. For all sequences, 4 mm slice thickness was used. The interval between plain x-ray and MRI was less than 3 months.

Data was collected in a pre-designed sheet, which included pre-tested questionnaire, clinical findings and image findings. Statistical analysis was done using SPSS version 16.0 statistical package. A descriptive analysis was performed for all data. For the validity of study outcome, sensitivity, specificity, accuracy, positive predictive value and negative predictive value of plain x-ray evaluation for prediction of only diskogenic spinal stenosis and both the diskogenic and non diskogenic spinal stenosis were calculated.

RESULTS

In this study, a total of 70 patients were included (n=70). The mean age (±SD) of the patients included in this study was 45.1 (±5.4) years, ranging from 33 to 53 years, where the majority [40 (57.15%)] belonged to the 41-50 years age group. Among the 70 patients, 42 (60%) were male and 28 (40%) were female, with a 1.5:1 male female ratio.

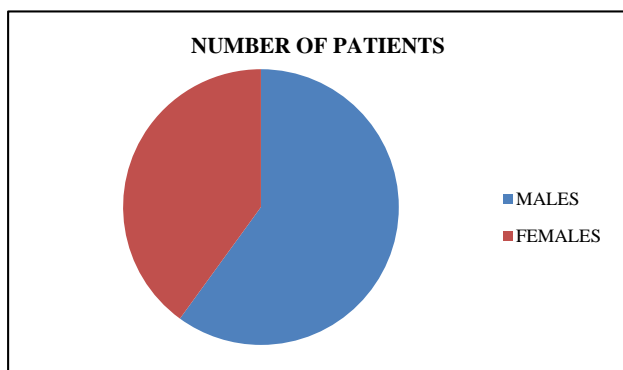


Figure 1: Sex wise distribution.

Regarding the distribution of the patients by the plain radiographic findings, straightened lumbar curvature was found in 52 (74.3%) cases, osteophytic lipping in 49 (70%), foraminal encroachment in 46 (65.7%), non-significant C/B ratio in 40 (57.1%), sacralization in 18 (25.1%) and scoliosis in 15 (21.4%) cases. Majority of the patients [25 (35.7%)] had L4-L5 disc space reduction,

followed by 16 (22.9%) in L5-S1 and 11 (15.7%) in L3-L4 level. Total 52 (74.3%) cases had posterior intervertebral disc height reduction. Spondylolisthesis was found in 8 (11.5%) cases, where 6 (8.6%) were in L5-S1, and 2 (2.9%) in L4-L5 level. 30 (42.9%) cases had significant C/B ratio, where 16 (22.9%) were at L5, and 14 (20.0%) at L4 level. 20 (28.6%) cases had 1:5.1 and 10 (14.3%) had 1:5.2 C/B ratio.

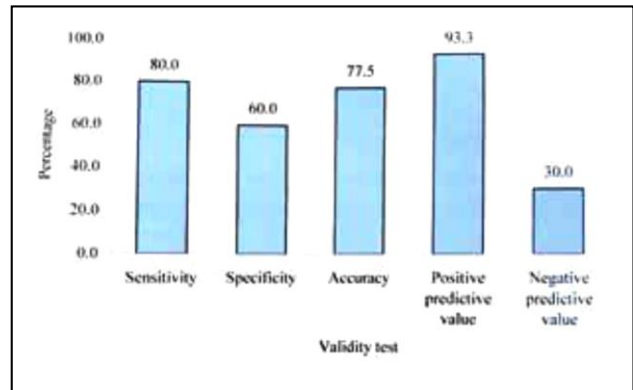


Figure 2: Bar diagram showing validity test of only diskogenic spinal canal stenosis.

Regarding the distribution of the patients by the MRI findings of lumbosacral spine, straightened curvature was found in 59 (84.3%), osteophytic lipping in 47 (67.1%), disk desiccation in 43 (61.4%) and Schmorl's node in 35 (50.0%) cases. 6 (8.6%) patients had L5-S1 spondylolisthesis. Total 59 (84.3%) cases had disk lesion, among them 27 (38.6%) had L4-L5, 21 (30.0%) had L5-S1 and 11 (15.7%) had L3-L4 level lesion.

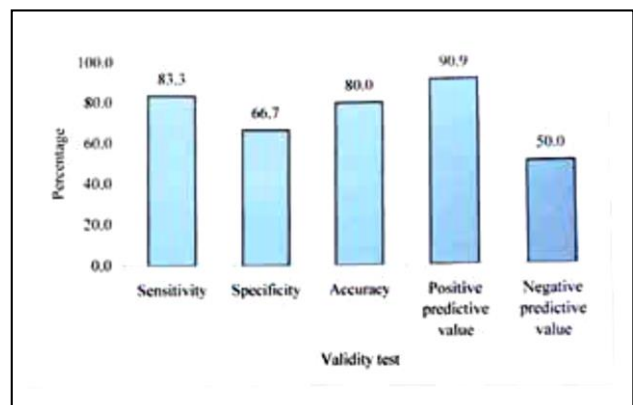


Figure 3: Bar diagram showing validity test of both diskogenic and non diskogenic spinal stenosis.

Regarding analysis of disc lesion by MRI at different levels, where single level lesion was considered, 60 (85.7%) cases had central canal stenosis, 60 (85.7%) had nerve root compression, 60 (85.7%) had neural foraminal narrowing, 60 (85.7%) had thecal sac indentation, 60 (85.7%) had paracentral spinal canal stenosis, 28 (40.0%) had facet hypertrophy, 26 (37.1%) had flaval hypertrophy, 26 (37.1%) had obliteration of lateral recess,

24 (34.3%) had disc bulge, 18 (25.7%) had upward and downward migration, 12 (17.1%) had disk protrusion and 4 (5.7%) had disc extrusion.

In the plain x-ray of the lumbosacral spine, among the 70 cases, 30 (42.9%) had diskogenic spinal canal stenosis only and 22 (31.4%) had both diskogenic and non diskogenic spinal canal stenosis. 18 (25.7%) had no radiological finding. In the MRI, it was found that, 35 (50.0%) cases had diskogenic spinal canal stenosis only and 24 (34.3%) had both diskogenic and non diskogenic spinal canal stenosis. 11 (15.7%) patients had normal MRI finding.

Regarding the comparison between MRI and plain x-ray evaluation of only diskogenic spinal canal stenosis (n=40), in plain x-ray, positive cases were 30 (n=30) and 10 (n=10) were negative in MRI, 35 (n=35) were positive cases and 5 (n=5) were negative. Among them, 28 were true positive, 2 were false positive, 7 were false negative and 3 were true negative. The validity of MRI evaluation for only diskogenic spinal canal stenosis was correlated, where the calculated values of plain x-ray evaluation were: sensitivity 80.0%, specificity 60.0%, accuracy 77.5%, positive predictive value 93.3% and negative predictive value 30.0%

Regarding the comparison between MRI and plain x-ray evaluation of both diskogenic and non diskogenic spinal canal stenosis (n=30), in plain x-ray, positive cases were 22 (n=22) and 8 (n=8) were negative; in MRI, 24 (n=24) were positive cases and 6 (n=6) were negative. Among them, 20 were true positive, 2 were false positive, 4 were false negative and 4 were true negative. The validity of MRI evaluation for both diskogenic and non diskogenic spinal canal stenosis was correlated, where the calculated values of plain x-ray evaluation were: sensitivity 83.3%, specificity 66.7%, accuracy 80.0%, positive predictive value 90.9% and negative predictive value 50.0%.

DISCUSSION

This cross sectional study was carried out with an aim to identify the plain radiographic finding and to determine the MRI features of the patients with lumbar spinal stenosis and also to compare plain x-ray and MRI finding in evaluation of lumbar spinal stenosis.

The findings of present study were discussed and compared with the previously published relevant studies.

Lumbar spinal stenosis is the most frequent indication for spinal surgery in patients older than 65 years of age.¹ Similarly, in this study, the majority (57.15%) patients were in 5th decade. The mean age was found 45.1±5.4 years, ranging from 33 to 53 years. In studies of Kalichman et al and Young et al the mean ages were 52.6±10.8 years, ranging from 32 to 79 years and 44.8±12.69 years, ranging from 20 to 71 years,

respectively, which are consistent with the current study.^{3,25}

In this study, majority (60.0%) patients were male with a male female ratio of 1.5:1. Similarly, in two other studies, the majority participants were male; 55.6% and 61.4% respectively.^{3,25} Degenerative spine changes are remarkably common in population studies. In a study, aging process was found to be the strongest risk factor for spinal degeneration.⁹ Lumbar spondylosis, while affecting 80% of the patients older than 40 years, nevertheless in another study, it was found in 3% cases aged 20-29 years.¹¹

In this study, in the plain x-ray of lumbosacral spine, straightened lumbar curvature was found in 74.3% cases, osteophytic lipping in 70%, foraminal encroachment in 65.7%, non-significant C/B ratio in 57.1%, sacralization in 25.1% and scoliosis in 21.4% cases. Majority of the patients 35.7%) had L₄-L₅ disc space reduction, 22.9% in L₅-S₁ and 15.7% in L₃-L₄ level. Total 52 (74.3%) cases had posterior intervertebral disc height reduction. 6 (8.6%) had L₅-S₁ spondylolisthesis. 30 (42.9%) cases had significant C/B ratio, where 16 (22.9%) were at L₅, and 14 (20.0%) at L₄ level. In the MRI of lumbosacral spine, straightened curvature was found in 84.3%, osteophytic lipping in 67.1%, disk desiccation in 61.4% and Schmorl's node in 50.0% cases. Total 84.3% had disk lesion, among them majority (38.6%) had L₄-L₅ level lesion. 6 (8.6%) patients had L₅-S₁ spondylolisthesis. In this study, 85.7% cases had central canal stenosis, 85.7% had nerve root compression, 85.7% had neural foraminal narrowing, 85.7% had thecal sac indentation, 85.7% had paracentral spinal canal stenosis, 40.0% had facet hypertrophy and 37.1% had flaval hypertrophy.

Young et al reported posterior intervertebral disc height reduction in 82.5% cases, which was the most frequent plain radiographic finding, followed by anterior osteophytes in 50.9%, facet atrophy in 15.8% and spondylolisthesis in 12.3% cases.²⁵ On MRI, intervertebral disc degeneration was observed in 91.2% patients, which was the most frequent finding. 63.2% patients had intervertebral disc herniation, among them, 50% had protrusion only, 19.4% had extrusion and 27.8% had protrusion and extrusion. Nerve root compression was present in 42.1% cases, 29.8% had facet hypertrophy and 7% had spondylolisthesis.²⁵ These findings are comparable with the current study.

In this series, the observed validity of plain x-ray for only diskogenic spinal canal stenosis were: sensitivity 80.0%, specificity 60.0%, accuracy 77.5%, positive predictive value 93.3% and negative predictive value 30.0%. Colhoun et al, in a study, reported sensitivity 88.0%, specificity 48.0%, positive predictive value 88.0% and negative predictive value 48.0%.²⁶ In another study, the observed sensitivity was 73.0%, specificity 27.0%, positive predictive value 45.0% and negative predictive value 55.0%.²⁷ Krenier et al observed a sensitivity 93.0%

and specificity 72.0%.²⁸ These findings are consistent with the current study.

In this series, the observed validity of plain x-ray for both diskogenic and non diskogenic spinal canal stenosis were sensitivity 83.3%, specificity 66.7%, accuracy 80.0%, positive predictive value 90.9% and negative predictive value 50.0%. Young et al showed the sensitivity 92.7% and positive predictive value 96.2%, which is comparable with the present study.²⁵

Limitations of this study were patient having claustrophobia and patient having history of metallic implants insertion, cardiac pacemakers and metallic foreign body in situ.

CONCLUSION

The plain x-ray diagnosis of lumbar spinal stenosis was well correlated with MRI, it can be concluded that, plain x-ray is a useful, effective and reliable diagnostic modality for the evaluation, assessment and the subsequent appropriate management of lumbar spinal stenosis in rural population.

Funding: No funding sources

Conflict of interest: None declared

Ethical approval: The study was approved by the Institutional Ethics Committee

REFERENCES

- Deyo R. Treatment of lumbar spinal stenosis: a balancing act. *Spine J.* 2010;10(7):625-7.
- NASS Evidence-Based Clinical Guidelines Committee. North American Spine Society. Evidence based clinical guidelines for Multi-disciplinary Spine Care. Diagnosis and Treatment of Degenerative Lumbar Spinal Stenosis. Burr Ridge IL. North American Spine Society; 2007.
- Kalichman L, Cole R, Kim D, Li L, Suri P, Guermazi A, et al. Spinal stenosis prevalence and association with symptoms: the Framingham study. *Spine J.* 2009;9(7):545-50.
- Geen J, Edelaar M. The long term of effect of multidisciplinary back training: a systematic review. *Spine J.* 2007;32(2):249-55.
- Dillane J, Fry J, Kalton G. Acute back pain- a study from general practice. *Br Med J.* 1966;2:82-4.
- Andersson GB. The epidemiology of spinal stenosis. In: Frymoyer JW, ed. *The adult spine: principles and practice*, Philadelphia, Lippincott-Raven; 1997:93-111
- Boden SD, Davis DO, Dina TS. Abnormal magnetic resonance scans of the lumbar spine in asymptomatic subjects: a prospective investigation. *J Bone Joint Surg.* 1990;72:403-8.
- Wiesel SW, Tsourmas N, Feffer HL. A study of computer-assisted tomography: the incidence of positive CAT scans in an asymptomatic group of patients. *Spine.* 1984;9:549.
- Buckwalter JA, Saltzman C, Brown T. The impact of osteoarthritis: implications of research. *Clin Orthop Relat Res.* 2004;427:6-15.
- Boos N, Weissbach S, Rohrbach H. Classification of age related changes in lumbar intervertebral discs: 2002 Volvo Award in basic science. *Spine.* 2002;27:2631-44.
- Rothschild B. Lumbar spondylosis. Emedicine publication. 2008. Available from: <http://emedicine.medscape.com/article/249036-overview>. Accessed on 1 September 2022.
- Moreland LW, Lopez MA, Alarcon GS. Spinal stenosis: a comprehensive review of the literature. *Semin Arthritis Rheum.* 1989;19:127-49.
- Sheldon JJ, Russin LA, Gargano FP. Lumbar spinal stenosis: radiographic diagnosis with special reference to transverse axial tomography. *Clin Orthop.* 1976;115:53-67.
- Spivak JM. Degenerative lumbar spinal stenosis. *J Bone Joint Surg.* 1998;80:1053-66.
- Radu AS, Menkes CJ. Update on lumbar spinal stenosis. Retrospective study of 62 patients and review of literature. *Rev Rheum Engl Ed.* 1998;65:337-45.
- Roberson GH, Llewellyn HJ, Traveras JM. The narrow lumbar spinal canal syndrome. *Radiology.* 1973;107:89-97.
- Granier N, Kressel HY, Schiebler ML, Grossman RI, Dalinka MK. Normal and degenerative posterior spinal structures: MR imaging. *Radiology.* 1987;165(2):517-25
- Hamanishi C, Matukura N, Fujita M, Tomihara M, Tanaka SJ. Cross sectional area of the stenotic lumbar dural tube measured from the transverse views of magnetic resonance imaging. *J Spine Disord.* 1994;7:388-93.
- Sasaki K. Magnetic resonance imaging findings of the lumbar root pathway in patients over 50 years old. *Eur Spine J.* 1995;4(2):71-76.
- Wildermuth S, Zanetti M, Duewell S. Lumbar spine: quantitative and qualitative assessment of positional (upright flexion and extension) MR imaging and myelography. *Radiology.* 1998;207(2):391-8.
- Annertz M, Holtas S, Coronqvist S, Jonsson B, Stromqvist B. Isthmic lumbar spondylolisthesis with sciatica: MR imaging versus myelography. *Acta Radiol.* 1990;31:49-53.
- Deutman R, Diercks RL, de Jong TE, van Woerden HH. Isthmic lumbar spondylolisthesis with sciatica: the role of the disc. *Eur Spine J.* 1995;4:136-8.
- Hashimoto M, Watanabe O, Hirano H. Extraforaminal stenosis in the lumbosacral spine: Efficacy of MR imaging in the coronal plane. *Acta Radiol.* 1996;37:610-3.
- Herzog RJ. The radiologic evaluation of lumbar degenerative disk disease and spinal stenosis in patients with back or radicular symptoms. *Instr Course Lect.* 1992;41:193-203.

25. Young PY, Alias NAA, Shuaib IL. Correlation of clinical presentation, radiology and magnetic resonance imaging for low back pain- a preliminary survey. *J HK Coll Radiol.* 2003;6:144-51.
26. Colhoun E, Mc Call IW, Williams L, Pullicino CVN. Provocation discography as a guide to planning operations on the spine, *J Bone Joint Surg.* 1988;70:267-71.
27. Willems PC, Elmans L, Andersen G, van der Schaaf DB, de Kluever M. Provocative discography and lumbar fusion: is preoperative assessment of adjacent discs useful? *Spine.* 2007;32(10):1094-9.
28. Krenier S, Summers J, Shaffer WO, Toton J, Baisden J, Hwang S, et al. Diagnosis and treatment of degenerative spinal stenosis. *North Am Spine Soc.* 2011;14.

Cite this article as: Chougule SR. Comparison of plain X-ray and MRI findings by determining the sensitivity and specificity in the diagnosis of lumbar spinal stenosis in rural population. *Int J Res Med Sci* 2023;11:213-8.