

## Original Research Article

# The role of magnetic resonance imaging in non-traumatic chronic hip joint pain in adult rural population

Soneshkumar R. Chougule\*

Department of Radiology, B. K. L. Walawalkar Rural Medical College, Ratnagiri, Maharashtra, India

**Received:** 30 August 2022

**Revised:** 29 September 2022

**Accepted:** 08 November 2022

### \*Correspondence:

Dr. Soneshkumar R. Chougule,

E-mail: [sonesh.chougule@yahoo.com](mailto:sonesh.chougule@yahoo.com)

**Copyright:** © the author(s), publisher and licensee Medip Academy. This is an open-access article distributed under the terms of the Creative Commons Attribution Non-Commercial License, which permits unrestricted non-commercial use, distribution, and reproduction in any medium, provided the original work is properly cited.

## ABSTRACT

**Background:** Magnetic resonance imaging (MRI) has changed the face of diagnostic techniques; it has been used for diagnosing the hip pathologies and is the earliest applications of MRI in diagnosing musculoskeletal disorders. MRI detects articular, extra articular and osseous pathologies in hip joint. Thus, is important in diagnosing the cases of chronic hip pain which indicates a long list of causes. MRI is also the investigation of choice for imaging avascular necrosis, radiographically occult fractures, marrow replacement disorders, musculoskeletal neoplasms, and various arthritides involving the hip joint.

**Methods:** This study was done to assess the role of MRI in non-traumatic chronic hip joint pain in adult age group. The study included 54 patients with hip pain who were evaluated by plain radiograph and MRI.

**Results:** Majority (42.59%) of the patients were from the age group of 31-50 years, majority of the patients, 36 were males (66.67%). Most common chief complaint was unilateral hip pain (79.6%), and most common pathology found was avascular necrosis in 27 cases (50%). There was no significant association between the age groups and AVN ( $p=0.582$ ), while gender showed significant association with AVN ( $p=0.021$ ). Plain radiograph was abnormal in 41 out of total 54 cases (75.93%). The accuracy of detecting etiology by MRI in current study was 96.2% as compared to plain radiograph was 75.9% in current study.

**Conclusions:** Thus, MRI was seen to be more effective in diagnosing cases of painful hip joint where plain radiographs may be entirely normal.

**Keywords:** MRI, AVN, X ray, Hip joint

## INTRODUCTION

One of the most revolutionary advances in the field of medicine that has essentially changed the face of diagnosis is magnetic resonance imaging (MRI). One of the earliest reported uses of musculoskeletal MRI is imaging of the hip. In the last few years, advantages such as reduced scan time and better image quality have significantly widened the scope of MRI.<sup>1</sup>

MRI is a highly specific and sensitive technique for detecting a number of abnormalities involving the hip and

surrounding tissues i.e. it helps in evaluation of articular, extra articular and osseous structures which can be affected by hip pathology. The hip is an important weight-bearing joint. Hip pain is an indication with a long list of etiologies including intraarticular, periarticular and extraarticular disorders.<sup>2</sup>

The exact origin of hip pain determination can be quite challenging.<sup>3</sup> Therefore, to maintain an awareness of neighboring structures as well as of the hip is important.<sup>5</sup> In the absence of known acute trauma, hip pain is a common diagnostic problem.<sup>4</sup>

MRI is also the modality of choice for imaging avascular necrosis, radiographically occult fractures, marrow replacement disorders, musculoskeletal neoplasms, and various arthritides involving the hip joint.<sup>6</sup>

**Aim**

Aim of the research was to study MRI appearance in non-traumatic chronic hip joint pain in adult patients and correlate them with plain radiograph.

**METHODS**

**Study population**

A plain radiograph and cross-sectional study was carried out on 54 patients over a period from May 2021 to June 2022 in the BKL Walawalkar Rural Hospital.

**Inclusion criteria**

Patients of both the sexes of adult age group (above 18 years); and non-traumatic clinically suspected cases of chronic hip joint pain: patients with unilateral or bilateral groin, buttock, thigh or knee pain, deformity or limitation of range of hip movement were included.

**Exclusion criteria**

Patients with history of trauma, having claustrophobia, with history of metallic implants insertion, cardiac pacemakers and metallic foreign body in situ, and patients with previous history of hip surgery were excluded.

MRI was performed using PHILIPS 1.5-TESLA MR system. All the patients undergone conventional hip AP and lateral radiographs on preceding the MRI examination.

The patient was asked to lie in supine position with the hip in close relation to the array surface body coil and both hips were examined simultaneously. Spin-echo T1-weighted (coronal/sagittal), PD FAT SAT (coronal/axial), T2-weighted (oblique sagittal) sequences of both hips sequences were performed. Intravenous contrast (Gadolinium @ 0.1 mmol/kg) was administered when needed based on the MRI findings.

**RESULTS**

Fifty-four patients with unilateral or bilateral hip pain of adult age groups and both sexes were studied by plain radiograph and MRI scan.

Most of patients i.e. 23 (42.59%) in our study were from 31–50 years of age, followed by more than 50 years 18 (33.33%) and lastly 19–30 years 13 (24.08%). Majority of the patients, 36 were males (66.67%) and rest 18 (33.33%) were females. The ratio of male: female came out to be 2:1.

The most common chief complaint in our patients was unilateral hip pains in 43 (79.6%) patients {(left hip pain-24 (44.44%) followed by right hip pain-19 (35.19%) patients}. Other presenting complaints were backache 9 (16.67%), bilateral hip pains 8 (14.81%), and bilateral lower limb pains with limitation of limb movements 6 (11.11%), fever 5 (9.2%), swelling 3 (5.565) and pain in the thighs 1 (1.85%) patients respectively.

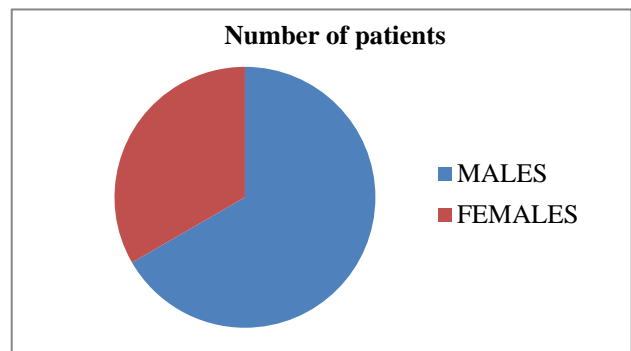
The study revealed pathological findings in 52 patients. Out of which the most common finding encountered in our study was avascular necrosis (50 %). Followed by sec. osteoarthritis (24.07%). All the tumours (including primary and secondary) together constituted 13.97% while infective pathologies 11.96% of the patients.

AVN was seen in half cases (27 cases – 50%), Majority of the AVN cases- 13 (48.15%) were from age group of 31–50 years, more than 50 years of age had 9 (33.33%) of cases and rest 5 (18.52%) were from 19- 30 years. In 27 cases without avascular necrosis, majority of patients 10 (37.04%) were from the age group of 31–50 years, 8 (29.63%) were from 19–30 years and rest 9 (33.33%) were from more than 50 years of age. There was no any association between age groups and presence of pathologies especially Avascular necrosis (p=0.582) in current study.

We saw a greater number of males in our study -22 with AVN than females - 5. There was significant association between presence of AVN and gender. (p=0.021).

Out of the 27 AVN cases, we had majority- 12 (44.44%) patients with left hip AVN, Right hip AVN was seen in 11 (40.74%) cases and bilateral was seen in 4 (14.82%) cases. So, in total we had 27+4=31, 31 total number of hips with AVN.

Majority of our patient’s hips (41.93%) were from stage IV of AVN, while others were in stage II (19.35%), stage III (19.35 %) and stage I (6.45 %).



**Figure 1: Sex wise distribution.**

Out of a total of 54 cases, plain radiographs were abnormal in 41 patients (75.93%) and normal in remaining. 13 cases

(24.07%), with most common diagnosis seen as AVN and osteoarthritis in 13 patients each (24.07%).

**Table 1: Age wise distribution of patients.**

Age (years)	Number of patients	Percentage
19-30	13	24.08
31-50	23	42.59
More than 50	18	33.33

**Table 2: Clinical characteristics of patients.**

Diagnosis	Number	Percentage
VN	27	50
Secondary OA	13	24.07
All tumours	08	13.97
Inf. pathologies	06	11.96

Out of all 52 (96.30%) abnormal cases detected on MRI, plain radiograph was abnormal in 41 patients, 11 cases more (20.37%) were seen on MRI. Sensitivity of X-ray in comparison with MRI was 78.8% and specificity was 100%. The accuracy of detecting etiology by MRI was 96.2% as compared to plain radiograph is 75.9% in our study.

**Table 3: Outcome of study.**

Plain radiograph	MRI (%)		Total (%)
	Normal	Abnormal	
Normal	2 (3.70)	11 (20.37)	13 (24.07)
Abnormal	0 (0)	41 (75.93)	41 (75.93)
Total	2 (3.70)	52 (96.30)	54 (100)

**DISCUSSION**

The hip is a primary weight-bearing joint. Hammer mentioned that in absence of known acute trauma, hip pain is a common diagnostic problem with many etiologies.<sup>7</sup> MRI is the most sensitive mean of diagnosing AVN, representing the gold standard of non-invasive diagnostic evaluation.

Fifty-four patients were evaluated, whose age group range from 19 years and above, in which majority 23 (42.5%) from age group of 31-50 years, followed by more than 50 years (33.33%) and then 19-30 years (24.08%). Similar age wise distribution was seen in Tushar et al study.<sup>8</sup> The study by Kumar et al had most of the patients from 41-50 years of age group similar to the current study.<sup>9</sup> In the present study, out of 54 patients, majority were (66.67%) males and rest (33.33%) females. Male predominance was seen in the study by Kumar et al, similar to the current study.<sup>9</sup> Male: female ratio of 2: 1. Mitchell et al got a gender ratio of 1.43:1 and Beltran et al got 1.7:1.<sup>10,11</sup> Thus, in our study, we got a slightly higher gender ratio.

The commonest chief complaint in our patients was chronic hip pain. Out of 54 cases, unilateral hip pain

(79.6%) {(left hip pain (44.44%) followed by right hip pain (35.19%)}. Other presenting complaints were backache (16.67%), bilateral hip pains (14.81%), bilateral lower limb pains with limitation of limb movements (11.11%), fever (9.2%), swelling (5.565) and pain in the thighs (1.85%). The study by Venkatesh et al, had 57.6% who had unilateral pain while in our study there were 79% patients with unilateral hip pains which is higher.<sup>12</sup>

In the current study we come across with a wide range of lesions who presented with chronic hip pain. Out of 54 patients who were evaluated, the most common finding encountered in our study was avascular necrosis (50%). Followed by sec. osteoarthritis 13 (24.07%). All the tumours (including primary and secondary) together constituted 20.37% while infective pathologies 12.96% of the patients. Ragab et al studied 34 patients with hip pain using MRI and found similar spectrum of disease conditions prevalent in the population.<sup>13</sup>

In our study, avascular necrosis (AVN) turned-out to be the most common hip pathology i.e. 27 (50%) with age varying from 19 to 70 years. The most common involved age group was 31-50 years, which comprised (48.15 %) of the cases which was similar to Khanna et al and Kamal et al studies.<sup>14,15</sup>

In our study, we saw a greater number of males (81.485%) with AVN than females (18.52%). There was significant association between presence of AVN and gender (p=0.021). Study by Patterson et al on AVN had 83% male and 17% female patients.<sup>16</sup>

In the present study, AVN was present unilaterally in 23 patients (42.59%) and bilaterally in 4 patients (14.82%). These results were similar to the study by Patterson et al.<sup>16</sup> They concluded that, bilateral AVN was found in 64% cases, however bilateral AVN may not match in their class, so either AVN is developing with different speediness in both hips or it may have been started early in one hip. Majority of our patient’s hips (41.93%) were in stage IV of AVN, while others were in stage II (32.25 %), stage III (41.93%) and stage I (6.45 %).

In the present study, stage 4 was the most common stage of AVN present in 13 (41.94%) of the cases followed by stage II (32.25%) {stage II a=4 (12.9 %) and stage II b=6 (19.35%)}, stage III (19.35%) and stage I (6.45%). In current study, most of the patients (61.2%) were from advanced disease i.e. stages III and IV. Kamal et al in his study found that majority (85.87%) were diagnosed in advance evolutionary stages of disease, stage 3 and stage 4.<sup>15</sup>

Beltran et al stated that in early stages of avascular necrosis, diagnosis with the help of conventional radiography is difficult.<sup>11</sup> Hence, MR imaging is often used. Thus, the two main goals in MR imaging evaluation of early avascular necrosis are: determination of: extent of involvement of femoral head pathology and percentage of femoral head involved segment.

In our study the 2nd common pathology was sec. osteoarthritis 13 (24.0%), the study by Venkatesh et al, had 11% of osteoarthritis.<sup>12</sup> In the present study, bone marrow edema was found in 37 (68.5%) of the cases. All patients having bone marrow edema had hip pain. Koo et al in their study established that combination of AVN femoral head and bone marrow edema is strongly associated with hip joint pain.<sup>17</sup>

We had 7 cases with infective etiology (12.96%) including pyogenic arthritis (1.8%), synovitis with joint effusion (1.8%), abscess (1.8%), tubercular arthritis (1.8%), osteomyelitis (1.8%) and isolated joint effusion (3.7%). The study by Tushar et al had 12% patients with infection which is slightly less than the current study.<sup>8</sup> In the study by Chevrot et al had majority cases of infective etiology.<sup>18</sup>

Out of all 54 cases in our study, MR showed abnormality in 52 cases where as plain radiograph was abnormal in 41 patients. All the 41 patients with abnormal plain radiographs had an abnormal MRI study. Only 2 out of 13 patients had normal plain radiographs and normal MRI. Sensitivity of X-ray in comparison with MRI was 78.8% and specificity was 100%.

The apparent sensitivity of plain radiographs is higher than reported in other cases/studies as the patient's inclusion criteria was painful hip conditions and exclusion of normal individuals.

The accuracy of detecting etiology by MRI in current study was 96.2% as compared to plain radiograph was 75.9% in current study.

The similar findings were from study by Huang et al.<sup>1</sup>

### Limitations

Patient having claustrophobia and patient having history of metallic implants insertion, cardiac pacemakers and metallic foreign body in situ.

### CONCLUSION

In our study AVN is very common in 50% cases detected on MRI and 24% cases detected on plain radiograph, followed by osteoarthritis in 24% cases detected on each MRI and plain radiograph. The accuracy of detecting etiology by MRI in current study was 96% as compared to plain radiograph was 76%. MRI is investigative modality which is free from radiation and non-invasive and well tolerated by the patients.

*Funding: No funding sources*

*Conflict of interest: None declared*

*Ethical approval: The study was approved by the Institutional Ethics Committee*

### REFERENCES

1. Manaster BJ. Adult Chronic Hip Pain: Radiographic Evaluation. *Radio Graphics*. 2000;20:S3-25.
2. Tibor LM, Sekiya JK. Differential diagnosis of pain around the hip joint. *Arthroscopy*. 2008;24(12):1407-21.
3. Maslowski E, Sullivan W, Forster Harwood J, Gonzalez P, Kaufman M, Vidal A, Akuthota V. The diagnostic validity of hip provocation maneuvers to detect intra-articular hip pathology. *PM R*. 2010;2(3):174-81.
4. Troelsen A, Rømer L, Kring S, Elmengaard B, Søballe K. Assessment of hip dysplasia and osteoarthritis: variability of different methods. *Acta Radiol*. 2010;51(2):187-93.
5. Manaster BJ. Adult chronic hip pain: radiographic evaluation. *Radiographics*. 2000;20(1):S3-25.
6. Sadro C. Current concepts in magnetic resonance imaging of the adult hip and pelvis. *Semin Roentgenol*. 2000;35(3):231-48.
7. Hammer WI, editor. *Functional soft-tissue examination and treatment by manual methods*. Jones & Bartlett Learning. 2007.
8. Kalekar T. MRI evaluation of non traumatic painful hip joint. *Int J Contemp Med Surg Radiol*. 2018;3(1):155-60.
9. Arvind Kumar SM, Kumar NV. Radiological assessment of inter-prosthetic joint movement in bipolar hip hemiarthroplasty for fracture neck of femur. *Int J Orthop*. 2017;3(2):583-9.
10. Mitchell MD, Kundel HL, Steinberg ME, Kressel HY, Alavi AB, Axel LE. Avascular necrosis of the hip: comparison of MR, CT, and scintigraph. *Am J Roentgenol*. 1986;147(1):67-71.
11. Beltran J, Noto AM, Herman LJ, Mosure JC, Burk JM. Joint effusions: MR imaging. *Radiology*. 1986;158(1):133-7.
12. Mahadevan V, Sapthagirivasan V. Information processing of medical images for the detection of osteoporosis in hip region of interest. *Int J Innov Management Technol*. 2010;1(5):516.
13. Ragab Y, Emad Y, Abou-Zeid A. Bone marrow edema syndromes of the hip: MRI features in different hip disorders. *Clinical Rheumatol*. 2008;27(4):475-82.
14. Khanna AJ, Yoon TR, Mont MA, Hungerford DS, Bluemke DA. Femoral head osteonecrosis: detection and grading by using a rapid MR imaging protocol. *Radiology*. 2000;217(1):188-92.
15. Kamal D, Trăistaru R, Alexandru DO, Grecu DC, Mogoanta L. Epidemiologic Study of Avascular Necrosis of the Femoral Head. *Curr Health Sci J*. 2013;39(3).
16. Patterson RJ, Bickel WH, Dahlin DC. Idiopathic avascular necrosis of the head of the femur: a study of fifty-two cases. *JBJS*. 1964;46(2):267-400.
17. Koo KH, Kim R. Quantifying the extent of osteonecrosis of the femoral head. A new method using MRI. *J Bone Joint Surg*. 1995;77(6):875-80.

18. Chevrot A, Drape JL, Godefroy D, Dupont AM, Gires F, Chemla N, Pessis E, Sarazin L, Minoui A. Stress fractures. *Radiological Imaging of Sports Injuries.* Springer, Berlin, Heidelberg. 1998;235-49.
19. Huang GS, Chan WP, Chang YC, Chang CY, Chen CY, Yu JS. MR imaging of bone marrow edema and joint effusion in patients with osteonecrosis of the femoral head: relationship to pain. *Am J Roentgenol.* 2003;181(2):545-9.

**Cite this article as:** Chougule SR. The role of magnetic resonance imaging in non-traumatic chronic hip joint pain in adult rural population. *Int J Res Med Sci* 2022;10:2821-5.