

[CASE REPORT]

Pulmonary and Intestinal Involvement in a Patient with Myeloperoxidase-specific Antineutrophil Cytoplasmic Antibody-positive Hermansky-Pudlak Syndrome

Takatomo Tokito¹, Noriho Sakamoto¹, Hiroshi Ishimoto¹, Daisuke Okuno¹, Takuto Miyamura¹, Atsuko Hara¹, Takashi Kido¹, Kazuko Yamamoto¹, Hiroyuki Yamaguchi¹, Yasushi Obase¹, Yuko Akazawa², Ken Okamura³, Tamio Suzuki³, Yuji Ishimatsu⁴ and Hiroshi Mukae¹

Abstract:

A 26-year-old Japanese woman was admitted with a 1-month history of diarrhea, a high fever for a few days, and exacerbation of dyspnea. She was treated with an antifibrotic drug and long-term oxygen therapy for Hermansky-Pudlak syndrome-related pulmonary fibrosis. New ground-glass attenuation appeared on chest computed tomography (CT), and a colon biopsy showed an inflammatory cell accumulation with a high titer of myeloperoxidase (MPO)-specific anti-neutrophil cytoplasmic antibodies (ANCA). Systemic inflammation related to MPO-ANCA titer elevation was suspected. Steroid pulse therapy and intravenous cyclophosphamide improved chest CT findings and diarrhea. Therefore, immunosuppressant treatment should be considered for systemic inflammation related to MPO-ANCA.

Key words: Hermansky-Pudlak syndrome, pulmonary fibrosis, MPO-ANCA, granulomatous colitis, steroid pulse treatment, vasculitis

(Intern Med 62: 103-106, 2023)

(DOI: 10.2169/internalmedicine.9350-22)

Introduction

Hermansky-Pudlak syndrome (HPS) is a rare autosomal recessive disease characterized by the triad of oculocutaneous albinism, bleeding disorders, and systemic accumulation of ceroid pigments (1, 2). The disease can cause pulmonary, intestinal, renal, or cardiac dysfunction (3, 4). HPS is often complicated by interstitial pneumonia, characterized by pulmonary fibrosis, and can be fatal because of the progression of chronic respiratory failure. Immunosuppressants and steroids have no therapeutic effect, and antifibrotic drugs, such as pirfenidone, have shown little efficacy (5). In contrast, immunosuppressants, such as rituximab, are effective against granulomatous colitis, which is one of its complica-

tions (6, 7).

We herein report a patient with HPS and a high titer of myeloperoxidase (MPO)-specific anti-neutrophil cytoplasmic antibodies (ANCA) who developed granulomatous colitis and worsening of pulmonary dysfunction. This case was successfully treated by immunosuppressant therapy.

Case Report

A 26-year-old woman complaining of chronic dry cough was diagnosed with HPS 2 years ago due to the presence of interstitial pneumonia, oculocutaneous albinism, bleeding disorder, and an *HPS1* gene mutation. She was a non-smoker, and her medical and family history were not significant. She was being treated with the antifibrotic drug pir-

¹Department of Respiratory Medicine, Nagasaki University Graduate School of Biomedical Sciences, Japan, ²Tissue and Histopathology Section, Atomic Bomb Disease Institute, Nagasaki University, Japan, ³Department of Dermatology, Faculty of Medicine, Yamagata University, Japan and ⁴Department of Nursing, Nagasaki University Graduate School of Biomedical Sciences, Japan

Received: January 6, 2022; Accepted: April 24, 2022; Advance Publication by J-STAGE: June 7, 2022

Correspondence to Dr. Noriho Sakamoto, nsakamot@nagasaki-u.ac.jp

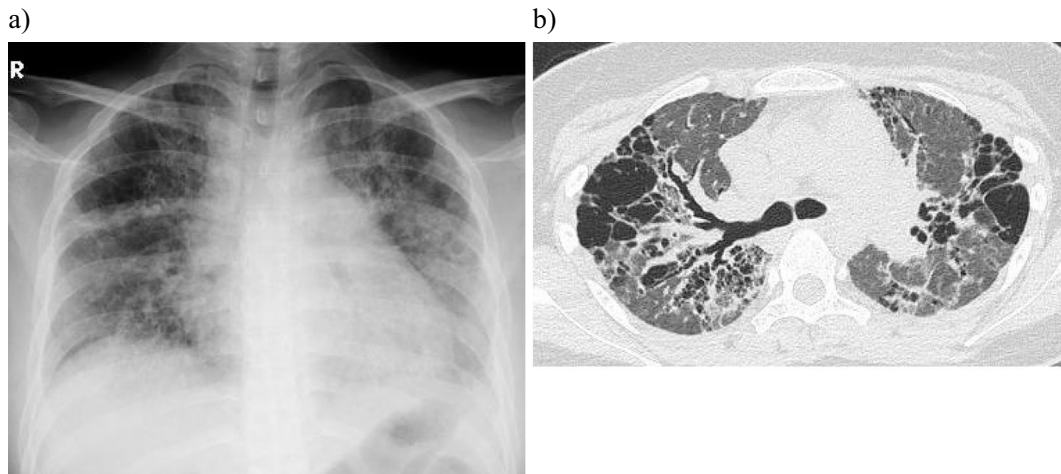


Figure 1. Radiological findings on admission. Chest radiography (a) and chest computed tomography (b) showed bilateral ground-glass opacities and cystic lesion.

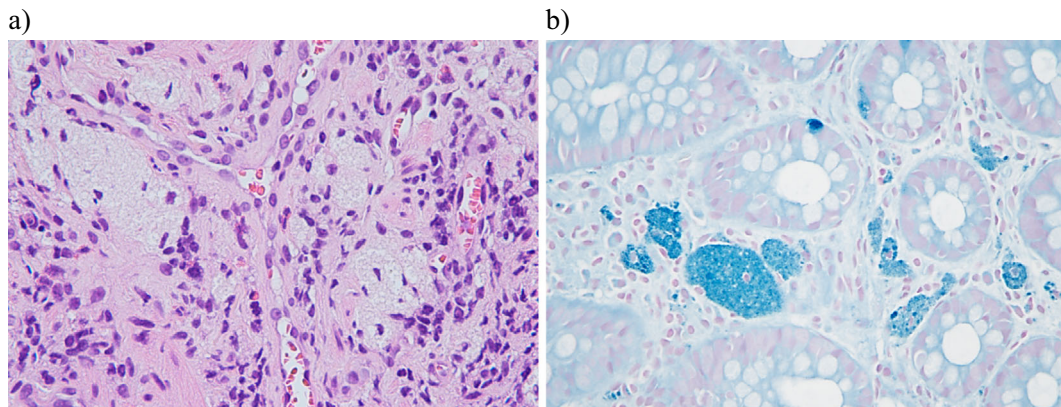


Figure 2. Histopathological findings of a colon biopsy. (a) Inflammatory cells infiltrating the interstitium and the accumulation of macrophages were observed (Hematoxylin and Eosin staining $\times 40$). (b) Macrophages that had phagocytosed ceroid-like granules were observed (Schmorl stain $\times 40$).

fenidone and long-term oxygen therapy.

She presented to our hospital with a one-month history of diarrhea, a high fever for the past few days, and exacerbation of dyspnea. There was no history of hemoptysis or bloody diarrhea. A physical examination on admission revealed a temperature of 38.0°C, blood pressure of 120/80 mmHg, pulse rate of 120/min, and respiratory rate of 28/min. Oxygen saturation was 92% on 3 L of oxygen administered through a nasal cannula. A pulmonary examination revealed fine crackles bilaterally. The abdomen was non-tender on palpation. Cyanosis and clubbing of the fingers were observed. Laboratory data showed a white blood cell count of 14,600/ μ L, hemoglobin of 14.1 g/dL, C-reactive protein (CRP) of 10.1 mg/dL, blood urea nitrogen of 5 mg/dL, creatinine of 0.54 mg/dL, immunoglobulin g (IgG) of 1,800 mg/dL, Krebs von den Lungen-6, an interstitial lung disease marker, of 470 U/mL, and titer of MPO-ANCA elevated to 281 U/mL. The results of an arterial blood gas analysis revealed a pH of 7.49, partial pressure (Pa) of CO₂ of 32.6 Torr, and PaO₂ of 53.0 Torr on 3 L of oxygen. Proteinuria or hematuria was not observed on a urine analysis.

Chest radiography findings showed newly developed diffuse bilateral ground-glass attenuation (Fig. 1a). High-resolution computed tomography (HRCT) revealed cystic lesions at the apices of both lungs, traction bronchiectasis, and newly developed diffuse bilateral ground-glass attenuation (Fig. 1b). The gross appearance of the intestinal tract on colonoscopy was unremarkable; however, a histopathological examination of a colon biopsy specimen showed inflammatory cell accumulation and macrophages that had phagocytosed ceroids, although there were no findings suggestive of vasculitis (Fig. 2a, b). Administration of antibacterial drugs did not relieve her pulmonary or intestinal symptoms. We suspected that HPS was complicated by MPO-ANCA-associated systemic inflammation, although histological findings suggestive of vasculitis were not demonstrated.

Steroid pulse treatment (methylprednisolone 1,000 mg/day for 3 days) provided symptomatic relief and led to the improvement of bilateral ground-glass attenuation on chest radiography and HRCT. However, the cystic lesions in both lungs worsened (Fig. 3a, b). We initiated intravenous cyclophosphamide therapy because her symptoms recurred during

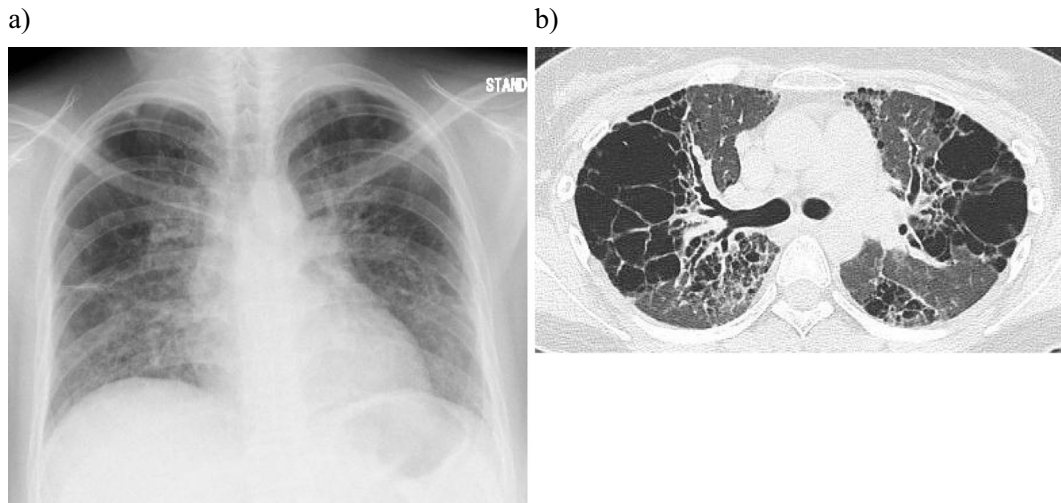


Figure 3. Radiological findings after two months of immunosuppressive therapy. Bilateral ground-glass opacities on chest radiography (a) and computed tomography (b) had improved compared with the imaging findings on admission.

tapering of steroids. The patient's general condition was improved, and the MPO-ANCA titer returned to normal. However, the patient died of respiratory failure progression six months after admission. She had shown no laboratory findings, such as IgG elevation, CRP elevation, anemia, and renal impairment, that were suggestive of vasculitis before her death. An autopsy was not performed.

Discussion

Our patient showed newly developed pulmonary infiltrates and granulomatous enteritis accompanied by a high titer of MPO-ANCA, which were improved after immunosuppressant treatment. The most important aspect of the present case is the involvement of MPO-ANCA in acute inflammation of the lungs and intestine.

Systemic complications of HPS are associated with the accumulation of ceroid-like material in the lysosomes of cells of various tissues. Ceroid accumulation is associated with pulmonary fibrosis, granulomatous enteropathy, and renal failure (3, 4, 8, 9). Patients with *HPS1* and *HPS4* mutations are prone to develop colitis, which occurs in 15-30% of cases (7, 10). In the present case, a histopathological analysis of the intestine showed ceroid deposition, suggesting that the cause of enteritis was granulomatous enteritis. Granulomatous enteritis has many characteristics similar to those of inflammatory bowel disease (IBD) and is considered to respond to the treatment of IBD, which is consistent with the course of our patient (11). ANCA is an antibody that reacts with cytoplasmic lysosomal enzymes of neutrophils and monocytes and is a known biomarker of vasculitis (12). ANCA is also elevated in chronic inflammation caused by non-vasculitis diseases, such as IBD (12-15).

Despite the elevation in MPO-ANCA titers, typical vasculitis symptoms, such as alveolar hemorrhaging or renal dysfunction, were not observed. Furthermore, histopathology

did not demonstrate vasculitis in the present case. These findings suggest that MPO-ANCA titers may increase due to chronic inflammation caused by granulomatous enteritis associated with HPS. The appearance of new lung lesions may be related to the systemic inflammation induced by granulomatous enteritis, instead of vasculitis. In contrast, a few reports documented cases of HPS complicated with MPO-ANCA-positive systemic vasculitis that were improved by steroid treatment (16, 17). We considered the MPO-ANCA elevation in this case not to have been associated with vasculitis. The persistent MPO-ANCA elevation might have induced vasculitis if immunosuppressive treatment had not been performed.

The role of MPO-ANCA in the pathogenesis of systemic inflammation in the present case is unknown. However, MPO-ANCA may be induced by HPS and play a pivotal role in systemic inflammation. Physicians should be aware of systemic inflammation related to MPO-ANCA, and the use of immunosuppressants should be considered, even though HPS is considered a steroid-refractory disease.

The authors state that they have no Conflict of Interest (COI).

References

- Hermansky F, Pudlak P. Albinism associated with hemorrhagic diathesis and unusual pigmented reticular cells in the bone marrow: report of two cases with histochemical studies. *Blood* **14**: 162-169, 1959.
- Velázquez-Díaz P, Nakajima E, Sorkhdini P, et al. Hermansky-Pudlak syndrome and lung disease: pathogenesis and therapeutics. *Front Pharmacol* **12**: 644671, 2021.
- Harada T, Ishimatsu Y, Nakashima S, et al. An autopsy case of Hermansky-Pudlak syndrome: a case report and review of the literature on treatment. *Intern Med* **53**: 2705-2709, 2014.
- Gordillo R, Del Rio M, Thomas DB, et al. Hypertension, chronic kidney disease, and renal pathology in a child with Hermansky-

- Pudlak syndrome. *Int J Nephrol* **2011**: 324916, 2011.
5. O'Brien K, Troendle J, Gochuico BR, et al. Pirfenidone for the treatment of Hermansky-Pudlak syndrome pulmonary fibrosis. *Mol Genet Metab* **103**: 128-134, 2011.
 6. Lozynska LY, Plawski A, Lozynska MR, et al. Variant of rare Hermansky-Pudlak syndrome associated with granulomatous colitis: diagnostics, clinical course and treatment. *Exp Oncol* **40**: 73-78, 2018.
 7. Mora AJ, Wolfsohn DM. The management of gastrointestinal disease in Hermansky-Pudlak syndrome. *J Clin Gastroenterol* **45**: 700-702, 2011.
 8. Gupta A, Utpat K, Desai U, Joshi JM. Hermansky-Pudlak syndrome with interstitial lung disease: a holistically worked up couplet. *Lung India* **36**: 345-348, 2019.
 9. Witkop CJ, Townsend D, Bitterman PB, Harmon K. The role of ceroid in lung and gastrointestinal disease in Hermansky-Pudlak syndrome. *Adv Exp Med Biol* **266**: 283-296; discussion 297, 1989.
 10. de Leusse AD, Dupuy E, Huizing M, et al. Ileal Crohn's disease in a woman with Hermansky-Pudlak syndrome. *Gastroenterol Clin Biol* **30**: 621-624, 2006.
 11. Girot P, Le Berre C, De Maissin A, et al. Crohn's-like acute severe colitis associated with Hermansky-Pudlak syndrome: a case report. *World J Gastroenterol* **25**: 1031-1036, 2019.
 12. Chen P, Zhou G, Lin J, et al. Serum biomarkers for inflammatory bowel disease. *Front Med (Lausanne)* **7**: 123, 2020.
 13. FijoŁek J, Wiatr E. Antineutrophil cytoplasmic antibodies (ANCA) - their role in pathogenesis, diagnosis, and treatment monitoring of ANCA-associated vasculitis. *Cent Eur J Immunol* **45**: 218-227, 2020.
 14. Mizuochi T, Arai K, Kudo T, et al. Diagnostic accuracy of serum proteinase 3 antineutrophil cytoplasmic antibodies in children with ulcerative colitis. *J Gastroenterol Hepatol* **36**: 1538-1544, 2021.
 15. Bosch X, Guilabert A, Font J. Antineutrophil cytoplasmic antibodies. *Lancet* **368**: 404-418, 2006.
 16. Nakamura T, Sato K, Hirai N, et al. Hermansky-Pudlak syndrome associated with myeloperoxidase-specific antineutrophil cytoplasmic antibody (MPO-ANCA). *Nihon Kokyuki Gakkai Zasshi* **37**: 224-229, 1999 (in Japanese, Abstract in English).
 17. Tagboto S, Carr S, Varghese A, et al. IgA nephropathy, antineutrophil cytoplasmic antibodies and crescentic glomerulonephritis in a patient with the Hermansky-Pudlak syndrome. *Am J Nephrol* **21**: 58-62, 2001.

The Internal Medicine is an Open Access journal distributed under the Creative Commons Attribution-NonCommercial-NoDerivatives 4.0 International License. To view the details of this license, please visit (<https://creativecommons.org/licenses/by-nc-nd/4.0/>).