



Case Study: A novel use for faecal microbial transplantation

V Ueckermann¹, EW Francis²

¹ MBChB, MMed (Internal Medicine), Cert Crit Care (SA), University of Pretoria

² B Dietetics, Zuid Afrikaans Hospital

Correspondence to: Veronica Ueckermann, email: Veronica.Ueckermann@up.ac.za

© SAJCN

S Afr J Clin Nutr 2019;32(1):42-46

Introduction

Faecal microbiota transplantation (FMT) refers to the infusion of faeces from a healthy donor, into the gastrointestinal tract of a recipient patient. There is considerable evidence for the efficacy of FMT for the treatment of recurrent *Clostridium difficile* infections and this treatment modality is recognised by the European Society for Microbiology and infectious diseases.¹⁻⁴

The introduction of culture-independent methods, detecting microbial DNA or RNA, to study bacteria has led to a surge of interest in the microbiome in both states of health and disease.⁵ FMT is a means to alter the components of the gut microbiome and, although currently the only registered indication for FMT is recurrent *C. difficile* infection, novel indications in a wide range of diseases, such as inflammatory bowel disease, irritable bowel syndrome, diabetes and various autoimmune diseases, have emerged in the literature.⁶

In the era of multi-drug resistance, the gut microbiome has become an area of keen interest. Dysbiosis of the gut microbiome is common in critically ill patients⁷ and there is an emerging role for the gut microbiome as a target for eradication of resistant organisms.⁸ We present a case where FMT was successfully used to prevent further episodes of sepsis in a patient with a multi-drug resistant organism.

Case study

A 60-year-old man was admitted to hospital with an episode of sepsis and septic shock. The source of sepsis was an infected pacemaker wire. He had further complications with acute kidney injury. Initial blood cultures revealed the offending organism to be *Klebsiella pneumoniae*, which was sensitive to all antibiotics except ampicillin. The pacemaker wire was removed and antibiotic therapy with cefepime was initiated. Other medical therapies included fluid resuscitation, thromboprophylaxis, ulcer prophylaxis, IV thiamin, vitamin C and solucortef. The latter three formed part of the metabolic resuscitation utilised by the treating practitioner.

Transoesophageal echocardiography did not reveal any vegetations on the valves, but a white cell localisation scan showed activity in the region of the aortic valve, and it was opted to treat the patient with a six-week course of antibiotics, as for infective endocarditis. He received adequate doses and prolonged infusions to maximise the time above minimum inhibitory concentration.

On admission, the patient's anthropometric values were as follows:

- Weight: 95 kg
- Height: 1.75 m
- BMI: 31 kg/m² (Class 1 Obesity)
- No unintentional weight loss prior to admission was reported.

The patient's Ideal Body Weight (IBW) was calculated as 77 kg, using a BMI value of 25 as reference.

Medical nutritional therapy was initiated on Day 5 post-admission. The patient had a history of decreased oral intake and, on initiation of nutritional therapy, consumed less than a third of his plate of food for the preceding three days. Nutritional requirements were calculated using the American Society for Parenteral and Enteral Nutrition (ASPEN) guidelines for Enteral Nutrition in Critically Ill patients.⁹ Adjustments were made for the acute kidney injury (protein 1.2–2 g/kg/d; energy 25–30 kcal/kg/d). No adjustments were made for electrolyte abnormalities, as all electrolytes were normal.

Oral nutritional supplements (ONS) were prescribed to provide 50% of the patient's protein requirements. On Day 7 post-admission the patient still had a sub-optimal oral intake and a nasogastric tube (NGT) was placed to commence enteral nutrition. Enteral nutrition was slowly increased over the next two days to reach a targeted rate of 75 ml/hr (Protein 1.2 g/kg IBW; Total Energy 25 kcal/kg IBW).

Two weeks after the initial presentation the patient presented once again with fever, rigors and raised inflammatory markers. Blood cultures were repeated and revealed the presence of *K. pneumoniae*, now multi-drug resistant, and requiring institution of a carbapenem (see Table I). Alternative sources of infection were sought and it was



Table I. Sequential blood cultures

BC	Date	Organism	Ampi / Amox*	Pip + taz*	Cefturoxime	Ceftroaxpime	Ceftriaxone	Cefepime	Imipenem	Meropenem	Ertapenem	Doripenem	Amikacin	Gentamicin	Tobramycin	Ciprofloxacin	Cotrimoxazole	Tigecycline	Colistin	
1	15/11/2017	Klebsiella pneumoniae	R	S	S	S	S	S	S	S	S	S	S	S	S	S	S	S	S	-
2	30/11/2017	Klebsiella pneumoniae	R	R	R	R	R	R	S	S	S	S	S	S	S	R	R	R	R	-
3	18/12/2017	Klebsiella pneumoniae	R	R	R	R	R	R	R	R	R	R	S	R	R	R	R	S	S	
4	31/12/2017	Klebsiella pneumoniae	R	R	R	R	R	R	R	R	R	R	R	R	R	R	R	S	S	

*Ampi=Ampicillin, Amox = Amoxicillin

**Pip+taz=Piperacillin tazobactam R=Resistant, S=Sensitive

found that the patient had diverticulitis.

The surgeon who had removed the septic pacemaker wire reported that a small segment of the pacemaker wire had been attached to the superior vena cava wall and was left in situ, as vascular injury was anticipated if removed. Thus, source control had not been fully achieved. The patient developed diarrhoea and cultures for *C. difficile* were negative. Multi-organ failure (MOF) and Acute Respiratory Distress Syndrome (ARDS) ensued, which required intubation, ventilation and inotropic support.

Amongst the failing organs was the gut, and enteral nutrition was no longer possible. Total parenteral nutrition (TPN) was initiated on Day 23 post-admission. TPN was calculated by using the European Society for Parenteral and Enteral Nutrition (ESPEN) guidelines for parenteral nutrition.¹⁰ We opted to use an all-in-one TPN bag, not containing additional glutamine, due to the presence of MOF. The patient presented with raised serum-potassium levels and was therefore started on an electrolyte-free TPN bag. (Requirements calculated at Protein 1 g/kg IBW; Total Energy at 20 kcal/kg IBW).

Several attempts to initiate enteral nutrition failed due to gastroparesis. A naso-jejunal feeding tube (NJT) was placed on Day 37 with the initiation of trickle feeds. Over the course of the following ten days, the TPN was slowly weaned and enteral feeds were increased via the NJT. TPN was stopped on Day 47, but unfortunately had to be recommenced on Day 49 due to blockage of the NJT. At this stage the patient still presented with unresolved gastroparesis. An NJT was reinserted and full enteral nutrition was restarted on Day 51 via the NJT. (Requirements calculated at Protein 1.4 g/kg IBW; Total Energy at 25 kcal/kg IBW). A percutaneous endoscopic gastrostomy tube (PEG) was inserted on Day 58. Over the next few days enteral nutrition was slowly initiated via the gastric route.

In the ensuing weeks, the patient suffered three episodes of sepsis and septic shock, each after an initial period of improvement. As illustrated in Figure 1, the organism cultured was still *K. pneumoniae* with a worsening resistance profile.

Antibiotics were adjusted according to culture results with each episode of sepsis. Doses were appropriate for a critically ill patient with enhanced renal clearance. Combination antibiotics were used once it became evident that the organism was becoming more resistant; for the second episode meropenem together with amikacin

was used; for the third amikacin, tigecycline and colistin and for the fourth episode colistin and tigecycline. With each episode of sepsis, potential additional sources were sought, and all lines and catheters replaced.

A candida parapsilosis was also cultured, not unexpected with the use of many broad-spectrum antibiotics, prolonged hospital stay, indwelling lines and the use of TPN. This was successfully treated with an echinocandin.

The patient survived the episodes of sepsis. He suffered from critical-illness-associated polymyoneuropathy and required intensive rehabilitation. Due to critical-illness polymyoneuropathy the patient's swallowing abilities were evaluated, with the use of the video swallow technique on Day 86, before the initiation of oral food. The patient suffered from silent aspiration on all food consistencies and therefore enteral nutrition was continued.

Upon resolution of his sepsis (defined by clinical improvement and normalisation of biomarkers), consideration was given to ways to address the dysbiosis of his gut microbiome. Review of the literature revealed case studies in which FMT was used to eradicate resistant microbes.⁸ After 16s rRNA sequencing was performed on the patient's stool, it was found that he had marked microbial diversity and predominance of multi-drug resistant organisms, as expected.

Figure 1 illustrates the marked dysbiosis in the microbiome of the patient. There was a loss of commensal microbiota in the patient, with a predominance of pathogenic organisms. Furthermore, there was a marked loss of microbial diversity.

Screening of the patient's wife as a potential donor was initiated, as per the European consensus statement.⁴ On history she had no known exposure to HIV, hepatitis, syphilis, Human T-cell lymphotropic virus or tuberculosis. She had no known metabolic or neurological disorders, no recent travel to tropical countries and no exposure to antibiotics, proton-pump inhibitors and immunosuppressants in the preceding six months.

Screening blood investigations in the donor included cytomegalovirus, Epstein Barr virus, Hepatitis A, B and C, HIV, syphilis, full blood count, albumin, C-reactive protein and erythrocyte sedimentation rate, creatinine, electrolytes, aminotransferases, gamma-glutamyltransferase and alkaline phosphatase. Stool was tested

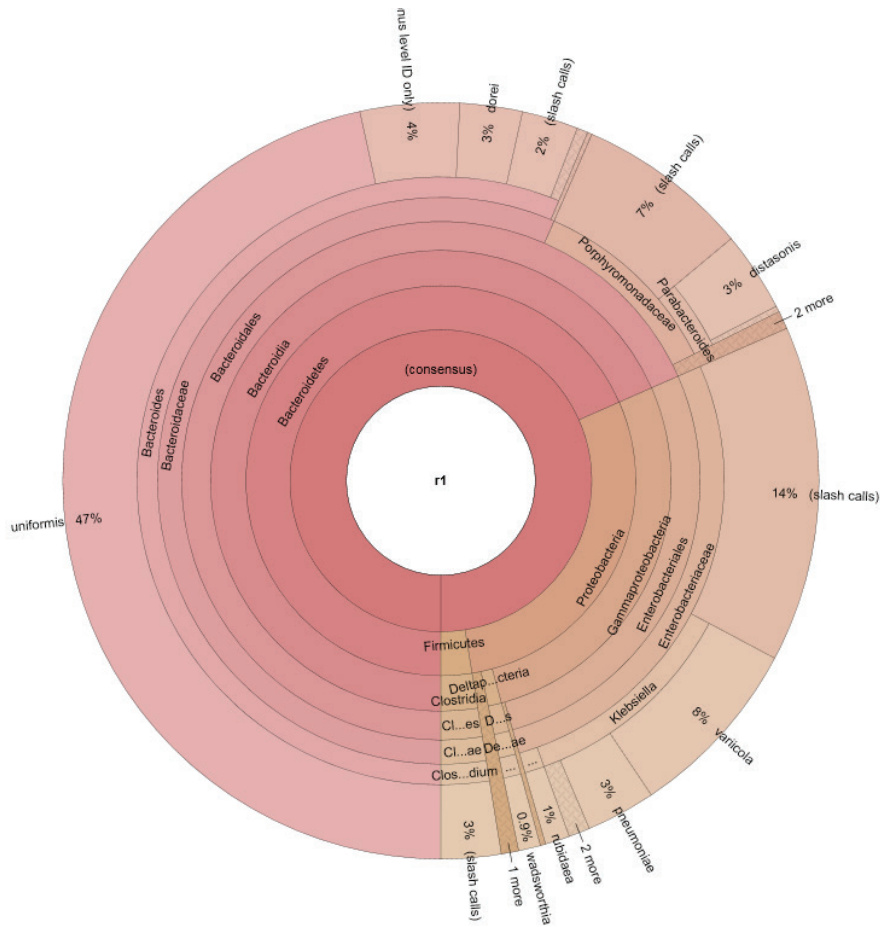


Figure 1. 16S rRNA sequencing of the patient's stool revealing marked loss of diversity and a loss of commensal organisms

for *C. difficile* and enteric pathogens. Occult faecal blood was performed. All the results of her investigations were normal.

Once she was deemed a suitable donor, after extensive counselling on the risks of FMT and informed consent had been obtained for the process, a transplant was performed. One hundred and fifty millilitres of faecal suspension were obtained by blending 30g of fresh donor stool with 0.9% saline. The faecal preparation was delivered to the patient via a naso-jejunal tube. He was kept in a 45 degrees upright position for four hours post-procedure. The procedure was without any complications and was repeated after two weeks.

Subsequent blood cultures did not show any bacterial growth and there were no further episodes of septicaemia. Enteral glutamine at a dosage of 0.3 g/kg was initiated as part of the GUT rehabilitation. Over the course of the next few weeks the patient improved significantly. The video swallow test was repeated on Day 106 and showed that the patient could swallow, without aspiration. Oral fluids were initiated with supplemental enteral nutrition through the PEG tube. The patient improved significantly and underwent post-ICU rehabilitation.

A permanent pacemaker was again inserted, and the patient was successfully discharged. At six-month follow-up the patient was well and recovering his physical strength. A repeat stool sample showed

eradication of the resistant *Klebsiella*.

Literature Review

Indications for FMT

FMT has been well-validated for recurrent *C. difficile* infection¹⁻⁴ and is at present the only FDA-approved indication for transplant. The effect is more durable than medical therapy, with a success rate of up to 95%.^{6,11,12} However, with the increasing awareness of the gut microbiome and the dysbiosis that occurs in diseased states, novel indications are emerging.

A body of evidence exists for the use of FMT in inflammatory bowel disease and irritable bowel syndrome.⁶ Mostly case reports and animal studies exist for more novel indications such as metabolic syndrome,^{13,14} neuropsychiatric diseases,¹⁴ haematological diseases¹⁵ and the eradication of resistant microbes.^{8,14}

Eight case reports were found in which FMT was used to eradicate resistant microbes.¹⁶⁻²³ The organisms in question were *Escherichia coli*, *K. pneumoniae*, methicillin-resistant *Staphylococcus aureus*, *Acinetobacter baumannii*, *Pseudomonas aeruginosa* and vancomycin-resistant *Enterococcus*. The follow-up period varied from two weeks to a year and seven of the studies reported subsequent eradication on cultures. The last case reported only a



reduction in post-FMT infections. Furthermore, one group reported a reduction in the number of antibiotic inactivation genes found in the stool of the patient post-FMT.¹⁶

Recently, a randomised controlled trial in patients with mild to moderate ulcerative colitis, showed that one week of treatment with donor FMT, as compared with autologous FMT, resulted in higher remission rates at eight weeks.²⁴

Donor screening

Rigorous screening of potential donors is essential to curb the risks associated with FMT. These risks include the transmission of infections including viruses (HIV, hepatitis, cytomegalovirus), resistant bacteria, clostridium and parasites. Furthermore, since there is a transfer of genetic material from the donor, autoimmune diseases, metabolic diseases (particularly diabetes and obesity), inflammatory bowel disease and even psychiatric conditions may be transferred to the recipient. A rigorous history should be obtained, including medical background, gastrointestinal symptoms, psychiatric history, travel history, medications used in the preceding six months and review of lifestyle habits to identify risk factors.⁴ Extensive blood and stool testing is then performed to check for any potentially transmittable diseases.⁴

Preparation and route of administration

Fresh stool should be used for the procedure and the stool should be used within six hours of defecation.²⁵ Storage and preparation should be brief in order to protect anaerobic bacteria and if storage needs to occur it should be at ambient temperature. A minimum of 30g should be used, suspended in saline using a blender. Commercial frozen stool capsules are available in some countries.

Donor stool may be administered via colonoscopy, via enema or via the upper gastrointestinal tract through a nasojejunal tube.⁴ Colonoscopic administration was shown to achieve a higher resolution rate in *C. difficile* infection,² however it requires more sophisticated equipment. Should the upper gastrointestinal route be used, care must be taken to avoid aspiration and the patient needs to be kept in a 45 degrees upright position for at least four hours. There is no proven benefit for the use of prokinetics in this scenario.⁴

Long-term complications

At present there is not enough long-term follow-up data on FMT-related diseases to assess long-term complications. Case reports include adverse events such as weight gain, rheumatoid arthritis, chronic constipation and idiopathic thrombocytopenic purpura.^{26,27} Causality could not be established in any of these cases. In animal models the transmission of autoimmune, malignant, metabolic and neuropsychiatric diseases after FMT has been demonstrated²⁸ and highlights the importance of appropriate donor screening.

The future

There are many promising indications for FMT in the literature with proof-of-concept case studies. However, robust randomised controlled trials are still lacking and long-term follow-up of patients

who have undergone FMT is needed to clearly delineate the associated risks and outcomes.

Conclusion

Traditionally the indication for FMT has been recurrent *C. Difficile* infection, with robust evidence to support its use in this context. However, in an era where the importance of the gut microbiome is being increasingly recognised, novel indications are coming to the forefront. Although further research is needed in the form of randomised controlled trials, FMT represents an exciting novel treatment modality to address various aspects of dysbiosis in the microbiome of patients.

References

1. Cammarota G, Masucci L, Ianiro G, et al. Randomized clinical trial: Faecal microbiota transplantation by colonoscopy with vancomycin for the treatment of recurrent *Clostridium Difficile* infection. *Aliment Pharmacol Ther*. 2015; 41(9):853-43.
2. Cammarota G, Ianiro G, Gasbarrini A. Faecal microbial transplantation for the treatment of *Clostridium difficile* infection: a systematic review. *J Clin Gastroenterol* 2014; 48:693-702.
3. Drekonja D, Reich J, Gezahegn S, et al. Faecal microbiota transplantation for *Clostridium difficile* infection: a systematic review. *Ann Intern Med* 2015; 162:630-638.
4. Cammarota G, Ianiro G, Tilg H, et al. European consensus conference on faecal microbiota transplantation in clinical practice. *Gut* 2017; 66:569-580.
5. Baumlér AJ, Sperandio V. Interactions between the microbiota and pathogenic bacteria in the gut. *Nature* 2016; 535:85-93.
6. Cohen N, Maharshak N. Novel Indications for faecal microbial transplantation: Update and review of the Literature. *Dig Dis Sci* 2017; 62:1131-1145.
7. Wolff N, Hugenholtz F, Wiersinga W. The emerging role of the microbiota in the ICU. *Crit Care* 2018; 22:78.
8. Bilinski J, Grzesiowski P, Muszynski J, et al. Faecal microbiota transplantation inhibits multidrug-resistant gut pathogens: Preliminary report performed in an immunocompromised host. *Archivum Immunologiae* 2016; 64:255-258.
9. McClave SA, Taylor BE, Martindale RG, et al. Guidelines for the provision and assessment of nutrition support therapy in the adult critically ill patient: Society of Critical Care Medicine (SCCM) and American Society for Parenteral and Enteral Nutrition (ASPEN). *JPEN* 2016; 40:159-211.
10. Singer P, Berger MM, Van den Berghe G, et al. ESPEN Guidelines on Parenteral Nutrition: Intensive Care. *Clinical Nutrition* 2009; 28:387-400.
11. Brandt LJ, Nroniadis OC, Mellow M, et al. Long-term follow-up of colonoscopic faecal microbiota transplant for recurrent *Clostridium Difficile* infection. *Am J Gastroenterol* 2012; 107:1079-1087.
12. Mattila E, Usitalo-Seppala R, Wuorela M, et al. Faecal transplant, through colonoscopy, is effective therapy for recurrent *Clostridium Difficile* infection. *Gastroenterology* 2012; 142:490-496.
13. Vrieze A, Van Nood E, Holleman F, et al. Transfer of intestinal microbiota from lean donors increases insulin sensitivity in individuals with metabolic syndrome. *Gastroenterology* 2012; 143(4):913-916.
14. Aroniadis O, Brandt L. Faecal microbiota transplantation: past, present and future. *Curr Opin Gastroenterol*. 2013;29:79-84.
15. Borody T, Campbell J, Torres M, et al. Reversal of idiopathic thrombocytopenic purpura with faecal microbiota transplantation. *Am J Gastroenterol*. 2011; 106:S352.
16. Millan B, Park H, Hotte N, et al. Faecal , reduce antibiotic-resistant genes in patients with recurrent *Clostridium difficile* infection. *Clin Infect Dis* 2016; 62:1479-1486.
17. Wei Y, Gong J, Zhu W, et al. Faecal microbiota transplantation restores dysbiosis in patients with methicillin resistant *Staphylococcus aureus* enterocolitis. *BMC Infect Dis* 2015; 15:265.
18. Bilinski J, Grzesiowski P, Muszynski J, et al. Faecal microbiota transplantation inhibits multidrug-resistant gut pathogens: Preliminary report in an immunocompromised host. *Archivum Immunologiae et therpiae experimentalis* 2016; 64:255-258.
19. Crum-Cianflone N, Sullivan E, Ballon-Landa G. Faecal microbiota transplantation and successful resolution of multidrug resistant organism colonization. *J Clin Microbiol* 2015; 53:1986-1989.
20. Freedman A, Eppes S. Use of stool transplant to clear faecal colonization with carbapenem-resistant Enterobacteriaceae (CRE): Proof of concept. Philadelphia: Infectious Disease Society of America; 2014.
21. Lagier JC, Million M, Fournier PE, et al. Faecal microbiota transplantation for stool decolonization of OXA-48 carbapenemase-producing *Klebsiella pneumoniae*. *J*



- Hosp Infect 2015; 90:173-174.
22. Singh R, Van Noord E, Niewdorm M, et al. Donor faeces infusion for eradication of extended spectrum beta-lactamase producing *Escherichia coli* in a patient with end stage renal disease. *Clin Microbiol Infect* 2014; 20: 0977-0978.
 23. Stripling J, Kumar R, Baddley J, et al. Loss of vancomycin-resistant enterococcus faecal dominance in an organ transplant patient with *Clostridium difficile* colitis after faecal microbiota transplant. *Open forum infectious diseases* 2015; 2: ofv078.
 24. Castello SP, Hughes PA, Waters O, et al. Effect of fecal microbial transplantation on 8-week remission in patients with ulcerative colitis. *JAMA* 2019;321(2):1560164.
 25. Satokari R, Matila E, Kainulainen V, et al. Simple faecal preparation and efficacy of frozen inoculum in faecal microbiota transplantation for recurrent *Clostridium difficile* infection – an observational cohort study. *Aliment Pharmacol Ther* 2015; 41:46-53.
 26. Brandt L, Armoados O, Mellow M, et al. Long-term follow-up of colonoscopic faecal microbiota transplant for recurrent *Clostridium difficile* infection. *Am J Gastroenterology* 2012; 107:1079-87.
 27. Alang N, Kelly CR. Weight gain after faecal microbiota transplant: a review of the literature. *J Hosp Infect* 2016; 92:117-27.
 28. Maschem AR, Gerner R, Wang J, et al. Lipocalin 2 protects from inflammation and tumorigenesis associated with gut microbiota alterations. *Cell Host Microbe* 2016;