

Probable abdominal compartment syndrome in an 8-month-old child

Sakher Awadalla^{1*}, Ahmed Kamal Mohamed²

1. Emergency Department, King's College Hospital London, Dubai, UAE.

2. Emergency Department, NMC Royal Hospital Khalifa City, Abu Dhabi, UAE.

*Corresponding author: Sakher Awadalla; Email: sakher.awadalla@yahoo.com

Published online: 2022-12-29

Cite this article as: Awadalla S, Mohamed AK. Probable abdominal compartment syndrome in an 8-month-old child. Front Emerg Med. In Press.

1. Case presentation

An 8-month-old, male child was brought to the emergency department (ED) by his parents with difficulty of breathing. The child developed shortness of breath for one day with cough, but he had no fever. According to the parents, they did not notice the abdominal distension. The child was born prematurely at 25 weeks of gestation and stayed in the neonatal intensive care unit (NICU) for 2 months. Otherwise, he was healthy with minor repeated chest infections and bronchiolitis. In triage, his vital signs were as follows: heart rate: 180 beats/min; respiratory rate: 35 breaths/min; temperature: 35°C; oxygen saturation: 70%; and his blood pressure was undetected. The child was immediately transferred to the resuscitation room. The primary survey showed that the patient was comatose with a Glasgow coma scale of 3/15, the pupils were brisk with an unstable airway, and there was bilateral diminished air entry. The oxygen saturation did not improve despite assisted ventilation using an Ambu bag. The central and peripheral pulsation was weak with a delayed capillary refill, and the blood glucose level was 9 mmol/L. The abdomen was hugely distended and rigid with minimal rectal bleeding. The patient was immediately intubated and connected to mechanical ventilation with subsequent rising of his oxygen saturation to 100%. A plain chest X-ray examination followed the patient's intubation (Figure 1a). Intravenous access was obtained followed by administration of normal saline (20 ml/kg) with subsequent elevation of the blood pressure (82/50 mmHg) and decrease in heart rate (160 beats/minute).

Initial arterial blood gases (ABG) analysis after intubation showed pH: 6.6; PaCO₂ >150 mmHg; PaO₂: 100 mmHg; HCO₃: 10 mEq/L; and lactic acid: 9 mg/dL. Therefore, a bolus of sodium bicarbonate was given, intravenously. Ventilator parameters were set at the maximum limits to wash out carbon dioxide. Repeated ABG analysis showed pH: 6.7; PaCO₂: 135 mmHg; PaO₂: 150 mmHg; HCO₃: 17 mEq/L; and lactic acid: 6.5 mg/dL. Immediate bedside abdominal X-ray (Figure 1b and c) and ultrasonography were carried out to rule out intussusception.

The child remained critically ill and unstable with fluctuating vital signs. Despite high ventilator parameters and gas-

tric tube suction, the child showed no improvement in the respiratory parameters. The child was then transferred to the operation theatre for decompression laparotomy, which showed small bowel (ileum) ischemia. After surgical decompression, the respiratory parameters improved, and the ventilator parameters were set back to normal settings for the patient's age and weight. Unfortunately, the child remained critically ill.

Then, he developed sepsis and multiple systems organ failure and died after 2 days.

2. Learning points

Patients with abdominal compartment syndrome (ACS) usually present with abdominal distension. Respiratory distress, tachycardia, and hypotension are also common findings (1). The presence of all these findings in our patient raised the level of suspicion of ACS diagnosis.

Imaging can be a useful aid in ACS diagnosis. On chest X-ray, the presence of unilateral diaphragmatic elevation, pleural effusions, or lobar collapse may suggest the diagnosis of ACS. Abdominal X-ray can confirm the diagnosis of intestinal obstruction (2). Abdominal pressure can be measured in several ways. Despite the accuracy provided by direct measurement using intraperitoneal catheters, its use is limited because it is invasive and may be accompanied by traumatic intestinal injury. Indirect measuring via nasogastric, intravesical, or intracolonic pressure transducers is an alternative diagnostic tool. Intravesical pressure monitoring via Foley catheter is the most commonly used method in adults and children (3). Abdominal perfusion pressure is the mean arterial pressure minus the intra-abdominal pressure (IAP). It was studied as a resuscitative endpoint in ACS, and it was superior to ABG and hourly urinary output (4).

The ideal treatment plan should include stabilizing the patient, treating the primary disease, and management of the ACS (5). Well-timed midline laparotomy is the most efficient method of reducing IAP if other treatment modalities are unsuccessful (6).

Despite its high mortality rates, ACS is still an underdiagnosed condition, especially among pediatrics. Delay in diagnosis and management has detrimental effects on patients.

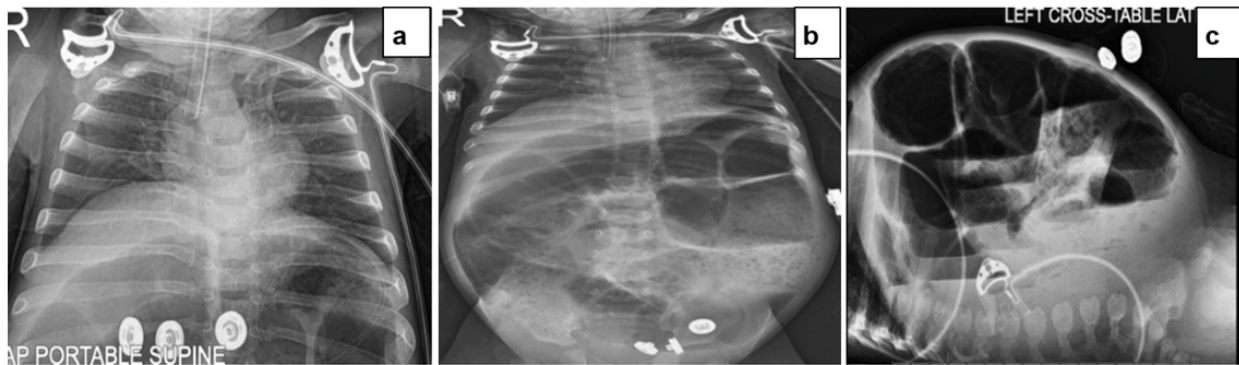


Figure 1 a: Chest X-ray showing an endotracheal tube in a low position; b: Anterior-posterior abdominal X-ray showing small bowel obstruction; c: Left lateral Abdominal X-ray showing marked distention of the whole length of the bowel loops.

Guidelines for timely diagnosis and management including decompressive laparotomy should be designed to avoid ACS consequences.

3. Declarations

3.1. Acknowledgment

None.

3.2. Authors' contribution

The authors meet all criteria for authorship based on the recommendations of the International Committee of Medical Journal Editors (ICMJE).

3.3. Conflict of interest

None.

3.4. Funding

None.

3.5. Consent for publication

We obtained the patient's parents' consent for publishing the case with no identifiable personal information.

References

1. Gottlieb M, Davenport DV, Adams S, Chien N. Current approach to the evaluation and management of abdominal compartment syndrome in pediatric patients. *Pediatr Emerg Care*. 2019;35(12):874-8.
2. Jackson P, Vigiola Cruz M. Intestinal obstruction: evaluation and management. *Am Fam Physician*. 2018;98(6):362-7.
3. Kirkpatrick AW, Roberts DJ, De Waele J, Jaeschke R, Malbrain ML, De Keulenaer B, et al. Pediatric guideline subcommittee for the world society of the abdominal compartment syndrome. Intra-abdominal hypertension and the abdominal compartment syndrome: updated consensus definitions and clinical practice guidelines from the world society of the abdominal compartment syndrome. *Intensive Care Med*. 2013;39(7):1190-206.
4. Cheatham ML, White MW, Sagraves SG, Johnson JL, Block EF. Abdominal perfusion pressure: a superior parameter in the assessment of intra-abdominal hypertension. *J Trauma*. 2000;49(4):621-6; discussion 626-7.
5. Padar M, Reintam Blaser A, Talving P, Lipping E, Starkopf J. Abdominal compartment syndrome: improving outcomes with a multidisciplinary approach-a narrative review. *J Multidiscip Healthc*. 2019;12:1061-74.
6. De Waele JJ, Hoste EA, Malbrain ML. Decompressive laparotomy for abdominal compartment syndrome: a critical analysis. *Crit Care*. 2006;10(2):R51.