

Roberto Cameriere · Luigi Ferrante · Dora Mirtella ·  
Mariano Cingolani

## Carpals and epiphyses of radius and ulna as age indicators

Received: 16 March 2005 / Accepted: 19 August 2005  
© Springer-Verlag 2005

**Abstract** Estimation of skeletal age using radiographic images is widely used for assessing biological growth in clinical and auxological studies. The most frequent areas used for age estimation in children and adolescents are tooth and wrist/hand, both giving good results with only a low level of radiation. In particular, ossification of the carpals shows good agreement with chronological age. This study of a sample of 150 Italian children and adolescents aged between 5 and 17 years focused on analyzing the possible applications of the proportion of carpal area (Ca) mineralization as a criterion of age estimation. The ratio between the total area of carpal bones and epiphyses of the ulna and radius (Bo) and Ca was calculated. This ratio (Bo/Ca) was used for linear regression analysis. The regression model, describing age as a linear function of the ratio Bo/Ca, yielded the following equation:  $\text{Age} = -3.253 + 0.719g + 20.610 \text{ Bo/Ca}$ , and explained 83% of the total variance ( $R^2 = 0.83$ ). The median of the absolute values of residuals (observed age minus predicted age) was 0.08 years, with a quartile deviation of 1.59 years, and a standard error of estimate of 1.19 years.

**Keywords** Age determination · Carpals · Linear regression · Illegal immigration

### Introduction

Estimation of skeletal age using radiographic images is one of the most important applications of X-ray analysis for assessing biological growth [1–5]. This method is used for diagnostic, prognostic, and therapeutic evaluation in auxologic pathology and also in forensic science.

The areas most often used for age estimation are tooth and wrist/hand, both giving good results with only a small amount of radiation.

With regard to the wrist and hand, the most important methods are those of Greulich and Pyle [6], the “atlas method” and TW3 [7], and FELS [8]. These methods analyze X-rays of the wrist/hand because, although this area is small, it has advantages with respect to other method, i.e., low levels of radiation, a simple radiographic position, and a significant number of bones.

In particular, ossification of the carpals shows good agreement with chronological age. Mineralization of this area begins at birth and lasts until approximately 13 years for girls and 15 for boys for carpals and 16–17 years for epiphyses of the ulna and radius [9].

The carpal area (Ca) is arranged in two transversal rows with four bones in each. The proximal row includes the scaphoid, lunate, triquetral, and pisiform bones, in the order from radial to ulnar, respectively. The second row is composed of trapezium, trapezoid, capitate, and lunate, again from radial to ulnar.

As changes in carpals are often not clear after 14–16 years, age estimation after the adolescent period is more difficult.

Good correlation between skeletal age and calendar age is used for forensic purposes, especially for personal identification. This problem is of particular significance in the European community, as a result of the large number of illegal immigrants without documents where age is unknown or unclear.

The above methods are important for evaluation of age in clinical studies as well as for forensic purposes.

This study was conducted on a sample of 150 Italian children and adolescents and analyzed the possible ap-

R. Cameriere (✉) · D. Mirtella · M. Cingolani  
Institute of Legal Medicine,  
University of Macerata,  
Via D. Minzoni 9,  
62100 Macerata, Italy  
e-mail: r.cameriere@unimc.it  
Tel.: +39-733-2582615  
Fax: +39-733-2582635

L. Ferrante  
Institute of Biochemical Biotechnologies,  
Faculty of Medicine,  
Polytechnical University of Marche,  
via Ranieri 65,  
60100 Ancona, Italy

plications of observed mineralization of the carpal area as a criterion of age estimation.

## Materials and methods

X-rays of wrist and hand taken from 150 Caucasian Italian children (89 boys and 61 girls) aged between 5 and 17 years were analyzed. X-rays were taken of the left hand, in the posteroanterior projection, and with fingers slightly splayed. The radiograms were produced under standardized conditions, following the indications of TW3. All the subjects included in the study did not display any growth disorders.

X-ray images of wrist and hand were processed using a computer-aided drafting (CAD) program (Adobe Photoshop 7, Adobe System Inc., 2001).

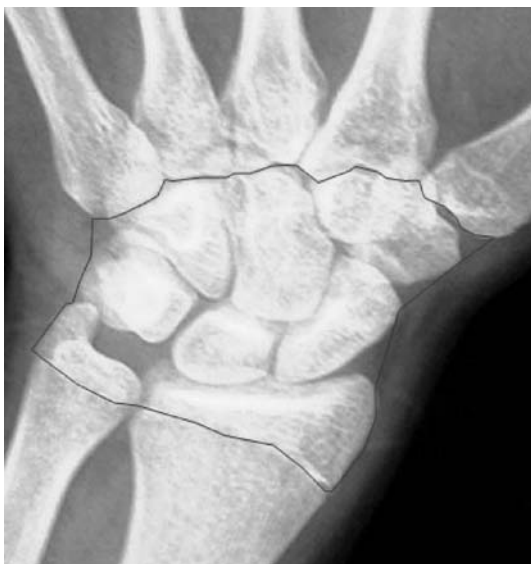The Ca and the epiphyses of ulna and radius were identified and defined by polygonal lasso instrument of Adobe Photoshop 7 software (Fig. 1). The pixels of the area were computed by CAD and are presented in a histogram.

The areas of the eight carpal bones were selected, and the pixel areas were calculated and added together to yield the global values of bone areas (Bo). If two bones overlapped, the common area was calculated only once (Fig. 2).

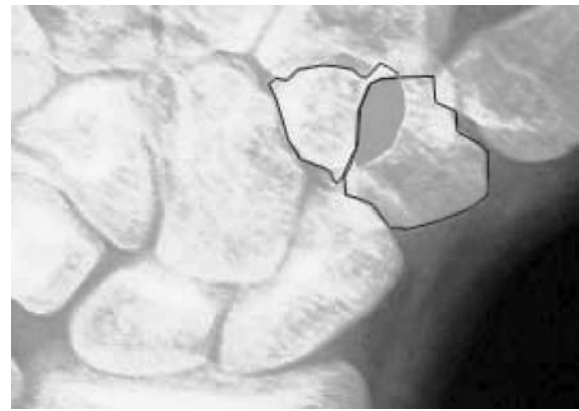
The Bo/Ca ratio between total area of bones and carpal area was calculated and used for linear regression analysis.

### Statistical analysis

A simple linear regression model was considered to describe the relation between age and the ratio (Bo/Ca). Analysis of covariance (ANCOVA) was then applied to study how gender affects the growth of the ratio Bo/Ca in the boys and girls groups.



**Fig. 1** An example of the carpal area selected using the polygonal lasso instrument of Adobe Photoshop 7 software



**Fig. 2** An example of correct selection of carpal bones. Distal board is defined by metacarpal board, and overlapping area between trapezium and trapezoid (*in gray*) is calculated only once

We fitted to the entire data set with the linear model  $Age = \beta_0 + \beta_1 g + \beta_2 Bo/Ca$  where  $g$  is the dummy variable equal to 1 for boys and 0 for girls. Furthermore, the model was used to test the hypothesis of equal intercepts ( $\beta_1 = 0$ ) and slopes  $\beta_2$  between boys and girls groups. Statistical analysis was performed with S-PLUS six statistical programs (S-PLUS 6.1 for Windows Professional edition Release 1). The significance threshold was set at 5%.

## Results

The analysis of covariance is reported in Table 1. The  $F$  test in the penultimate line of the table points out that the difference of the slopes in the regression models for boys and girls is not significant ( $p = 0.95$ ), which corresponds to the parallel regression lines. The parameter estimates of the model with equal slope but separate intercepts for boys and girls, using the least-squares method, are listed in Table 2. The regression model, describing age as a linear function of

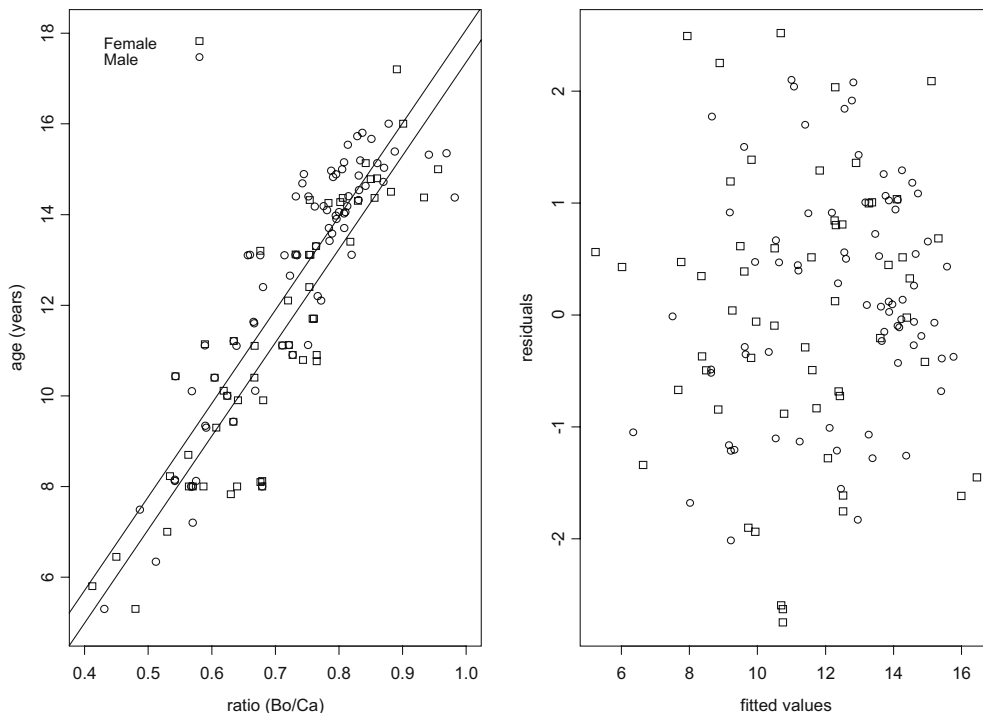
**Table 1** The ANCOVA table for the model

	<i>df</i>	SS	MS	<i>F</i> Value	<i>p</i>
<i>g</i>	1	74.37	74.37	51.69	<0.001
Bo/Ca	1	952.50	952.50	661.99	<0.001
<i>g</i> : Bo/Ca	1	0.005	0.005	0.004	0.95
Residuals	146	210.071	1.4388		

**Table 2** Regression analysis predicting chronological age from the percentage

Coefficients	Value	Standard error	<i>t</i> value	<i>p</i>
Intercept	-3.253	0.572	-5.690	<0.001
<i>g</i>	0.719	0.201	3.585	<0.001
Slope	20.610	0.798	25.817	<0.001

**Fig. 3** Plot of the data and regression lines (*left panel*) and plot of the residuals against the fitted values (*right panel*) by using a simple linear regression model (Eq. 1)



percentage, yielded the following linear regression formula (Fig. 3, left panel):

$$\text{Age} = -3.253 + 0.719g + 20.610 \text{ Bo/Ca} \quad (1)$$

This model explained 83% of total variance ( $R^2=0.83$ ). The median of the absolute values of residuals (observed age minus predicted age) was 0.08 years, with a quartile deviation of 1.59 years and a standard error of estimate of 1.19 years.

The residual plot (Fig. 3, right panel) shows no obvious pattern, and observations did not appear outside the expected boundaries. The regression lines (Fig. 3, left panel) show that the regression model fits the trend of the data reasonably well. Hence, both diagnostic plots support the chosen model.

## Discussion

The need to estimate the age of living individuals during their growth period is becoming increasingly important in forensic science. Guidelines for age estimation in living individuals in criminal proceedings [10] were published in the year 2000 (Table 3).

X-ray examination of the left hand is one of the most widely used procedures for age estimation, and several methods have been employed to study the morphological parameters of hand and wrist for this purpose[6–8].

This study analyzes a new method based on the mineralization of carpals for age assessment in a sample of 150 young individuals. This evaluation method (Bo/Ca ratio) correlates very well with subjects' chronological age

( $R^2=0.83$ ). According to the literature, equation Eq. 1 emphasizes the relation between age estimation and gender. In particular, the regression lines for both boys and girls are parallel, but the estimated ages for girls are 0.719 years below those for boys.

The Bo/Ca method (ratio between bone/carpal areas) yields a median of the absolute value of residual error of 0.08 years, and a standard error estimate of 1.19 years. These results highlight the fact that the accuracy of chronological age estimation based on this new method is comparable to that of the FELS and TW3 methods.

Nevertheless, Bo/Ca, using a global maturation index for the carpals, is easier to use than the FELS and TW3 techniques, which take into account many correlated measures to evaluate skeletal age.

In addition, processing X-ray images of wrist and hand using a CAD program reduces the between-subject variability observed when skeletal maturity is evaluated by means of an atlas and many qualitative predictors.

**Table 3** Guidelines recommended for age estimation in living individuals in criminal proceedings [10]

- 
- Physical examination, basic anthropometric measurements (weight, height, build); ascertainment of signs of sexual maturity (stage of pubic hair development according to Tanner); identification of any developmental disorders affecting age-appropriate development
- 
- X-ray study of hand and wrist
  - Dental maturity, determination of dental status and radiographic study of dentition
  - X-ray of medial clavicular epiphyseal cartilage is recommended to confirm age of 21
-

Possible future developments along the lines of the results presented in this study relate to investigations on the importance of single carpal bones and the possible addition of tooth growth information for better age estimation.

---

## References

1. Demirjian A, Goldstein H, Tanner JH (1973) A new system of dental age assessment. *Hum Biol* 45:221–227
2. Cameriere R, Ferrante L, Cingolani M (2004) Precision and reliability of pulp/tooth area ratio (RA) of second molar as indicator of adult age. *J Forensic Sci* 49:1319–1323
3. Mincer HH, Harris EF, Berryman HE (1993) The A.B.F.O. study of third molar development and its use as an estimator of chronological age. *J Forensic Sci* 38:379–390
4. Schmeling A, Schulz R, Reisinger W, Mühler M, Wernecke KD, Geserick G (2004) Studies on the time frame for ossification of the medial clavicular epiphyseal cartilage in conventional radiography. *Int J Leg Med* 118:5–8
5. Schulz R, Mühler M, Mutze S, Schmidt S, Reisinger W, Schmeling A (2005) Studies on the time frame for ossification of medial epiphysis of the clavicle as revealed by CT scans. *Int J Leg Med* (in press)
6. Greulich W, Pyle SI (1959) Radiographic atlas of skeletal development of the hand and wrist, 2nd edn. Stafford University Press, Stafford
7. Tanner JM, Healy MJR, Goldstein H, Cameron N (2001) Assessment of skeletal maturity and prediction of adult height (TW3 method). WD Saunders, London
8. Roche AF, Cameron Chumlea W, Thissen D (1988) Assessing the skeletal maturity of the hand-wrist: Fels method. Charles C. Thomas, Springfield
9. Scheuer L, Black S (2000) Developmental juvenile osteology, Academic Press, London
10. Schmeling A, Olze A, Reisinger W, Geserick G (2001) Age estimation of living people undergoing criminal proceedings. *Lancet* 358:89–90